



Volume 2, No 1 (2012) ISSN 2250- 0359

Secondary Tuberculosis of Tonsil case report and literature review

Dr T Balasubramanian, Dr U Venkatesan, Dr R Geetha

Abstract: A case report of secondary tuberculosis of tonsil is being discussed along with review of published literature. This report attempts to draw attention to the fact that Tuberculosis is resurgent despite excellent chemotherapeutic drugs available. This could be probably due to wide spread drug resistance, Immune deficiency states like Diabetes and HIV. Diagnosis of this condition needs a high index of suspicion. Biopsy should be performed in all these patients to rule out coexistent malignancy. Even though oral cavity is highly resistant to tuberculous infection due to the inherent bactericidal effect of saliva still cases of tuberculosis tonsil continue to be reported in developing countries like India.

Introduction:

Every year roughly about 8-10 million people worldwide contract Tuberculosis. Majority of these patients suffer from pulmonary tuberculosis. Every year 3 million die of Tuberculosis worldwide. According to W.H.O the largest number of new TB cases was reported from SE Asia region. Tuberculosis is still considered to be a scourge even today because of the increasing incidence of drug resistance² among Tubercle bacilli and wide prevalence of HIV³ infection.

Incidence of tuberculosis involving tonsillar tissue has been rather low. One study conducted by Weller during the years 1906-1919 reported the incidence to be 2.3%.

Wilkinson⁴ (1929) put the incidence to be about 0.5%. Abrol & Sinha⁵ (1965) reported nil incidence of tonsillar tuberculosis. This decline in incidence was attributed to widespread pasteurization of milk during that time.

Even though tonsil is a lymphoid tissue positioned critically where it is constantly drenched by infected sputum / saliva the incidence of tonsillar tuberculosis has remained rather low.

Probable reasons for this low incidence could be ⁶:

1. The antiseptic and cleansing action of saliva
2. Presence of saprophytes in oral cavity making colonization of tuberculous bacilli rather difficult
3. Thick protective stratified squamous epithelial surface covering of tonsil resistant to colonization by mycobacterium tuberculosis

4. Inherent resistance of tonsil to tuberculosis

Earliest references to Tubercle bacilli involving pharynx is credited to Virchow (1864) ⁷. Lermoyez demonstrated tubercle bacilli in adenoid tissue of 6 years old child. Dr Sims Woodhead⁶ Professor of Pathology Cambridge University in his paper titled “Channels of infections in tuberculosis” reviewed the various ways in which tuberculous bacilli enter the living organism. He concluded the portal of infection to cervical lymph nodes is via tonsil. Philip Mitchel in 1917 after performing autopsies on patients who died of tuberculosis of cervical nodes concluded that primary focus to be in the faucial tonsil. He thus advocated routine tonsillectomy for all patients with cervical tuberculous nodes.

Classification of tonsillar tuberculosis:

Irwin Moore’s classification: In his classic treatise on tonsillar tuberculosis Moore classified it into:

Primary tuberculosis of tonsil: Where there is tuberculosis of tonsil without involvement of lungs. He concluded that primary tuberculosis of tonsil could be due to Bovine strain of the organism.

Secondary tuberculosis of tonsil: In this category there is pulmonary involvement in addition to tonsillar tuberculosis.

Case Report:

53 years old male patient reported with complaints of:

1. Sore throat – 2 months duration
2. Painful swallowing – Odynophagia (2 months)

History revealed:

Loss of weight and appetite

Ear pain

Cough

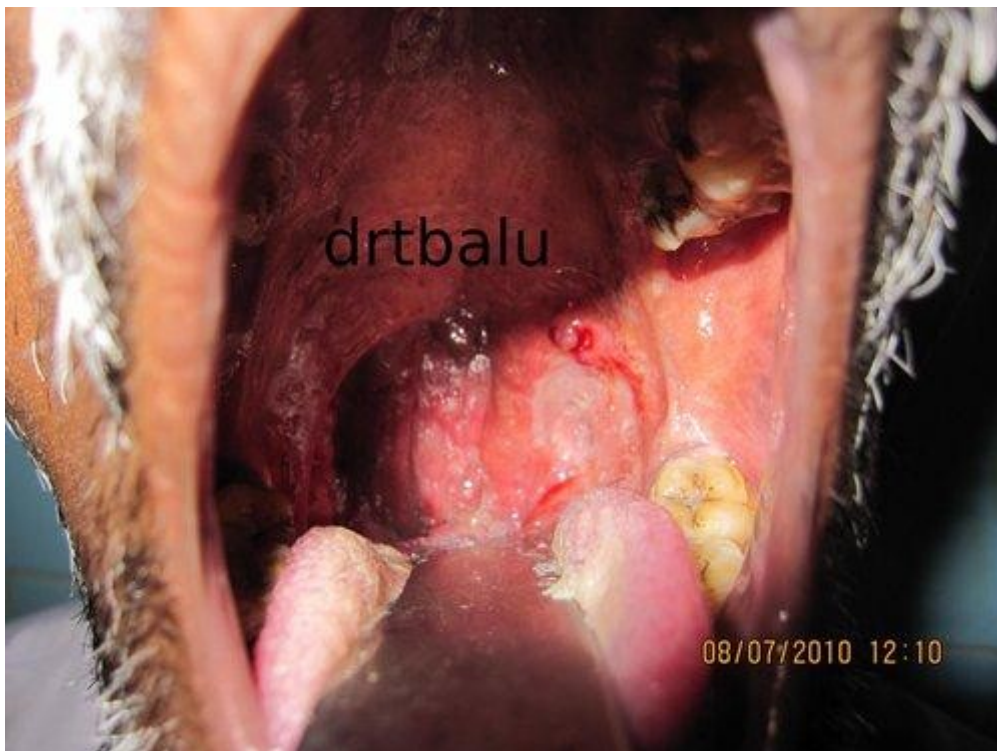
No history of haemoptysis / evening rise in temperature

He is a smoker and alcoholic.

Examination:

Patient was ill built.

Oral cavity: Revealed ulcerative lesion involving left tonsil. Anterior and posterior pillars were found to be eroded.



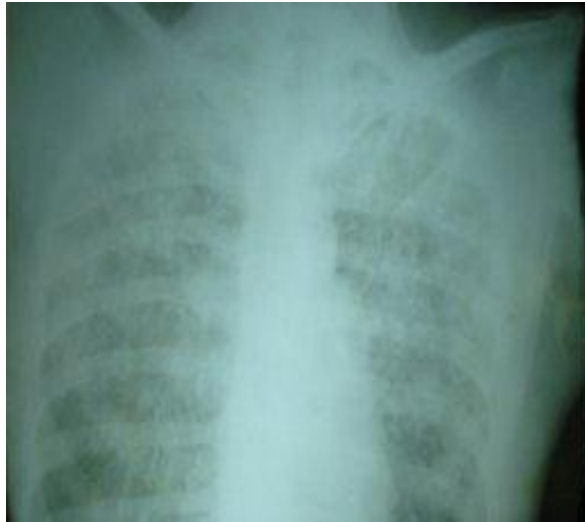Photograph showing ulceration of left tonsil with erosion of both pillars

Neck examination:

Revealed enlarged, tender, and mobile jugulodigastric node on the left side. It measured 3cms in its largest dimension.

X-ray chest:

Revealed military mottling.



X-ray chest revealed Miliary mottling

Sputum for AFB:

Revealed the presence of Acid fast Bacilli.

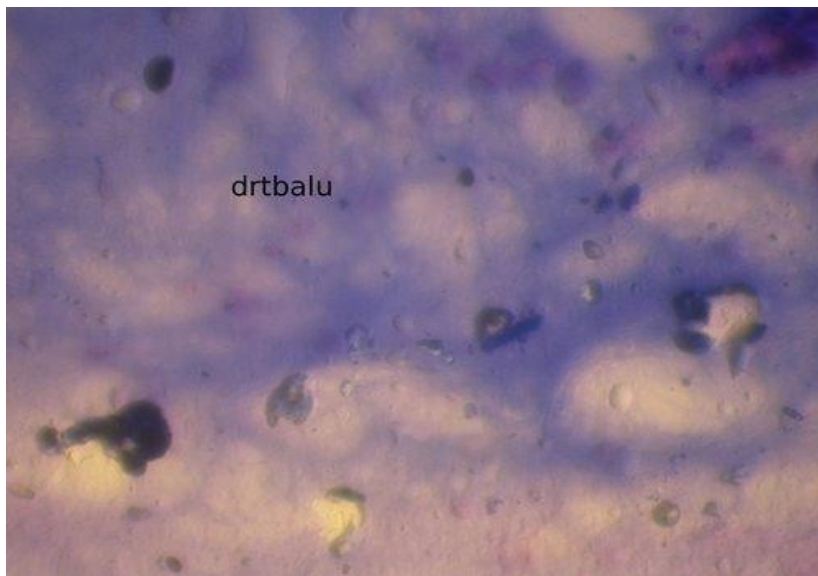
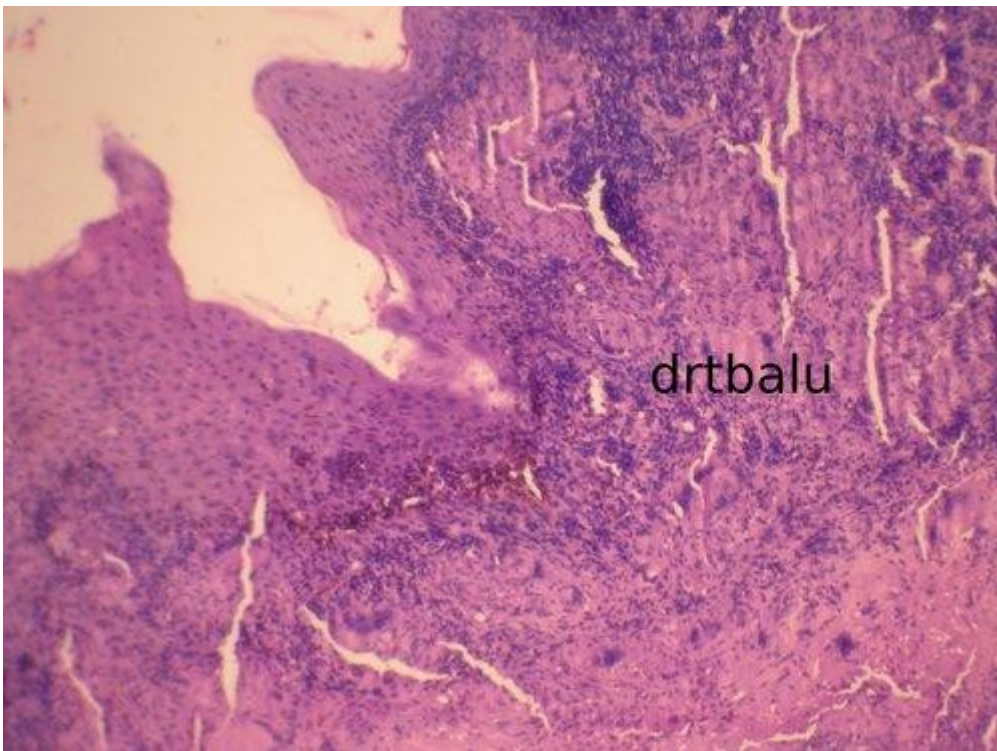


Image showing AFB in sputum

Biopsy was taken from the lesion to rule out malignancy as it could co-exist with tonsillar tuberculosis⁹.

Histopathology:

Section studied showed granulomatous lesion showing areas of caseation necrosis. Epithelial giant cells and Langhans giant cells were also seen.



Picture showing histopathology of the lesion

This patient was tested for HIV and was found to be negative.

Discussion:

Tuberculosis involving the tonsil is very rare. These days it is still rare because of better milk processing techniques like pasteurization which eradicates the bovine

<http://www.jorl.net/>

strain of tuberculosis. Even though tonsils are situated in an exposed area where infected material like sputum and food stuffs come into contact this lesion is rare because of the following features:

1. Antiseptic and cleansing action of saliva (first and foremost)
2. Presence of saprophytic organisms in the oral cavity which prevents growth of tubercle bacilli
3. The stratified squamous epithelial lining of the tonsil also offers some degree of protection

Tuberculosis of tonsils may be:

Primary - Due to ingestion of infected milk (Bovine strain)

Secondary - Due to pulmonary infection. The coughed out infected sputum finds its way to the throat to involve the tonsils.

Diagnosis of tuberculosis of tonsil is not straight forward. It needs high degree of suspicion.

Pointers for the diagnosis of tuberculosis tonsil:

1. Asymmetric enlargement of tonsil
2. Tonsillar enlargement without exudate
3. Obliteration of crypts
4. Painful deglutition
5. Presence of enlarged mobile jugulodigastric nodes

All these patients should undergo sputum examination as this could dictate the probable treatment modality. Sputum positive patient as the one reported in this case record should be started on multi drug regimen which includes 4 drugs.

INH

Rifampicin

Pyrazinamide

Ethambutol

Regimen I is indicated in all patients with tonsillar tuberculosis with AFB positive sputum.

This regimen includes:

Initial phase

INH

Rifampicin

Pyrazinamide

Ethambutol

Administered 7 days a week (once a day dose) (DOT) for 8 weeks.

Continuation Phase:

1. INH
 2. Rifampicin
- In two days a week dose for 18 days
- Followed by:
1. INH
 2. Rifampicin
- Once a day / week dose for 18 weeks.

References:

1. Dolin PJ, Paviglione MC, Kochi A. Estimate of future global Tuberculous morbidity and mortality. MMWR 1993;42:961 – 4
2. Drug resistance in Mycobacterium tuberculosis Rabia Jhonson etal online journal of www.cimb.org 8:97-112
3. HIV and tuberculosis in India Sowmya swaminathan etal J.biosci.33 527-537
4. Wilkinson HF (1929) Archives of otolaryngology 10, 127
5. Abrol and Sinha (1963) (thesis) AIIMS Delhi
6. Tuberculosis of tonsil - A rare site involvement U. jana, S Mukherjee Indian journal of otolaryngology and head and neck surgery vol 55 No2 April-June 2003
7. Tuberculosis of upper respiratory tract Paul L Chodush The laryngoscope May 1970
8. Dr Sims Woodhead Channels of infections in tuberculosis Lancet, 1894
9. Anim JT etal Tuberculosis of tonsil revisited West AFR J Med 1991;10:194-7

