



Yahya Basith * Balasubramanian Thiagarajan*

*Stanley Medical College

ROLE OF ANATOMICAL OBSTRUCTION IN THE PATHOGENESIS OF CHRONIC SINUSITIS

A case series study based on radiological assessment

Abstract

Sinusitis is a commonly diagnosed condition in the general population. This article is a study to assess the role of anatomical obstruction in the pathogenesis of chronic sinusitis, based on symptomatology and radiological findings of the patients. The frequency of major anatomical variants like deviated nasal septum, concha bullosa, and paradoxical middle turbinate leading to chronic sinusitis has been analyzed. In majority of cases the obstruction at osteomeatal complex is found to be caused by more than one factor.

Chronic rhinosinusitis

Definition: Group of disorders characterized by inflammation of the mucosa of the nose and para nasal sinuses of at least 12 consecutive weeks duration. Patients with CRS may have acute flare-ups, in such conditions the disorder is called acute exacerbation of chronic sinusitis.^[1,2]

Since it involves inflammation of the mucosa of nasal cavities as well as the paranasal sinuses, its more aptly termed as rhinosinusitis. There are several etiological factors leading to the development of chronic sinusitis. They are broadly classified in to three main groups i.e 1)genetic/physiological factors 2) environmental factors 3) structural factors.^[3]

Role of anatomical obstruction

Patency of the pathways through which the sinuses drain is crucial of adequate mucociliary function and subsequent sinus drainage. Nasal and sinus mucosa produces approximately 1 L of mucus per day^[4], which is cleared by mucociliary transport. Osteal obstruction may lead to fluid accumulation and stagnation, creating a moist, hypoxemic environment ideal for growth of pathogens^[4]

Major anatomic variants leading to osteo meatal obstruction are deviated nasal septum, concha bullosa, paradoxical middle turbinate and infra orbital (Haller) cell^[5].

Deviated nasal septum: Deviated nasal septum at the level of middle turbinate is one of the main causes of anatomical obstruction at osteo meatal complex.

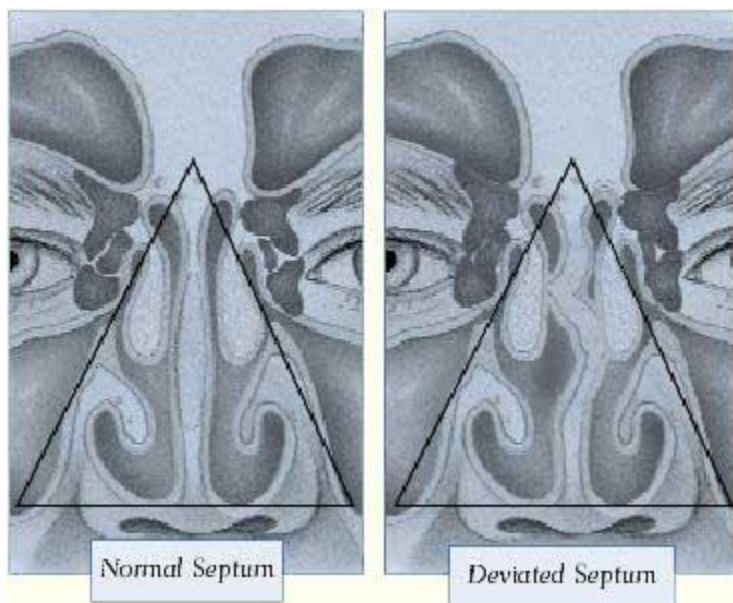


Figure: 1

Cottle classified septal deviation into 3 types i.e

- 1) Simple deviation: only mild deviation with no obstruction and it is the most common type seen.
- 2) Obstruction: here the deviated septum touches the lateral wall, but on decongestion with vasoconstrictors the turbinate shrinks and the obstruction is relieved.
- 3) Impaction: massive angulation of the septum with a spur^[6]

Patients with significant deviation i.e type 2 & 3, who is having CT evidence of sinusitis have been included in the study.

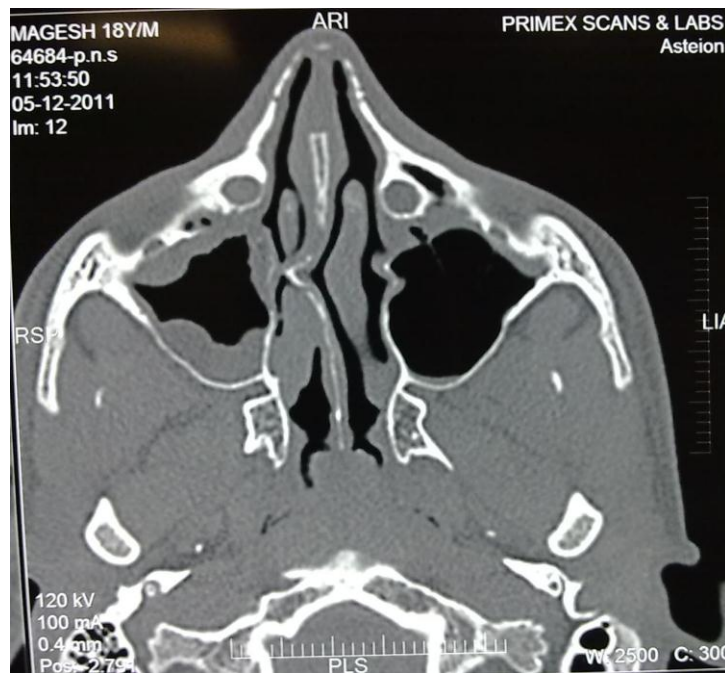
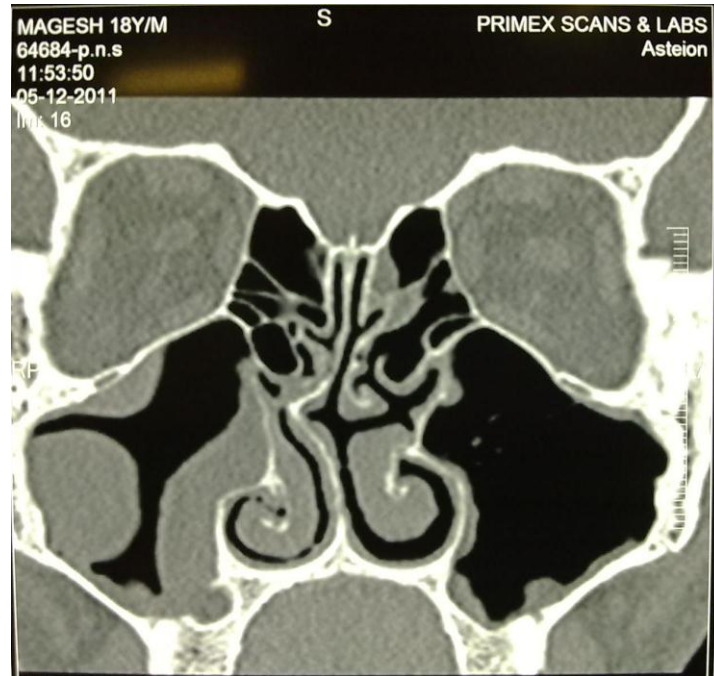


Figure 2: Coronal CT scan of a patient showing deviated nasal

Figure 3: axial cut of the same patient showing deviated septum.
Septum leading to OMC obstruction.

Concha bullosa: concha bullosa is pneumatisation of the concha, usually the middle turbinate and is one of the most common anatomic variation in nose. Bolger et al classified pneumatisation of the concha based on the location as lamellar concha bullosa, bulbous concha bullosa, and extensive concha bullosa.^[7] There are many studies in the literature suggesting the role of concha bullosa in sinus disease etiology. If the concha is expanded significantly, it leads to deviation or compression of the uncinate process to the lateral wall of nose leading to obstruction of the ethmoid infundibulum.

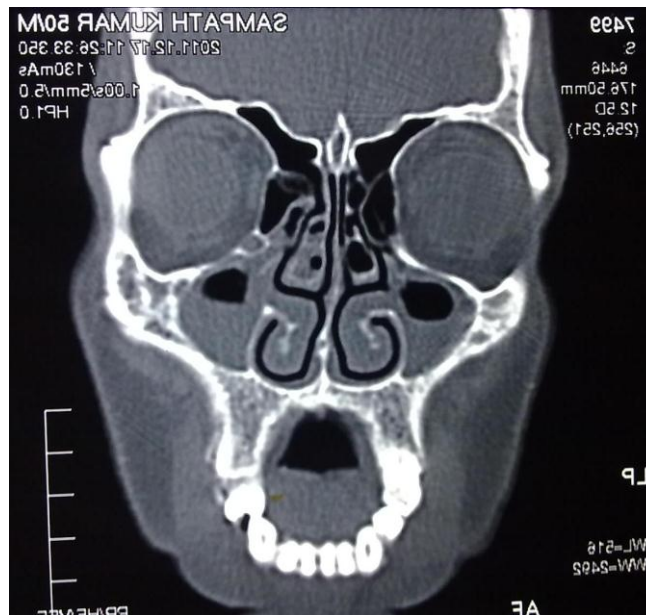
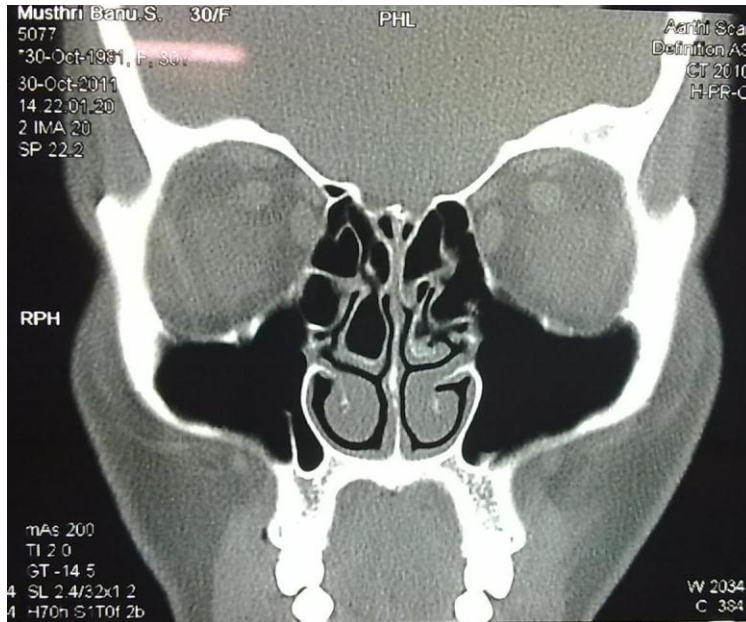

Figure 4: CT scan of a patient showing concha bullosa



1

Figure 5: CT image of another patient with extensive pneumatization of the right middle turbinate.

Paradoxical middle turbinate: another anomaly of the nasal cavity leading to air way obstruction and chronic sinusitis is a paradoxical turbinate. A middle turbinate that is concave medially rather than laterally is called paradoxical. Usually paradoxical turbinates occur where the maxillary sinus is hyperplastic. The overgrowth causes the mucosa to buckle and fold inwards, with the resultant curve pointing towards the septum. An exaggeratedly curved paradoxical turbinate compresses the uncinate process leading to meatal obstruction.

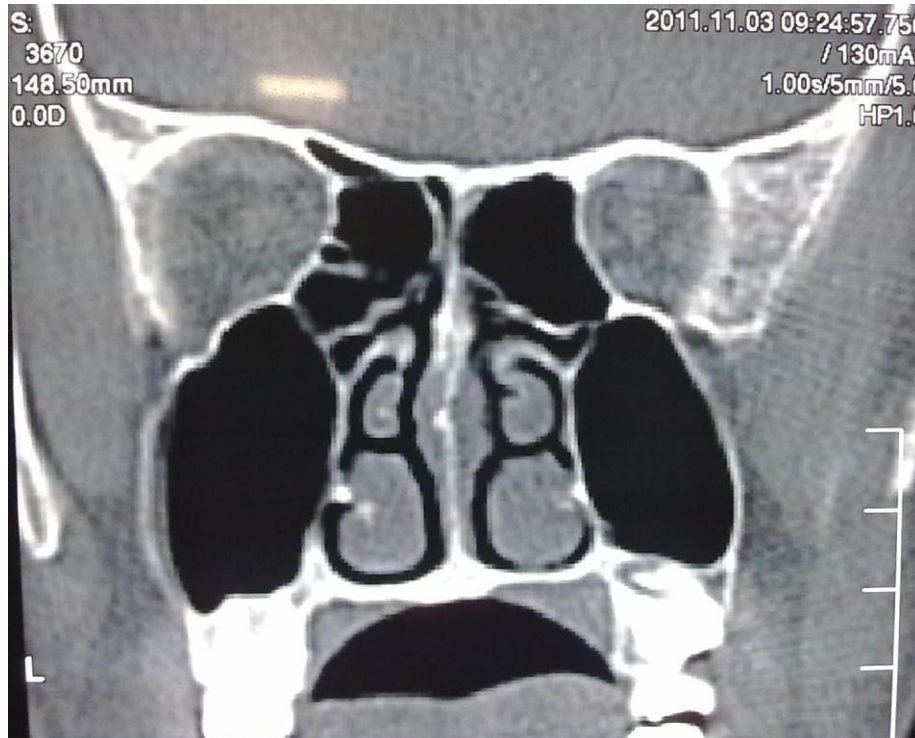


Figure 6: CT scan of a patient showing paradoxical middle turbinates

Aim of study:

Is to assess the role of anatomical obstruction in the pathogenesis of chronic sinusitis. Anatomical obstruction due to deviated nasal septum, concha bullosa, and paradoxical middle turbinate are included in the study.

Materials and methods

After the advent of endoscopic sinus surgery, pre operative evaluation of the osteomeatal complex has gained very importance in the management of sinus disorders. Computed tomography (CT) is the method of choice for the morphological evaluation of the osteomeatal complex. Coronal plane is the most commonly used plane by endoscopic surgeons because of its similarity with surgical orientation. In this study we have used patient symptomatology, anterior rhinoscopic findings and radiological evidence in to consideration.

Inclusion criteria

Patients who presented to the department of E.N.T and Head & neck surgery, Stanley medical college, during a one month periode with symptoms suggestive of chronic rhinosinusitis were subjected to undergo coronal CT scan of the para nasal

sinuses. 40 Patients who have symptoms of chronic rhinosinusitis (>12 wks duration) and whose CT scan shows mucosal thickening of paranasal sinuses suggestive of chronic sinusitis were included in the study.

Study results

Among the 40 patients studied, CT image of 32 (40%) cases showed septal deviation to either right or left. Concha bullosa was seen in 17 (42.5%) cases and paradoxical turbinates in 11 (27.5%) cases. Considering isolated variants, 15 (37.5%) cases had septal deviation alone as an anatomical variation, 5 (12.5%) had concha bullosa alone and 3 (7.5%) cases had paradoxical middle turbinate alone in their CT images. Most of the cases of concha bullosa was associated with a septal deviation i.e out of the 17 cases 12 (70.5%) cases had an associated septal deviation as anatomical variation.

Anatomical variation	No.of patients	Percentage
Deviated septum	32	80%
Concha bullosa	17	42.5%
Paradoxical turbinate	11	27.5%

Figure 7: table showing the aggregate frequency of anatomical variations studied.

Anatomical variation	no.of patients	Percentage
Deviated septum	15	37.5%
Concha bullosa	5	12.5%
Paradoxical turbinate	3	7.5%
Mixed variation	17	42.5%

Figure 8: table showing isolated frequencies of anatomical variations studied.

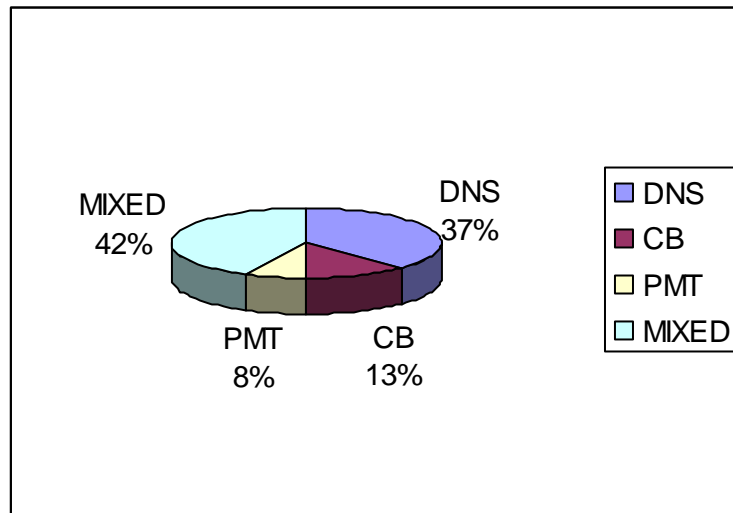


Figure 9: A pie chart showing the distribution of the major anatomical variants included in The study. DNS: deviated nasal septum, CB : concha bullosa, PMT : paradoxical middle turbinate.

Conclusion:

Most of the cases of chronic sinusitis caused by anatomical obstruction in the nose are found to be due to a deviated nasal septum leading to obstruction of osteomeatal complex. Other major causes are concha bullosa and paradoxical middle turbinate. Many a time more than one anatomical variation occurs in the same individual, rather than occurring as isolated single variation i.e a deviated septum with a concha bullosa or a deviated septum with a paradoxical turbinate. A concha bullosa of the nose is usually associated with a septal deviation in majority of the patients. Most common sinus affected due to anatomical obstruction at osteomeatal complex was maxillary sinus.

References:

- 1.. Lanza DC, Kennedy DW: Adult rhinosinusitis defined. *Otolaryngol Head Neck surg* 1997; 117:S1-S7.

- 2.. Benninger MS, Ferguson BJ, Hadley JA, et al: Adult chronic rhinosinusitis: definitions, diagnosis, epidemiology, and pathophysiology. *Otolaryngol Head Neck Surg* 2003; 129:S1-S32.
3. Byron J bailey & jonas T.Johnson,Head and Neck surgery,p406, 4th ed.
4. Byron J Bailey & Jonas T.Johnson, Head and Neck surgery,p406,4th ed.
5. Byron J Bailey & Jonas T.Johnson, Head and Neck surgery, p408, 4th ed
6. Devated nasal sepyum, drtbalu's otolaryngology online , www.drtbalu.co.in/dns.html
7. Bolger WE, Butzin CA, Parsons DS. Paranasal sinus bony anatomic variations and mucosal abnormalities: CT analysis for endoscopic sinus surgery. *Laryngoscope* 1991; 101:56-64.
- 8.Levin HL: The office diagnosis nasal and sinus disorders using rigid nasal endoscopy.*Otolaryngol Head Neck Surg* 102:370-373,1990.
- 9.May M, Mester SJ, O' Daniel TG, Curtin HD:Decreasing the risk of endonasal endoscopic nasal surgery by imaging techniques. *Op Tech Otolaryngol Head Neck Surg* 1:89-91,1990.
- 10.Benninger MS, Ferguson BJ, Hadley JA, et al. Adult chronic rhinosinusitis:Definitions, diagnosis, epidemiology and pathophysiology. *Otolaryngol Head Neck Surg* 2003; 129(3 spp1)
- 11.Hwang PH, Irwin SB, Griest SE, et al.Radiologic correlates of symptom based diagnostic criteria for chronic rhinosinusitis. *Otolaryngol Head Neck Surg* 2003;128(4):489.
- 12.Zoumalan RA, Lebowitz RA, Wang E, Yung K, Babb JS, Jacob JB. Flat panel cone beam computed tomography of the sinuses. *Otolaryngol Head Neck Surg*, 2009,140(6):841-4.
- 13.Zinriech S: Imaging of inflammatory sinus disease. *Otolaryngol Clin Am* 1993 ; 26:535.