

## **MANDIBULAR SWING APPROACH FOR A RECURRENT PARA PHARYNGEAL SPACE TUMOR – REPORT OF A CASE.**

### **ABSTRACT:**

Para pharyngeal space tumors , most of them benign, account for some 0.5% of tumors of head & neck. The importance of these tumors lie mainly in two aspects- on the one hand, the difficulty of early diagnosis & on the other hand the extreme complications of performing surgery in Para pharyngeal region.

This article discusses a clinical case of recurrent para pharyngeal tumor. A 32 yr old man presented with a recurrent left side neck swelling,4cm in diameter,which was subsequently confirmed as schwannoma by FNAC. Para pharyngeal tumor was successfully removed by mandibular swing approach & excision technique. His post operative course was uneventful & the pre operative clinical symptoms such as dysphagia & dysphnea completely resolved after surgery.

## **INTRODUCTION:**

Parapharyngeal space (PPS) tumours are not very frequent, accounting for some 0.5% of neoplasms of the head and neck. Most of these tumours (70-80%) are benign and 40-50% of the total originate in the salivary glands, particularly the pleomorphic adenoma<sup>1</sup> .

The PPS is in the shape of an inverted pyramid, going from the base of the skull to the hyoid bone, up to the petro tympanic part of the temporal lobe. The back wall is delineated by the aponeurosis and the C1, C2 and C3 pre vertebral muscles. It is delimited medially by the pharyngobasilar fascia and the superior pharyngeal constrictor muscle, and laterally by the ascending branch of the jaw, superficial cervical aponeurosis and the submaxillary gland. The styloid diaphragm, an aponeurotic sheath originating in the styloid apophysis is located on a plane inclined from above to below and from back to front, dividing the PPS into two compartments: the pre-styloid compartment

occupied mainly by the parotid gland deep lobe, and the retro-styloid compartment, containing the internal carotid artery, internal jugular vein, cervical sympathetic chain and the last four pairs of cranial nerves<sup>2</sup> .

PPS tumours may remain undetected for long periods of time, and generally present anodyne symptoms, normally as asymptomatic lumps medially displacing oropharyngeal structures. Other symptoms observed include the feeling of having a foreign body, obstruction of tubes, changes in the voice and cervical mass. Pain along with lock-jaw and/or paralysis of any of the pairs of cranial nerves would suggest malignancy<sup>3</sup> .

Because of its anatomical complexity, complementary MR and CT scanning are necessary for diagnosis, and Fine Needle Aspiration Cytology (FNAC) is very specific in the histological diagnosis of these tumours. Open biopsy is not advised, due to the risk of bleeding, opening of the capsule and, accordingly, relapse and seeding to neighbouring tissues<sup>4</sup> .

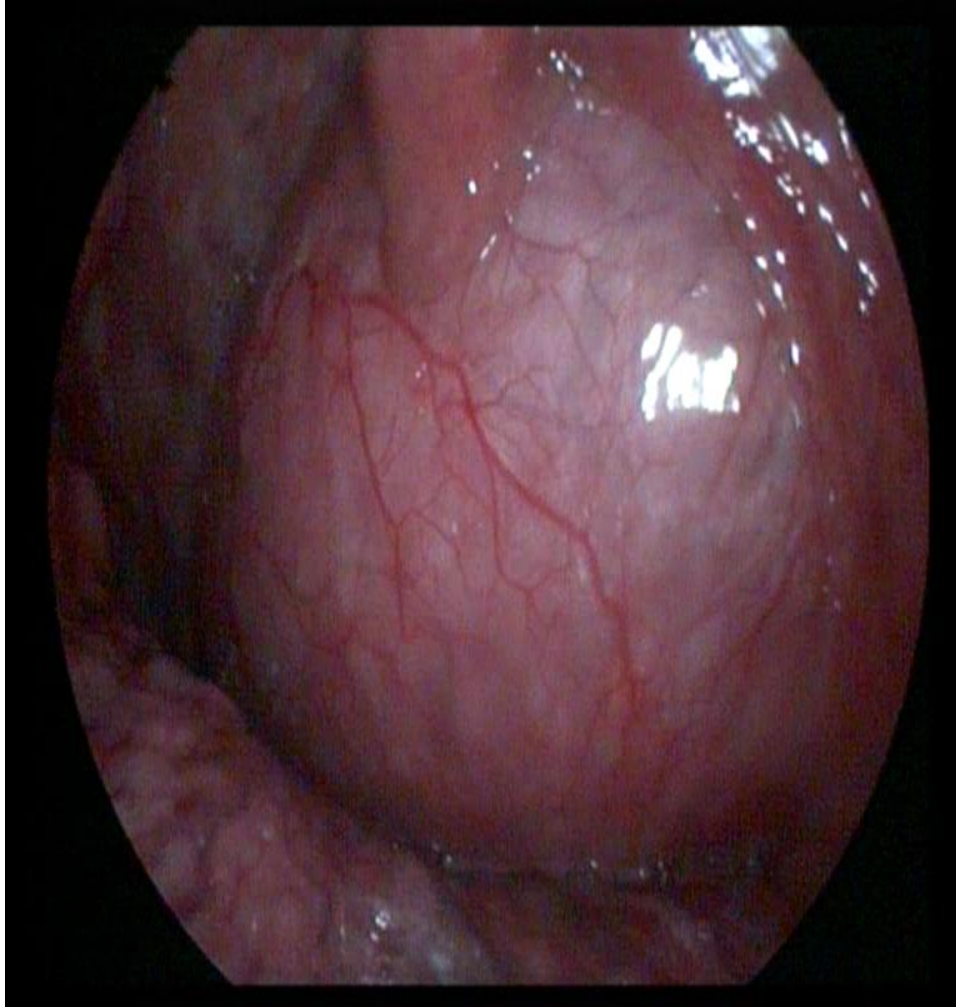
Because of the difficulty involved in getting into the PPS, many different approaches have been described, including transcervical, the first approach, described by Morfit in 1955<sup>1,5</sup> ; transcervical-transparotid, the most widely used, helpful in PPS tumours originating in the parotid deep lobe; transpalatal or transoral, described by Ehrlich<sup>6</sup> and limited to small non-vascular tumours; transmandibular, mandibular osteotomy being described as a complement to the other approaches, in order to improve and increase access to the PPS; Ariel et al<sup>7</sup>. were the first to propose opening the jaw to enter the PPS, many variations being later described<sup>8</sup> ; and, lastly, the orbitozygomatic approach to the middle cranial fossa, described in detail by Fisch<sup>9</sup> in 1978, to give access to PPS tumours affecting the temporal bone or very large tumours reaching the base of the skull.

In order to treat these kind of tumours correctly, it is first necessary to select the right surgical approach for each case, balancing maximum exposition, for complete and

safe removal of the tumour with minimum aesthetic and functional morbidity.

### **CLINICAL CASE :**

Male ,32 yrs of age, presented with dysphagia & left sided recurrent neck swelling. Physical examination of oral cavity showed smooth bulge predominantly over left posterior pharyngeal & lateral pharyngeal wall, Fig (1). Neck examination revealed diffuse firm swelling of 4cm diameter with surgical scar over which in the left posterior triangle of neck. Previous surgical details unavailable except HPE report as Schwannoma.



FIG(1) shows smooth bulge in the oropharynx .

## **SURGICAL TECHNIQUE: MANDIBULAR SWING APPROACH & EXCISION OF TUMOR.**

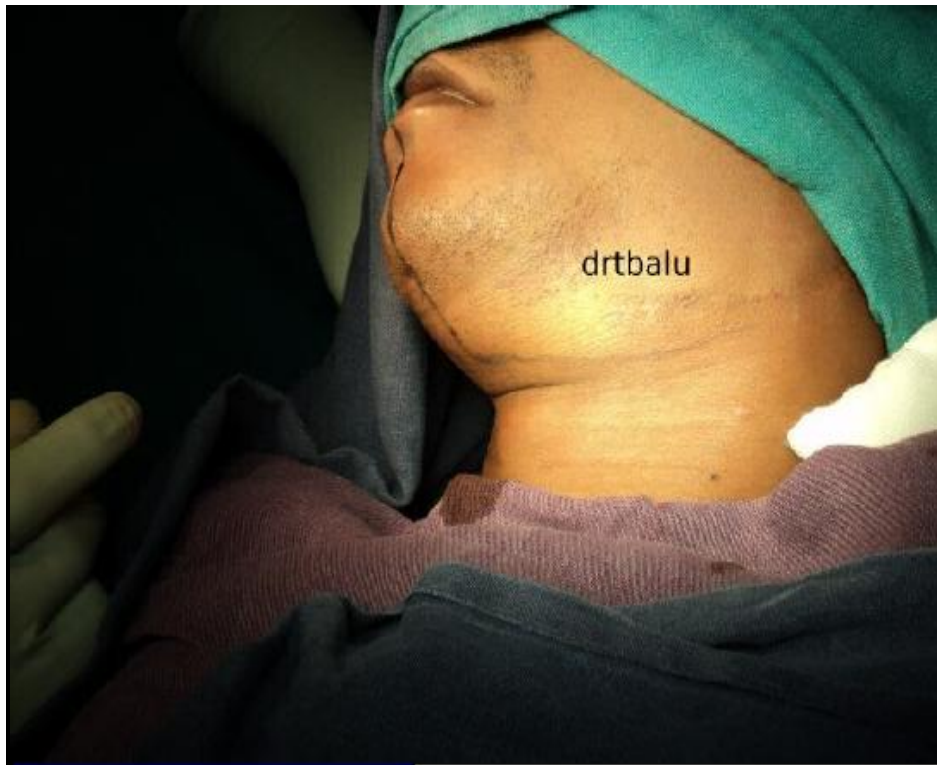This procedure performed under general anaesthesia.

We did preliminary tracheostomy & ET intubation performed via the tracheostome & the tube anchored to the chest.

Naso gastric tube introduced. We started incision from the Vermilion border of lower lip directly extending down to the Chin. From just below the chin the incision takes a gentle lateral Curve at the level of hyoid bone up to the medial border of sternocleidomastoid muscle fig(1). We divided lower lip up to its full thickness. Neck dissection carried out in the sub platysmal plane. Deep cervical fascia enveloping sub mandibular gland incised. Mandibular periosteum elevated on both sides. Mandibular osteotomy performed using a fissure burr fig(2). Incision continued in the para lingual gutter extending up to the anterior pillar fig(3)with adequate cuff left in the para lingual area. Identified wharton's duct , dissected & reflected it along with the swung mandible. Pharyngeal part of swelling visualized fig(4). vertical incision made over the swelling. By finger dissection , we excised the tumor. Finally mandibular segments stabilized

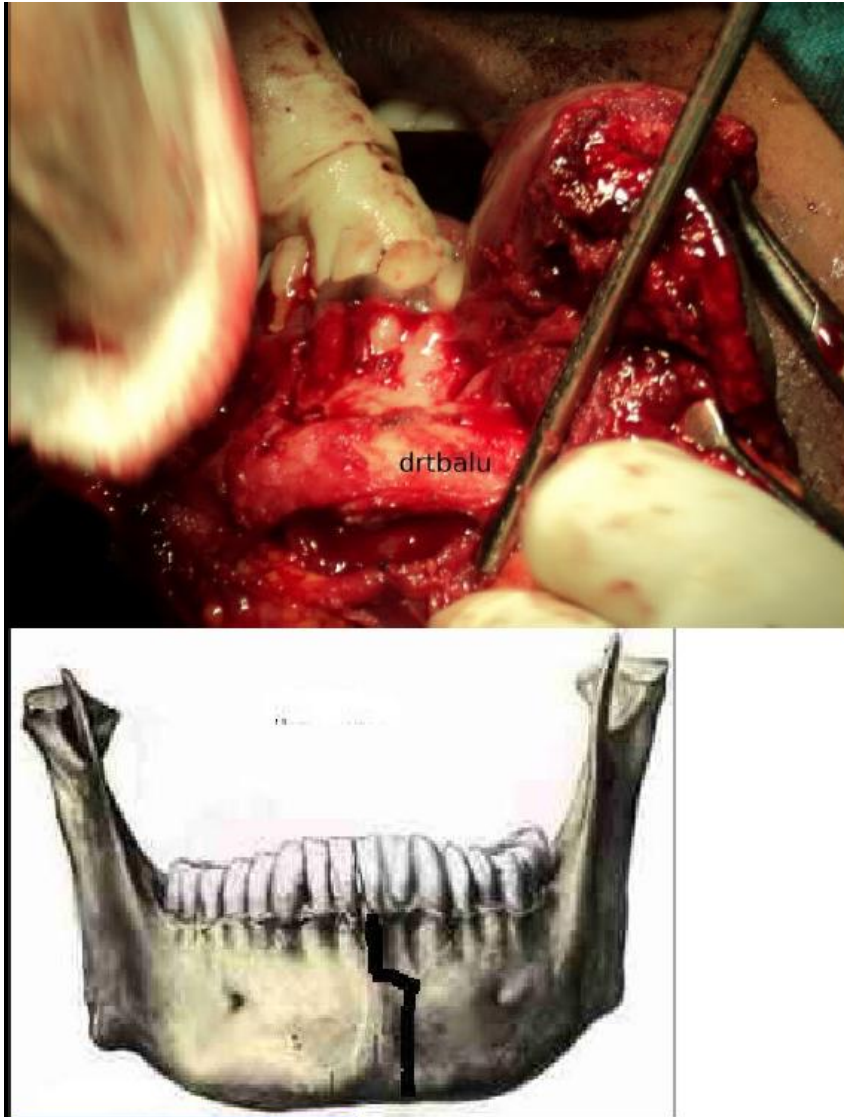
with screws fig(5) . Soft tissues approximated using absorbable suture.

Post operatively, we decannulated the tracheostome & passed without incident . Patient was reviewed 2 weeks, 1 month later & the preoperative symptoms such as dysphagia , dysphnea completely resolved without any complications.



Fig(1) shows the incision





Fig(2) shows the mandibular osteotomy

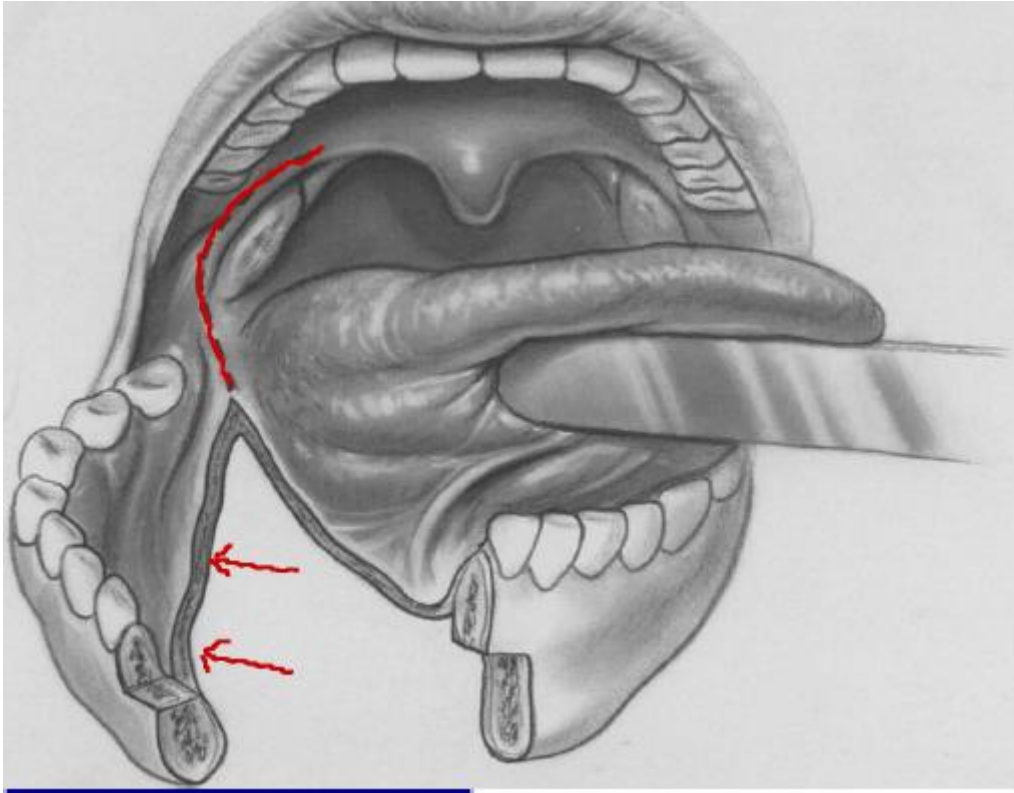
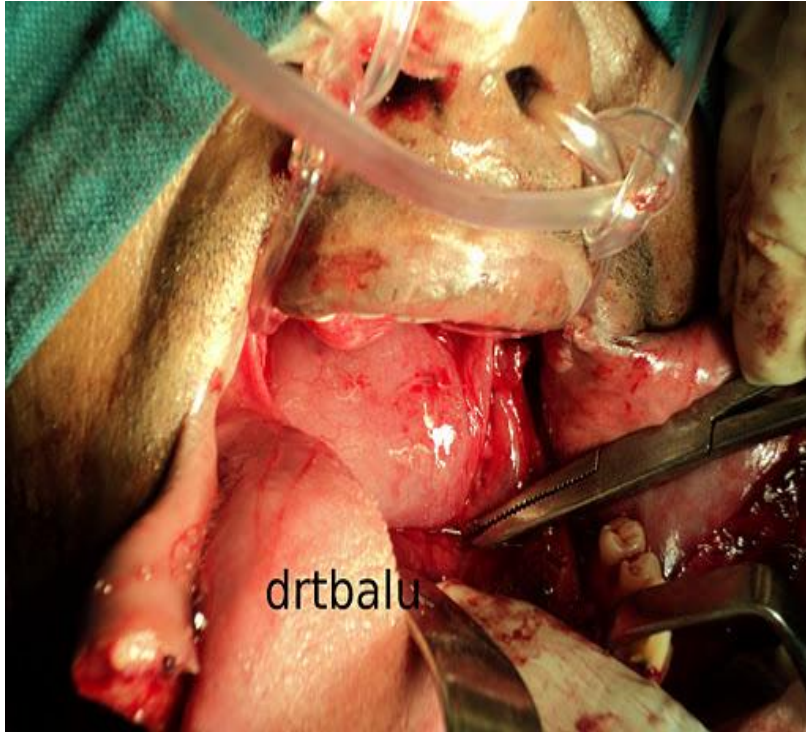
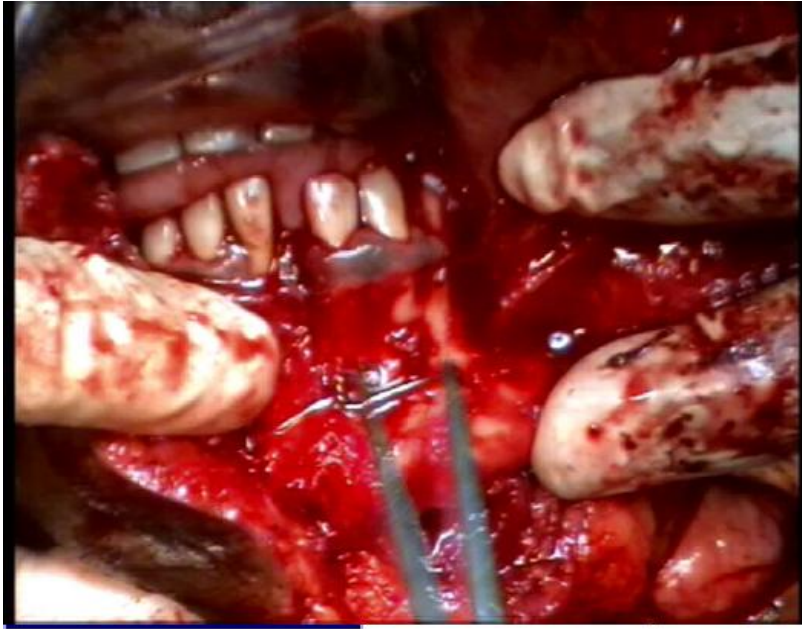


Fig (2) shows incision in the intra oral region



Fig(4) tumor mass clearly seen after mandibular swing is complete.



FIG(5) shows mandibular segments stabilized with screws & the reducing forceps.

## **DISCUSSION:**

PPS tumours usually present very few symptoms and are often associated with dysphagia, dyspnoea, obstructive sleep apnoea syndrome, cranial nerve deficits, Horner's syndrome, pain, hoarseness, dysarthria and trismus. Sometimes, a neck mass is present but it is often discovered only during a routine physical examination. Intraorally, they commonly appear as a smooth submucosal mass displacing the lateral pharyngeal wall, tonsil and soft palate antero-medially and it is often misdiagnosed as an infection or a tonsil tumour. In addition, the space itself is clinically inaccessible since it is surrounded by the mastication muscles, the mandible, and parotid glands which makes physical examination of the tumour difficult. In these cases, a bimanual evaluation is the most effective clinical examination although tumours of < 2.5 cm are undetectable <sup>10</sup>.

Imaging studies are used to predict the origin, side and the size of parapharyngeal tumours. MRI with gadolinium, is better than a CT scan and is the examination of choice. It can reliably

distinguish a deep lobe parotid tumour from a primary parapharyngeal tumour of neurovascular origins or of extra-parotid minor salivary glands, from evidence, in T2 weighted slices, of the fatty layer between the tumour and the pharyngeal wall.

US- or CT-guided FNAC is usually performed to determine the nature of the mass. According to data in the literature, FNAC is accurate in 90-95% of cases. It is performed transorally, transcervically or guided by CT or US and can predict the nature of the lesion which will assist surgeon-patient planning.

An accurate diagnosis is essential for planning the best surgical approach to safely and radically remove PPS tumours.

Tumours which involve the PPS are primary neoplasms, metastatic cancer and lesions which overlap from neighbouring areas and are reported in the literature as 80% benign and 20% malignant. The several kinds of mandibular osteotomy described in the literature give excellent access to the PPS, being very useful for the complete excision of tumours and allowing better control of the vascular structures. Since the first osteotomies

were described by Ariel et al.<sup>11</sup> , several variants<sup>12</sup> have been described..Another possible variant is osteotomy at the level of the condyle or, more recently, vertical osteotomy of the mandibular branch<sup>13</sup> to facilitate greater mobilisation of the corresponding segment of the mandible. In short, the success of PPS surgery depends on two conditions: correct identification and exposition of the lesion, allowing for complete removal; and minimum functional and aesthetic morbidity as a consequence of the surgery. Most patients may benefit from a simple transcervical or transparotid approach, but a group of patients with larger tumours require the use of techniques which, while simple, in combination may widen the surgical field without necessarily increasing morbidity. It is, accordingly, necessary to use all available surgical resources, adapting the chosen approach to the characteristics of the lesion.

## REFERENCES:

1. Khafif A, Segev Y, Kaplan DM, Gil Z, Fliss DM. Surgical management of parapharyngeal space tumors: a 10-year review. *Otolaryngol Head Neck Surg.* 2005 Mar;132(3):401-6.
2. Rouvière H, Delmas A. Anatomía topográfica de la cabeza y el cuello. En: *Anatomía Humana descriptiva, funcional y topográfica.* Barcelona:Editorial Masson ; 1987.p. 550-6.
3. Rodríguez-Ciurana J, Rodado C, Sáez M, Bassas C. Giant parotid pleomorphic adenoma involving the parapharyngeal space: report of a case. *J Oral Maxillofac Surg.* 2000 Oct;58(10):1184-7.
4. Acosta L, Montalvão P, Magalhães M, Olias J, Santiago N. Parapharyngeal space tumors. Our experience. I.P.O. Francisco Gentil, Lisbon. *Acta Otorrinolaringol Esp.* 2002 Aug-Sep;53(7):485-90.
5. Morfit HM. Retromandibular parotid tumors; their surgical treatment and mode of origin. *AMA Arch Surg.* 1955 Jun;70(6):906-13.
6. Ehrlich H. Mixed tumors of the pterygomaxillary space; operative removal; oral approach. *Oral Surg Oral Med Oral Pathol.* 1950 Nov;3(11):1366-71.
7. Ariel IM, Jerome AP, Pack GT. Treatment of tumors of the parotid salivary gland. *Surgery.* 1954 Jan;35(1):124-58.
8. Lazaridis N, Antoniadis K. Double mandibular osteotomy with coronoidectomy for tumours in the parapharyngeal space. *Br J Oral Maxillofac Surg.* 2003 Jun;41(3):142-6.



9. Fisch U. Infratemporal fossa approach to tumours of the temporal bone and base of the skull. J Laryngol Otol. 1978 Nov;92(11):949-67.
10. Carrau RL, Myers EN, Johnson JT. Management of tumors arising in the parapharyngeal space. Laryngoscope 1990;100:583-9. [[PubMed](#)]
11. Ariel IM, Jerome AP, Pack GT. Treatment of tumors of the parotid salivary gland. Surgery. 1954 Jan;335(11):1124-58.
12. Teng MS, Genden EM, Buchbinder D, Urken ML. Subcutaneous mandibulotomy: a new surgical access for large tumors of the parapharyngeal space. Laryngoscope. 2003 Nov;113(11):11893-77.
13. Smith GI, Brennan PA, Webb AA, Ilankovan V. Vertical ramus osteotomy combined with a parasymphiseal mandibulotomy for improved access to the parapharyngeal space. Head Neck. 2003 Dec;25(112):11000-3.