



ISSN 2250- 0359

Volume 2 supplement 1 2012

Endoscopic stapedectomy our experience

Balasubramanian Thiagarajan¹ Venkatesan Ulaganathan²¹Stanley Medical College ² Meenakshi Medical College

Abstract:

Stapedectomy traditionally is performed using operating microscope. Eventhough it is a time tested procedure, it had its own draw backs. In patients with excessive bony overhang it would be difficult to access the middle ear cavity using operating microscope. Using Endoscope authors were able to circumvent these difficulties. Endoscopic examination of middle ear cavity was in vogue since 1992.¹⁰ Advantages of using endoscope include: Excellent exposure, visualization of entire middle ear cavity with ease, excellent crystal clear images. All the steps of stapedectomy could easily be performed using endoscope. Only flip side being the use of only one hand for the entire procedure as the non dominant hand will be holding the endoscope.

Introduction:

Otosclerosis the ? Hereditary disease involving the otic capsule characterised by alternating phases of bone resorption and new bone formation was first described by Valsalva in 1704¹. Historically stapes surgery dates way back to 1853. It was Toynbee who gave the first description of ankylosis of stapes and changes that took place in the foot plate area².

In his work Kessel proposed that removal of ear drum, malleus and incus could cure deafness. In 1885 Lucae reported excellent results using Kessel's procedure³. Surgical management of otosclerosis was first described extensively by Bousheron in 1890. He went on to record 60 cases of stapes mobilisation.

Bousheron procedure⁴: This was a modification of Kessel's procedure. This surgery involved separation of incus from stapes, excision of posterior half of tympanic membrane, and mobilisation of stapes by gentle traction by means of a hook. He concluded favorable results were obtained only during early stages of stapedial ankylosis.

Evolution and standardization of modern stapedectomy operation should be credited to Shea,⁵ who was responsible for making it a universally followed standard treatment procedure for otosclerosis.

The concept of small fenestra stapedotomy was proposed by Fisch in 1982 ⁶. The advantage of this procedure being that it carried less risk of sensorineural hearing loss and the results were acceptable.

Silverstein's partial stapedectomy ⁷:

Silverstein in 1998 proposed this procedure. Laser was used to perform stapedotomy, and no prosthesis was used. The stapedial tendon was left undisturbed. This procedure is very useful in managing patients with anterior foot plate otosclerosis, when the disease is confined to fissula antefenestrum alone. Argon laser was used by Silverstein to remove the anterior crus to stapes. The posterior portion of stapes is left intact attached to stapedial tendon, hence it prevents acoustic trauma from occurring later on. Since this portion is not involved during the early phases of otosclerosis the results were excellent. This is actually a conservative procedure with very minimal risk of permanent inner ear damage.

Common difficulties encountered while doing stapedectomy under microscopic vision include ⁸:

1. Prominent posterior bony overhang
2. Very short chorda tympani nerve
3. Dehiscent facial nerve passing over oval window
4. Excessive narrowing of oval window by otosclerotic foci.

Methodology:

Stapedectomy performed using endoscope and microscope was compared. The operating surgeon was the same person. 25 cases of endoscopic stapedectomy were used for comparison with microscope used stapedectomy. Comparison was made actually during each step of the procedure. All these cases were performed under local anesthesia. All these surgeries were performed via endomeatal approach.

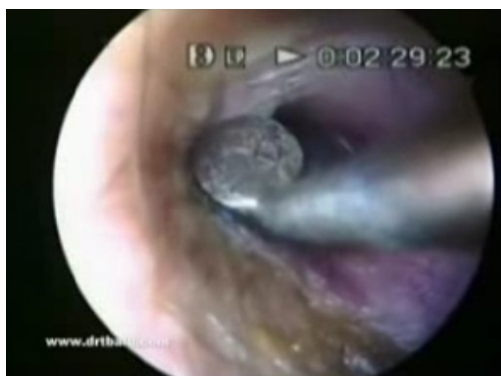Elevation of tympanomeatal flap:

Microscope:

Elevation of tympanomeatal flap was easy. In one patient who had a large posterior bony overhang elevation was found difficult. Angulation of objective had to be changed for visualizing the area.

Endoscope:

Elevation of tympanomeatal flap was fairly simple. Image resolution was excellent. With minimal manipulation of endoscope the entire area of tympanic membrane could be clearly seen.



Elevation of tympanomeatal flap (Endoscopic view)

Bony overhang area could be clearly seen without any problem.

Handling chorda tympani nerve:

Too short chorda tympani⁹ will cause problems during curettage because of inadequate operating angle. It should hence be mobilised adequately by dissecting the mucosal fold covering it. In patients with a short chorda tympani nerve curetting the bony overhang would free up some more of the nerve. Overzealous curettage could cause permanent problems like postero superior retraction pockets. This is where the use of endoscope helps. Endoscopic stapedectomy vitates the necessity of excessive mobilisation of chorda tympani nerve. The angle of the chorda being sufficient for the procedure to be completed successfully. This could be a problem if microscope is used.

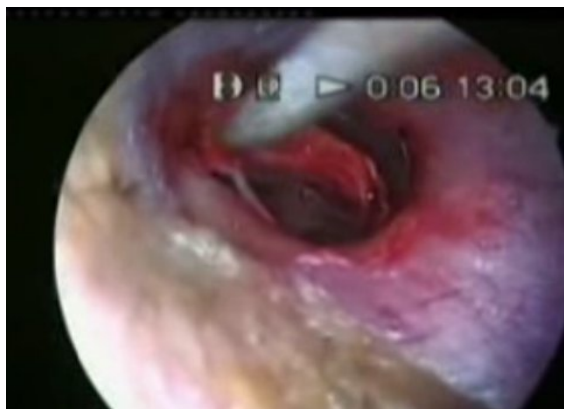Removal of bony overhang:

Microscope:

Ideally adequate amount of bone from the posterosuperior portion of posterior canal wall should be removed. The amount of bone removal should be just enough to expose the pyramid, and entire suprastructure of stapes. If the chorda tympani nerve is short, the angle which is available for curettage is reduced. This could cause injury to the nerve while operating with a microscope. Too liberal removal of bony overhang can cause retraction pocket / small perforation of ear drum in that area. While using the microscope the angle of objective had to be changed two / three times for adequate visualization of suprastructure of stapes.

Endoscope:

When endoscope is used the amount of bony overhang to be removed need not be too aggressive. By just tilting the endoscope the suprastructure of the foot plate can be easily visualized. Endoscope offered the best help during this stage of the entire procedure.



Chorda tympani nerve clearly seen on elevating the tympanomeatal flap (Endoscopic vision)

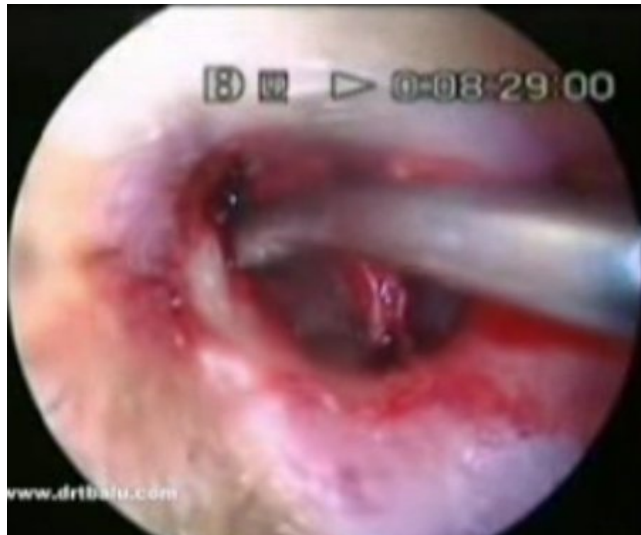

Image showing bony overhang being curetted (Endoscopic vision)

Stages of cutting the stapedial tendon, dislocation of incudo stapedial joint and fracture of the crura can easily be performed both under microscopic / endoscopic vision with ease. The use of endoscope does away with the obvious need for excessive removal of bony over hang.

Fenestration of foot plate and insertion of prosthesis:

This step is the most crucial and difficult part of the entire surgery. When microscope is used both hands of the surgeon are free and facilitates better insertion technique. With more and more otolaryngologists adept at doing endoscopic sinus surgeries, they easily adapt to one hand technique which needs to be followed if endoscope is used.

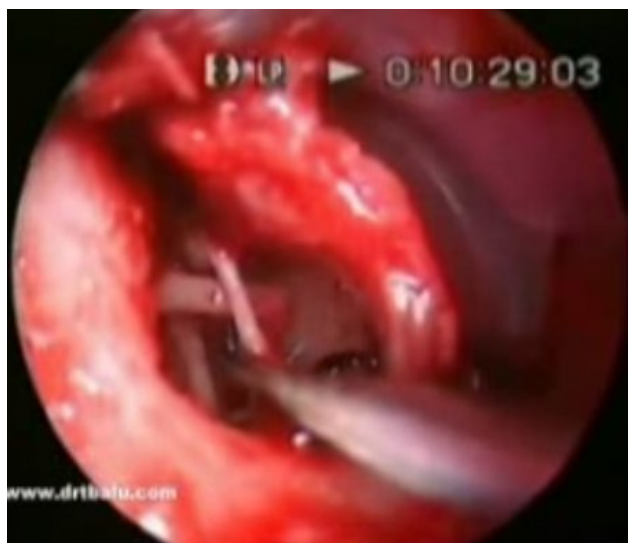


Image showing fenestration of foot plate being performed (endoscopic vision)

Discussion:

This tool needs to be evaluated with all seriousness. The author has been performing endoscopic stapedectomy for the past 8 years. Results are consistently good.

Advantages of endoscopic stapedectomy are:

1. Cost effective as equipment use is optimized
2. Image resolution is excellent. It can be used for documentation purposes
3. Very portable can be used even in rural settings which may not have operating microscopes
4. Useful in performing the surgery in patients with a short chorda tympani nerve
5. Excessive removal of bony overhang need not be resorted to.

References:

1. %0 Book
%T Otosclerosis
%A Balasubramanian, T.
%U <http://books.google.co.in/books?id=IAE7-dVZKK8C>
2. Toynbee i: Case of complete bony ankylosis of the stapes to the fenestra ovalis. Trans Pathol Soc London 4:253, 1853
3. Baracz R: Die Exzision des Trommelfells sammt Hammer bei Sklerose der Paukenschleimhaut. Wien Med Wochenschr 37:290, 1887 (as described in Otosclerosis ~1
4. D.S. Poe, Laser-assisted endoscopic stapedectomy: a prospective study, Laryngoscope 110 (Suppl. 95) (2000) 1 – 37.
5. J. Shea Jr., Fenestration of the oval window, Ann. Otol. Rhinol. Laryngol. 67 (1958) 932 – 951.
6. U. Fisch, Stapedotomy versus stapedectomy, Am. J. Otol. 4 (1982) 112 – 117.
7. H. Silverstein, Laser stapedectomy minus prosthesis (laser STAMP): a minimally invasive procedure, Am. J. Otol. 19 (1998) 277 – 282.
8. Endoscopic assisted stapedectomy Mohamed L Begermy International Congress Series 1240 (2003) 919 – 925
9. T.R. Bull, Taste and chorda tympani, J. Laryngol. Otol. 79 (1965) 479 – 493
10. S.B. Mer, A.J. Derbyshire, A. Brushenko, D.A. Pontarelli, Fiberoptic endoscopies for examination of the middle ear, Arch. Otolaryngol. 85 (1967) 387 – 393