



'old foley's in a new bottle'- USE OF FOLEY'S CATHETER IN ANTERIOR MAXILLARY WALL FRACTURES

Vrinda B Nair Seethalakshmi Narashiman Srikamakshi Kothandaraman

Stanley Medical College

ABSTRACT

Management of comminuted zygomaticomaxillary fractures are is an entity that has always tested the skill of surgeons. A variety of methods have been coined over the years for management of these fractures. Packing the antrum with a gauze or balloon can be used in much comminuted fractures especially with anterior antral wall communication. Internal immobilization with a Foley's balloon catheter is being used widely in Blow out fractures of orbit and rarely in tripod fractures. Despite a thorough search, not much literature could be found of its use in anterior maxillary wall fractures. The purpose of this article is to appraise this technique in anterior maxillary wall fractures.

INTRODUCTION

The Maxilla acts as a bridge between the cranial base superiorly and the dental occlusal plane inferiorly. It is associated intimately with the oral cavity, nasal cavity, and orbits and this makes the maxilla an important structure both functionally and cosmetically. Fracture of these bones can lead to not only cosmetic disfigurement but can also be life-threatening. Timely and systematic repair of these fractures provides the best chance to correct deformity and prevent unfavorable sequelae.

CASE REPORT

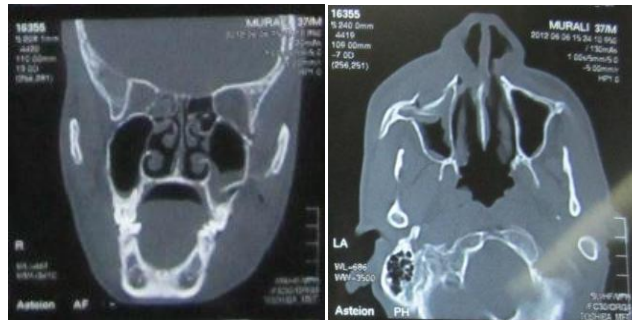
A 37 year old male, was admitted in our department as a case of RTA-h/o fall from motor bike, hitting left side of face against side-walk. Following the incident he sustained multiple injuries- lacerated wounds over face, bilateral nasal bleed and deviation of jaw to right side.

H/o infraorbital numbness.

No h/o loc, seizures, vomiting.

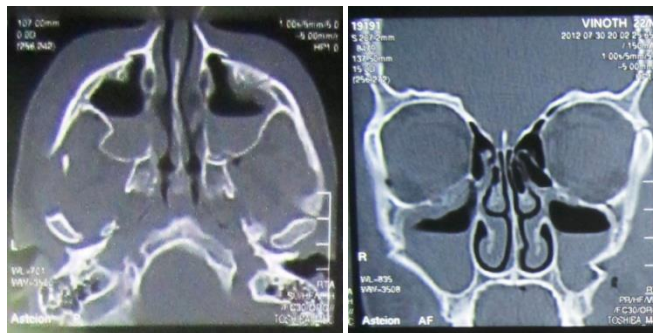
CT Facial bones revealed, comminuted depressed fracture –anterior wall of left maxillary sinus with hemosinus.

CT Brain was normal.



Another patient, 22 year old male sustained injury to face following a road traffic accident ,was admitted with complaints of pain and swelling of both cheeks,and numbness over the left lower lid,side of nose and left half of upper lip. No h/o loss of consciousness,headache or vomiting.

On examination he had tenderness over both maxillary sinus ,and reduced sensation over left infraorbital nerve distribution.

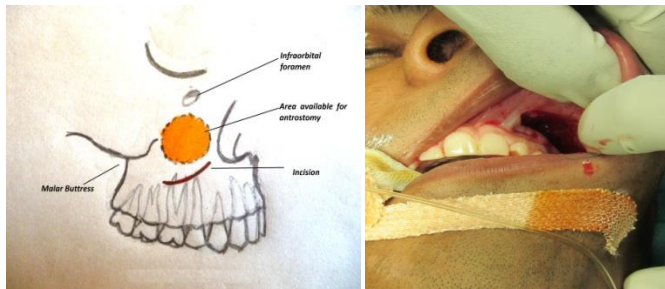


CT Facial bones revealed, comminuted depressed fracture –anterior wall of left maxillary sinus, and a minimally displaced anterior maxillary wall fracture over the right side with

bilateral hem sinus.

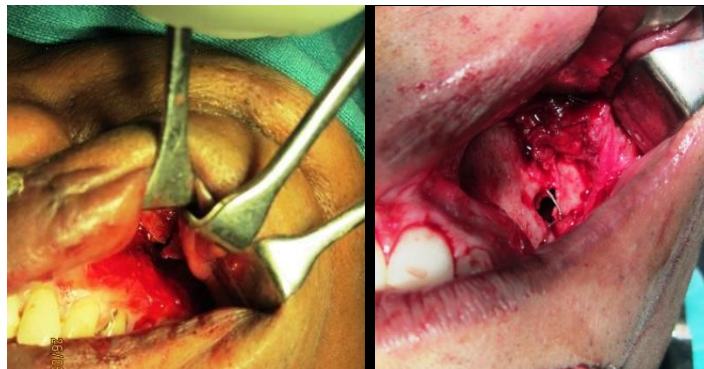
CT Brain was normal.

After initial stabilization, and treating with antibiotics and anti-inflammatories, patients were taken up for surgery.

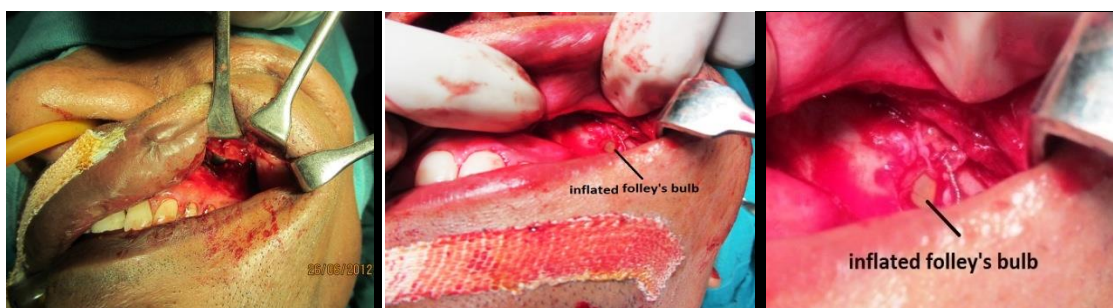

With patient in supine position, head turned 20° to right side, infiltration was given in left sublabial and gingivolabial sulcus. Incision made in left gingivobuccal sulcus.

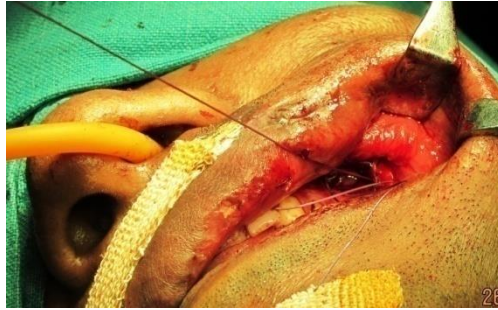Periosteum was elevated over anterior wall of maxilla. Fractured fragments seen dislodged from anterior wall of maxilla was repositioned with metal wire.



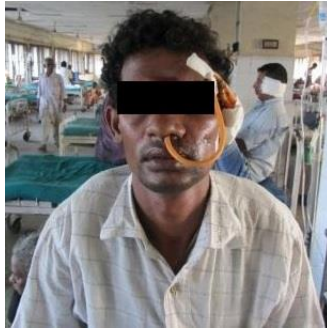Inferior meatal antrostomy was done, No.16 Foley's catheter introduced through it and inflated with AIR until fracture segments were aligned.



The same was sutured with the nose. Flaps were repositioned and periosteum sutured with 2-0 vicryl.



On day 8, patient was discharged with the foley's catheter in situ. The same was removed on day 15.



DISCUSSION

Faciomaxillary trauma and upper airway injuries are very common and pose problems in airway management. There may be associated injuries to the cranial fossae and brain, cervical spine, skeleton and chest. Hence a multidisciplinary management involving otolaryngologists, oral surgeons and dentists, plastic surgeons, ophthalmologists, neurosurgeons, anaesthetists and trauma surgeons is what is to be coordinated and followed rather than fragmented care.^[12]

SIGNS & SYMPTOMS^[14]

FRACTURES	SIGNS & SYMPTOMS				
	V2 Deficit	Diplopia	Deformity	Trismus	Malocclusion
Ant. Maxillary Wall	+				
Orbital Floor	+	+			
Zygomaticomaxillary Complex	+	+	+	+	
Nasomaxillary Complex	+	+	+		
Zygomatic Arch			+	+	
Entire Unilateral Maxilla	+	+	+	+	+

Mechanisms of Injury^[12]

Faciomaxillary and upper airway injuries are due to sharp or blunt injuries to the head or neck. Sharp injuries usually result in lacerations and penetrating injuries, whereas blunt injuries result in fractures to the facial skeleton. Over 50% of facial trauma are the result of motor vehicle accidents. Rest are due to physical violence, sports injuries, falls and work-related accidents. The severity of facial fractures are directly related to the degree of force applied and the velocity of injury. Over 50% of severe faciomaxillary injury are accompanied by other associated injuries.

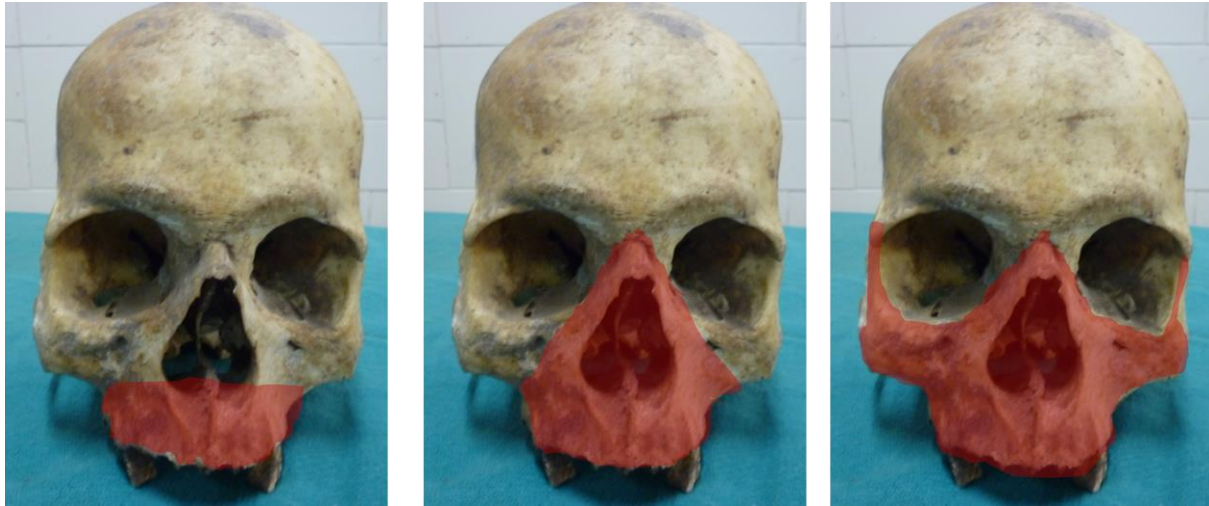CLASSIFICATION OF MIDDLE THIRD FRACTURES

Broadly classified as

- A) **Le fort** I ,II ,III
- B) **Erich's** in 1942 , as per the direction of fracture line- **Horizontal , Pyramidal , Transverse.**
- C) Depending on the relation of fracture to zygomatic bone – **Subzygomatic , Suprazygomatic.**
- D) Depending on the level of fracture – **Low level , Mid level , High level.**

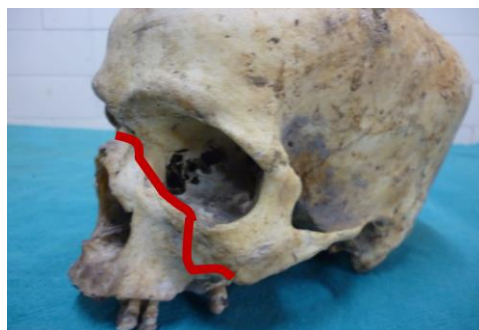
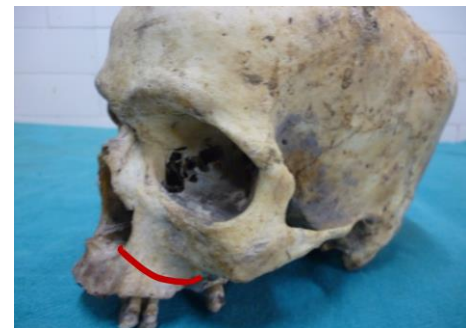Le fort classification of Maxillary Fractures^{[1] [12]}

René Le Fort described a classification of maxillary fractures in 1901 which is still used today, although fractures are usually of mixed types. Three predominant types were described.



Le Fort I fractures (horizontal) also known as **Guerin's fracture** /**floating fractures** may result from a force of injury directed low on the maxillary alveolar rim in a downward direction. It separates the palate from the remainder of the facial skeleton.

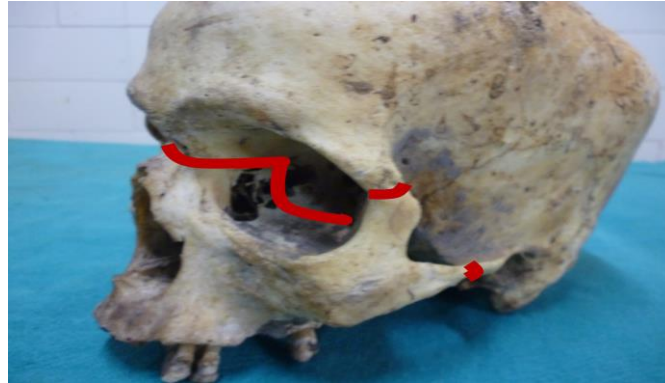
The fracture extends from the nasal septum to the lateral pyriform rims, travels horizontally above the teeth apices, crosses below the zygomaticomaxillary junction, and traverses the pterygomaxillary junction to interrupt the pterygoid plates.



pterygoid plates.

Le Fort II fractures (pyramidal/Subzygomatic fractures) may result from a blow to the lower or mid maxilla. Such a fracture has a pyramidal shape and extends from the nasal bridge at or below the nasofrontal suture through the frontal processes of the maxilla, inferolaterally through the lacrimal bones and inferior orbital floor and rim through or near the inferior orbital foramen, and inferiorly through the anterior wall of the maxillary sinus; it then travels under the zygoma, across the pterygomaxillary fissure, and through the

Le Fort III fractures (transverse/Suprazygomatic fracture), also termed **Craniofacial Dysjunctions/"Dish-Face" deformity**, may follow impact to the nasal bridge or upper maxilla; usually as a consequence of superiorly-directed blows to the nasal bones.



These fractures start at the nasofrontal and frontomaxillary sutures and extend posteriorly along the medial wall of the orbit through the nasolacrimal groove and ethmoid bones. The thicker sphenoid bone posteriorly usually prevents continuation of the fracture into the optic canal. Instead, the fracture continues along the floor of the orbit along the inferior orbital fissure and continues superolaterally through the lateral orbital wall, through the zygomaticofrontal junction and the zygomatic arch. Intranasally, a branch of the fracture extends through the base of the perpendicular plate of the ethmoid, through the vomer, and through the interface of the pterygoid plates to the base of the sphenoid. As it involves the ethmoid bone, it may affect the cribriform plate at the base of the skull.

Despite the LeFort classification, maxillary fractures may often be a mixed variety. Similarly, facial fractures may be comminuted and may not be symmetrically distributed. Nevertheless, comminuted fractures usually follow the LeFort fracture lines. LeFort II and III fractures involve the orbit and are frequently associated with orbital blowout fractures through which ocular muscles may herniate.

Acute Management ^[12]

The major concern during acute management of faciomaxillary and neck injuries is airway patency. Once that has been managed, other life-threatening injuries and trauma-related major system failure may be addressed. Thus, treatment priorities are to clear and secure the airway, control haemorrhage, treat hypovolaemia, and evaluate for associated life-threatening injuries. When these are satisfied, management is directed towards the facial, neck and other injuries.

GENERAL MANAGEMENT^[12]

In patients without airway obstruction, a 30° head-up position is preferred so as to encourage drainage of blood, saliva and CSF away from the airway. This also helps in preventing obstruction by the disrupted tissue. Following airway management, maxillary and mandibular fragments can be repositioned and a head wrap applied to maintain stabilization.

The definitive approach towards faciomaxillary fractures can be planned after a "*grace period*" of up to 10 days taking into account patient comfort. But in orbital injuries when ocular function is at risk, an early surgery is mandatory. When gross facial swelling occurs, definitive surgery should be delayed and measures like wound debridement, removal of foreign bodies, closure of facial lacerations, ice packs, and head-up nursing to reduce venous pressure and encourage fluid resorption should be instituted. Prophylactic antibiotics should be used in those with CSF rhinorrhoea, compound wounds and when operative fixation of fractures is performed.

RADIOLOGICAL EVALUATION

Once the patient is fully stabilized, radiologic evaluation should commence.

When using Plain films, the following radiographs should be taken –

- 1) Lateral skull view
- 2) Water's view
- 3) PA & AP views of skull
- 4) OPG
- 5) Towne's view- zygomatic arches, vertical rami of mandible.
- 6) Occlusal radiograph for split palate.

Preferred Radiologic Modality: CT scan.

DEFINITIVE MANAGEMENT

Goals of treatment –

- 1) Precise anatomical reduction to cranial base above and to the mandible below.
- 2) Stable fixation of reduced fragments
- 3) Preservation of blood supply to fractured site.
- 4) Restoration of function.

REDUCTION OF MAXILLA

- Manual reduction.
- Reduction with wires.
- Reduction using disimpaction forceps.
- Reduction by means of traction(elastics)

Closed reduction can be done in

- 1) Non displaced fracture
- 2) Grossly comminuted fractures
- 3) Fractures exposed by significant loss of overlying soft tissues.
- 4) Edentulous maxillary fractures
- 5) In children with developing dentition.

Open reduction to be done in

- 1) Displaced fractures
- 2) Multiple fractures of facial bones
- 3) Fractures of edentulous maxilla with severe displacement.
- 4) Edentulous maxillary fracture opposing an edentulous mandibular fracture.
- 5) Delay of treatment and interposition of soft tissues between non-contacting displaced fracture segments.
- 6) Specific systemic conditions contraindicating IMF.

Surgical Approaches^[13]

Multiple approaches are often required to achieve the necessary exposure in cases where open reduction is required. Common routes for faciomaxillary fractures viz. *Labiobuccal, Gillies, and lateral brow incisions, Coronal & Hemicoronal, Midfacial Degloving, Transconjunctival/Subciliary* will not be discussed here.

Transantral

This is basically the Caldwell-Luc approach and is easily utilized in cases where there is a defect in the anterior maxillary wall, giving direct access to the orbital floor, lateral nasal wall, and inner aspects of the zygoma and zygomaticomaxillary buttress. This access can be used prior to repair of the anterior maxillary wall, or the defect can be left unrepaired if it is small. Alternatively, a defect can be created surgically. Through this opening, elevators or other instruments such as urethral sounds (see below) can be used to assist in reduction of fractures. Maxillary sinus packing to support an isolated lateral nasal wall or orbital floor fracture can also be introduced through the opening, with the end of the packing material brought out through the defect or through a nasoantral window.

Nasoantral window

This method of access to the inner surface of the zygoma has been useful in cases where reduction of the zygoma is difficult and there is a desire to avoid additional surgical approaches. It can be utilized in combination with other approaches or alone in cases where closed reduction is planned. The technique requires the creation of a nasoantral window under the inferior turbinate to allow the introduction of a curved urethral sound into the maxillary sinus. The sound is advanced until the blunt tip of it is against the hollow of the interior surface of the zygoma. By applying manual pressure over the zygoma while maintaining pressure on the inner surface of the zygoma with the sound, the zygoma can be fairly easily manipulated bimanually.

Palpation of the fracture lines and or the malar eminence is used to evaluate the reduction. Internal fixation can then be carried out if needed.

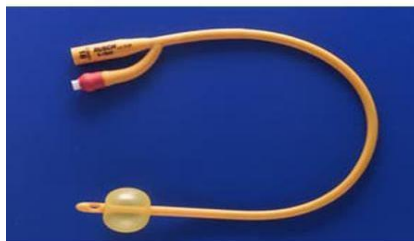ROLE OF FOLEY'S CATHETER^[4]

The first Antral balloon was introduced by Anthony(1952),via an intranasal antrostomy. The direct sublabial approach was not used as it was used in fractures with a large orbital floor component, the pressure within the bag being used to both reduce and fixate any bony fragments. Jackson et al in 1956 reported two cases in which the Shea –Anthony Balloon catheter was used in zygomatic fractures again via an intranasal antrostomy. They suggested this technique in conjunction with the Gillies temporal approach (1927), or external traction method. Jarabak (1959) first used the 30cc. Foley's catheter via sublabial transantral route. Fixation of the balloon was done following a manual reduction of the fracture. Gutman et al (1965) modified the Foley's catheter technique by reducing the fracture via the sublabial transantral approach by inserting the catheter through an intranasal antrostomy.

We introduced the foley's bulb into the antrum via an inferior meatal antrostomy and inflated it with AIR so as to prevent complication of aspiration just in case of a bulb rupture. We found an antral Foley's bulb much better than antral packing for internal fracture immobilization.

Unlike antral packs which have to be removed by 48-72 hours, Foley's could be kept insitu even upto 3 weeks without fear of infection. It gave good results in terms of fracture reduction and improvement of infraorbital numbness. Patients found it more comfortable as it didn't give them that 'stuffed' feeling as with antral packing ;neither did they have any annoying foul smelling nasal discharge despite being kept for a longer period. The only thing that worried the patients was the cosmetic disfigurement caused by a long tube sticking out of their nose. But considering its benefits, a small cosmetic trouble for a short span is quite acceptable.

The extended uses of Foley catheter in Plastic Surgery^[3]



Following modification of the urinary catheter by a simple addition of an inflatable distal retaining balloon by Dr. Frederick E. B. Foley in 1934, surgeons have been using it widely in many fields of surgery -

- Reduction of orbital, unstable zygomatic arch and corpus fractures.
- Reconstruction of the orbital floor: A Foley catheter was placed into the maxillary sinus to provide temporary support for the lyophilized tensor fascia lata graft.
- Eye socket reconstruction: Foley's catheter has been used for 2 purposes in this situation: to keep the skin bag bulging and to drain the exudates in the skin bag.
- Intraoperative tissue expansion: Tissue gain has been achieved by intraoperative tissue expansion using Foley's catheter. For this aim Foley's catheter has been used for cleft palate repair, eyelid reconstruction and some skin defects.
- Alar stabilization: A technique of intraoperative nasal ala stabilization to aid excision of skin lesions on the nasal ala and the surrounding skin has been described.
- Nostril retainer: A part of silicone urine catheter has been used as a nostril retainer.
- Short-term drainage in frontal sinus surgery: Foley's catheter has been used purpose a short-term drainage and fronto-nasal duct kept patent for several weeks or months of frontal sinus disease.

In addition of these, there should probably be many more unpublished uses of the Foley's catheter in Plastic Surgery.

REFERANCES

1. **Maxillary and Le Fort Fractures Treatment & Management.** Author: Kris S Moe, MD, FACS Chief, Division of Facial Plastic and Reconstructive Surgery, Department of Otolaryngology-Head and Neck Surgery, University of Washington School of Medicine; Chief Editor: Al Aly, MD, FACS.
2. **Foley's Catheter Stabilization of Comminuted Zygomaticomaxillary Fracture:A Review and Case Report.** Bansal Shallu ,Assistant Professor ,Rai Manjunath,Professor &Head, Hegde Padmaraj,Postgraduate student ,Sachdev Vaibhav,Professor & Head. *Online published on 1 May,2012. Indianjournals.com*
3. **The extended uses of Foley catheter in Plastic Surgery,** Indian J Plast Surg January-June 2006 Vol 39 Issue 1 ,page111
4. **The use of the Foley balloon catheter in the tripod fracture.**A. G. D. Maran and G. W. Glover Department of Otolaryngology, 11 Dudhope Terrace Cambridge Journals OnlineThe Journal of Laryngology & Otology / Volume 85 / Issue 09 / September 1971 , pp 897 – 902, Published online: 29 June 2007
5. **COMPLICATIONS OF THE CALDWELL-LUC OPERATION AND HOW TO AVOID THEM.** W. K. Low. Australian and New Zealand Journal of Surgery,Volume 65, Issue 8, pages 582–584, August 1995
6. TY - BOOK

T1 - Blow out fracture current management trends

A1 - Balasubramanian, T.

UR - <http://books.google.co.in/books?id=6JeJ4PhBJToC>

PB - Geetha R

ER -
7. **Assessment of patients with facial fractures.**Ellis E 3rd, Scott K. Department of Oral and Maxillofacial Surgery, University of Texas Southwestern Medical Center, Dallas, USA. Emerg Med Clin North Am. 2000 Aug;18(3):411-48, vi.
8. **Scott Brown 7th edition /vol.2/chapter128** fractures of facial skeleton :fracture Of maxilla. Pgs.1625-1628.
9. **A procedure for stabilization of the infraorbital rim in comminuted malar complex fractures.** Yamashita DD, Arnet GF .Plast Reconstr Surg. 1981 Mar ;67(3):375-7.

10. The use of the foley catheter in the treatment of zygomatic bone fractures,B.S., D.D.S. D. Gutman,

D.M.D. D.Lafer, D.M.D. A Neder;**British Journal of Oral Surgery**,Volume 2, 1964–1965, Pages 153-157.

11. Fixation of bone fragments using a Foley catheter in the comprehensive treatment of maxillo-zygomatic fractures.Czas Stomatol. 1979 Mar ;32(3):237-42

12. P G Moore ,Part X: Trauma;Chapter 68: Faciomaxillary and Upper Airway Injuries.

13. MIDFACE FRACTURES;SOURCE: Dept. of Otolaryngology, UTMB, Grand Rounds;DATE: APRIL 17, 1996 RESIDENT PHYSICIAN: Michael Bryan, M.D.;FACULTY: Brian Driscoll, M.D.;SERIES EDITOR: Francis B. Quinn, Jr., M.D.

14. Unilateral Fractures;Dr John Hennessy,The Australian Rural Doctor – February 2004