



Volume 3 Issue 1 2013

ISSN: 2250-0359

SINONASAL VERRUCOUS CARCINOMA

Case series and review of literature

*SAJAD.M.QAZI * IRFAN IQBAL * ANEESA MIRZA *IHSHAN ALI *SHEETAL

*DEPARTMENT OF OTORHINOLARYNGOLOGY HEAD AND NECK SURGERY, S.M.H.S
HOSPITAL, GMC SRINAGAR

Abstract:

Verrucous carcinoma is a low grade malignancy and is a variant of squamous cell carcinoma. It is a rare tumour of the Sino nasal tract. The neoplasm occurs in older people usually in the seventh or eighth decade of life. Our cases were sinonasal in origin and patients affected were young.

Introduction:

Verrucous carcinoma is a rare entity in the Sino nasal tract¹. It was first described and characterised as a distinct entity in 1948 by Ackerman². Verrucous carcinoma involving the upper aero digestive tract is most in the oral cavity with the glottic larynx being the most frequent non oral head and neck site³. Verrucous carcinoma of the nose has been reported to involve the columella⁴, nasal septum⁵, nasopharynx⁶ and uncommonly the Para nasal sinuses. The incidence varies from 4.5% to 9% and elderly men are most often affected⁷.

Discussion:

Verrucous carcinoma is a highly differentiated variant of squamous cell carcinoma⁸. It has cytological and architectural features similar to that of a reactive process and not that of invasive carcinoma. However, it has the ability to invade normal tissues to a limited extent, demonstrating its aggressiveness⁹. The gross appearance is usually a warty, grey white lesion with filiform projections. The characteristic histologic features are highly keratinising surface,

papillary areas and apparent absence of dysplastic changes in the squamous epithelium⁸. Regional lymph node metastasis and distant metastasis are extremely rare⁵. Tobacco plays a significant role in the pathogenesis of verrucous carcinoma of the aero digestive tract². An association between human papilloma virus and verrucous carcinoma has also been proposed. However results have been inconsistent. Although HPV types 6, 11, 16 and 18 have been detected to varying degrees in verrucous carcinoma of the oral cavity and the larynx^{10,11}. Orvidas et al could detect no HPV in association with nasal and Para nasal sinus verrucous carcinoma using the polymerase chain reaction technique¹².

The main histopathological differential diagnosis of verrucous carcinoma is from leukoplakia, papilloma, pseudoepitheliomatous hyperplasia, verrucous hyperplasia and highly differentiated squamous cell carcinoma¹³.

Treatment of verrucous carcinoma remains controversial. Surgery is the mainstay of treatment of this neoplasm. Radiotherapy is reported to cause anaplastic change in the tumour within 6 months, making it more aggressive with change of distant metastasis^{14,15}

CASE 1:

A 30 year old female, housewife by occupation presented to our hospital with left nasal obstruction and left nasal anosmia for 1 year. The patient's medical history was unremarkable. Anterior rhinoscopy revealed a greyish white mass which was insensitive to touch in left nasal cavity. Routine laboratory tests were within normal limits. Contrast enhanced CT PNS revealed (FIG;1) CONTRAST ENHANCED MASS INVOLVING WHOLE OF LEFT NASAL CAVITY AN GOING INTO INFERIOR MARGINS OF ORBIT. Pre-operative biopsy of the nasal mass was suggestive of verrucous squamous neoplasm. Left subtotal maxillectomy, left anterior and posterior ethmoidectomy, left sphenoidotomy, left frontal sinusotomy with orbital floor repair was done. The patient had an uneventful post-operative recovery. Histopathological examination of the surgical specimen showed marked hyperplasia of epidermis with thick bands of parakeratin, bland squamous cells with broad rete ridges suggesting diagnosis of verrucous carcinoma.

CASE 2:

A 50 year old male presented with complaints of right nasal obstruction for last 5 months. The patient was operated 2 years back for same complaint by endoscopic approach. Histopathological examination of the resected specimen showed squamous papilloma. Presently on anterior rhinoscopy no mass was visualised and contrast enhanced CT PNS showed (FIG;2)CONTRAST ENHANCED MASS INVOLVING RT. NASAL CAVITY INVOLVING BOTH ANT. AND POST. ETHMOIDS. Endoscopic excision of mass was planned. Intraoperatively mass was seen involving right maxilla, anterior and posterior ethmoids, sphenoid and roof of nasal cavity. Post-operative period was uneventful. Post-operative histopathological examination of specimen was compatible with verrucous carcinoma.

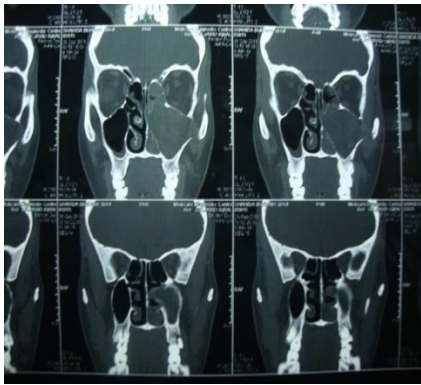


Figure 1

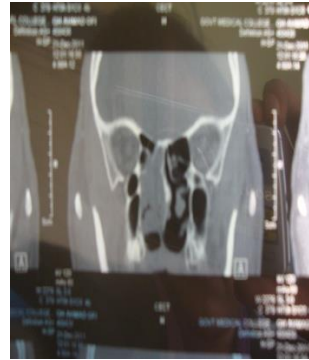

Figure 2

BIBLIOGRAPHY:

1. Michaels L. Ear Nose and Throat histopathology. London: Springer verlag 1987: 171-3.
2. Ackerman LV. Verrucous carcinoma of the oral cavity. *Surgery* 1948;23:670-678.
3. Taybos GM, feltman R, Terezhalmly GT. Verrucous carcinoma invading the orbit. Report of a case. *J oral med* 1983;38:31-34.
4. Vico P, Nagypal P, Rahier I, Derraemaecker R. Verrucous carcinoma of the nasal septum and columella. *ActaChirBelg* 1997;97:50-51.
5. Hanna GS, Ali MH. Verrucous carcinoma of the nasal septum. *J LaryngolOtol* 1987;101:184-187.
6. Wolff AP, Ossoff RH, Clemis JD. Four unusual neoplasms of the nasopharynx. *Otolaryngol Head Neck Surg* 1980;88:753-759.
7. Spiro RH. Verrucous carcinoma, then and now. *Am J Surg* 1998;176:393-397
8. Michaels L. Ear Nose and Throat histopathology. London: Springer verlag 1987: 409-415.
9. Sternberg SS. Diagnostic surgical pathology. Philadelphia PA. Lipincott Raven publishers 1996: 906-908.
10. Fliss DM, Noble-Topham SE, McLachlin CM, et al. Laryngeal verrucous carcinoma. A clinicopathologic study and detection of human papilloma virus using polymerase chain reaction. *Laryngoscope* 1994;104:146-152.
11. Shroyer KR, Greer RO, Fankhouser CA, et al. Detection of human papilloma virus DNA in oral verrucous carcinoma by polymerase chain reaction. *Mod Pathol* 1993;6:669-672.
12. Orvidas LJ, Lewis JE, Olsen KD, Weiner JS. Intranasal verrucous carcinoma: relationship to inverting papilloma and human papilloma virus. *Laryngoscope* 1999;109:371-375.

13. Schrader M, Laberke HG. Differential diagnosis of verrucous carcinoma in the oral cavity and larynx. *J Laryngol otol* 1988; 102: 700-703.
14. Fonts EA, Greenlaw RH, Rush BJ, Roven S. Verrucous squamous cell carcinoma of the oral cavity. *Cancer* 1969; 23: 152-160.
15. Biller HF, Bergmann JA. Verrucous carcinoma of the larynx. *Laryngoscope* 1975; 85: 1698-1700.