



Volume 2, No 1 (2012) ISSN 2250- 0359

FOREIGN BODY ORBIT

Dr Rajaselvam Krishnan Dr T Balasubramanian

Abstract:

The aim of this case presentation was to present the troubles and significance of a proper diagnosis of a foreign body which was retained in the orbit. A 13 years old boy, had a wound on the infraorbital margin caused by a metal foreign body, which stayed in close to the orbit. X-ray and echographic examinations of the orbit were not conclusive regarding the question whether this foreign body was situated within or outside the eyeball. Only CT imaging showed location of the foreign body. Foreign body was extracted by the same healed wound site.

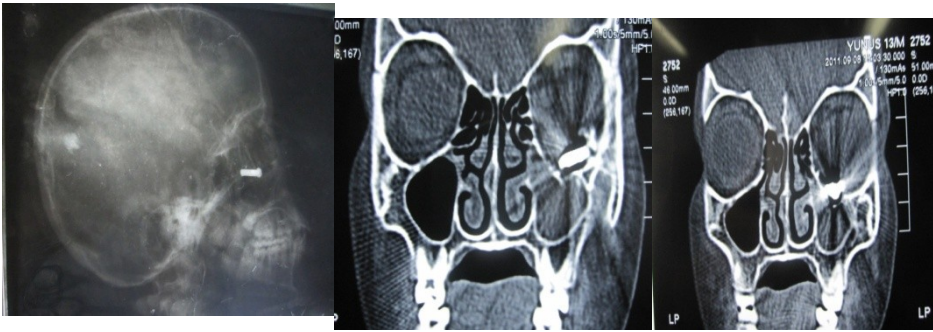
Case history:

13 years old boy fell down over a steel rod while playing. He was treated elsewhere and suture done immediately after the injury in the right infraorbital margin. He presented after 4 days to us.

On examination, Proptosis (mild) of right eye+. Upwards movement of eye was restricted. Sutured wound seen just below right orbit (Fig-4). Wound had been healed. vision RE: 6/6 LE: 6/6. The patient was afebrile. No other specific complaints.

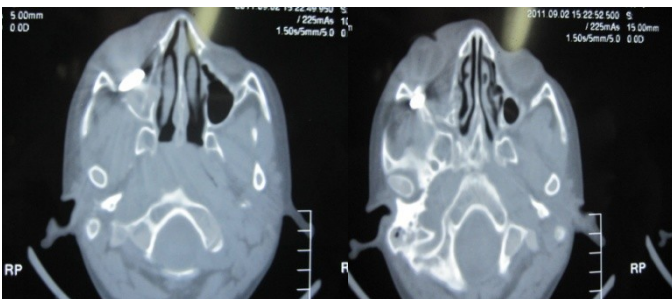
X-ray orbit revealed periosteal reaction of orbital floor near the wound site. The patient's general health was good. A diagnosis of foreign body right orbit was made.

Since metal foreign body noticed in plain radiographs and CT (Fig 2-3-4), exploration under general anaesthesia was planned.



X-ray skull lateral Fig1

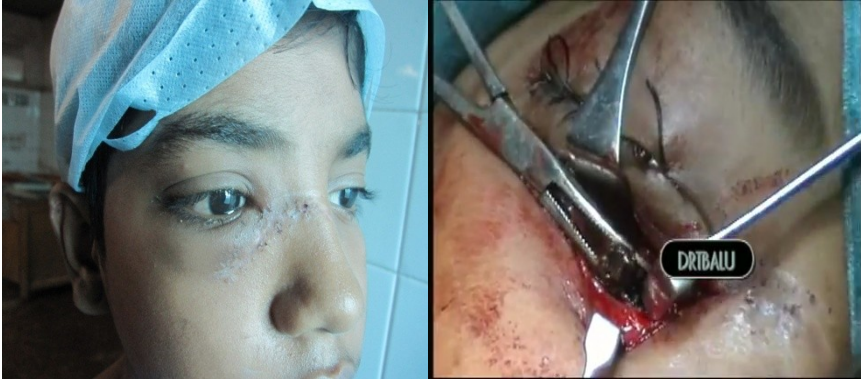CT nose and sinuses coronal cut showing FB Fig 2



CT-PNS axial section Fig 3

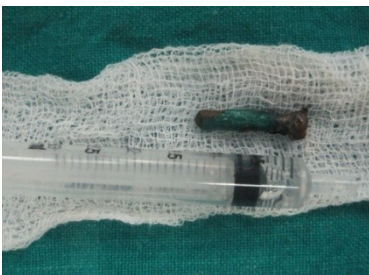Procedure :

Under GA, patient in supine position ,insicion made along the sutured wound ,meticulous dissection made out and the steel foreign body was found out at the apex of the orbit and the same is removed(Fig-5&6). Skin sutured with 2.0 silk. Post operative period was uneventfull.Patient discharged after one week .



Pre op picture Fig 4

Intraop picture Fig 5



FB after removal Fig 6

Discussion

The presence of a foreign body was not suspected initially due to inadequate history and paucity of clinical findings. An object that penetrates through the orbit may leave only a small entry wound². These patients may have normal vision, a normal neurological examination, despite trauma that may lead to significant complications⁶.

A plain radiograph and CT of the orbit was performed when the patient came back. The plain radiograph and CT showed the presence and exact location of the foreign body (Fig 2-3-4).

Intra-orbital foreign bodies usually result from occupational accidents, gunshot injuries and road traffic accidents. Self-inflicted injuries have also been reported⁵. Most of the foreign bodies are metallic, wooden particles or glass pieces¹.

Accurate localization of foreign bodies in the region of the orbit is vital for correct management⁴. CT is the investigation of choice. Both axial and direct coronal views are preferred with 3mm sections proving sufficient for most orbital injuries³.

Though it is not necessary to surgically remove inert extraocular foreign bodies, in our case, surgical removal was performed considering the risk of infection.

In an age when plastics are used in most day to day objects and are largely replacing metal and glass, it must be remembered that plastic is not particularly radio-opaque and can be missed on plain radiographs. The superior sensitivity of CT for detecting small variations in X-ray absorption allows easy and accurate detection of such foreign bodies.

It is surprising to come across such lengthy foreign bodies which are retained for long periods without the patients being aware (Fig 6). The metal particle in the above cases have remained in orbit for a long time without any symptoms. After an initial quiescent period of considerable variability in duration ranging from days to years complications often arise. There may be granuloma, orbital cellulitis, orbital abscess, osteomyelitis, periosteitis or chronic draining fistula, through the conjunctiva or through the palpebral skin. Retained foreign body is frequently missed due to its location within the orbit and its relative radio-lucency.

REFERENCES:

1. Feist RM, Lim JI, Joondeph BC, Pflugfelder SC, Mieler WF, Ticho BH, Resnick K. "Penetrating ocular injury from contaminated eating utensils." *Archives of Ophthalmology*. 1991 Jan;109(1):23-30. PMID 1987951.
2. Bullock JD, Warwwar RE, Bastley GB, Waller RR, Henderson JW. Unusual orbital foreign bodies. *Ophthal Plast Constr Surg* 1999; 15: 44-51.
3. Peter AD Rubin Jurij R Bilyk John Wshore. Management of orbital trauma: Fractures, hemorrhage and traumatic optic neuropathy. *Focal points*. Sept 1994; 12: 1-17.
4. Etherington R.J. Houriham M.D. Localistaion of intraocular and intraorbital foreign bodies using computed tomography. *Clinical Radiology* 1989; 40: 610-614.
5. Green KA, Dickman CA, Smith KA, Kinder EJ, Zabramski, JM. Self-inflicted orbital and intracranial injury with a retained foreign body, associated with psychotic depression: case report and review. *Surg Neurol* Dec1993; 40: 499-503.
6. Wesley RE anderson SR, Weiss PIR, Smith HP. Management of orbital cranial trauma. *Adv. Ophthal Plastic Reconstruct. Surgery* 1987; 7: 3-26
7. Macral J.A. 1979, *Brit. J, Ophthalmol* 63; 848. †
8. *Journal of Maxillofacial Surgery, Volume 12, 1984, Pages 97-102*
9. *Neurosurgery*. 2006 May;58(5):E999; discussion E999.

