

Open

Evaluation of Esophageal Motility Utilizing the Functional Lumen Imaging Probe

Dustin A. Carlson, MD, MS¹, Peter J. Kahrilas, MD¹, Zhiyue Lin, BS¹, Ikuo Hirano, MD¹, Nirmala Gonsalves, MD¹, Zoe Listernick, BS¹, Katherine Ritter, BA¹, Michael Tye, BA¹, Fraukje A. Ponds, MD², Ian Wong, MD³ and John E. Pandolfino, MD, MS¹

- OBJECTIVES:** Esophagogastric junction (EGJ) distensibility and distension-mediated peristalsis can be assessed with the functional lumen imaging probe (FLIP) during a sedated upper endoscopy. We aimed to describe esophageal motility assessment using FLIP topography in patients presenting with dysphagia.
- METHODS:** In all, 145 patients (aged 18–85 years, 54% female) with dysphagia that completed upper endoscopy with a 16-cm FLIP assembly and high-resolution manometry (HRM) were included. HRM was analyzed according to the Chicago Classification of esophageal motility disorders; major esophageal motility disorders were considered “abnormal”. FLIP studies were analyzed using a customized program to calculate the EGJ-distensibility index (DI) and generate FLIP topography plots to identify esophageal contractility patterns. FLIP topography was considered “abnormal” if EGJ-DI was $<2.8 \text{ mm}^2/\text{mm Hg}$ or contractility pattern demonstrated absent contractility or repetitive, retrograde contractions.
- RESULTS:** HRM was abnormal in 111 (77%) patients: 70 achalasia (19 type I, 39 type II, and 12 type III), 38 EGJ outflow obstruction, and three jackhammer esophagus. FLIP topography was abnormal in 106 (95%) of these patients, including all 70 achalasia patients. HRM was “normal” in 34 (23%) patients: five ineffective esophageal motility and 29 normal motility. In all, 17 (50%) had abnormal FLIP topography including 13 (37%) with abnormal EGJ-DI.
- CONCLUSIONS:** FLIP topography provides a well-tolerated method for esophageal motility assessment (especially to identify achalasia) at the time of upper endoscopy. FLIP topography findings that are discordant with HRM may indicate otherwise undetected abnormalities of esophageal function, thus FLIP provides an alternative and complementary method to HRM for evaluation of non-obstructive dysphagia.

Am J Gastroenterol 2016; 111:1726–1735; doi:10.1038/ajg.2016.454; published online 11 October 2016

INTRODUCTION

An evaluation of esophageal motility is indicated for the evaluation of non-obstructive dysphagia. Esophageal manometry is the primary methodology used and typically evaluates primary peristalsis and esophagogastric junction (EGJ) pressures following standardized swallows. However, the trans-nasal catheter placement required for esophageal manometry is associated with patient discomfort. In addition, the standard manometric evaluation may not identify an etiology for patients’ symptoms (1). Thus,

an alternate method to objectively evaluate measure esophageal motility would be valuable.

The functional lumen imaging probe (FLIP) uses high-resolution impedance planimetry to measure the relationship of luminal dimensions and distensive pressure (i.e., distensibility) during controlled, volumetric distension. The distensibility of the EGJ is assessed by a metric termed the EGJ-distensibility index (DI), which was demonstrated to be abnormally low in treatment-naïve achalasia (2–4). Distension-mediated contractility was reported in

¹Department of Medicine, Division of Gastroenterology and Hepatology, Feinberg School of Medicine, Northwestern University, Chicago, Illinois, USA;

²Department of Gastroenterology and Hepatology, Academic Medical Center, University of Amsterdam, Amsterdam, The Netherlands; ³Department of Surgery, The University of Hong Kong, Hong Kong SAR, China. **Correspondence:** Dustin A. Carlson, MD, MS, Department of Medicine, Division of Gastroenterology and Hepatology, Feinberg School of Medicine, Northwestern University, 676 St Clair Street, Suite 1400, Chicago, Illinois 60611-2951, USA.

E-mail: dustin-carlson@northwestern.edu

Received 27 May 2016; accepted 23 August 2016

initial studies utilizing esophageal impedance planimetry and later observed as a complicating factor during FLIP-distensibility assessment of the esophageal body in eosinophilic esophagitis (5–8). However, by using customized software to generate FLIP topography plots, organized patterns of distension-associated contractions were identified (9–11). In asymptomatic controls, the predominant contractile pattern involved repetitive, antegrade contractions (RACs), which we proposed was a secondary peristaltic response to the sustained volumetric distension that occurs during the FLIP study. Esophageal contractions were also frequently observed with FLIP topography among achalasia patients and the patterns of contractility differed by subtype (11). The majority of non-spastic (type I and II) achalasia patients demonstrated absent or non-patterned contractility. Patients with spastic (type III) achalasia typically demonstrated repetitive, retrograde contractions (RRCs), a pattern not observed in asymptomatic controls, suggesting that RRCs are a pathological finding.

Although awake trans-nasal placement of the FLIP can be used, the FLIP study can be performed in <5 min during a sedated upper endoscopy. Thus, FLIP represents a well-tolerated method that can be used at the time of an upper endoscopy to evaluate non-obstructive dysphagia. Analogous to the hierarchical analysis of high-resolution manometry (HRM) studies that first evaluate deglutitive EGJ pressures and then the associated esophageal contractility pattern (12,13), we hypothesized that a similar scheme could be applied to FLIP topography using EGJ-DI and distension-induced contractility. Thus, we aimed to evaluate the diagnostic utility of FLIP topography to assess esophageal motility in patients with non-obstructive dysphagia.

METHODS

Subjects

Patients presenting to the Esophageal Center of Northwestern for evaluation of dysphagia between November 2012 and April 2016 who completed HRM and FLIP during upper endoscopy were prospectively included. Upper endoscopy was completed using sedation with midazolam (2–15 mg) and fentanyl (0–300 mcg); propofol (in addition to midazolam and fentanyl) was used with anesthesiologist assistance at the discretion of the performing endoscopist in some cases. Patients with previous upper gastrointestinal surgery, significant medical co-morbidities, eosinophilic esophagitis, severe reflux esophagitis (LA-classification C or D), or large hiatal hernia were excluded. Patients were often identified by referral for manometry, thus FLIP was commonly included with the endoscopic evaluation if an esophageal motility disorder was suspected. Enrollment of achalasia patients was prioritized, but limited to 70 patients: 49 of the achalasia patients were previously described (11). We intentionally included an excess of achalasia patients to evaluate the diagnostic effectiveness of FLIP topography for this important esophageal motility disorder. Additional clinical evaluation (e.g., barium esophagram) were obtained and management decisions made at the discretion of the primary treating gastroenterologist. The study protocol was approved by the Northwestern University institutional review board.

High-resolution manometry

Manometry studies were completed using a 4.2-mm outer diameter solid-state assembly with 36 circumferential pressure sensors at 1-cm intervals (Medtronic, Shoreview, MN, USA). After a minimum 6-h fast, the HRIM assembly was placed trans-nasally and positioned to record from the hypopharynx to the stomach with approximately three intragastric pressure sensors. The HRM protocol included a 5-min baseline recording, ten 5-ml swallows in a supine position using 50% saline for test swallows at 20–30 s intervals.

Functional lumen imaging probe

The FLIP assembly consisted of a 240-cm long, 3-mm outer diameter catheter with an 18-cm, infinitely compliant balloon (up to a distension volume of 60 ml) mounted near the distal end of the catheter (EndoFLIP; Crospon, Galway, Ireland). The balloon tapered at both ends to assume a 16-cm long cylindrical shape in the center that housed 17 impedance planimetry ring electrodes spaced at 1-cm intervals and a solid-state pressure transducer positioned at the distal end to provide simultaneous measurement of 16 channels of cross-sectional area (CSA) converted to diameter based on the assumption of circular geometry and intraballoon pressure. The impedance planimetry segment had a range of measureable diameters of 5.2–22 mm within the infinitely compliant limits of the balloon. Diameter and pressure values could be measured when the balloon was distended beyond a 22-mm diameter, but mechanical properties of the balloon would be engaged. Measurements from the impedance planimetry electrode pairs and the pressure transducer were sampled at 10 Hz with the data-acquisition system and transmitted to the recording unit.

Subjects underwent sedated upper endoscopy in the left lateral decubitus position. The FLIP probe was placed trans-orally and positioned with the distal 2–3 impedance sensors beyond the EGJ as confirmed by demonstration of a waist in the impedance planimetry segment at a balloon distension volume of 20–30 ml. The endoscope was withdrawn before initiation of the FLIP study protocol. The FLIP assembly position was adjusted by the endoscopist during the study to maintain placement relative to the EGJ as visualized on real-time output. Simultaneous CSAs and intra-balloon pressures were measured during 5–10 ml stepwise distensions beginning with 5 ml and increasing to target volume of 60 or 70 ml; each incremental distension volume was maintained for 10–30 s. The distension protocol was modified during the course of the evaluation period, initially with a limit of 60 ml and later to a limit of 70 ml, as well as initially with 5-ml stepwise distensions and later with 10-ml stepwise distensions. The recording unit was set to stop infusing and display an alarm message if the intra-balloon pressure exceeded 60 mm Hg, which sometimes limited the extent of balloon distension.

Data analysis

Manometry studies were analyzed using ManoView version 3.0 (Medtronic, Shoreview, MN) analysis software to measure basal EGJ pressure at end-expiration, the 4-s integrated relaxation pressure (IRP), distal contractile integral, and distal

latency. Esophageal motility diagnoses were generated from the ten supine swallows according to the Chicago Classification v3.0, using a median IRP of 15 mmHg as the upper-limit of normal (13). Achalasia, EGJ outflow obstruction (EGJOO), absent contractility, distal esophageal spasm, or jackhammer esophagus were considered major motility disorders (i.e., those not observed in asymptomatic controls) (13).

FLIP data including distension volume, intra-balloon pressure, and 16 channels of luminal diameter for each subject were exported to MATLAB (The Math Works, Natick, MA) for analysis using a customized MATLAB program (14). This program applied a filter to minimize vascular and respiratory artifact and then generated tracings of each channel's luminal diameter. Interpolation between channels was applied to generate color-coded topography plots by time with corresponding plots of volume distension and intra-balloon pressure. The program identified the EGJ-midline by searching for the minimal diameter of the distal impedance planimetry channels. The EGJ-DI was calculated by measuring the narrowest EGJ CSA and intra-balloon pressure at each data sample obtained during the time course at the 60-ml distension volume, which corresponds with the 40-ml distension volumes previously reported using a shorter (8-cm) FLIP assembly (3). The median values for narrowest EGJ CSA and intra-balloon pressure were then divided to calculate the EGJ-DI (CSA/pressure; mm²/mm Hg). If a 60-ml distension volume was not achieved, values obtained at the maximum fill volume were utilized to calculate the EGJ-DI. An EGJ-DI < 2.8 mm²/mm Hg was considered abnormal based on the lower range of values from previously evaluated normal controls (11). This value was also reported as a reliable threshold using shorter (6.4 cm and 8 cm) FLIP assemblies (2,3).

Esophageal body contractions were identified by a transient decrease of ≥ 5 mm in the measured luminal diameter detected in ≥ 2 adjacent axial impedance planimetry channels using the FLIP topography plots and 16-channel diameter-tracing output (10,11). Contractions were described in terms of propagation direction (antegrade or retrograde) based on the tangent line placed on the onset of contraction. Contractions were considered repetitive (RACs or RRCs based on propagation direction) when ≥ 3 occurred consecutively. The presence of RACs and RRCs was not mutually exclusive, thus both could be present in a single patient over the course of the FLIP study.

A FLIP topography esophageal motility diagnosis was generated for each patient using the classification scheme detailed in **Figure 1**. Motility diagnoses were classified using a hierarchical scheme designating (i) presence or absence of EGJOO as defined by an abnormal EGJ-DI and (ii) contractility pattern (**Figure 2**): (a) absent contractility, (b) contractility without RACs nor RRCs, (c) RACs without RRCs, and (d) RRCs, with or without RACs. Findings not observed in asymptomatic controls (abnormal EGJ-DI, absent contractility, or RRCs) constituted a major motor disorder and were considered "abnormal" FLIP topography (10,11).

Statistical analysis

Values are expressed as median (interquartile range), unless otherwise specified. Groups were compared using χ^2 -test or Kruskal-

Wallis test for categorical and continuous variables, respectively. Analyses assumed a 5% level of statistical significance; a *post hoc* Bonferroni's correction was applied for multiple comparisons.

RESULTS

Subjects

In all, 145 patients (mean age 52 years, range 18–85; 54% female) were included in the analysis. A major motility disorder on HRM was observed in 111 (77%) patients; HRM motility diagnoses included 70 (48%) patients with achalasia (19 (13%) type I, 39 (27%) type II, and 12 (8%) type III), 38 (26%) with EGJOO, and three (2%) with jackhammer esophagus. The remaining 34 (23%) patients without major motility disorders included 5 (4%) patients with ineffective esophageal motility (IEM) and 29 (19%) patients with normal motility. Two patients were diagnosed with achalasia with an IRP < 15 mm Hg via Chicago Classification caveats: one had absent contractility with an IRP of 12 mm Hg (type I achalasia) the other had pan-esophageal pressurization with an IRP of 12 mm Hg (type II achalasia). Patient characteristics by esophageal motility diagnosis are displayed in **Table 1**. Though the majority of patients underwent endoscopy with conscious sedation, 10 (7%) patients had an endoscopic-sedation regimen including propofol. There were no differences in sedation dosages or propofol usage between patients with normal and abnormal EGJ-DI or among patients based on FLIP topography motility classification (**Table 2**). Seven patients, five with achalasia (three type III) and two with normal motility on HRM, were on chronic opiate therapy at the time of evaluation.

During the study period, two patients were unable to tolerate HRM but had FLIP performed that both demonstrated abnormal EGJ-DI (0.7 and 1.0 mm²/mm Hg) and absent contractility. They were both subsequently diagnosed as achalasia and treated with 30-mm balloon dilation. Without corresponding HRM, they were not included in subsequent analysis. In addition, there were 13 patients excluded for poor FLIP catheter placement (i.e., distal migration of the catheter that prevented contractility evaluation) and six excluded for technical-limitations.

Relationship of HRM and FLIP topography

Of the 105 patients with an EGJOO (IRP > 15 mm Hg) on HRM, 98 (85%) also had an EGJOO (EGJ-DI < 2.8 mm²/mm Hg) on FLIP. EGJ-DI differed among HRM motility diagnoses ($P < 0.001$, **Figure 3**). A *post hoc* Bonferroni's adjustment for multiple comparisons assumed statistical significance at a P value of 0.003; due to small sample size, jackhammer patients were not subjected to pair-wise group comparison. Achalasia (all three sub-types) and EGJOO had lower EGJ-DI compared with normal motility (P values ≤ 0.001). Type II achalasia and type III achalasia had lower EGJ-DI compared with IEM (P values ≤ 0.001); there was a numeric trend toward lower EGJ-DI in type I achalasia and EGJOO than IEM (P values = 0.005). Trends toward differences in EGJ-DIs were also detected between type I and type II achalasia ($P = 0.034$), type I and type III achalasia ($P = 0.011$), type II and type III achalasia ($P = 0.087$), and type III achalasia and EGJOO ($P = 0.038$).

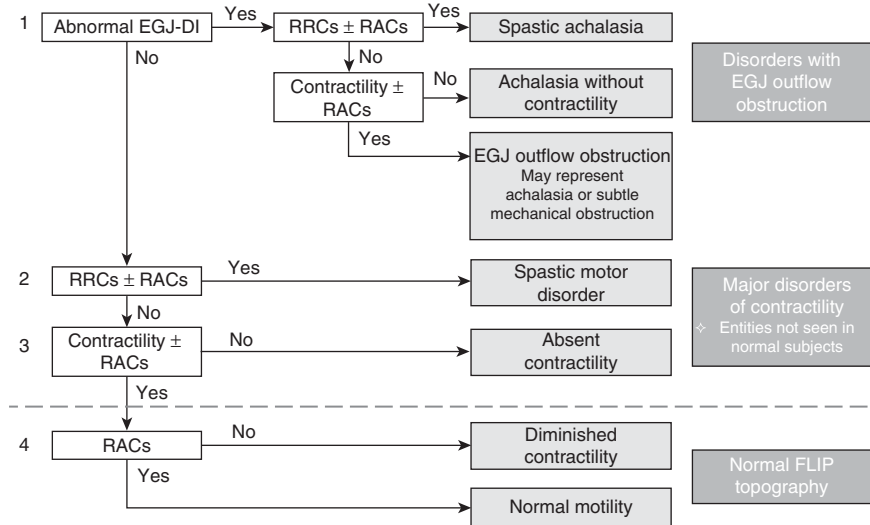


Figure 1. Functional lumen imaging probe (FLIP) topography motility classification. FLIP topography motility diagnoses were generated using a hierarchical analysis scheme based on (i) esophagogastric junction (EGJ)-distensibility index (DI) and (ii) contractile pattern. Motility diagnoses above the dashed line represent patterns not observed in asymptomatic controls and therefore considered major motor disorders, i.e., “abnormal” FLIP topography. RACs, repetitive, antegrade contractions; RRCs, repetitive, retrograde contractions.

Among all patients, FLIP topography contractility patterns consisted of 30 (19%) patients with no contractility, 25 (16%) patients with contractility, but without RACs or RRCs, 77 (53%) patients with RACs, and 50 (34%) patients with RRCs; 27 (17%) had both RACs and RRCs. FLIP topography contractility patterns differed among HRM esophageal motility diagnoses ($P < 0.001$). Frequencies of FLIP topography classifications by HRM diagnosis are displayed in **Table 3**. The majority (68%) of type I achalasia patients had abnormal EGJ-DI with absent contractility (achalasia without contractility) and the majority (83%) of type III achalasia patients had abnormal EGJ-DI with RRCs (spastic achalasia). There was a more substantial amount of heterogeneity of FLIP topography classifications among patients with type II achalasia, EGJOO, IEM, and normal motility.

Among the 111 patients with a major motility disorder on HRM, 106 (95%) had a FLIP topography pattern consistent with a major motility disorder, i.e., abnormal FLIP topography (**Figure 4**). Of the 34 patients without a major motility disorder on HRM, 17 (50%) had abnormal FLIP topography.

All 70 patients with achalasia by HRM had abnormal FLIP topographies. Sixty-eight (97%) had an abnormal EGJ-DI. Of the remaining two achalasia patients with normal EGJ-DI, one (type I HRM) had absent contractility; the other (type II HRM) had RRCs (spastic motor disorder). Both of these patients had a median intra-balloon pressure during the 60-ml fill volume of 11 mm Hg, whereas the median CSAs were only 33 and 38 mm² (i.e., diameters of 6.5 and 7 mm, respectively). In addition, the two-included achalasia patients with IRP < 15 mm Hg had EGJ-DIs of 1.6 (**Figure 5a**) and 1.7 mm²/mm Hg.

An abnormal FLIP topography was observed in 33 of 38 (87%) patients with EGJOO on HRM. An achalasia without contractility pattern was observed in two (5%) EGJOO patients; in both,

the global clinical impression was of evolving achalasia: one was treated with botulinum toxin injection (**Figure 5b**), and the other is being evaluated for lower esophageal sphincter myotomy. Five (13% of 38) patients with EGJOO on HRM (median IRPs ranging from 19 to 26 mm Hg) had normal EGJ-DI; all five also had RACs and thus normal FLIP topography. Median intra-balloon pressures at the 60-ml fill volume were >30 mm Hg and median CSA was >180 mm² (diameter 15 mm) for all five. Three of these patients had barium esophagrams judged to be normal either on the basis of normal 12.5 mm tablet passage ($n=2$) or rapid clearance of 200 ml of a thin liquid barium challenge ($n=1$; **Figure 5c**). For these five patients, one was treated with hyoscyamine, one was referred for cognitive behavioral therapy, and the remaining three patients were managed with observation.

An abnormal FLIP topography was observed in all three patients with jackhammer on HRM. All three had an abnormal EGJ-DI and RRCs.

Abnormal FLIP topography was observed in 50% (17/34) of patients with normal motility or IEM on HRM. An EGJOO was the most common criterion for FLIP topography abnormality observed in 13/17 (76%). Four patients had abnormal EGJ-DI and RRCs (i.e., a FLIP topography spastic achalasia pattern); among these, two had a single hypercontractile (distal contractile integral >8,000 mm Hg/cm per s) swallow, one had a barium esophagram and endoscopic ultrasound consistent with achalasia (**Figure 5d**), and one an esophagram with tertiary contractions, but normal passage of a 12.5 mm tablet. Among the remaining nine patients with an abnormal EGJ-DI and normal motility or IEM on HRM, four completed an esophagram: two were normal, one had transient delay of a 12.5 mm barium tablet at the EGJ, and one patient was unable to swallow a 12.5 mm barium tablet. Among the remaining five patients, one had dysphagia improvement following empiric

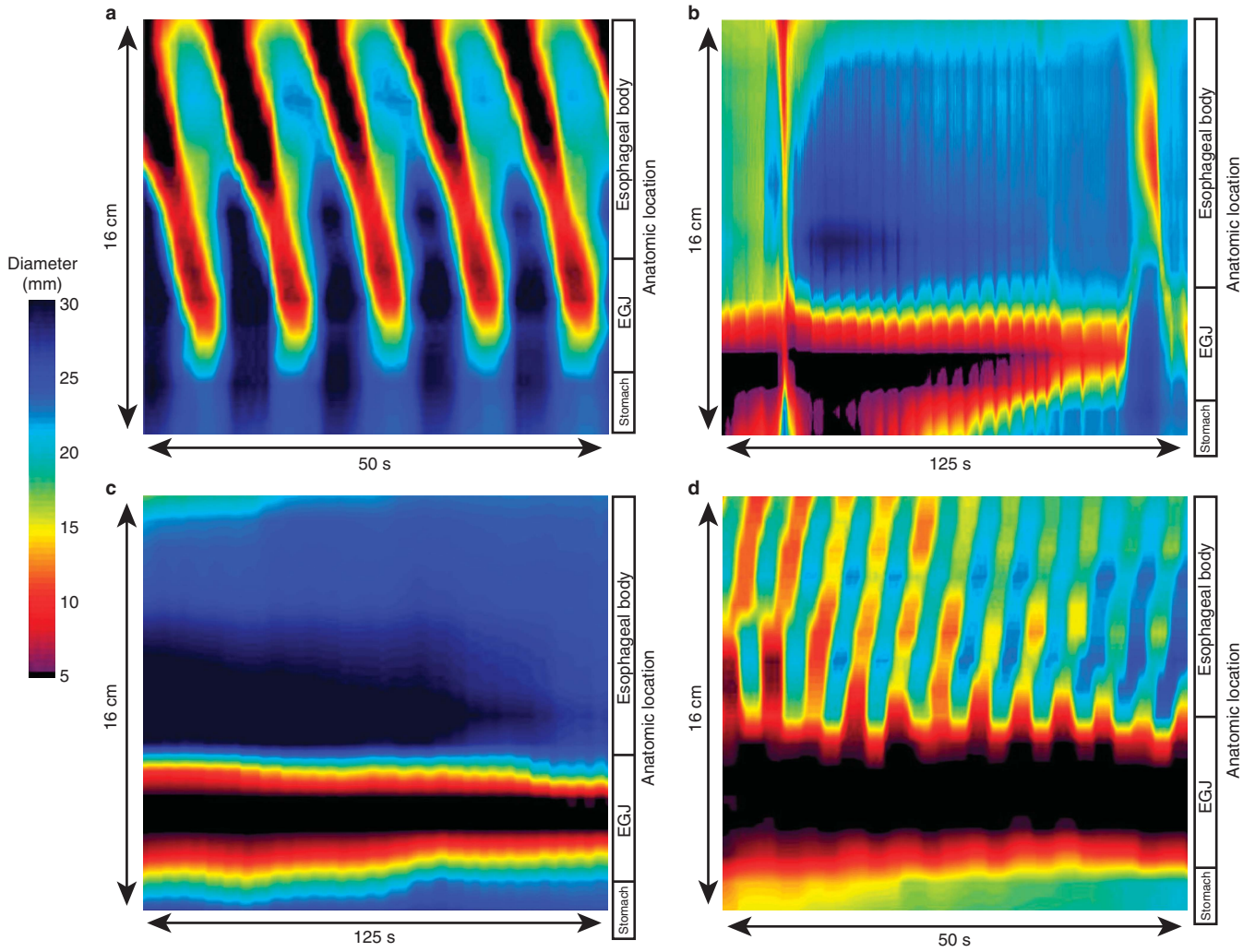


Figure 2. Functional lumen imaging probe (FLIP) topography contractile patterns. (a) Repetitive, antegrade contractions (RACs) from a patient with normal motility on high-resolution manometry (HRM). RACs were the most commonly observed contractile pattern in asymptomatic controls (10,11). (b) Contractility without RAC or repetitive, retrograde contractions in a patients with a HRM demonstrating EGJ outflow obstruction with a peristaltic pattern of ineffective esophageal motility. (c) Absent contractility in a patient with type I achalasia on HRM. (d) Repetitive, retrograde contractions (RRCs) in a patient with type III achalasia on HRM.

Table 1. Subject characteristics by high-resolution manometry motility diagnosis

	Type I achalasia	Type II achalasia	Type III achalasia	EGJOO	Jackhammer	IEM	Normal motility
<i>n</i>	19	39	12	38	3	5	29
Age (years)	57 (40–67)	47 (28–62)	65 (58–67)	60 (49–67)	52, 60, 79	50 (45–63)	48 (31–59)
Gender (F/M)	8/11	17/22	4/8	23/15	2/1	3/2	21/8
Median IRP (mm Hg)	38 (24–56)	33 (25–42)	32 (22–42)	22 (19–26)	12, 12, 13	12 (6–13)	9 (6–12)
Basal EGJ pressure (mm Hg)	30 (19–45)	26 (23–41)	38 (29–46)	32 (24–44)	32, 49, 55	8 (8–21)	16 (11–23)

EGJ, esophago-gastric junction; EGJOO, EGJ outflow obstruction; F, female; IEM, ineffective esophageal motility; IRP, integrated relaxation pressure; M, male. Values are median (IQR) unless otherwise specified.

Table 2. Sedation dosages and utilization among FLIP topography findings

FLIP classification	n	Midazolam, mg; median (IQR)	Fentanyl, mcg; median (IQR)	Propofol, n (%)
Abnormal EGJ-DI	117	7 (5–9)	150 (125–200)	8 (7)
Normal EGJ-DI	28	8 (5–9)	150 (125–200)	2 (7)
Abnormal FLIP topography	123	7 (5–9)	150 (125–200)	8 (7)
Normal FLIP topography	22	8 (5–9)	150 (119–200)	2 (9)
Achalasia without contractility	29	7 (6–10)	163 (125–200)	3 (10)
Spastic achalasia	44	5 (5–9)	125 (125–200)	4 (9)
EGJOO	44	7 (5–8)	150 (125–175)	1 (2)
Spastic motor disorder	5	9 (7–10)	200 (175–200)	0
Absent contractility	1	5	125	0
Diminished contractility	1	10	200	0
Normal motility	21	8 (5–9)	150 (113–188)	2 (10)

EGJ-DI, esophagogastric junction distensibility index; EGJOO, EGJ outflow obstruction; FLIP, functional lumen imaging probe; IQR, interquartile range.

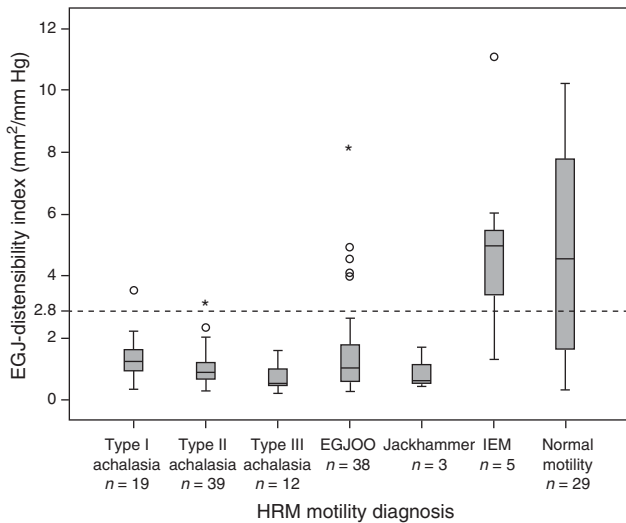


Figure 3. Esophagogastric junction (EGJ)-distensibility index (DI) by manometric esophageal motility diagnosis. The dashed line indicates the lower range of normal based on previous study of asymptomatic controls (10,11). EGJOO, esophagogastric junction outflow obstruction; IEM, ineffective esophageal motility; HRM, high-resolution manometry.

bougie dilation, two were treated with hyoscyamine, and observation was recommended in two (including a patient on chronic opiate therapy).

Finally, four patients (11% of 35) with normal motility or IEM on HRM had RRCs and a normal EGJ-DI on FLIP topography.

Among these patients, one had a history of food impaction resulting in endoscopic disimpaction, but esophageal mucosal biopsies, HRM, and esophagram that were normal. The remaining three patients with RRCs had reflux or esophageal hypersensitivity suspected as the etiology for their symptoms.

DISCUSSION

The main finding of our study was that esophageal motility evaluation with FLIP topography generated during a sedated upper endoscopy accurately detected major esophageal motility disorders and achalasia: 95% of patients with a major motility disorder on HRM had an abnormal FLIP topography including 100% of patients with achalasia on HRM. In addition, FLIP topography appeared to enhance the esophageal functional evaluation of non-obstructive dysphagia by detecting an abnormal response to esophageal distension in 50% of patients with IEM or a normal HRM study. Furthermore, FLIP topography may help arbitrate whether a true EGJOO exists, as opposed to a recording artifact. Thus, FLIP topography may evolve to a disruptive technology for the evaluation of non-obstructive dysphagia that can be performed in conjunction with a sedated upper endoscopy leading to greater patient acceptance.

Although the high proportion of achalasia patients in our cohort may not be representative of typical clinical practice, we thought it was important to adequately assess the diagnosis of this important esophageal motility disorder. In doing so, we demonstrated that all 70 achalasia patients had abnormal FLIP topography. Similar to the significance placed on the IRP for the HRM evaluation by the Chicago Classification, the EGJ-DI is paramount in the FLIP topography evaluation. A caveat of the Chicago Classification dictates that HRM with absent contractility and borderline IRP may be considered as type I achalasia, but it can be difficult to clinically differentiate between achalasia and absent contractility, such as in systemic sclerosis (13). FLIP may help as an arbiter in these borderline cases (as in **Figure 5a**). Among our 70 achalasia patients (by HRM diagnosis), only two (3%) had a normal EGJ-DI. As the EGJ-DI is a calculated value with the denominator consisting of the intra-balloon pressure, the EGJ-DI may be prone to error from pressure readings at extremes of the range. Thus, a caveat that low intra-balloon pressures (e.g., <15 mm Hg) associated with narrow EGJ-diameters (e.g., <12.5 mm) may generate a normal EGJ-DI, but still reflect an EGJOO should be implemented.

Though we described the correspondence of the FLIP topography motility classification with HRM-defined esophageal motility disorders, we recognize that HRM is not a perfect diagnostic tool in the evaluation of non-obstructive dysphagia. HRM may be non-diagnostic and remains susceptible to pressure artifacts that can complicate motility diagnoses, particularly with EGJOO (1). Thus, the objective is not necessarily to reproduce HRM findings, but rather to detect functional abnormalities with clinical significance. Although our assessment of clinical outcomes is limited without a standardized treatment or follow-up protocol, we describe numerous clinical examples (**Figure 5**) from even a relatively small patient cohort in which FLIP topography enhanced the clinical

Table 3. FLIP topography classification by manometric motility diagnosis

HRM motility diagnosis	n	FLIP topography motility classification, n (%)						
		Achalasia without contractility	Spastic achalasia	EGJOO (achalasia or subtle mechanical obstruction)	Spastic motor disorder	Absent contractility	Diminished contractility	Normal motility
Type I achalasia	19	13 (68)	2 (11)	3 (16)	0	1 (5)	0	0
Type II achalasia	39	14 (36)	13 (33)	12 (31)	1 (3)	0	0	0
Type III achalasia	12	0	10 (83)	2 (17)	0	0	0	0
EGJOO	38	2 (5)	13 (34)	18 (47)	0	0	0	5 (13)
Jackhammer	3	0	3 (100)	0	0	0	0	0
IEM	5	0	0	1 (20)	1 (20)	0	1 (20)	2 (40)
Normal	29	0	4 (14)	8 (28)	3 (10)	0	0	14 (48)
Controls (10,11)	10	0	0	0	0	0	2 (20)	8 (80)

EGJOO, esophagogastric junction outflow obstruction; FLIP, functional lumen imaging probe; HRM, high-resolution manometry; IEM, ineffective esophageal motility. Values represent number of patients and percentage within each HRM motility diagnosis. Previously evaluated asymptomatic controls are included as a reference (10,11).

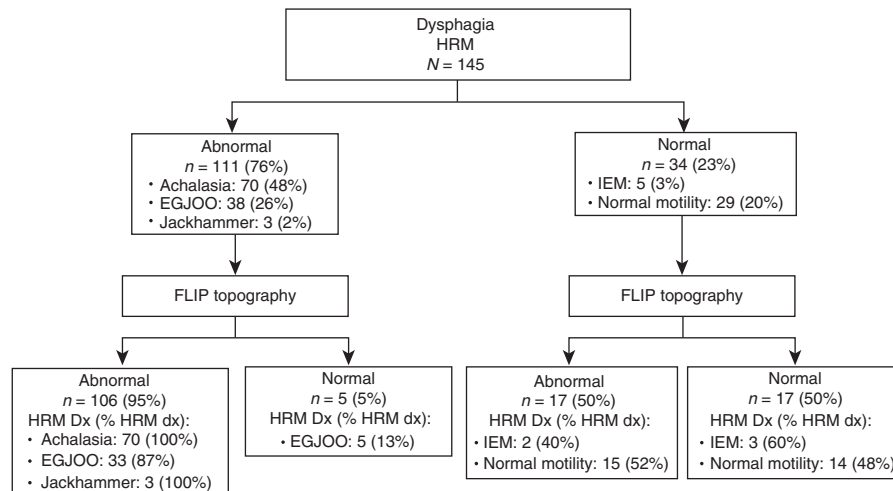


Figure 4. Flow diagram of high-resolution manometry (HRM) and functional lumen imaging probe (FLIP) topography motility diagnoses. “Abnormal” indicated detection of a major esophageal motility disorder. DX, diagnosis; EGJOO, EGJ outflow obstruction; IEM, ineffective esophageal motility.

evaluation beyond what was provided by HRM. Hence, we propose that distinct motility patterns of achalasia without contractility and normal motility identified on FLIP topography may be sufficient to characterize esophageal motility during endoscopy. Further, FLIP topography may supplement the manometric evaluation in non-obstructive dysphagia patients with other less well-defined esophageal motility diagnoses, such as EGJOO.

An HRM diagnosis of EGJOO reflects a heterogeneous patient population, and thus often presents a challenging clinical scenario (13,15). The elevated IRP may not always reflect a primary esophageal motor disorder, but instead can be related to other causes (including hiatal hernia and recording artifact) (13). Although EGJOO may represent evolving achalasia, it can also represent a benign clinical condition in which symptoms spontaneously remit

(15–17). We demonstrated that FLIP topography helps improve characterization of HRM-defined EGJOO patients. EGJOO patients with confirmed abnormal EGJ-response to distension with FLIP topography can be treated with EGJ-directed interventions. The EGJOO patients with normal EGJ-DI in our study did not have evidence of EGJ obstruction on subsequent imaging (as in **Figure 5c**), and thus may represent patients more likely to carry a benign course and thus warrant expectant management.

The majority (13/23, 57%) of our FLIP-HRM discordance to detect major motility disorders resulted from abnormal EGJ-DI in patients with a normal IRP on HRM (normal motility and IEM). In most of these patients, subtle abnormalities were also appreciated in other tests (HRM or esophagram) that supported an abnormality in esophageal function in these symptomatic patients.

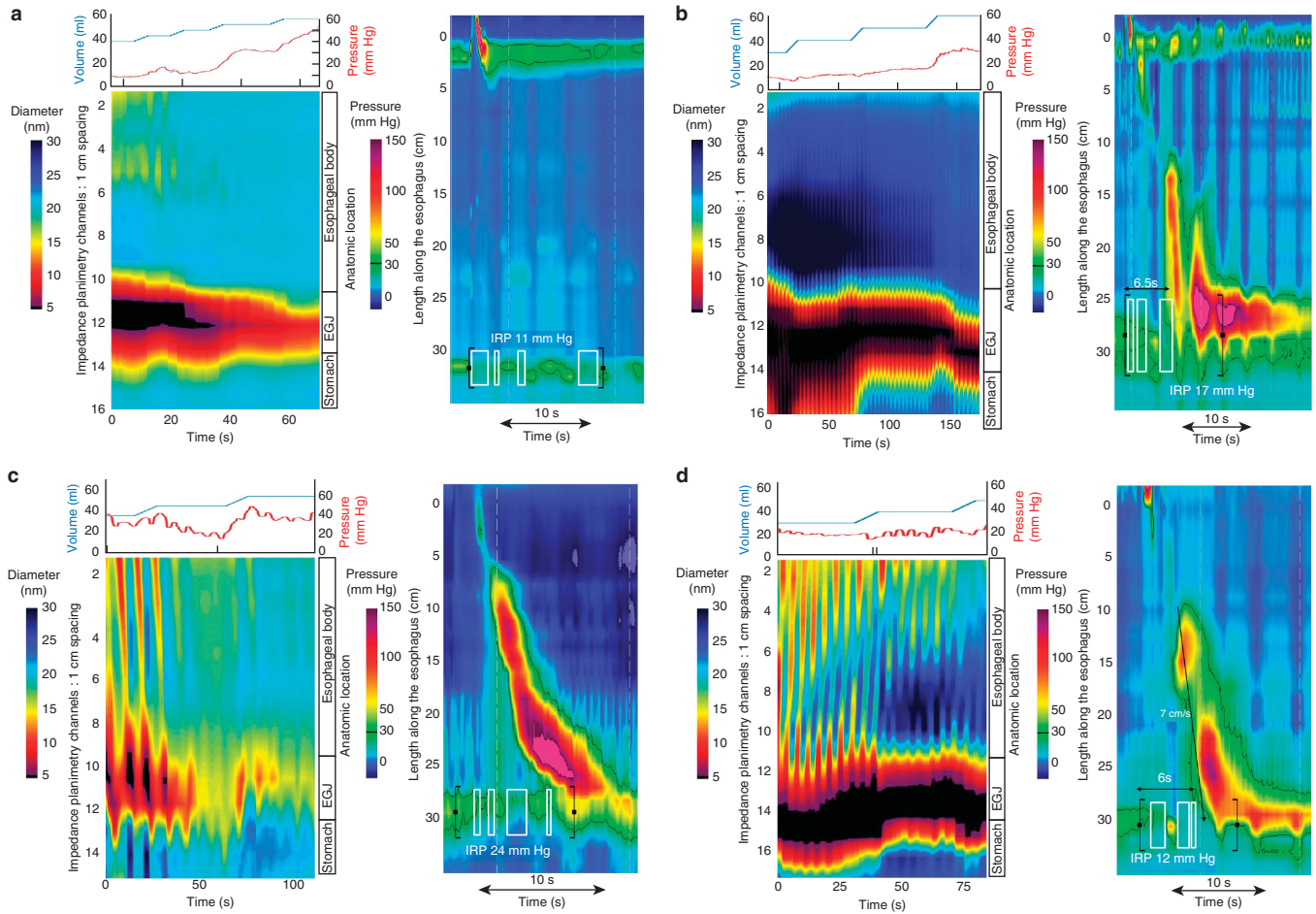


Figure 5. Case examples of functional lumen imaging probe (FLIP) topography. Left panels represent portions of the FLIP study: distension volume (top, blue line), and intra-balloon pressure (top, red line), and FLIP topography (bottom). A swallow from the corresponding high-resolution manometry (HRM) is included in the right panels. **(a)** A patient with type I achalasia, but borderline integrated relaxation pressure (IRP; median 12 mmHg). FLIP topography demonstrated an abnormal EGJ-DI of 1.6 mm²/mmHg and absent contractility. **(b)** A patient with EGJ outflow obstruction (EGJOO), and suspected evolving achalasia, on HRM. FLIP topography demonstrated abnormal EGJ-DI and absent contractility, supporting the diagnosis of achalasia. The patient was treated with a botulinum toxin injection to the lower esophageal sphincter that resulted in improvement in dysphagia. **(c)** A patient with EGJOO on HRM. FLIP topography was essentially normal with a normal EGJ-DI (4.9 mm²/mmHg) and RACs. An esophagram showed normal clearance of barium. Dysphagia had resolved without intervention at 6-month follow-up. **(d)** A patient with normal motility on HRM (median IRP 13 mmHg), but with an abnormal EGJ-DI (0.46 mm²/mmHg) and RRCs on FLIP topography. Esophagram demonstrated persistent esophageal barium column height of 4.4-cm after 5 min and impaction of a 12.5-mm barium tablet at the EGJ. The patient underwent endoscopic ultrasound with diffusely thickened distal esophageal muscle layers supporting diagnosis of a primary esophageal motor disorder. A per-oral endoscopic myotomy was recommended.

However, future study to refine and validate the measurement of EGJ-distensibility in patients without achalasia is needed.

Given the reported association of esophageal motility disorders (particularly type III achalasia) with chronic opiate use, the reliability of motility evaluation during sedated endoscopy may also be questioned (18–20). Although rapid-acting opiates and benzodiazepines may cause transient changes in esophageal motility parameters (with some inconsistencies, previous studies reported opiates generally increased EGJ pressures and benzodiazepines generally reduced or did not affect EGJ pressures), short-term opiate use is unlikely to alter the neural networks that are hypothesized to account for the association of esophageal motility disorders with chronic opiate use (19,21–25). In addition, our analysis paradigm

is based on control subjects also evaluated during endoscopy with conscious sedation and we did not observe differences in dosage or utilization of sedating agents across FLIP topography findings (Table 2). Regardless of the use during sedation, FLIP topography motility classifications ultimately appeared to accurately characterize patients. Esophageal motility evaluation during sedated endoscopy was also reported using other methods including visual inspection of lower esophageal sphincter characteristics and esophageal contractility, and through-the-scope manometry catheters (26,27). However, the subjective nature of endoscopic-visual inspection and the reliance on cooperation of a sedated patient to swallow on command are limitations. Thus the clinical application of these techniques was not broadly adopted. Endoscopic motility

evaluation using the FLIP, on the other hand, evaluates distension-induced esophageal contractility and provides objective measurement of esophageal function. Thus, reliance on patient cooperation is minimized and an additional component of esophageal function that is not well-evaluated with standard methods is assessed: the esophageal response to distension.

A limitation of our study is the paucity of major disorders of peristalsis other than achalasia (e.g., jackhammer and distal esophageal spasm). To some degree, this reflects the overall rarity of these disorders. This may particularly affect the reliance on RRCs as an abnormal finding in the proposed FLIP topography paradigm. On the basis of the frequent observation of RRCs in type III achalasia patients and the absence of RRCs in the cohort of ten asymptomatic controls, RRCs were hypothesized as a potential manifestation of dysfunctional esophageal inhibitory innervation (i.e., spastic contractions) (11). However, it remains possible that RRCs may represent a manifestation of the secondary peristaltic response to esophageal outflow obstruction; alternatively, RRCs in isolation (i.e., without co-existing esophageal outflow obstruction) may not reflect a pathologic finding. In the present study, all three jackhammer patients (and two additional patients classified as “normal motility,” but with hypercontractility not meeting criteria for jackhammer on HRM), had an abnormal EGJ-DI despite normal IRP, which may support the hypothesis that hypercontractile esophagus is related to an EGJOO (28). Alternatively, as all five of these patients demonstrated RRCs, the potential remains that hypercontractility (and retrograde contractions as a response to distension) are related to an imbalance of inhibitory and excitatory neural regulation (29,30). Future studies evaluating a greater number of asymptomatic controls and patients with HRM-defined spastic motor disorders, as well as patients with mechanical esophageal obstruction, will clarify the clinical significance of RRCs and aid refinement of the FLIP topography motility classification.

Generalizability of our findings to broad clinical practice is also presently limited by the need for the FLIP system and more so, the requisite customized MATLAB program to generate the topographic plots. Thus, greater distribution and experience with FLIP and development of commercially-available analytic software will aid future evaluation of the broader application of FLIP topography.

In conclusion, although further study and refinement of diagnostic parameters are needed, esophageal motility evaluation during endoscopy with FLIP topography is an appealing concept for patient-centered care. Incorporation of FLIP topography into clinical practice could reduce the need for esophageal manometry (a test associated with patient discomfort) and also be more convenient for patients (i.e., negate the need for a return visit to complete manometry). In addition, although HRM is often considered the gold standard for esophageal motility diagnoses, HRM may be non-diagnostic in non-obstructive dysphagia and sometimes, esophageal motility diagnoses can still be missed (such as in **Figure 5d**). Thus, supplementary diagnostic information may be obtained from cases with discordant FLIP and HRM motility diagnoses. Ultimately, FLIP topography has the potential to

become a valuable tool in the diagnostic evaluation of non-obstructive dysphagia.

CONFLICT OF INTEREST

Guarantor of the article: Dustin A. Carlson, MD, MS.

Specific author contributions: Study concept and design, data analysis, data interpretation, drafting of the manuscript, and approval of the final version: Dustin A. Carlson; data acquisition, revising the manuscript critically, and approval of the final version: Peter J. Kahrilas; data analysis and approval of the final version: Zhiyue Lin; recruitment of patients, data acquisition, and approval of the final version: Ikuo Hirano, Nirmala Gonsalves, Zoe Listernick, Katherine Ritter, and Michael Tye; data analysis and approval of the final version: Fraukje A. Ponds and Ian Wong; study concept and design, revising the manuscript critically, and approval of the final version: John E. Pandolfino.

Financial support: This work was supported by T32 DK101363 (to J.E.P.) and R01 DK079902 (to J.E.P.) from the Public Health service.

Potential competing interests: J.E.P.: Given Imaging (consultant, grant, speaking), Sandhill Scientific (consulting, speaking), Takeda (speaking), Astra Zeneca (speaking). I.H.: Receptos, Inc. (consulting); Regeneron Pharmaceutical, Inc. (consulting), Shire (consulting). N.G.: Nutricia (speaking). The remaining authors declare no potential competing interests.

Study Highlights

WHAT IS CURRENT KNOWLEDGE

- ✓ Esophageal manometry is indicated for evaluation of non-obstructive dysphagia, though manometry catheter placement is associated with patient discomfort.
- ✓ The functional lumen imaging probe (FLIP) study can be performed during sedated endoscopy to measure the esophageal response to distension.

WHAT IS NEW HERE

- ✓ Esophageal motility can be classified using the FLIP by assessing (i) esophagogastric junction distensibility and (ii) distension-induced contractility by using a novel, analytic paradigm: FLIP topography.
- ✓ FLIP topography identified abnormalities in esophageal motility in the vast majority (95%) of patients with abnormal motility on high-resolution manometry, including 100% of achalasia patients.
- ✓ FLIP topography may enhance the diagnostic evaluation of non-obstructive dysphagia by clarifying equivocal manometric diagnoses and identifying abnormalities not appreciated on manometry.

REFERENCES

1. Xiao Y, Kahrilas PJ, Nicodeme F *et al.* Lack of correlation between HRM metrics and symptoms during the manometric protocol. *Am J Gastroenterol* 2014;109:521–6.
2. Rohof WO, Hirsch DP, Kessing BF *et al.* Efficacy of treatment for patients with achalasia depends on the distensibility of the esophagogastric junction. *Gastroenterology* 2012;143:328–35.

3. Pandolfino JE, de Ruigh A, Nicodeme F *et al*. Distensibility of the esophagogastric junction assessed with the functional lumen imaging probe (FLIP) in achalasia patients. *Neurogastroenterol Motil* 2013;25:496–501.
4. Smeets FG, Masclee AA, Keszhelyi D *et al*. Esophagogastric junction distensibility in the management of achalasia patients: relation to treatment outcome. *Neurogastroenterol Motil* 2015;27:1495–503.
5. Orvar KB, Gregersen H, Christensen J. Biomechanical characteristics of the human esophagus. *Dig Dis Sci* 1993;38:197–205.
6. Mujica VR, Mudipalli RS, Rao SS. Pathophysiology of chest pain in patients with nutcracker esophagus. *Am J Gastroenterol* 2001;96:1371–7.
7. Kwiatek MA, Hirano I, Kahrilas PJ *et al*. Mechanical properties of the esophagus in eosinophilic esophagitis. *Gastroenterology* 2011;140:82–90.
8. Nicodeme F, Hirano I, Chen J *et al*. Esophageal distensibility as a measure of disease severity in patients with eosinophilic esophagitis. *Clin Gastroenterol Hepatol* 2013;11:1101–7.e1.
9. Lin Z, Kahrilas PJ, Xiao Y *et al*. Functional luminal imaging probe topography: an improved method for characterizing esophageal distensibility in eosinophilic esophagitis. *Therap Adv Gastroenterol* 2013;6:97–107.
10. Carlson DA, Lin Z, Rogers MC *et al*. Utilizing functional lumen imaging probe topography to evaluate esophageal contractility during volumetric distention: a pilot study. *Neurogastroenterol Motil* 2015;27:981–9.
11. Carlson DA, Lin Z, Kahrilas PJ *et al*. The functional lumen imaging probe detects esophageal contractility not observed with manometry in patients with achalasia. *Gastroenterology* 2015;149:1742–51.
12. Pandolfino JE, Ghosh SK, Rice J *et al*. Classifying esophageal motility by pressure topography characteristics: a study of 400 patients and 75 controls. *Am J Gastroenterol* 2008;103:27–37.
13. Kahrilas PJ, Bredenoord AJ, Fox M *et al*. The Chicago Classification of esophageal motility disorders, v3.0. *Neurogastroenterol Motil* 2015;27:160–74.
14. Lin Z, Nicodeme F, Boris L *et al*. Regional variation in distal esophagus distensibility assessed using the functional luminal imaging probe (FLIP). *Neurogastroenterol Motil* 2013;25:e765–71.
15. Scherer JR, Kwiatek MA, Soper NJ *et al*. Functional esophagogastric junction obstruction with intact peristalsis: a heterogeneous syndrome sometimes akin to achalasia. *J Gastrointest Surg* 2009;13:2219–25.
16. van Hoeij FB, Smout AJ, Bredenoord AJ. Characterization of idiopathic esophagogastric junction outflow obstruction. *Neurogastroenterol Motil* 2015;27:1310–6.
17. Perez-Fernandez MT, Santander C, Marinero A *et al*. Characterization and follow-up of esophagogastric junction outflow obstruction detected by high resolution manometry. *Neurogastroenterol Motil* 2016;28:116–26.
18. Kraichely RE, Arora AS, Murray JA. Opiate-induced oesophageal dysmotility. *Aliment Pharmacol Ther* 2010;31:601–6.
19. Ratuapli SK, Crowell MD, DiBaise JK *et al*. Opioid-induced esophageal dysfunction (OIED) in patients on chronic opioids. *Am J Gastroenterol* 2015;110:979–84.
20. Ravi K, Murray JA, Geno DM *et al*. Achalasia and chronic opiate use: innocent bystanders or associated conditions? *Dis Esophagus* 2016;29:15–21.
21. Mittal RK, Frank EB, Lange RC *et al*. Effects of morphine and naloxone on esophageal motility and gastric emptying in man. *Dig Dis Sci* 1986;31:936–42.
22. Penagini R, Picone A, Bianchi PA. Effect of morphine and naloxone on motor response of the human esophagus to swallowing and distension. *Am J Physiol* 1996;271:G675–80.
23. Hall AW, Moossa AR, Clark J *et al*. The effects of premedication drugs on the lower oesophageal high pressure zone and reflux status of rhesus monkeys and man. *Gut* 1975;16:347–52.
24. Rushnak MJ, Leevy CM. Effect of diazepam on the lower esophageal sphincter. A double-blind controlled study. *Am J Gastroenterol* 1980;73:127–30.
25. Marsh JK, Hoffman SM, Dmuchowski CF. Effect of intravenous midazolam on esophageal motility testing in normal human volunteers. *Am J Gastroenterol* 1993;88:860–3.
26. Cameron AJ, Malcolm A, Prather CM *et al*. Videoendoscopic diagnosis of esophageal motility disorders. *Gastrointest Endosc* 1999;49:62–9.
27. Kwo PY, Cameron AJ, Phillips SF. Endoscopic esophageal manometry. *Am J Gastroenterol* 1995;90:1985–8.
28. Burton PR, Brown W, Laurie C *et al*. The effect of laparoscopic adjustable gastric bands on esophageal motility and the gastroesophageal junction: analysis using high-resolution video manometry. *Obes Surg* 2009;19:905–14.
29. Jung HY, Puckett JL, Bhalla V *et al*. Asynchrony between the circular and the longitudinal muscle contraction in patients with nutcracker esophagus. *Gastroenterology* 2005;128:1179–86.
30. Kim HS, Park H, Lim JH *et al*. Morphometric evaluation of oesophageal wall in patients with nutcracker oesophagus and ineffective oesophageal motility. *Neurogastroenterol Motil* 2008;20:869–76.



This work is licensed under a Creative Commons Attribution-NonCommercial-NoDerivs 4.0 International License. The images or other third party material in this article are included in the article's Creative Commons license, unless indicated otherwise in the credit line; if the material is not included under the Creative Commons license, users will need to obtain permission from the license holder to reproduce the material. To view a copy of this license, visit <http://creativecommons.org/licenses/by-nc-nd/4.0/>