

# Increased epidermal thickness and abnormal epidermal differentiation in keloid scars

G.C. Limandjaja,<sup>1</sup> L.J. van den Broek,<sup>1</sup> T. Waaijman,<sup>1</sup> H.A. van Veen,<sup>2</sup> V. Everts,<sup>2,3</sup> S. Monstrey,<sup>4</sup> R.J. Scheper,<sup>5</sup> F.B. Niessen<sup>6</sup> and S. Gibbs<sup>1,3</sup>

<sup>1</sup>Department of Dermatology, <sup>5</sup>Department of Pathology and <sup>6</sup>Department of Plastic, Reconstructive and Hand Surgery, VU Medical Centre, Amsterdam, the Netherlands

<sup>2</sup>Van Leeuwenhoek Centre for Advanced Microscopy, Amsterdam Medical Centre, Amsterdam, the Netherlands

<sup>3</sup>Department of Oral Cell Biology, Academic Center for Dentistry Amsterdam, University of Amsterdam and VU University, Amsterdam, the Netherlands

<sup>4</sup>Department of Plastic Surgery, University of Ghent, Ghent, Belgium

## Summary

### Correspondence

Susan Gibbs.

E-mail: s.gibbs@vumc.nl

### Accepted for publication

12 June 2016

### Funding sources

This study was financed by a grant given to A-Skin BV, VU Medical Centre and the University of Ghent from the Dutch Government: Rijksdienst voor Ondernemend Nederland, project number INT102010.

### Conflicts of interest

S.G. (scientific officer) and R.J.S. (chief executive officer) are cofounders of the university spin-off company (SME) A-Skin BV, Amsterdam, the Netherlands.

DOI 10.1111/bjd.14844

**Background** The pathogenesis underlying keloid formation is still poorly understood. Research has focused mostly on dermal abnormalities, while the epidermis has not yet been studied.

**Objectives** To identify differences within the epidermis of mature keloid scars compared with normal skin and mature normotrophic and hypertrophic scars.

**Methods** Rete ridge formation and epidermal thickness were evaluated in tissue sections. Epidermal proliferation was assessed using immunohistochemistry (Ki67, keratins 6, 16 and 17) and with an *in vitro* proliferation assay. Epidermal differentiation was evaluated using immunohistochemistry (keratin 10, involucrin, loricrin, filaggrin, SPRR2, SKALP), reverse-transcriptase polymerase chain reaction (involucrin) and transmission electron microscopy (stratum corneum).

**Results** All scars showed flattening of the epidermis. A trend of increasing epidermal thickness correlating to increasing scar abnormality was observed when comparing normal skin, normotrophic scars, hypertrophic scars and keloids. No difference in epidermal proliferation was observed. Only the early differentiation marker involucrin showed abnormal expression in scars. Involucrin was restricted to the granular layer in healthy skin, but showed panepidermal expression in keloids. Normotrophic scars expressed involucrin in the granular and upper spinous layers, while hypertrophic scars resembled normotrophic scars or keloids. Abnormal differentiation was associated with ultrastructural disorganization of the stratum corneum in keloids compared with normal skin.

**Conclusions** Keloids showed increased epidermal thickness compared with normal skin and normotrophic and hypertrophic scars. This was not due to hyperproliferation, but possibly caused by abnormal early terminal differentiation, which affects stratum corneum formation. Our findings indicate that the epidermis is associated with keloid pathogenesis and identify involucrin as a potential diagnostic marker for abnormal scarring.

### What's already known about this topic?

- With regards to keloid scarring, the focus has always been on the dermal compartment when studying the underlying pathogenesis.
- However, we know that epidermal–dermal interactions are essential in wound healing and, as such, the epidermis of keloid scars is worth further investigation.
- While epidermal abnormalities have already been described in hypertrophic scars, the literature on the keloid epidermis remains inconclusive.

**What does this study add?**

- We show that keloids have increased epidermal thickness compared with normal skin and normotrophic and hypertrophic scars.
- This was not due to hyperproliferation, but possibly caused by abnormal early terminal differentiation, which affects stratum corneum formation.

**What is the translational message?**

- Our findings indicate that the epidermis is associated with keloid pathogenesis and identify involucrin as a potential diagnostic marker for abnormal scarring.

The keloid epidermis is often described as appearing histologically normal,<sup>1,2</sup> and as a result it is frequently overlooked. However, several lines of evidence suggest that keloid-derived keratinocytes might not be mere bystanders in the process of abnormal scar formation. In normal wound healing, fibroblast behaviour is known to be influenced by keratinocytes, and the interactions between these two cell types contribute essential signals for normal scar formation via the secretion of soluble mediators.<sup>3–9</sup> Therefore it is possible that keratinocytes also participate in abnormal wound healing processes leading to the formation of keloid scars.

In fact, epidermal abnormalities have already been described in another type of abnormal scarring.<sup>3,10,11</sup> Young hypertrophic scars showed increased proliferation, increased epidermal thickness and increased expression of the keratinocyte hyperproliferation and activation markers keratins 6, 16 and 17. Upon further maturation, this hyperactivated phenotype diminished and could eventually no longer be detected, but these early epidermal abnormalities do suggest that the epidermal compartment is involved in the pathogenesis of this abnormal scar.<sup>3,10,11</sup> However, while both hypertrophic scars and keloids fall into the abnormal scarring spectrum, they are not necessarily one and the same. Several important differences exist between the two, but most importantly keloids are distinguished clinically from hypertrophic scars by their invasive and often relentless growth into the surrounding healthy tissue.<sup>12</sup> For this reason, it is important to maintain this distinction in research, as findings relating to hypertrophic scars should not be automatically extrapolated to keloids.

While such immunohistochemical abnormalities of the epidermis have not previously been demonstrated for keloid scars, abnormalities in keloid-derived keratinocytes cultured *in vitro* have been reported.<sup>13–20</sup> Keloid keratinocytes show intrinsic abnormalities, such as increased transforming growth factor- $\beta$ 2 expression<sup>2</sup> and altered gene expression,<sup>20</sup> and are capable of interacting with keloid-derived fibroblasts to stimulate keloid scar formation.<sup>2,8,19</sup> Furthermore, keloid keratinocytes have been shown to induce a keloid scar phenotype (e.g. increased collagen production) in fibroblasts derived from unaffected normal skin as well.<sup>14–16</sup> Taken together, these results strongly suggest that the keloid epidermis might

in fact not be as 'normal' as previously assumed, and could thus play an important role in keloid scar formation.

This study aimed to investigate the epidermal characteristics of mature keloid scars compared with normal skin and other mature scars (normotrophic and hypertrophic), and in turn help to identify novel biomarkers for keloid scarring. The possibility of heterogeneity within a keloid scar was also considered in our study design, as clinical observations suggest a possible distinction between the periphery and the centre of keloid scars. The periphery is often thought to be responsible for the active invasive growth into the surrounding normal skin, as opposed to the less elevated central area, which shows signs of clinical regression over time.<sup>1,12,21</sup> For this reason, keloid scars were divided into peripheral and central regions prior to comparison with normal skin and normotrophic and hypertrophic scars with respect to epidermal morphology, proliferation and differentiation.

**Materials and methods**

Tissue biopsies of normal skin, normotrophic scars, hypertrophic scars and keloid scars were obtained from the plastic surgery departments of the VU Medical Centre and the St Antonius Hospital (normal skin only). This was in compliance with the Dutch 'Code for Proper Secondary Use of Human Tissue' in accordance with the Declaration of Helsinki. Scars were selected for inclusion by an experienced scar expert (plastic surgeon; author F.B.N.) and were included only if patients had given consent for their coded use in research. All scars were at least 1 year old to ensure the inclusion of mature scars. Normal skin was included only if patients had not elected to opt out after receiving written information about the anonymous secondary use of their material. Table 1 lists the donor characteristics and Tables S1–S4 (see Supporting Information) give detailed donor characteristics per experiment.

For (immuno)histochemical analysis, keloids were further subdivided into peripheral and central regions. Peripheral keloid scar was defined as the outer margin of the keloid growth bordering on surrounding healthy skin, and central keloid scar was defined as the central region within the keloid. When paraffin embedding the tissue for further analysis, care was taken that the plane of the tissue section was always

Table 1 Summary of characteristics of the donors and associated tissue samples for each of the experiments

Donors	Tissue type	Location	Age (years)	Previous treatment	Aetiology	Skin colour
Immunohistochemistry						
5	Normal skin	Breast, abdomen, thigh	Unknown	Not applicable	Not applicable	Unknown
10	Normal scar	Face, breast, sternum	15–60	Usually none	Unknown	White, unknown
10	Hypertrophic scar	Abdomen, flank, breast, sternum	15–54	Usually none	Unknown	White, dark brown, unknown
10	Keloid scar: periphery and centre	Ear, sternum, pubic region	13–40	Excision, silicone sheets, corticosteroid injections, laser therapy, radiotherapy, cryotherapy (1 donor), unknown	Surgery, insect bite, piercing, trauma (blunt and sharp), unknown	White, brown, dark brown, unknown
Keratinocyte proliferation assay						
5	Normal skin	Breast	18–53	Not applicable	Not applicable	White, brown
5	Normal scar	Abdomen, neck, back	18–54	None, unknown (1 donor)	Surgery, unknown	White
3	Hypertrophic scar	Abdomen, breast, upper extremity	24–40	Excision, corticosteroid injections, none	Surgery	White
6	Keloid scar	Abdomen, ear, breast, neck, shoulder, chest	18–49	Excision, corticosteroid injections, none	Surgery, acne, unknown	White, brown, dark brown
Involucrin reverse-transcriptase polymerase chain reaction						
10	Normal skin	Abdomen, breast, lower extremity	34–48	Not applicable	Not applicable	White, brown, unknown
10	Normal scar	Abdomen, neck, back, flank, lower extremity	24–60	None	Surgery, dog bite, wound dehiscence, unknown	White, brown
4	Hypertrophic scar	Breast, lip, unknown	24–42	Excision, corticosteroid injections, none	Surgery, trauma	White, brown
7	Keloid scar	Abdomen, occiput, face, thorax, ear, labia minora	32–49	Excision, corticosteroid injections, laser therapy, none	Surgery, wound, inflammation	Brown, dark brown
Transmission electron microscopy						
3	Normal skin	Abdomen, breast	29–48	Not applicable	Not applicable	White, brown
3	Keloid scar	Abdomen, breast	40–54	Excision, corticosteroid injections	Acne, unknown	Brown, dark brown

There was an equal distribution of both sexes (except for normal scars used for immunohistochemistry experiments: mostly female; and the keratinocyte proliferation assays and transmission electron microscopy experiments: mostly female), and scars were  $\geq 1$  year old.

perpendicular to the plane of dissection, after subdivision into peripheral and central regions.

### Histological analysis

Haematoxylin and eosin-stained 5- $\mu$ m paraffin-embedded tissue sections were used to assess rete ridge formation and epidermal thickness. For rete ridges, semiquantitative analysis was performed to determine their presence in all tissue samples by evaluating the depth of ridges (scored as 0, absent; 1, superficial; 2, average; 3, deep) and the frequency of occurrence across the entire longitudinal epidermal plane (scored as 1, 0–24%; 2, 25–49%; 3, 50–74%; 4, 75–100%) and combining both for a cumulative score. Epidermal thickness was quantified by counting the number of keratinocyte cell layers at six points in the tissue sections (magnification  $\times 200$ ; three measurements on random rete ridges and three on random nonrete ridges).

### Immunohistochemical staining

Immunohistochemical staining was performed on deparaffinized, formalin-fixed tissue sections to assess epidermal proliferation (Ki67), differentiation [keratin 10, involucrin, loricrin, filaggrin, small proline-rich region protein (SPRR)2 and skin-derived antileucoprotease (SKALP)] and activation/hyperproliferation (keratin 6, 16 and 17) as listed in Table 2. Immunohistochemical staining was scored as (–) absence of staining; (+) normal staining pattern; (++) increased number of positively stained cells; (+++) strongly increased number of positively stained cells. For the Ki67 proliferation index, 100 basal cells were counted in three random locations in a tissue section (magnification  $\times 100$ ), after which the number of positive cells along this length of the epidermis was determined. The proliferation index was defined as the average percentage of Ki67-positive nuclei.

Table 2 Immunohistochemical staining protocols

Target marker	Antibody source	Dilution of antibody	Supplementary treatments prior to antibody addition
Epidermal (hyper)proliferation			
Ki67	Mouse monoclonal, clone MIB-1 (DakoCytomation, Glostrup, Denmark)	1 : 50	A
Keratin 6	Murine monoclonal, clone Ks6.KA12 (Monosan, Uden, the Netherlands)	1 : 150	A
Keratin 16	Murine monoclonal, clone LL025 (Monosan)	1 : 20	A
Keratin 17	Murine monoclonal, clone Ks17.E3 (Monosan)	1 : 40	A
Epidermal differentiation			
Keratin 10	Murine monoclonal, clone DE-K10 (Progen, Heidelberg, Germany)	1 : 500	A + B
Involucrin	Mouse monoclonal, clone SY5 (Novocastra, Newcastle, U.K.)	1 : 1000	C
Loricrin	Rabbit polyclonal, clone AF62 (Covance, Emeryville CA, U.S.A.)	1 : 500	C + D
Filaggrin	Rabbit polyclonal, catalogue no. PRB-417P-100 (Covance)	1 : 500	A
SPRR	Rabbit polyclonal, catalogue no. LS-B630 (LifeSpan BioSciences, Seattle, WA, U.S.A.)	1 : 500	C + D
Elafin/SKALP	Mouse monoclonal, clone TRAB20 (Hycult Biotechnology, Canton, MA, U.S.A.)	1 : 400	B

SPRR, small proline-rich region protein 2; SKALP, skin-derived antileucoproteinase. Supplementary treatments prior to primary antibody incubation included A, heat-induced antigen retrieval with 0.01-mol L<sup>-1</sup> citrate buffer pH 6.0; B, 15-min incubation with pepsin; C, blocking of endogenous peroxidase by 20-min incubation in a 0.3% H<sub>2</sub>O<sub>2</sub> in methanol solution; and D, 15-min preincubation with goat serum.

### Keratinocyte culture and proliferation experiments

Tissue was dissected into smaller squares and incubated in dispase II solution (Roche Diagnostics GmbH, Mannheim, Germany) overnight at 4 °C. Keratinocytes were isolated and cultured as described previously.<sup>22</sup> Keratinocytes were then seeded at 3 × 10<sup>6</sup> cells on 0.5-µg cm<sup>-2</sup> collagen IV-coated 9-cm dishes and cultured in keratinocyte culture medium comprising Dulbecco's Modified Eagle Medium (Lonza, Verriers, Belgium) and F12-HAM nutrient mixture plus L-glutamine (HAMF12; Gibco, Grand Island, NY, U.S.A.) in a 3 : 1 ratio, with 1% UltrosorG (BioSeptra, Cergy-St-Christophe, France), 1% PenStrep (Gibco), 2-ng mL<sup>-1</sup> human keratinocyte growth factor, 0.09-µmol L<sup>-1</sup> insulin, 1-µmol L<sup>-1</sup> hydrocortisone and 1-µmol L<sup>-1</sup> (-)-isoproterenol hydrochloride. The medium was changed twice a week.

Cells were passaged at approximately 80% confluence. Passage 0 keratinocytes were trypsinized with 0.05% trypsin (Gibco), counted using the Adam AccuChip 4× Kit with an automatic cell counter (Digital Bio; NanoEnTek Inc., Seoul, Korea) and plated at 1.5 × 10<sup>6</sup> keratinocytes per 9-cm-diameter Petri dish on day 0. Medium was changed once on day 2, and cells were trypsinized and counted again on day 5 to determine proliferation of passage 1 keratinocytes. The readout was the fold increase in cell number over 5 days, which was calculated as the number of keratinocytes on day 5 divided by 1.5 × 10<sup>6</sup>. All culture components were obtained from Sigma-Aldrich (St Louis, MO, U.S.A.) unless stated otherwise.

### Involucrin mRNA expression in scars

Biopsies (3–6-mm diameter) were taken from normal skin, normotrophic scars, hypertrophic scars and keloid scars (three donors per tissue type). Excess dermal tissue was removed

from the biopsies before snap freezing and subsequent storage at -80 °C. Samples were disrupted and homogenized in TissueLyser II (Qiagen GmbH, Hilden, Germany), then snap frozen again and stored at -80 °C. RNA isolation was performed using QiaShredder kits and RNeasy<sup>®</sup> Mini Kits with on-column DNase digestion (Qiagen) according to the manufacturer's protocols, and stored at -80 °C. The Nanodrop spectrophotometer (Nanodrop Technologies Inc., Wilmington, DE, U.S.A.) was used to measure total RNA concentration. Real-time polymerase chain reaction (PCR) reactions were performed essentially as described previously<sup>23</sup>: 2 µL of cDNA was amplified in a 25 µL total volume containing 9.5 µL RNase-free H<sub>2</sub>O, 12.5 µL SYBRGreen iQ<sup>™</sup> SYBR<sup>®</sup> Green Supermix (Bio-Rad Laboratories, Hercules, CA, U.S.A.) and 1 µL of a quantitative PCR primer pair for involucrin (HP208665) or the housekeeping genes HPRT1 (HP200179) and GAPDH (HP205798; all OriGene, Rockville, MD, U.S.A.). Involucrin expression (2<sup>-ΔCt</sup>) was normalized with the geometric mean of both housekeeping genes.

### Transmission electron microscopy

Biopsies (3-mm diameter) of normal skin and keloid scars were washed in phosphate-buffered saline before immersion in a fixative consisting of 4% paraformaldehyde and 1% glutaraldehyde in a 0.1 mol L<sup>-1</sup> sodium cacodylate buffer (pH 7.4). After fixation, biopsies were washed in distilled water, osmicated for 60 min in 1% OsO<sub>4</sub> in water, and washed again in distilled water. Biopsies were block stained overnight in 1.5% aqueous uranyl acetate (for contrast enhancement), dehydrated through a series of ethanol, and then embedded in LX-112 (Ladd Research, Williston, VT, U.S.A.). Ultrathin sections (80 nm) were cut with a diamond knife, collected on Formvar-coated grids, and stained with uranyl acetate and lead citrate. Sections were examined with an FEI Tecnai-12 G2

Spirit Bio twin electron microscope (Thermo Fisher Scientific Inc., Waltham, MA, U.S.A.).

### Statistical analysis

The results are presented as the mean  $\pm$  SEM, except for individual data plots with the median. Experiments were performed with at least three donors per tissue type. Experimental groups were compared with one another using a one-way ANOVA with *post hoc* Tukey's honest significant difference tests (epidermal proliferation index and keratinocyte proliferation index) or a Kruskal–Wallis test with *post hoc* Dunn's multiple comparisons tests (presence of rete ridges, epidermal thickness and involucrin expression), depending on the outcome of normality testing (Shapiro–Wilk test) of the residuals (errors). Differences were considered statistically significant at \* $P < 0.05$ , \*\* $P < 0.01$  or \*\*\* $P < 0.001$ . Statistical tests were performed using GraphPad Prism version 6 (GraphPad Software Inc., San Diego, CA, U.S.A.).

## Results

### Reduced rete ridge formation in scars and increased epidermal thickness in keloids

From haematoxylin and eosin-stained tissue sections it is clearly apparent that both abnormal scar types (hypertrophic scars and keloids) show a thicker and flattened epidermis than normal skin and normotrophic scars (Fig. 1); this was particularly obvious in keloids. Semiquantitative analysis showed that all scar types had decreased rete ridge formation compared with normal skin ( $P < 0.05$ ), with no difference between the scar types (Fig. 2a).

To quantify differences in epidermal thickness between scar types, the number of viable epidermal cell layers was determined. There was a clear trend of increasing epidermal thickness with increasing abnormality of the scar types when compared with normal skin (Fig. 2b). However, only keloid scars showed significantly increased epidermal thickness,

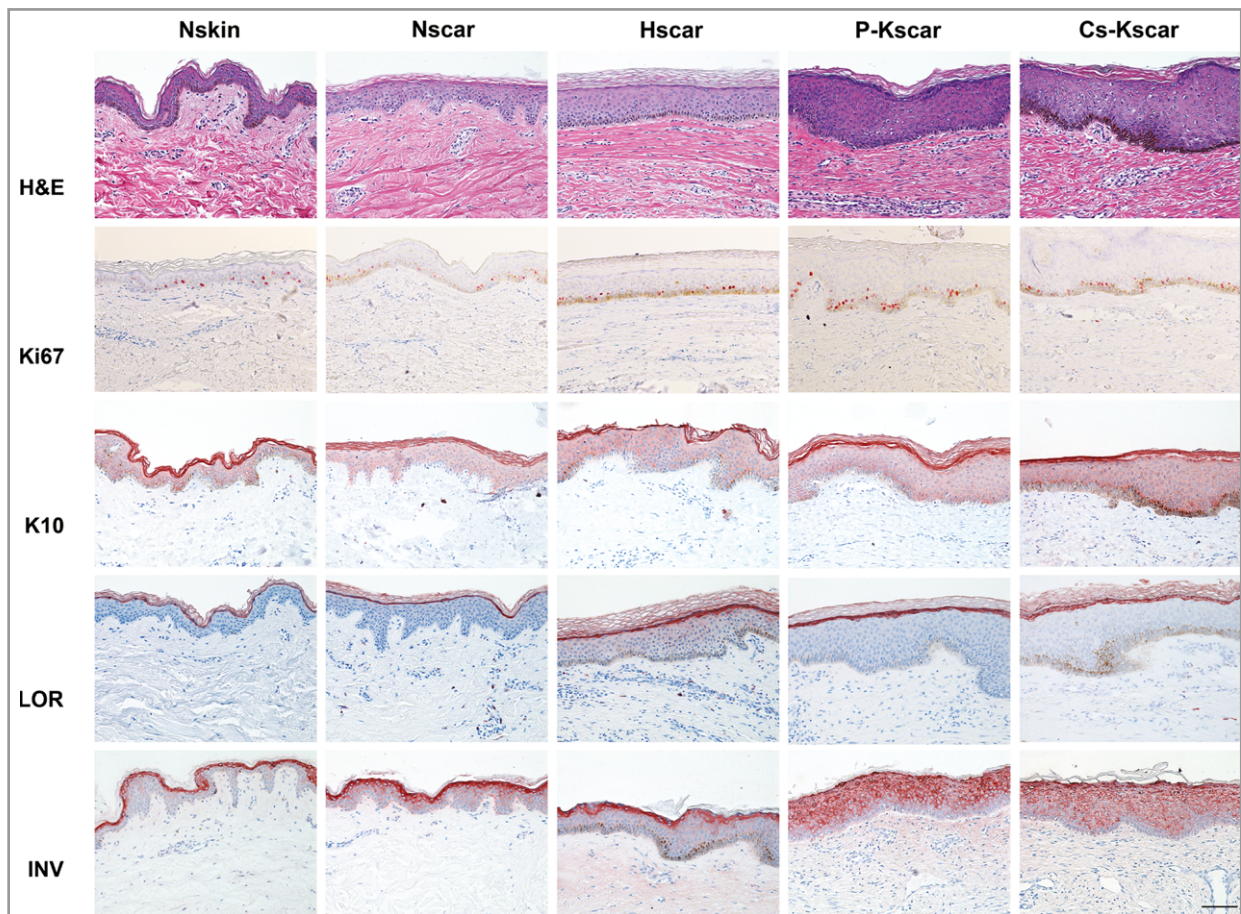


Fig 1. Increased involucrin expression in keloid scars. Representative (immuno)histochemical stainings for normal skin (Nskin,  $n = 5$ ), normotrophic scar (Nscar,  $n = 10$ ), hypertrophic scar (Hscar,  $n = 10$ ), keloid scar periphery (P-Kscar,  $n = 10$ ) and keloid scar central region (Cs-Kscar,  $n = 10$ ). Samples are not donor matched. Patient information can be found in Table 1 and Tables S1–S4. Histology (haematoxylin and eosin, H&E); proliferation (Ki67) and differentiation (keratin 10, K10; loricrin, LOR; involucrin, INV) marker localization are shown. Scale bar = 50  $\mu$ m.



Table 3 Summary results of immunohistochemical stainings

Marker	Function of marker	Nskin	Nscar	Hscar	P-Kscar	Cs-Kscar
Epidermal (hyper)proliferation						
Ki67	Nuclear protein expressed during active phases of cell cycle	16.8 ± 3.5	17.7 ± 6.8	14.8 ± 6.0	21.7 ± 11.8	22.7 ± 9.4
Keratin 6	Intermediate filament protein, expressed in hyperproliferation	–	–	– (9/10)	– (9/10)	– (8/10)
Keratin 16	Intermediate filament protein, expressed in hyperproliferation	–	–	– (8/10)	– (8/10)	– (9/10)
Keratin 17	Intermediate filament protein, expressed in hyperproliferation	–	– (9/10)	– (8/10)	– (8/10)	– (9/10)
Epidermal differentiation						
Keratin 10	Intermediate filament protein expressed in keratinizing cells	SPB	SPB	SPB	SPB	SPB
Involucrin	Scaffolding protein in cornified envelope, expressed by differentiating keratinocytes	+	++ (7/10); + (3/10)	+++ (4/10); ++ (3/10); + (3/10)	+++ (7/10); ++ (3/10)	+++ (9/10); ++ (1/10)
Loricrin	Major cornified envelope protein, expressed in granular keratinocytes	SG	SG	SG	SG	SG
Filaggrin	Aggregates keratin intermediate filaments in lower stratum corneum, expressed as profilaggrin in granular keratinocytes	SG	SG	SG	SG	SG
SPRR2	Cornified envelope protein expressed in granular keratinocytes	SG	SG	SG	SG	SG
SKALP	Cornified envelope protein, epithelial proteinase inhibitor acting as substrate for transglutaminases, expressed in inflammation (absent from normal skin)	–	–	–	– (9/10)	– (8/10)

Summary of the immunohistochemical results for localization of keratinocyte differentiation, proliferation and activation markers in normal skin (Nskin), normotrophic scar (Nscar), hypertrophic scar (Hscar), periphery of keloid scar (P-Kscar) and superficial centre of keloid scar (Cs-Kscar). Ki67 is expressed as the mean ± SEM. Numbers in brackets (x/y) denote the number of 'x' donors showing the indicated score, out of the total number of 'y' donors included. For keratins 6, 16 and 17, the remaining donors showed weak intermittent staining. SPB, suprabasal expression; SG, stratum granulosum expression; NA, not applicable; +, normal expression; ++, increased expression; +++, strongly increased expression; –, absent. SPRR2, small proline-rich region protein 2; SKALP, skin-derived antileucoproteinase.

pattern that was intermediate between normal scars and keloid scars, with six of 10 scars showing similar expression to normal scars and four of 10 scars showing increased involucrin expression similar to that of keloid scars.

This increased involucrin expression in keloid keratinocytes was further confirmed with reverse-transcriptase PCR on RNA isolated from the epidermis of fresh tissue biopsies (Fig. 2e). As increased expression of involucrin was always present in at least one of the two regions, the entire keloid scar was used. In line with our immunohistochemical results, involucrin mRNA expression was significantly increased in the epidermis of keloid scars compared with normal skin. This suggests that increased epidermal thickness is related to abnormal differentiation, as observed by increased expression of the terminal differentiation marker involucrin, rather than increased proliferation.

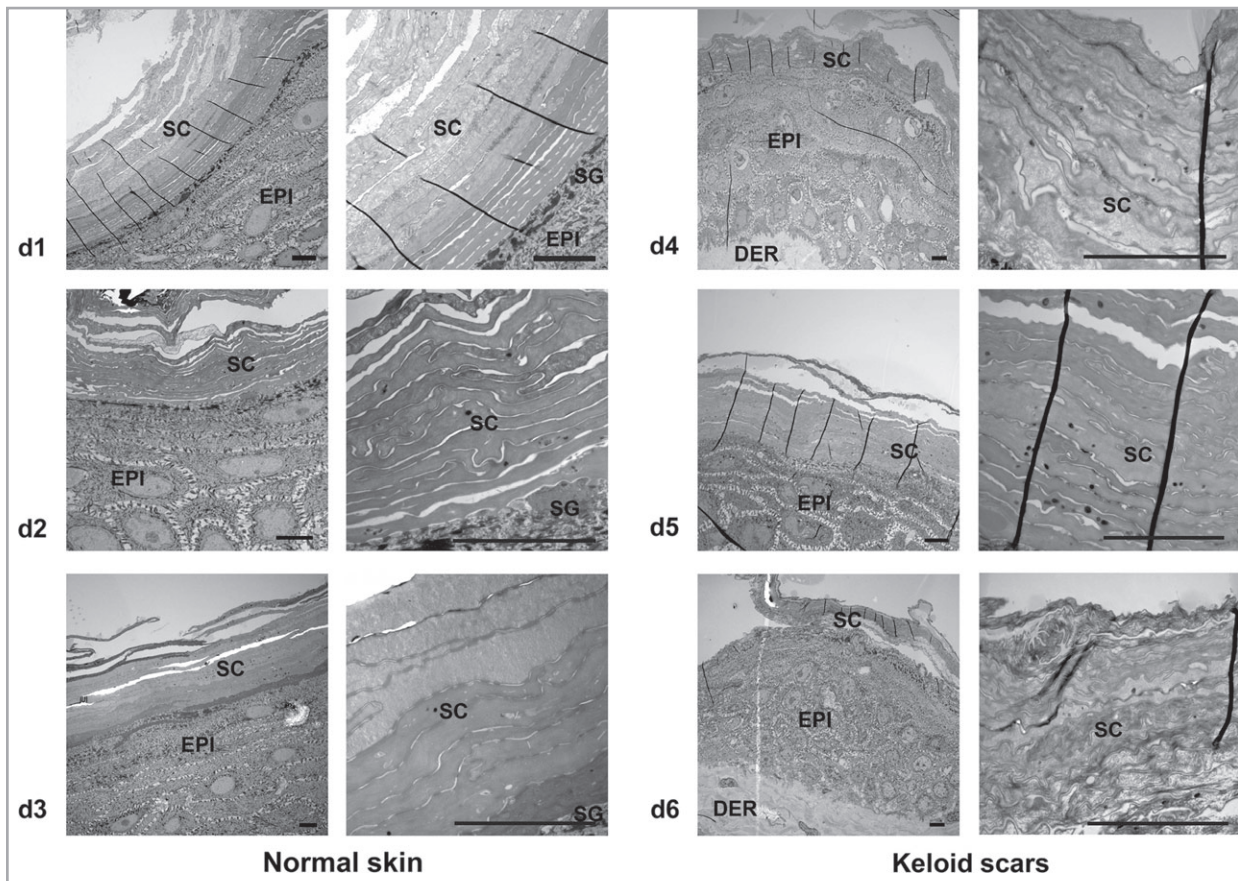
### Disorganization of the stratum corneum in keloid scars

Transmission electron microscopy was used to evaluate the morphology of the stratum corneum, the end stage of

epidermal differentiation. Only the two most extreme phenotypes were selected for this purpose – normal skin and keloid scars – both from the torso region. In healthy skin, the stratum corneum showed deposition of several strata of approximately equal thickness in parallel alignment, with a clear distinction between the stratum corneum and underlying viable epidermal layers. However, the strata in keloid scars had irregular, disorganized, poorly aligned contours compared with normal skin, with a less pronounced interface between the stratum corneum and viable epidermal layers underneath (Fig. 3). These findings are consistent with the previously described abnormal expression of the cornified envelope (CE) precursor involucrin in keloid scars.

### Discussion

In this study we have confirmed that epidermal abnormalities are not limited to mature hypertrophic scars, but are also present in mature keloid scars. We found that keloid scars have greater epidermal thickness than normal skin and mature normotrophic scars. This was not the result of increased



**Fig 3.** General disorganization of stratum corneum in keloid scars. Transmission electron microscopy pictures of the stratum corneum in normal skin and keloid scars are shown, with increasing magnifications (from left to right, with each row depicting a different donor: d1–d6). Scale bar = 5  $\mu$ m. The dermis (DER), epidermis (EPI), stratum granulosum (SG) and stratum corneum (SC) are indicated in the figures. Tissue samples were not donor matched.

proliferation. However, it could be associated with abnormal early terminal differentiation (involucrin expression), which may in turn affect stratum corneum formation.

One of our first considerations for the experimental set-up of this study was the possible heterogeneity within keloid scars. Clinicians have long since described the presence of an actively growing periphery as opposed to a regressive central region. However, the opposite has also been suggested, with the central area within the keloid seen as the actively growing and expanding region.<sup>24,25</sup> In this study, we did not find any obvious differences between the peripheral and central regions of the keloid in the epidermal compartment. It would seem that increased epidermal thickness and early involucrin expression are features of keloid scars in their entirety, rather than specific qualities of a particular region within the keloids.

At the dermoepidermal interface we found that the depth and frequency of epidermal rete ridge formation was significantly reduced in all scar types compared with normal skin. Others have reported both the absence<sup>26–30</sup> and presence of rete ridges,<sup>30,31</sup> or even both<sup>3,11</sup> in abnormal scars. Using our method to assess rete ridge formation in a semiquantifiable manner, our results are in line with those of Ehrlich *et al.*,<sup>28</sup>

who also found that rete ridges are absent from normotrophic, hypertrophic and keloid scars. However, Moshref and Mufti<sup>32</sup> reported flattening of the epidermis in all hypertrophic scars, but in only one-third of keloids.

We found that a gradation in increasing epidermal thickness correlated with the degree of severity of the scar: epidermal-thickness keloid > hypertrophic scar > normotrophic scar > normal skin. In the literature, the keloid epidermis has been described as both appearing morphologically normal<sup>1,2,26,33</sup> and having increased thickness,<sup>14,34–38</sup> while some found a thicker epidermis in both abnormal scars,<sup>31,39,40</sup> and yet others considered a thicker epidermis to be an inconsistent finding.<sup>28,41</sup> However, to date we have not found a publication comparing and measuring the epidermal thickness of sufficiently matured scars ( $\geq 1$  year old) of the entire scar spectrum in a standardized, quantifiable manner. Hypertrophic scars also showed a trend towards increased epidermal thickness compared with normal skin and normotrophic scars, in line with Andriessen *et al.*<sup>3,42</sup> However, in our study only keloid scars were found to have significantly increased epidermal thickness compared with normotrophic scars in addition to normal skin.



Increased epidermal thickness was not associated with increased proliferation. This was concluded from our immunohistochemical stainings performed to assess activation and hyperproliferation markers (keratins 6, 16 and 17) and proliferation (Ki67). This is in contrast with reports from others citing the presence of epidermal hyperproliferation in keloids and/or hypertrophic scars.<sup>37,43,44</sup> However, with the exception of Ong *et al.*<sup>37</sup> it is unclear whether the scars included in these studies had sufficiently matured. Notably, in hypertrophic scars, early increased and abnormal Ki67 and keratin 16 expression also normalizes after 12 months.<sup>3</sup> We do not consider that early increased epidermal proliferation in young scars could be responsible for the observed epidermal thickening in our mature scars, as epidermal turnover takes place in approximately 4–6 weeks and our scars were older than 1 year. In addition, our immunohistochemical results are further corroborated by our *in vitro* keratinocyte proliferation assay, where indeed cultured keloid keratinocytes showed no difference in proliferation compared with keratinocytes derived from normal scars. Taken together these results indicate that mature abnormal scars do not show increased proliferation of the epidermis.

Having determined that increased epidermal thickness was not related to increased proliferation, we next determined whether abnormal differentiation could be involved. Interestingly, from a panel of epidermal differentiation markers, only involucrin showed abnormal expression. A significantly enhanced expression of this early terminal differentiation marker was observed in most keloid scars and approximately half of the hypertrophic scars. Notably, if the periphery and the central region of the keloid were considered together, increased involucrin expression was always present in at least one of the two regions. Increased involucrin expression in the context of a thickened epidermal cell layer has previously been reported for skin fibrosis induced by radiation.<sup>45</sup> While increased epidermal thickness in our study was not related to hyperproliferation, it was possibly related to abnormal terminal differentiation, specifically at the level of involucrin expression.

At the ultrastructural level, we found that the abnormal epidermal differentiation was in fact associated with disorganization of the stratum corneum in keloid scars. Deposition of involucrin protein on the inner side of the keratinocyte cell membrane is an important first scaffolding step, with other CE proteins subsequently added. Ultimately, the process of keratinocyte differentiation results in the production of corneocytes, flattened dead cells comprising mostly keratin filaments encased in an impermeable CE. Together with intercellular lipids, they make up the 'bricks and mortar' of the stratum corneum barrier.<sup>46</sup> As such, it is not unreasonable to assume that the abnormal differentiation may have affected the CE, the end result of the differentiation process. Involucrin is also known to be expressed prematurely in psoriasis and is thought to be related to the observed ultrastructural immature CE formation.<sup>47,48</sup> Psoriatic involucrin-expressing CE developed already in lower spinous layers and remained thin instead of thickening, and showed reduced involucrin expression as in

healthy skin.<sup>46,49</sup> For this reason, it seems likely that the precocious involucrin expression in keloids also correlates with changes in CE formation and, consequently, in stratum corneum formation.

There is also evidence suggesting that the stratum corneum is not only structurally but also functionally compromised. The stratum corneum of both keloids and hypertrophic scars showed increased transepidermal water loss (TEWL) and/or water-holding capacity (high-frequency conductance) compared with atrophic scars and corresponding normal skin, as well as a faster turnover rate of the stratum corneum.<sup>50,51</sup> Interestingly, the abnormal TEWL found in keloids resembled that of young scars, suggesting that keloid scars do not progress beyond the early stages of wound healing and remain in this state for years.<sup>51</sup> This is particularly interesting given that Kunii *et al.*<sup>52</sup> not only found numerous immature and less hydrophobic CEs in the corneocytes derived from superficial stratum corneum layers in young scars, but also saw that barrier dysfunction could be attributed to these defective corneocytes rather than the intercellular lipid abnormalities. Thus, the abnormal epidermal differentiation characterizing keloid scars may very well lead to defective CEs, with subsequent stratum corneum barrier dysfunction. Decreased hydration levels, in turn, have been known to result in increased pro-inflammatory gene expression in epidermal keratinocytes.<sup>53</sup>

In summary, this study lends further support to the hypothesis that keratinocytes are involved in abnormal scar formation. Yan *et al.*<sup>54</sup> showed that keloid epidermal cells undergoing an epidermal–mesenchymal transition may be one of the cell types responsible for generating keloid fibroblasts. Furthermore, the possible involvement of the epidermis in hypertrophic scar formation has previously been implied and demonstrated via immunohistochemical studies by several authors.<sup>10,44</sup> In our study, hypertrophic scars showed a mostly mixed phenotype that was intermediate between normotrophic and keloid scars, while the epidermal abnormalities in keloid scars were more pronounced and more frequent. Our findings thus do not yet allow for a clear distinction between the two abnormal scar types, but do suggest they are not simply one and the same. Together with our current findings of increased epidermal thickness with abnormal terminal differentiation, this study strongly supports the possibility that the epidermal abnormalities are associated with mature keloid scar formation and, as such, should no longer be overlooked when studying the underlying pathogenesis.

## Acknowledgments

The authors would like to thank S.C. Sampat-Sardjoepersad for technical assistance.

## References

- Hollywood KA, Maatje M, Shadi IT *et al.* Phenotypic profiling of keloid scars using FT-IR microspectroscopy reveals a unique spectral signature. *Arch Dermatol Res* 2010; **302**:705–15.

- 2 Butler PD, Ly DP, Longaker MT *et al.* Use of organotypic coculture to study keloid biology. *Am J Surg* 2008; **195**:144–8.
- 3 Andriessen MP, Niessen FB, Van de Kerkhof PC *et al.* Hypertrophic scarring is associated with epidermal abnormalities: an immunohistochemical study. *J Pathol* 1998; **186**:192–200.
- 4 Werner S, Krieg T, Smola H. Keratinocyte–fibroblast interactions in wound healing. *J Invest Dermatol* 2007; **127**:998–1008.
- 5 Harrison CA, Dalley AJ, MacNeil S. A simple in vitro model for investigating epithelial/mesenchymal interactions: keratinocyte inhibition of fibroblast proliferation and fibronectin synthesis. *Wound Repair Regen* 2005; **13**:543–50.
- 6 Garner WL. Epidermal regulation of dermal fibroblast activity. *Plast Reconstr Surg* 1998; **102**:135–9.
- 7 Eisinger M, Sadan S, Silver IA *et al.* Growth regulation of skin cells by epidermal cell-derived factors: implications for wound healing. *Proc Natl Acad Sci USA* 1988; **85**:1937–41.
- 8 Amjad SB, Carachi R, Edward M. Keratinocyte regulation of TGF- $\beta$  and connective tissue growth factor expression: a role in suppression of scar tissue formation. *Wound Repair Regen* 2007; **15**:748–55.
- 9 Silver IA, Eisinger M. Influence of an epidermal cell extract on skin healing and scar formation. *Int J Tissue React* 1988; **10**:381–5.
- 10 Hakvoort TE, Altun V, Ramrattan RS *et al.* Epidermal participation in post-burn hypertrophic scar development. *Virchows Arch* 1999; **434**:221–6.
- 11 Machesney M, Tidman N, Waseem A *et al.* Activated keratinocytes in the epidermis of hypertrophic scars. *Am J Pathol* 1998; **152**:1133–41.
- 12 Seifert O, Mrowietz U. Keloid scarring: bench and bedside. *Arch Dermatol Res* 2009; **301**:259–72.
- 13 Burd A, Chan E. Keratinocyte–keloid interaction. *Plast Reconstr Surg* 2002; **110**:197–202.
- 14 Lim IJ, Phan TT, Bay BH *et al.* Fibroblasts cocultured with keloid keratinocytes: normal fibroblasts secrete collagen in a keloidlike manner. *Am J Physiol Cell Physiol* 2002; **283**:C212–22.
- 15 Lim IJ, Phan TT, Song C *et al.* Investigation of the influence of keloid-derived keratinocytes on fibroblast growth and proliferation in vitro. *Plast Reconstr Surg* 2001; **107**:797–808.
- 16 Phan TT, Lim IJ, Bay BH *et al.* Differences in collagen production between normal and keloid-derived fibroblasts in serum-media coculture with keloid-derived keratinocytes. *J Dermatol Sci* 2002; **29**:26–34.
- 17 Phan TT, Lim IJ, Bay BH *et al.* Role of IGF system of mitogens in the induction of fibroblast proliferation by keloid-derived keratinocytes in vitro. *Am J Physiol Cell Physiol* 2003; **284**:C860–9.
- 18 Funayama E, Chodon T, Oyama A *et al.* Keratinocytes promote proliferation and inhibit apoptosis of the underlying fibroblasts: an important role in the pathogenesis of keloid. *J Invest Dermatol* 2003; **121**:1326–31.
- 19 Khoo YT, Ong CT, Mukhopadhyay A *et al.* Upregulation of secretory connective tissue growth factor (CTGF) in keratinocyte–fibroblast coculture contributes to keloid pathogenesis. *J Cell Physiol* 2006; **208**:336–43.
- 20 Hahn JM, Glaser K, McFarland KL *et al.* Keloid-derived keratinocytes exhibit an abnormal gene expression profile consistent with a distinct causal role in keloid pathology. *Wound Repair Regen* 2013; **21**:530–44.
- 21 Louw L, van der Westhuizen JP, de Duyvene WL *et al.* Keloids: peripheral and central differences in cell morphology and fatty acid compositions of lipids. *Adv Exp Med Biol* 1997; **407**:515–20.
- 22 Waaijman T, Breetveld M, Ulrich M *et al.* Use of a collagen–elastin matrix as transport carrier system to transfer proliferating epidermal cells to human dermis in vitro. *Cell Transplant* 2010; **19**:1339–48.
- 23 van der Meijden K, Lips P, van Driel M *et al.* Primary human osteoblasts in response to 25-hydroxyvitamin D<sub>3</sub>, 1,25-dihydroxyvitamin D<sub>3</sub> and 24R,25-dihydroxyvitamin D<sub>3</sub>. *PLoS ONE* 2014; **9**:e110283.
- 24 Lu F, Gao J, Ogawa R *et al.* Biological differences between fibroblasts derived from peripheral and central areas of keloid tissues. *Plast Reconstr Surg* 2007; **120**:625–30.
- 25 Tsujita-Kyutoku M, Uehara N, Matsuoka Y *et al.* Comparison of transforming growth factor- $\beta$ /Smad signaling between normal dermal fibroblasts and fibroblasts derived from central and peripheral areas of keloid lesions. *In Vivo* 2005; **19**:959–63.
- 26 Kose O, Waseem A. Keloids and hypertrophic scars: are they two different sides of the same coin? *Dermatol Surg* 2008; **34**:336–46.
- 27 Niessen FB, Spauwen PH, Schalkwijk J *et al.* On the nature of hypertrophic scars and keloids: a review. *Plast Reconstr Surg* 1999; **104**:1435–58.
- 28 Ehrlich HP, Desmouliere A, Diegelmann RF *et al.* Morphological and immunohistochemical differences between keloid and hypertrophic scar. *Am J Pathol* 1994; **145**:105–13.
- 29 Shaker SA, Ayuob NN, Hajrah NH. Cell talk: a phenomenon observed in the keloid scar by immunohistochemical study. *Appl Immunohistochem Mol Morphol* 2011; **19**:153–9.
- 30 Lee JY-Y, Yang CC, Chao SC *et al.* Histopathological differential diagnosis of keloid and hypertrophic scar. *Am J Dermatopathol* 2004; **26**:379–84.
- 31 Atiyeh BS, Costagliola M, Hayek SN. Keloid or hypertrophic scar: the controversy: review of the literature. *Ann Plast Surg* 2005; **54**:676–80.
- 32 Moshref SS, Mufti ST. Keloid and hypertrophic scars: comparative histopathological and immunohistochemical study. *J King Abdulaziz Univ Med Sci* 2010; **17**:3–22.
- 33 Gira AK, Brown LF, Washington CV *et al.* Keloids demonstrate high-level epidermal expression of vascular endothelial growth factor. *J Am Acad Dermatol* 2004; **50**:850–3.
- 34 Chua AW, Ma D, Gan SU *et al.* The role of R-spondin2 in keratinocyte proliferation and epidermal thickening in keloid scarring. *J Invest Dermatol* 2011; **131**:644–54.
- 35 Sidgwick GP, Iqbal SA, Bayat A. Altered expression of hyaluronan synthase and hyaluronidase mRNA may affect hyaluronic acid distribution in keloid disease compared with normal skin. *Exp Dermatol* 2013; **22**:377–9.
- 36 Bertheim U, Hellstrom S. The distribution of hyaluronan in human skin and mature, hypertrophic and keloid scars. *Br J Plast Surg* 1994; **47**:483–9.
- 37 Ong CT, Khoo YT, Mukhopadhyay A *et al.* Comparative proteomic analysis between normal skin and keloid scar. *Br J Dermatol* 2010; **162**:1302–15.
- 38 Lee YS, Hsu T, Chiu WC *et al.* Keloid-derived, plasma/fibrin-based skin equivalents generate *de novo* dermal and epidermal pathology of keloid fibrosis in a mouse model. *Wound Repair Regen* 2016; **24**:302–16.
- 39 Niessen FB, Spauwen PH, Robinson PH *et al.* The use of silicone occlusive sheeting (Sil-K) and silicone occlusive gel (Epiderm) in the prevention of hypertrophic scar formation. *Plast Reconstr Surg* 1998; **102**:1962–72.
- 40 Amadeu T, Braune A, Mandarin-de-Lacerda C *et al.* Vascularization pattern in hypertrophic scars and keloids: a stereological analysis. *Pathol Res Pract* 2003; **199**:469–73.
- 41 Materazzi S, Pellerito S, Di SC *et al.* Analysis of protease-activated receptor-1 and -2 in human scar formation. *J Pathol* 2007; **212**:440–9.
- 42 Choi YH, Kim KM, Kim HO *et al.* Clinical and histological correlation in post-burn hypertrophic scar for pain and itching sensation. *Ann Dermatol* 2013; **25**:428–33.

- 43 Jumper N, Paus R, Bayat A. Functional histopathology of keloid disease. *Histol Histopathol* 2015; **30**:1033–57.
- 44 Bloor BK, Tidman N, Leigh IM *et al.* Expression of keratin K2e in cutaneous and oral lesions: association with keratinocyte activation, proliferation, and keratinization. *Am J Pathol* 2003; **162**:963–75.
- 45 Sivan V, Vozenin-Brotans MC, Tricaud Y *et al.* Altered proliferation and differentiation of human epidermis in cases of skin fibrosis after radiotherapy. *Int J Radiat Oncol Biol Phys* 2002; **53**:385–93.
- 46 Nemes Z, Steinert PM. Bricks and mortar of the epidermal barrier. *Exp Mol Med* 1999; **31**:5–19.
- 47 Ishida-Yamamoto A, Iizuka H. Differences in involucrin immunolabeling within cornified cell envelopes in normal and psoriatic epidermis. *J Invest Dermatol* 1995; **104**:391–5.
- 48 Bernard BA, Reano A, Darmon YM *et al.* Precocious appearance of involucrin and epidermal transglutaminase during differentiation of psoriatic skin. *Br J Dermatol* 1986; **114**:279–83.
- 49 Hirao T, Denda M, Takahashi M. Identification of immature cornified envelopes in the barrier-impaired epidermis by characterization of their hydrophobicity and antigenicities of the components. *Exp Dermatol* 2001; **10**:35–44.
- 50 Sogabe Y, Akimoto S, Abe M *et al.* Functions of the stratum corneum in systemic sclerosis as distinct from hypertrophic scar and keloid functions. *J Dermatol Sci* 2002; **29**:49–53.
- 51 Suetake T, Sasai S, Zhen YX *et al.* Functional analyses of the stratum corneum in scars. Sequential studies after injury and comparison among keloids, hypertrophic scars, and atrophic scars. *Arch Dermatol* 1996; **132**:1453–8.
- 52 Kunii T, Hirao T, Kikuchi K *et al.* Stratum corneum lipid profile and maturation pattern of corneocytes in the outermost layer of fresh scars: the presence of immature corneocytes plays a much more important role in the barrier dysfunction than do changes in intercellular lipids. *Br J Dermatol* 2003; **149**:749–56.
- 53 Xu W, Jia S, Xie P *et al.* The expression of proinflammatory genes in epidermal keratinocytes is regulated by hydration status. *J Invest Dermatol* 2014; **134**:1044–55.
- 54 Yan L, Cao R, Wang L *et al.* Epithelial–mesenchymal transition in keloid tissues and TGF- $\beta$ 1-induced hair follicle outer root sheath keratinocytes. *Wound Repair Regen* 2015; **23**:601–10.

## Supporting Information

Additional Supporting Information may be found in the online version of this article at the publisher's website:

**Table S1.** Donor characteristics: immunohistochemistry.

**Table S2.** Donor characteristics: keratinocyte amplification assay.

**Table S3.** Donor characteristics: involucrin reverse-transcriptase polymerase chain reaction.

**Table S4.** Donor characteristics: transmission electron microscopy.