

FOXN1 Deficiency: from the Discovery to Novel Therapeutic Approaches

Vera Gallo¹ · Emilia Cirillo¹ · Giuliana Giardino¹ · Claudio Pignata¹ 

Received: 29 June 2017 / Accepted: 11 September 2017
© Springer Science+Business Media, LLC 2017

Abstract Since the discovery of FOXN1 deficiency, the human counterpart of the nude mouse, a growing body of evidence investigating the role of FOXN1 in thymus and skin, has been published. FOXN1 has emerged as fundamental for thymus development, function, and homeostasis, representing the master regulator of thymic epithelial and T cell development. In the skin, it also plays a pivotal role in keratinocytes and hair follicle cell differentiation, although the underlying molecular mechanisms still remain to be fully elucidated. The nude severe combined immunodeficiency phenotype is indeed characterized by the clinical hallmarks of athymia with severe T cell immunodeficiency, congenital alopecia, and nail dystrophy. In this review, we summarize recent discoveries in the field and give interesting perspective about new and promising therapeutic approaches for disorders of immune system with athymia.

Keywords FOXN1 · Severe combined immunodeficiency · Athymia · Nude SCID phenotype · Nude mouse · T cell development · Thymus transplantation

Introduction

Severe combined immunodeficiency (SCID) indicates a clinically and genetically heterogeneous group of congenital disorders due to abnormalities of development and/or function of T, B, and NK cells, always resulting in impairment of both

cellular and humoral immunity. To date, more than 20 genetic alterations have been identified as responsible for the disease [1]. Among these, the *FOXN1* gene mutation, causative of the nude SCID phenotype, is the unique condition in which the immunological defect is related to an alteration of the thymic epithelial stroma and not to an intrinsic defect of the hematopoietic cell. The nude SCID phenotype has been identified in human for the first time in 1996 in two female patients who presented with thymus aplasia and ectodermal abnormalities [2], approximately 30 years later than the initial description of the murine counterpart. Thereafter, several nude SCID patients from all over the world have been described in the literature [3–5]. The immunological phenotype is $T^{-/low}B^{+}NK^{+}$, with a profound functional T cell impairment, leading to severe and life-threatening infections in the first months of life. In addition to the classical SCID phenotype, the patients affected also exhibited extra-immunological features, involving primarily the skin and hair.

FOXN1 is a member of the forkhead box gene family that comprises a diverse group of “winged helix” transcription factors implicated in a variety of cellular processes: development, metabolism, cancer, and aging [6]. While during fetal life FOXN1 is expressed in several mesenchymal and epithelial cells, including those of the liver, lung, intestine, kidney, and urinary tract, its postnatal expression is restricted to stromal thymus and skin cells, where FOXN1 is necessarily required for the normal development, function, and maintenance of hair follicles and thymic epithelial cells (TECs). However, the molecular mechanisms by which FOXN1 expression and activity are regulated are only incompletely understood.

The aim of this review is to give an updated and broad picture of the role of FOXN1, and its implications in human disease, based on previously published work, which we hope may be proven useful for both clinicians and scientists in the field. We will begin by summarizing the

✉ Claudio Pignata
pignata@unina.it

¹ Department of Translational Medical Sciences, Section of Pediatrics, Federico II University, Via S. Pansini, 5, 80131 Naples, Italy

history of FOXN1 discovery in mice and humans, dissecting the human nude SCID phenotype and the disease mechanisms through the elucidation of the role of FOXN1 in the thymus, skin, and nervous system, followed by treatment options and relative outcome of the disease and potential future areas of research.

The Role of Foxn1 Revealed by Animal Models: the Nude Mouse

The nude mouse phenotype has been described by Flanagan in 1966, after its spontaneous appearance in the Virus Laboratory of Ruchill Hospital, Glasgow, UK [7]. This mouse showed abnormalities of hair keratinization and thymic dysgenesis, resulting in both hairlessness and profound T cell immunodeficiency, indicating that the gene exerted pleiotropic effects. Indeed, positional cloning allowed to identify a member of the forkhead or winged helix superfamily, *Foxn1* (originally referred as winged helix nude, *Whn*), as the gene mutated [8–10]. Mice homozygous for the mutation “nude,” *nu/nu* mice, were hairless, had delayed growth, decreased fertility, and died early in life because of severe infections. In particular, as concerned the skin, hair follicles were present in the same number in wild-type control and nude mouse; however, in the latter, these follicles result in a hair that started to twist and coil due to the absence of free sulfhydryl groups in the mid-follicle region, thus failing to penetrate into the epidermis. In these mice, moreover, the differentiation of the epidermis was abnormal as well, and characterized by abnormal balance between proliferation and differentiation of keratinocytes in the hair follicle [11, 12]. In addition to these cutaneous abnormalities, the immunological hallmark of the nude mice was an abnormal, or even absent, thymus, resulting in a severe T cell deficiency and an overall severely impaired immune system. The thymus morphogenesis was blocked at the beginning of the development, resulting in a profound alteration of the organ architecture with no subcapsular, cortical, and medullary region formation [9]. In addition, the hair growth could not be rescued by thymus restoration, indicating that the annexa abnormality was due to a direct role of the gene in epidermis differentiation [9, 13]. In support of this, the nude phenotype was also characterized by nail malformations and severe infertility. The first condition was attributed to an abnormal production of fillagrin, a protein of the nail matrix and plate, subsequent to the loss of keratin 1 protein. Differently, the infertility, related to small ovaries with low egg counts in the females and no motile sperm in the males [7], may be the result of hormonal changes, as demonstrated by the altered serum levels of estradiol, progesterone, and thyroxine [14].

FOXN1 Deficiency in Humans: the Nude SCID

History

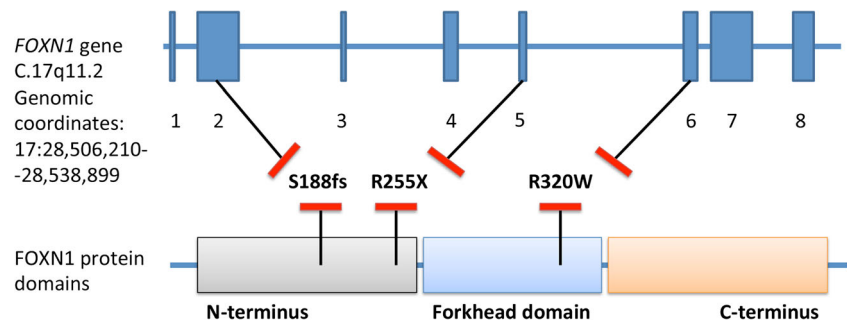
Most of the knowledge on cell-mediated immunity and particularly on T cell thymic lymphopoiesis originated from studies performed in the nude SCID mouse model. Since its first description and the identification of FOXN1 gene, more than 100 papers have been published dissecting its immunological role. As for the human phenotype, for many years, DiGeorge syndrome has been erroneously considered the human counterpart based on the thymic aplasia or hypoplasia [15]. However, DiGeorge syndrome shows a wide spectrum of clinical features, including parathyroid and cardiac and great vessel malformations [16, 17], absent in the nude phenotype, whereas the hallmarks of the nude SCID, hairlessness and abnormalities of skin annexa, are missing. More importantly, the immune defect in DiGeorge patients is also much less severe than the nude phenotype [17]. The identification of the full equivalent human phenotype of nude mouse occurred surprisingly about 30 years later with the description of two Italian sisters, who presented congenital alopecia, eyebrows, eyelashes, and nail dystrophy associated with a severe T cell immunodeficiency, as detailed below [2]. The consanguinity of the parents and the small community where the patients originated from suggested an autosomal recessive inheritance [18]. The time gap from the original mouse description led to hypothesize a lethal phenotype in subjects with complete expression.

Genetics

FOXN1 gene is located on chromosome 17q11.2 and consists of eight exons, spanning about 30 kb [19] (Fig. 1). Interesting, two different first exons, which are noncoding, have been identified through an extensive screening of cDNA clones obtained from skin cells, the exons 1a and 1b, that undergo to alternative splicing [20]. This suggests the presence of two distinct promoters of exons 1a and 1b [21]. The alternative usage of the exon 1a or 1b seems to be tissue specific, in that promoter 1a is active in thymus and skin, while promoter 1b is active only in skin [20].

Up to date, only three mutations of the *FOXN1* gene have been reported in humans: the R255X, the S188fs, and the R320W [2–5]. These mutations are located in different domains of the molecule, and all resulted in a loss of function of the protein (Fig. 1). The first mutation identified, the R255X, resulted from a homozygous 792C-T aminoacidic transition in the N-terminus exon 5, leading to a premature stop codon causing the truncation of the protein before the start of the evolutionary conserved forkhead domain. The R320W was a homozygous missense mutation located in the forkhead domain (exon 6) in which aminoacidic substitution,

Fig. 1 Schematic representation of the *FOXN1* gene with the distinct eight exons and protein domains showing the position of identified mutations annotated by amino acid alterations



C987T, impaired its DNA binding ability, and thus the transcriptional regulation of target genes. The last reported S188fs mutation was a small deletion of exon 2, c.562delA, also resulted in a frameshift and premature truncation of the protein after the first 24 amino acids of the forkhead domain.

Focus on Immunodeficiency: FOXN1 in TECs and T Cell Development

All nude SCID patients reported so far showed decreased T cell counts [2–5], with a predominant reduction of CD4⁺ T cells [2, 3] and an increase of double-negative lymphocytes in the peripheral blood [3, 4]. T cells had a poor or absent proliferative response to mitogens and exhibited an oligoclonal TCR repertoire [2–4]. NK and B cells, although normal in number, were also functionally impaired with abnormal specific antibody production [2–5]. The T cell immunodeficiency resulted also in a severe reduction of T cell receptor rearrangement excision circles (TRECs) [3], CD31⁺ recent thymic emigrants [4], and naïve CD4⁺ CD45RA⁺ T cells, the latter turning in favor of a CD45RO⁺ memory phenotype [3, 4, 22].

The identification of the nude/SCID phenotype greatly contributed to unravel important issues of thymic and T cell development. Studies on both mouse and human have demonstrated that the transcription factor FOXN1 plays a key role in the morphogenesis of the three-dimensional thymic architecture, which is important for the functionality of the thymus. In particular, Foxn1 is expressed in all TECs during initial thymus organogenesis and is required to induce both cortical and medullary thymic epithelial cell differentiation [9, 23–26]. Moreover, FOXN1 is considered essential also for the prevention of thymic involution during adulthood [27–29]. In particular, in mice, Foxn1 mainly regulates TEC differentiation and homeostasis during fetal and postnatal life [28, 30]. TECs are implicated in either thymus organogenesis or most stages of the maturation of T cell precursors [31, 32] (Fig. 2). In a Foxn1-dependent manner, TECs release several chemokines, including CCL25, CCL21, and CXCL12, that allow hematopoietic progenitors to enter into the developing thymus [33, 34]. These progenitors, subsequently, are committed to a T cell fate and progress through the different phases of the

ontogenesis, thanks to the crosstalk with TECs and under the stimuli of TEC-derived molecules, such as the notch ligand DLL4, which, in turn, is also transcriptionally regulated by FOXN1 [35, 36]. In developing T cells, cortical and medullary TECs (cTECs and mTECs) induce the “positive” and “negative” selection processes, respectively, with mTECs acting only in negative selection [37] (Fig. 2). These processes are driven by MHC–self-antigen complexes presented on the surface of TECs [38, 39] (Fig. 2). In addition to CCL25, CXCL12, and DLL4, FOXN1 has been recently proven to promote the expression of hundreds of genes in TECs that support intrathymic T cell development through the antigen processing and presentation. In particular, it was found that the expression of *Prss16* in cTECs, which encodes a thymus-specific serine protease required for CD4 lineage selection and high MHCII expression, is regulated by Foxn1 [34]. Moreover, a direct binding target of Foxn1 has been detected uniquely in cTECs, represented by a cis-regulatory element involved in the transcriptional promotion of relevant cTEC genes. Indeed, the Foxn1 binding to this element promotes the transcription of $\beta 5t$ gene, the catalytic subunit of cTEC thymoproteasome, which has an essential role in positive selection induction of functionally competent CD8⁺ T cells within the thymus [40]. In the absence of FOXN1 expression in TECs, the thymic development is thereby blocked at a rudimentary stage [27, 28, 34], characterized by an alymphoid two-dimensional anlage with a cystic structure [22, 41, 42]. In this thymic rudiment, TECs are not capable to allow the hematopoietic precursor cells (HPCs) to enter into the epithelial cluster [43]. Taken together, this evidence strongly demonstrated the pivotal role of the lymphostromal crosstalk. Nevertheless, significant numbers of circulating T cells of non-maternal origin with major expansions of CD3⁺CD4[−]CD8[−] $\alpha\beta$ TCR have been documented in all cases reported of homozygous R255X FOXN1 deficiency [2, 3]. Differently, no circulating T cells were found in the patient with the R320W mutation [3]. A possible explanation is that a thymic rudiment may persist, supporting a limited production of T cells. An alternative explanation is that an extrathymic site of T cell differentiation is capable to support the development, albeit with a narrow TCR repertoire and impaired T cell selection. Furthermore, during prenatal T cell

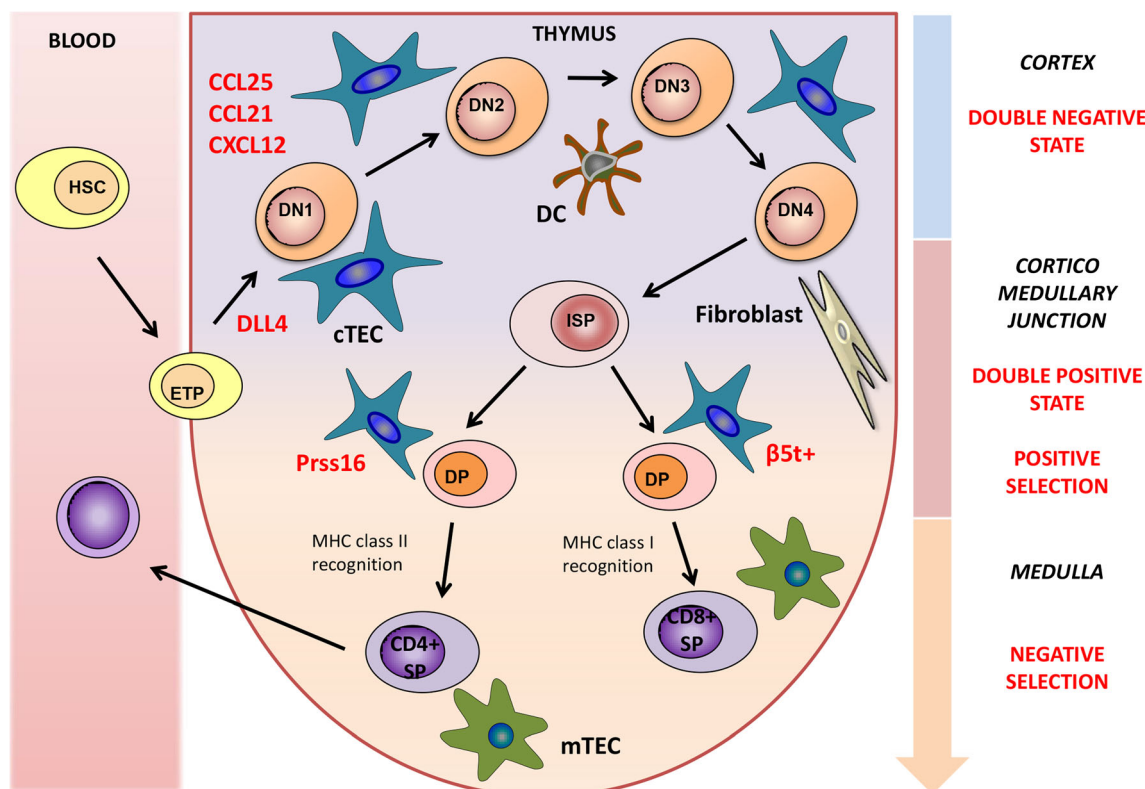


Fig. 2 Intrathymic T cell development. Lymphoid progenitor cells get access into the thymus through the vessel of the corticomedullary junction under the stimuli of Foxn1-related chemokines released by cTECs. Double-negative (DN) lymphocyte ($CD4^- CD8^-$) interaction with cTECs in the thymic cortex allows them to mature through different double-negative stages and finally generate double-positive (DP) lymphocytes ($CD3^+ CD4^+ CD8^+$). cTECs, expressing specific genes under

the control of Foxn1, are involved in positive selection. In the medulla, positively selected lymphocytes interact with mTECs to complete the maturation process. Self-reactive lymphocytes are further deleted, through the so-called negative selection. Eventually, single-positive (SP) ($CD3^+ CD4^+$ or $CD3^+ CD8^+$) lymphocytes are generated and released in the peripheral blood

development in humans, it has been observed that FOXN1 mutation completely abrogates T cell ontogeny of CD4 compartment, while having a limited production of CD8⁺ cells, indicating a possible different origin of these cells [42].

Focus on Ectodermal Abnormalities: FOXN1 and the Skin

In addition to athymia and T cell immunodeficiency, FOXN1 mutations are also associated with ectodermal defects of skin and hair, namely alopecia of the scalp, eyebrows, and eyelashes and nail dystrophy. In both patients and nude mice, hair follicles are normal in number but give rise to altered hairs unable to curl and that break off at the level of the skin surface leading to alopecia [7, 44]. As for nail dystrophy, the most frequent features were leukonychia and koilonychia (“spoon nail”), the first one characterized by a proximal arciform alteration of the nail plate and the second one by a concave surface and raised edges of the distal nail plate [45]. Canaliform dystrophy and transverse groove of the nail plate (Beau line) were also noted, although less frequently. The

same skin annexa alterations were also reported in a few strains of nude mice [12].

Studies from mouse skin revealed a specific pattern of expression of Foxn1 in both epidermis and hair follicle, indicative of its involvement in cell growth and differentiation processes, and particularly of its role as regulator of starting terminal differentiation [21]. Indeed, in the epidermis, Foxn1 is primarily expressed in the keratinocytes of the first suprabasal layer, which stopped to proliferate and initiated terminal differentiation [12], although rare cell Foxn1⁺Ki67⁺ was found in the basal layer, likely representative of the very early stages of commitment to differentiation [46]. Similarly, in the hair follicle, Foxn1 expression was found in cells located in the supramatrical region and ready to begin terminal differentiation [47, 48]. Functionally, although molecular pathways still remain to be fully elucidated, Foxn1 promotes keratinocyte differentiation through the regulation of more than 50 target genes, including protein kinase B and protein kinase C (PKC), the latter being a potent inhibitor of human hair follicle growth in vitro [49–51]. In keeping with this, PKC activity was found upregulated in Foxn1^{-/-} mouse keratinocytes, while Foxn1 overexpression determined the suppression of PKC activation

and inhibition of keratinocyte differentiation [51]. Studies performed on human epidermal keratinocytes confirmed the role of FOXN1 in the initiation of keratinocyte differentiation, but it was found to be not sufficient to induce the final stages of terminal differentiation [52].

Focus on Neurological Abnormalities: FOXN1 and the Nervous System

Up to date, central nervous system (CNS) abnormalities have only been found in two fetuses carrying the R255X mutation from the same family in the highly consanguineous village of Acerno [53, 54]. The first fetus showed severe neural tube defects, such as anencephaly and spina bifida, while the second one had milder defects including an enlarged interhemispheric fissure with the absence of the cavum septi pellucidi and corpus callosum [53, 54]. Although other members of the forkhead/winged helix family proteins, such as mouse HNF-3b and BF-1 and human FOXP2, were reported to be involved in CNS development and function [55, 56], the absence of neurological abnormalities in nude mouse models along with the high rate of consanguinity in the population of the two fetuses suggested that another genetic etiology could have caused the neurological features. Thus, the role of FOXN1 in CNS development still remains unconfirmed and to be further investigated [53].

FOXN1 Mutations in Heterozygous Subjects

In the small community of south Italy, where the first two sisters with FOXN1 deficiency were identified, additional cases of patients with congenital alopecia and early child death because of severe infections were reported [18]. Interestingly, 55 subjects of 843 inhabitants studied were found to carry the heterozygous FOXN1 mutation. All the carriers and affected cases identified belonged to an extended seven generational pedigree, derived by a single ancestral couple born at the beginning of the nineteenth century from which four family groups originated. Physical examination of the identified heterozygous subjects revealed that 39 of the 55 heterozygous subjects showed a nail dystrophy. Leukonychia, characterized by a typical arciform pattern reminiscent of a half-moon and involving the proximal part of the nail plate, was the most specific phenotypic alteration together with koilonychia and Beau line. Immunological alterations have also been documented in a heterozygous carrier, including lymphopenia and absence of TREC (personal communication by Dr. Gelfand). Unfortunately, no lymphocyte counts or other lab investigations were performed in the large group of heterozygous subjects of south Italy [18].

Focus on Therapy and Long-Term Outcome: HSCT and Thymus Transplantation

The SCID diagnosis requires a prompt and appropriate treatment, that in the majority of cases is represented by hematopoietic stem cell transplantation (HSCT) that leads to reconstitute the immune system before the onset of life-threatening complications. The sooner the HSCT is performed, the better the outcome [57]. As for nude SCID, since thymic stromal alterations due to FOXN1 mutation underlie the immune defect, thymus transplantation could be a good alternative therapeutic approach to HSCT, even though conclusive results are still not available. Restoring a functional thymic stromal environment is expected to provide a long-lasting immune reconstitution [3, 4]. In complete DiGeorge syndrome, it has been observed that HSCT did not result in a high-quality immune reconstitution [22, 58–61].

Of the nine nude SCID patients reported, five of them have been treated in order to achieve immune reconstitution, three receiving HLA-matched sibling/genoidental HSCT at 5 months of age [2, 4, 5, 22] and two with thymus transplantation at the age of 9 and 14 months [3]. One of the HSCT recipients 6 years after HSCT was alive and infection-free with reconstitution of CD3⁺, CD4⁺, and CD8⁺ subsets, although naïve CD4⁺ lymphocyte regeneration and lymphocyte proliferative capacities were impaired [22]. Surprisingly, naïve CD8⁺ cell was normal, suggesting a different thymus requirement for the generation of naïve CD4⁺ or CD8⁺ lymphocytes. The other HSCT recipients died due to post-transplant complications [4, 5]. In the other two cases treated with thymus transplantation, a successful T cell lymphopoiesis was restored with the development of a functional T cell compartment, although it took several months. Both patients showed a normal T cell number, TREC-positive naïve CD4⁺ T cells, and CD31⁺ recent thymic emigrants in the peripheral blood. Moreover, the newly generated T cells showed normal proliferative response in vitro, developed a diverse TCR repertoire, and were able to support B cell function, leading to normalization of Ig levels and production of specific antibodies directed against T cell-dependent antigens [3, 62]. The functional immune reconstitution allowed both patients to clear the ongoing pre-transplantation infections and to remain infection-free at 3 and 5 years after thymic transplant, although one patient developed autoimmune hypothyroidism and vitiligo [3, 63].

In conclusion, although thymic transplantation may be considered a promising therapeutic option in nude SCID patients, it should be considered as the most appropriate treatment only if a HLA-matched sibling donor is not available and when a rapid T cell recovery is not needed.

Future Perspective: Surrogate Organ

Recent evidence documented a new promising perspective, consisting of a scaffold mimicking the three-dimensional architecture of thymus, which may be potentially useful to allow the differentiation of hematopoietic cell precursors and, eventually, the restoration of functional immune system in congenital immunodeficiencies with athymia, such as nude SCID and DiGeorge syndrome. In keeping with this, Clark et al. documented that human skin fibroblasts and keratinocytes arrayed on a synthetic three-dimensional matrix were capable to support the development of functional human T cells from hematopoietic precursor cells in the absence of thymic tissue [64]. The newly generated T cells exhibited the same characteristics of recent thymic emigrants, contained T cell receptor excision circles, possessed a diverse T cell repertoire, and were functionally mature and tolerant to self MHC, indicating a successful differentiation process [64]. Thereafter, using a poly ϵ -caprolactone (PCL) scaffold reconfiguring a three-dimensional microenvironment, it has been shown that in the absence of thymic cellular epithelial elements, it is possible in succeeding the commitment of lymphoid precursors to the T cell lineage [65–67]. In particular, it has been documented a de novo generation in the matrix of cells of the T lineage expressing surface and molecular markers of early T cell commitment. In particular, a downregulation of *TAL1* and upregulation of *Spi-B* genes, consistently with the loss of the multilineage differentiative potential, was found [65]. Furthermore, *PTCRA* and *RAG2* expressions were also detectable during the culture, indicating that a recombination activity, indispensable for the generation of a T cell repertoire, was active [65]. However, a full maturation process in the matrix was not achieved, suggesting that additional factors or molecular manipulations could be necessary to create a TEC-like surrogate microenvironment capable to support the entire process of T cell ontogenesis. Nevertheless, effort should be maximized in this field of research, since the in vitro re-build of such a surrogate organ capable of reproducing tissue features of primary lymphoid organs is a promising helpful tool for future therapeutic strategies in patients affected with congenital disorders of immune system related to athymia.

Conclusion

Nude SCID due to FOXP1 mutations is a rare form of immunodeficiency with only a few cases documented up to now, characterized by severe T cell lymphopenia, alopecia, and nail dystrophy. Notably, the nude SCID phenotype is the only form of SCID associated with an alteration of a gene that is not expressed in the hematopoietic cell, but rather related to a peculiar alteration of thymus anlage. This makes the disorder a unique model of disease to investigate molecular pathways

involved in thymus dependent and independent T cell ontogeny. However, despite the increasing evidence, the detailed mechanisms of FOXP1 action in thymus and skin still remain to be fully clarified. Additional research in this field would be very helpful in conclusively defining the role of FOXP1 in the biological process and to pave the way for the development of novel therapeutic strategies, such as thymic transplantation or the generation of surrogate organ to treat congenital disorders of immune system.

Compliance with Ethical Standards

Conflict of Interest The authors declare that they have no competing interests.

References

1. Cirillo E, Giardino G, Gallo V, D'Assante R, Grasso F, Romano R, et al. Severe combined immunodeficiency—an update. *Ann N Y Acad Sci.* 2015;1356:90–106.
2. Pignata C, Fiore M, Guzzetta V, Castaldo A, Sebastio G, Porta F, et al. Congenital alopecia and nail dystrophy associated with severe functional T-cell immunodeficiency in two sibs. *Am J Med Genet.* 1996;65(2):167–70.
3. Markert ML, Marques J, Neven B, Devlin B, McCarthy E, Chinn I, et al. First use of thymus transplantation therapy for Foxp1 deficiency (nude/SCID): a report of two cases. *Blood.* 2011;117(2):688–96.
4. Chou J, Massaad MJ, Wakim RH, Bainter W, Dbaibo G, Geha RS. A novel mutation in FOXP1 resulting in SCID: a case report and literature review. *Clin Immunol.* 2014;155(1):30–2.
5. Radha Rama Devi A, Panday NN, Naushad SM. FOXP1 Italian founder mutation in Indian family: implications in prenatal diagnosis. *Gene.* 2017;627:222–5.
6. Kaufmann E, Knochel W. Five years on the wings of fork head. *Mech Dev.* 1996;57(1):3–20.
7. Flanagan SP. 'Nude', a new hairless gene with pleiotropic effects in the mouse. *Genet Res.* 1966;8(3):295–309.
8. Nehls M, Pfeifer D, Schorpp M, Hedrich H, Boehm T. New member of the winged-helix protein family disrupted in mouse and rat nude mutations. *Nature.* 1994;372(6501):103–7.
9. Nehls M, Kyewski B, Messerle M, Waldschutz R, Schuddekopf K, Smith AJ, et al. Two genetically separable steps in the differentiation of thymic epithelium. *Science.* 1996;272(5263):886–9.
10. Kaestner KH, Knochel W, Martinez DE. Unified nomenclature for the winged helix/forkhead transcription factors. *Genes Dev.* 2000;14(2):142–6.
11. Brisette JL, Li J, Kamimura J, Lee D, Dotto GP. The product of the mouse nude locus, Whn, regulates the balance between epithelial cell growth and differentiation. *Genes Dev.* 1996;10(17):2212–21.
12. Lee D, Prowse DM, Brisette JL. Association between mouse nude gene expression and the initiation of epithelial terminal differentiation. *Dev Biol.* 1999;208(2):362–74.
13. Eaton GJ. Hair growth cycles and wave patterns in "nude" mice. *Transplantation.* 1976;22(3):217–22.
14. Kopf-Maier P, Mboneko VF. Anomalies in the hormonal status of athymic nude mice. *J Cancer Res Clin Oncol.* 1990;116(3):229–31.
15. Gershwin ME. DiGeorge syndrome: congenital thymic hypoplasia. Animal model: congenitally athymic (nude) mouse. *Am J Pathol.* 1977;89(3):809–12.

16. Cancrini C, Puliafio P, Digilio MC, Soresina A, Martino S, Rondelli R, et al. Clinical features and follow-up in patients with 22q11.2 deletion syndrome. *J Pediatr*. 2014;164(6):1475–80.
17. McDonald-McGinn DM, Sullivan KE, Marino B, Philip N, Swillen A, Vorstman JAS, et al. 22q11.2 deletion syndrome. *Nat Rev Dis Primers*. 2015;1:15071.
18. Adriani M, Martinez-Mir A, Fusco F, Busiello R, Frank J, Telese S, et al. Ancestral founder mutation of the nude (FOXP1) gene in congenital severe combined immunodeficiency associated with alpecia in southern Italy population. *Ann Hum Genet*. 2004;68(3):265–8.
19. Takahama Y. Journey through the thymus: stromal guides for T-cell development and selection. *Nat Rev Immunol*. 2006;6(2):127–35.
20. Schorpp M, Hofmann M, Dear TN, Boehm T. Characterization of mouse and human nude genes. *Immunogenetics*. 1997;46(6):509–15.
21. Schlake T. The nude gene and the skin. *Exp Dermatol*. 2001;10(5):293–304.
22. Pignata C, Gaetaniello L, Masci AM, Frank J, Christiano A, Matrecano E, et al. Human equivalent of the mouse nude/SCID phenotype: long-term evaluation of immunological reconstitution after bone marrow transplantation. *Blood*. 2001;97(4):880–5.
23. Bleul CC, Corbeaux T, Reuter A, Fisch P, Monting JS, Boehm T. Formation of a functional thymus initiated by a postnatal epithelial progenitor cell. *Nature*. 2006;441(7096):992–6.
24. Su D, Navarre S, Oh W, Condie BG, Manley NR. A domain of Foxn1 required for crosstalk-dependent thymic epithelial cell differentiation. *Nat Immunol*. 2003;4(11):1128–35.
25. Gordon J, Bennett AR, Blackburn CC, Manley NR. Gem2 and Foxn1 mark early parathyroid- and thymus-specific domains in the developing third pharyngeal pouch. *Mech Dev*. 2001;103(1–2):141–3.
26. Itoi M, Tsukamoto N, Amagai T. Expression of Dll4 and CCL25 in Foxn1-negative epithelial cells in the post-natal thymus. *Int Immunol*. 2007;19(2):127–32.
27. Chen L, Xiao S, Manley NR. Foxn1 is required to maintain the postnatal thymic microenvironment in a dosage-sensitive manner. *Blood*. 2009;113(3):567–74.
28. Cheng L, Guo J, Sun L, Fu J, Barnes PF, Metzger D, et al. Postnatal tissue-specific disruption of transcription factor FoxN1 triggers acute thymic atrophy. *J Biol Chem*. 2010;285(8):5836–47.
29. Corbeaux T, Hess I, Swann JB, Kanzler B, Haas-Assenbaum A, Boehm T. Thymopoiesis in mice depends on a Foxn1-positive thymic epithelial cell lineage. *Proc Natl Acad Sci U S A*. 2010;107(38):16613–8.
30. Shakib S, Desanti GE, Jenkinson WE, Parnell SM, Jenkinson EJ, Anderson G. Checkpoints in the development of thymic cortical epithelial cells. *J Immunol*. 2009;182(1):130–7.
31. Blackburn CC, Manley NR, Palmer DB, Boyd RL, Anderson G, Ritter MA. One for all and all for one: thymic epithelial stem cells and regeneration. *Trends Immunol*. 2002;23(8):391–5.
32. Manley NR, Blackburn CC. A developmental look at thymus organogenesis: where do the non-hematopoietic cells in the thymus come from? *Curr Opin Immunol*. 2003;15(2):225–32.
33. Bleul CC, Boehm T. Chemokines define distinct microenvironments in the developing thymus. *Eur J Immunol*. 2000;30(12):3371–9.
34. Zuklys S, Handel A, Zhanybekova S, Govani F, Keller M, Maio S, et al. Foxn1 regulates key targets genes essential for T cell development in postnatal thymic epithelial cells. *Nat Immunol*. 2016;17(10):1206–15.
35. Tsukamoto N, Itoi M, Nishikawa M, Amagai T. Lack of Delta like 1 and 4 expressions in nude thymus anlagen. *Cell Immunol*. 2005;234(2):77–80.
36. Hozumi K, Mailhos C, Negishi N, Hirano K, Yahata T, Ando K, et al. Delta-like 4 is indispensable in thymic environment specific for T cell development. *J Exp Med*. 2008;205(11):2507–13.
37. Klein L, Kyewski B, Allen PM, Hogquist KA. Positive and negative selection of the T cell repertoire: what thymocytes see (and don't see). *Nat Rev Immunol*. 2014;14(6):377–91.
38. Anderson G, Takahama Y. Thymic epithelial cells: working class heroes for T cell development and repertoire selection. *Trends Immunol*. 2012;33(6):256–63.
39. Anderson G, Jenkinson EJ. Lymphostromal interactions in thymic development and function. *Nature Rev Immunol*. 2001;1(1):31–40.
40. Uddin MM, Ohigashi I, Motosugi R, Nakayama T, Sakata M, Hamazaki J, et al. Foxn1-b5t transcriptional axis controls CD8+ T-cell production in the thymus. *Nat Commun*. 2017;8:14419.
41. Pantelouris EM. Absence of thymus in a mouse mutant. *Nature*. 1968;217(5126):370–1.
42. Vigliano I, Gorrese M, Fusco A, Vitiello L, Amorosi S, Panico L, et al. FOXP1 mutation abrogates prenatal T-cell development in humans. *J Med Genet*. 2011;48(6):413–6.
43. Itoi M, Kawamoto H, Katsura Y, Amagai T. Two distinct steps of immigration of hematopoietic progenitors into the early thymus anlage. *Int Immunol*. 2001;13(9):1203–11.
44. D'Assante R, Fusco A, Palamaro L, Giardino G, Gallo V, Cirillo E, et al. Unraveling the link between ectodermal disorders and primary immunodeficiencies. *Int Rev Immunol*. 2016;35(1):25–38.
45. Auricchio L, Adriani M, Frank J, Busiello R, Christiano A, Pignata C. Nail dystrophy associated with a heterozygous mutation of the nude/SCID human FOXP1 (WHN) gene. *Arch Dermatol*. 2005;141(5):647–8.
46. Watt FM, Kubler MD, Hotchin NA, Nicholson LJ, Adams JC. Regulation of keratinocyte terminal differentiation by integrin-extracellular matrix interactions. *J Cell Sci*. 1993;106(1):175–82.
47. Meier N, Dear TN, Boehm T. Whn and mHa3 are components of the genetic hierarchy controlling hair follicle differentiation. *Mech Dev*. 1999;89(1–2):215–21.
48. Hardy MH. The secret life of the hair follicle. *Trends Genet*. 1992;8(2):55–61.
49. Xiong Y, Harmon CS. Interleukin-1beta is differentially expressed by human dermal papilla cells in response to PKC activation and is a potent inhibitor of human hair follicle growth in organ culture. *J Interf Cytokine Res*. 1997;17(3):151–7.
50. Takahashi T, Kamimura A, Shirai A, Yokoo Y. Several selective protein kinase C inhibitors including procyanidins promote hair growth. *Skin Pharmacol Appl Skin Physiol*. 2000;13(3–4):133–42.
51. Li J, Baxter RM, Weiner L, Goetinck PF, Calautti E, Brissette JL. Foxn1 promotes keratinocyte differentiation by regulating the activity of protein kinase C. *Differentiation*. 2007;75(8):694–701.
52. Janes SM, Ofstad TA, Campbell DH, Watt FM, Prowse DM. Transient activation of FOXP1 in keratinocytes induces a transcriptional programme that promotes terminal differentiation: contrasting roles of FOXP1 and Akt. *J Cell Sci*. 2004;117(18):4157–68.
53. Amorosi S, D'Armiento M, Calcagno G, Russo I, Adriani M, Christiano AM, et al. FOXP1 homozygous mutation associated with anencephaly and severe neural tube defect in human athymic nude/SCID fetus. *Clin Genet*. 2008;73(4):380–4.
54. Amorosi S, Vigliano I, Giudice ED, Panico L, Maruotti GM, Fusco A, et al. Brain alteration in a nude/SCID fetus carrying FOXP1 homozygous. *J Neurol Sci*. 2010;298(1–2):121–3.
55. Weinstein DC, Ruiz i Atalba A, Chen WS, Hoodless P, Prezioso VR, Jessell TM, et al. The winged-helix transcription factor HNF-3 beta is required for notochord development in the mouse embryo. *Cell*. 1994;78(4):575–88.
56. Lai CS, Fisher SE, Hurst JA, Vargha-Khadem F, Monaco AP. A forkhead-domain gene is mutated in a severe speech and language disorder. *Nature*. 2001;413(6855):519–23.

57. Rivers L, Gaspar HB. Severe combined immunodeficiency: recent development and guidance on clinical management. *Arch Dis Child*. 2015;100:667–72.
58. Davies EG. Immunodeficiency in DiGeorge syndrome and options for treating cases with complete athymia. *Front Immunol*. 2013;4:322.
59. Janda A, Sedlacek P, Honig M, Friedrich W, Champagne M, Matsumoto T, et al. Multicenter survey on the outcome of transplantation of hematopoietic cells in patients with the complete form of DiGeorge anomaly. *Blood*. 2010;116(13):2229–36.
60. Markert ML, Devlin BH, Chinn IK, McCarthy EA. Thymus transplantation in complete DiGeorge anomaly. *Immunol Res*. 2009;44(1–3):61–70.
61. Markert ML, Devlin BH, Alexieff MJ, Li J, McCarthy EA, Gupton SE, et al. Review of 54 patients with complete DiGeorge anomaly enrolled in protocols for thymus transplantation: outcome of 44 consecutive transplants. *Blood*. 2007;109(10):4539–47.
62. Albuquerque A, Marques JG, Silva SL, Ligeiro D, Devline BH, Dutriex J, et al. Human FOXN1-deficiency is associated with $\alpha\beta$ double-negative and FoxP3+ T-cell expansions that are distinctly modulated upon thymic transplantation. *PLoS One*. 2012;7(5): e37042.
63. Levy E, Neven B, Entz-Werle N, Cribier B, Lipsker D. Post-thymus transplant vitiligo in a child with Foxn1 deficiency. *Ann Dermatol Venereol*. 2012;139(6–7):468–71.
64. Clark RA, Yamanaka K, Bai M, Dowgiert R, Kupper TS. Human skin cells support thymus-independent T cell development. *J Clin Invest*. 2005;115(11):3239–49.
65. Palamaro L, Guarino V, Scalia G, Antonini D, De Falco L, Bianchino G, et al. Human skin-derived keratinocytes and fibroblasts co-culture on 3D poly ϵ -caprolactone scaffold support in vitro HSCs differentiation into T-lineage committed cells. *Int Immunol*. 2013;25(12):703–14.
66. Petrie HT. Role of thymic organ structure and stromal composition in steady-state postnatal T-cell production. *Immunol Rev*. 2002;189:8–19.
67. Petrie HT, Van Ewijk W. Thymus by numbers. *Nat Immunol*. 2002;3(7):604–5.