

Coverage of exposed hardware after lower leg fractures with free flaps or pedicled flaps

N. FALLICO, F. SOMMA, E. CIGNA, L.A. DESSY, M. TARALLO, D. RIBUFFO

Division of Plastic and Reconstructive Surgery, "Sapienza" University of Rome, Rome, Italy

Abstract. – **OBJECTIVE:** The placement of osteosynthetic materials in the leg may be complicated by hardware exposure. Successful soft tissue reconstruction often provides a critical means for limb salvage in patients with hardware exposure in the leg. Free flaps are currently considered the standard surgical procedure for soft tissue coverage of the wounds with internal hardware exposure. However, to date, no conclusive literature shows the superiority of a specific type of flap.

MATERIALS AND METHODS: The current review compares data from the literature concerning outcomes and complications of free and pedicled flaps for exposed osteosynthetic material preservation in the leg.

RESULTS: A total of 81 cases from twelve different articles presenting internal hardware exposure of the leg were analyzed in our study. Thirty-two patients underwent immediate reconstructive surgery with pedicled flaps, while forty-nine patients underwent free flap reconstruction. The overall survival rate for pedicled flaps was 96.77%, while for free flaps it was 97.77%. The overall implant preservation rate was 78.12% for pedicled flaps and 53.33% for free flaps. With reference to postoperative complications, the overall complication rate was 46.87% for pedicled flaps and 10.20% for free flaps.

CONCLUSIONS: No significant difference was found in terms of overall flap survival. However, a significant difference was found regarding successful implant preservation (78.12% in the pedicled flap group vs. 53.33% in the free flap group). In particular, the first observation appears to be in contrast with the current trend of considering the free flaps the first choice procedure for soft tissue coverage of the wounds with internal hardware exposure. Nevertheless, a higher occurrence of postoperative complications was observed in the pedicled flap group (46.87% vs. 10.20%). The choice of the most appropriate reconstructive procedure should take into account several issues including the size of the wounds with internal hardware exposure, the possibility of soft tissue coverage with pedicled flaps, the availability of recipient vessels,

general conditions of the patients (such as age, diabetes, smoking history), patients' preference and presence of a microsurgical team. However, according to the results of this review, we believe that pedicled flap reconstruction should be reconsidered as a valid alternative procedure for skin tissue loss with hardware exposure whenever it is possible.

Key Words:

Hardware exposure, Soft tissue coverage, Leg, Free flap, Pedicled flap.

Introduction

The placement of osteosynthetic materials is a common procedure for the open reduction internal fixation (ORIF) of fractures in the leg¹. However, this procedure may be complicated by exposure of the hardware^{2,3}. Traditionally, the postoperative management of wound dehiscence with hardware exposure consists of wound irrigation and debridement, antibiotic administration and, possibly, removal of the hardware and its replacement with external fixators. Soft tissue reconstruction is usually performed in a later stage. However, several studies have shown the possibility of a single-stage procedure consisting of wound debridement and soft tissue reconstruction either with pedicle or free flaps without internal hardware removal^{4,7}. Free flaps are currently considered the standard surgical procedure for soft tissue coverage of the wounds with internal hardware exposure. However, to date, there is no conclusive literature that shows the superiority of a specific type of flap.

The following review includes case series of patients affected by wound dehiscence with hardware exposure in the leg that underwent soft tissue reconstruction with free or pedicled flaps and aims at investigating which of these flaps is best suited for tissue coverage.

Materials and Methods

A literature review on soft tissue reconstruction for wound dehiscence with hardware exposure in the leg was performed using PubMed search engine. The aim of our investigation was to compare the efficacy of pedicled flaps vs. free flaps in preserving the hardware.

Inclusion criteria for article selection were: papers published no more than 15 years ago, presenting cases of hardware exposure on the leg without hardware removal, and soft tissue reconstruction with either pedicled or free flaps.

The keywords used for the research were: Internal hardware exposure, immediate reconstruction, leg fracture, pedicled flaps, free flaps. The search words were entered in PubMed central and appropriate abstracts reviewed. Relevant full text articles were retrieved and perused. Cross references from these articles were also reviewed. Articles presenting alternative methods of wound closure without hardware removal were also included. Review articles were excluded.

Bibliographies were reviewed to identify additional articles relevant to the topic.

Results

A total of 81 cases from twelve different articles presenting internal hardware exposure of the leg were analyzed in our study⁸⁻¹⁹.

Thirty-two patients underwent immediate reconstructive surgery with pedicled flaps, while forty-nine patients underwent free flap reconstruction. Eleven cases underwent Vacuum-Assisted Closure (VAC) therapy preoperatively.

Details of reconstructive procedures are shown in Tables I and II.

In particular, recovery time ranges from 20 days to 18 months. The overall survival rate for pedicled flaps was 96.77%, while for free flaps it was 97.77%. The overall implant salvage rate was 78.12% for pedicled flaps and 53.33% for free flaps.

With reference to postoperative complications, the overall complication rate was 46.87% for pedicled flaps and 10.20% for free flaps (Table I). In particular, the following complications were recorded for reconstructions with pedicled flaps: 1 case of total flap necrosis (3.12%), 4 cases of partial flap necrosis (12.5%), 7 cases of fistula (21.87%), 2 cases of infection (6.25%), 2

cases of dehiscence (6.25%), 7 cases required hardware removal (21.87%). Patients reconstructed with free flaps presented the following complications: 1 case of total flap necrosis (2.04%), 2 cases of thrombosis (4.08%), 2 cases of infection, one of which consisting of a sub-muscular abscess (4.08%), 2 cases required hardware removal (4.08%), one of which underwent later amputation, and 6 cases required amputation (12.24%).

Discussion

Successful soft tissue reconstruction often provides a critical means for limb salvage in patients with hardware exposure in the leg. The use of well-vascularized flaps provides soft tissue coverage, obliterates dead space, and controls the infection²⁰. Free flaps are currently considered the standard surgical procedure for soft tissue coverage of the wounds with internal hardware exposure^{8,21}. However, to date, there is no conclusive literature that shows the superiority of a specific type of flap. The location of the defect plays a role in the choice between a pedicled or free transfer.

Several free flaps have been used for coverage of wounds in the lower extremities. The *latissimus dorsi* muscle flap and the gracilis muscle flap^{14,20} provide a large mass of well-vascularized tissue, especially when dead space presents. The anterolateral thigh fasciocutaneous flap can provide a large skin paddle nourished by a long and large-caliber pedicle²², and is now used more than the forearm flap (Figure 1 A-B).

However, free flaps may have some disadvantages such as the bulkiness and the possible donor-site morbidity. Moreover, all free flaps have the common drawback of the difficulty of choosing the recipient vessels because of the poor local wound condition in the lower extremity.

There are also many pedicled flaps for soft tissue reconstruction in lower extremities, such as local fasciocutaneous flaps (as described by Ponten), the sural flap or reverse sural flap (Figure 2 A-B), the gastrocnemius flap, the saphenous fasciocutaneous flap, the soleus or hemisoleus flap, and the lateral supramalleolar flap, and the perforator-based propeller flap²³⁻²⁹. However, the selection of the flaps depends on the availability of the donor sites, which are mainly located around the injured area.

Table 1. Comparison of post-operative course after free/pedicled flap cover of exposed osteosynthetic material in the distal leg

	Number of patients and type of pedicled/free flap cover	Complications	Duration of post-primary surgery to wound breakdown	Duration of post-wound breakdown to flap cover	Duration of post-primary surgery to flap cover	Further surgeries	Eventual flap survival	Success/failure of implant preservation
Verhelle et al ⁷	4 – Gracilis flap 1 – Medial adipofascial flap	1 fistula				1 hardware removal		1 Failure
Vaienti et al ⁸	4 – Sural fasciomuscular flap	1 fistula 1 dehiscence partial necrosis	3-20 days (mean 12.66)		30 days	1 hardware removal	4 yes	3 Success, 1 failure
Vaienti et al ⁹	7 – Sural fasciomuscular flap 3 – Medial gastrocnemius flap 1 – Soleus flap 1 – Perforator flap	3 fistula 1 dehiscence 1 partial necrosis 1 fistula	5 months (mean)	8 months (mean)	13 months (mean)	1 debridement 1 hardware removal	7 yes	6 success, 1 failure
Temmen et al ¹⁰	1 – ALT flap 3 – Gracilis flap	1 fistula 1 total necrosis				1 hardware removal 1 hardware removal 1 sural fasciocutaneous flap	3 yes 1 yes 1 no	2 Success, 1 failure 1 Failure 1 Success
Wen et al ¹¹	7 – VAC + reversed saphenous neurocutaneous perforator flap	1 thrombosis 1 flap ischemia 1 partial necrosis	4 weeks-20 years	7-26 days		2 harvest of proximal gracilis	1 yes 3 yes 7 yes	1 Success 3 Success 7 Success
Zhang et al ¹²	1 – Musculocutaneous flap of the saphenous nerve and great saphenous vein + medial gastrocnemius flap + soleus flap	3 days					yes	Success
Viol et al ¹³	1 – ALT flap 1 – LD flap	1 Submuscular abscess	1 year			1 debridement and hardware removal followed by amputation for continued infection	1 yes 1 no	1 yes 1 no
	1 – VAC + LD flap						1 yes	1 Yes

Table continued

Table 1 (Continued). Comparison of post-operative course after free/pedicled flap cover of exposed osteosynthetic material in the distal leg

	Number of patients and type of pedicled/free flap cover	Complications	Duration of post-primary surgery to wound breakdown	Duration of post-wound breakdown to flap cover	Duration of post-primary surgery to flap cover	Further surgeries	Eventual flap survival	Success/failure of implant preservation
Pu1 ⁴	3 – VAC + combined medialgastrocnemius and medial hemisoleus muscle flap				Within 10 days		3 yes	3 Success
Tan et al ¹⁵	2 – Free gracilis flap	1 infection	2-44 days (mean 16.83)	6-30 days (mean 14.66)	8-63 days (mean 31.5)	1 hardware removal	2 yes	1 Failure, 1 Success
Yazar et al ¹⁶	4 – Sural flap	2 infection	21 days			2 hardware removal	4 yes	2 Failure, 2 Success
Patel et al ¹⁷	1 – Groin flap 21 – Rectus abdominis flap 7 – Gracilis flap					5 late amputation	yes 34 yes	Success 14 Failure, 7 Success
Ribuffo et al ¹⁸	4 – ALT flap 1 – Lateral arm flap 1 – Radial forearm flap 1 – Radial forearm flap	Venous thrombosis				1 skin graft	yes	3 Failure, 4 Success 2 Failure, 2 Success 1 Success 1 Success Success

Table II. Details of reconstructive procedures.

	Operative time	Duration of hospital stay	Recovery time	Full weight bearing	Length of follow-up (months)
Verhelle et al ⁷	3-4:25 hours (mean 3:40) – gracilis flap	10-31 days (mean 16) – gracilis flap			16-38 (mean 26) – gracilis flap
Vaienti et al ⁸	1:15-2:05 (mean 1:35) – medial adipose-fascial flap	7-12 days (mean 10) – medial adipose-fascial flap	20-60 days (mean 32.5)	10-40 days (mean 23.5)	19-47 (mean 30) – medial adipose-fascial flap
Vaienti et al ⁹					7-24 (mean 12.5)
Temmen et al ¹⁰			9-18 months	9 months	12-18
Wen et al ¹¹			4-6 months (mean 4.7)		8-14 (mean 10.6)
Zhang et al ¹²					5
Viol et al ¹³		5 days			12-24
Pu ¹⁴					60
Tan et al ¹⁵					14.7-51.4 (mean 26.08)
Yazar et al ¹⁶				16 months	36
Patel et al ¹⁷					0.3-7 years (mean 3.2)
Ribuffo et al ¹⁸					

According to the literature, soft tissue necrosis after internal fixation with the conventional plate-screw system is a common complication². The main risks of internal hardware exposure are infections, osteomyelitis and non-unions.

According to Viol et al³⁰, important prognostic factors for the success of management of exposed hardware are the duration of exposure and the duration of infection. In particular, better results are achieved when debridement and soft-tissue coverage are performed within 2 to 3 weeks

after exposure of the hardware and higher rates of hardware salvage are observed if the infection occurred within 2 weeks of the original operation.

In case of infection, the vacuum-assisted closure (VAC) can be used before surgery in order to obtain a more favorable preoperative condition¹¹. The use of the VAC therapy may reduce the need for flap coverage, alter the type of flap required or even eliminate the need for soft tissue coverage with flaps.

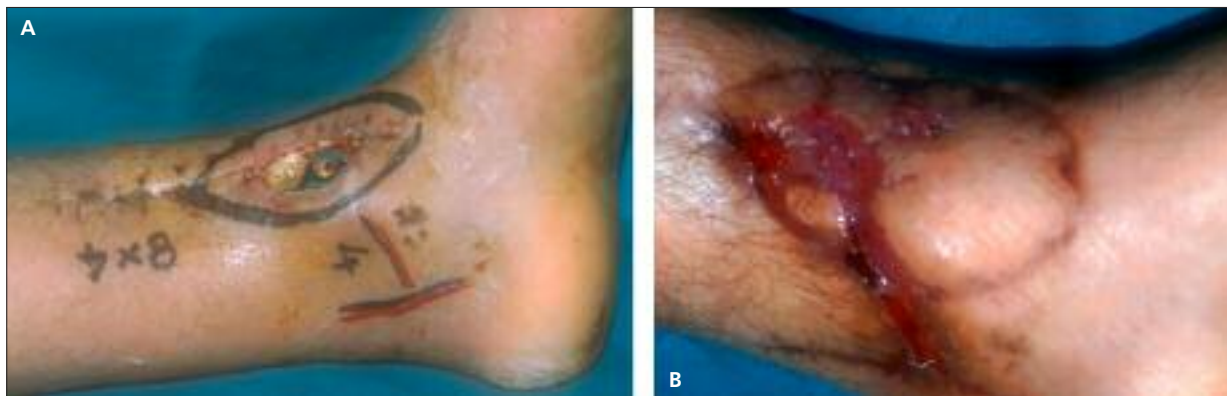


Figure 1. **A**, Trauma to the lower leg with hardware exposure. **B**, Reconstruction with a free forearm flap, which suffered from marginal necrosis.

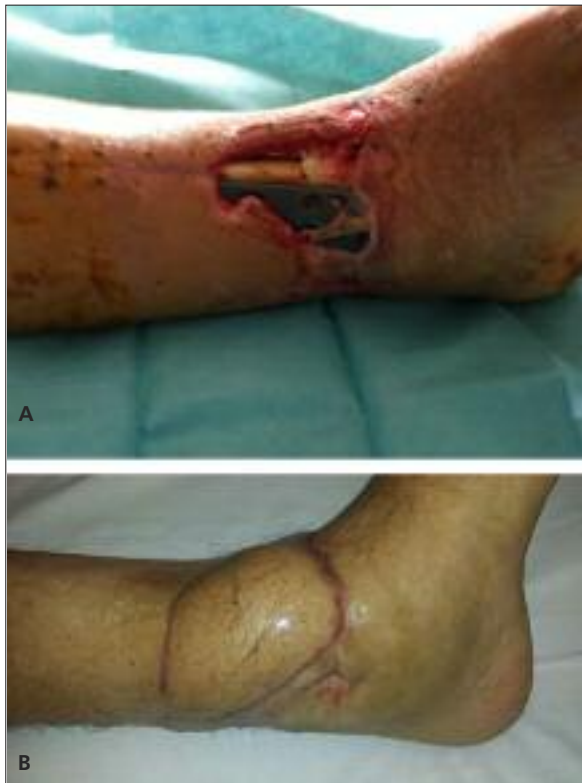

Figure 2. *A*, Trauma to the lower leg with hardware exposure. *B*, Reconstruction with a sural flap.

The most important data emerging from our review are two: the higher implant preservation rate in the pedicled flap group compared to the free flap group (78.12% vs. 53.33%) and the higher prevalence of postoperative complications in the pedicled flap group (46.87% vs. 10.20%). In particular, the first observation appears to be in contrast with the current trend of considering the free flaps the first choice procedure for soft tissue coverage of the wounds with internal hardware exposure. This is probably due to the fact that the choice of a pedicled flap is reserved for less complicated cases with limited tissue loss. Nevertheless, the choice of the more appropriate surgical procedure should be evaluated singularly according to the general and local conditions of the patient, keeping in mind that the two are both valid options for soft tissue coverage in case of hardware exposure.

Conclusions

The exposure of osteosynthetic material with skin tissue loss is a common complication that

plastic surgeons encounter. Reconstructive strategies mainly consist of a pedicled or free flap reconstruction. The current review compares data from the literature in terms of outcomes and complications of each procedure. No significant difference was found in terms of overall flap survival. However, a significant difference was found in terms of successful implant preservation.

With reference to postoperative complications, patients reconstructed with pedicled flaps experienced a higher number of complications. On the other hand, operative time and hospital stay are definitely higher for free flap reconstruction, with an increase in costs.

The choice of the most appropriate reconstructive procedure should take into account several issues including the size of the wounds with internal hardware exposure, the possibility of soft tissue coverage with pedicled flaps, the availability of recipient vessels, general conditions of the patients (such as age, diabetes mellitus, smoking history), patients' preference and presence of a microsurgical team. However, according to the results of this review, we believe that pedicled flap reconstruction should be reconsidered as a valid alternative procedure for skin tissue loss with hardware exposure whenever it is possible.

Conflict of Interest

The Authors declare that there are no conflicts of interest.

References

- 1) MA H, WANG C, WEI Q, LI ZH, YU BQ. Double plating for the treatment of distal tibia and fibula fractures: case series of twenty five patients. *Eur Rev Med Pharmacol Sci* 2013; 17: 2250-2253.
- 2) NAMAZI H, MOZAFFARIAN K. Awful considerations with LCP instrumentation: a new pitfall. *Arch Orthop Trauma Surg* 2007; 127: 573-575.
- 3) RONGA M, LONGO UG, MAFFULLI N. Minimally invasive locked plating of distal tibia fractures is safe and effective. *Clin Orthop Relat Res* 2000; 468: 975-982.
- 4) PUGH KJ, WOLINSKY PR, McANDREW MP, JOHNSON KD. Tibial pilon fractures: a comparison of treatment methods. *J Trauma* 1999; 47: 937-941.
- 5) WYRSCH B, McFERRAN MA, McANDREW M, LIMBIRD TJ, HARPER MC, JOHNSON KD, SCHWARTZ HS. Operative treatment of fractures of the tibial plafond. A randomized, prospective study. *J Bone Joint Surg Am* 1996; 78: 1646-1657.

- 6) MCFERRAN MA, SMITH SW, BOULAS HJ, SCHWARTZ HS. Complications encountered in the treatment of pilon fractures. *J Orthop Trauma* 1992; 6: 195-200.
- 7) POLLAK A, MCCARTHY ML, BURGESS AR. Short-term wound complications after application of flaps for coverage of traumatic soft tissue defects about the tibia. *J Bone Joint Surg* 2000; 82-A: 1681-1691.
- 8) VERHELLE N, VRANCKX J, VAN DEN HOF B, HEYMANS O. Bone exposure in the leg: is a free muscle flap mandatory? *Plast Reconstr Surg* 2005; 116: 170-177; discussion 178-181.
- 9) VAIENTI L, DI MATTEO A, GAZZOLA R, PIERANNUNZII L, PALITTA G, MARCHESI A. First results with the immediate reconstructive strategy for internal hardware exposure in non-united fractures of the distal third of the leg: case series and literature review. *J Orthop Surg Res* 2012; 7: 30.
- 10) VAIENTI L, DI MATTEO A, GAZZOLA R, RANDELLI P, LONIGRO J. Distally based sural fasciomusculocutaneous flap for treatment of wounds of the distal third of the leg and ankle with exposed internal hardware. *J Orthopaed Traumatol* 2012; 13: 35-39.
- 11) TEMMEN TM, PEREZ J, SMITH DJ. Transverse splitting of the gracilis muscle free flap: Maximal use of a single muscle. *Microsurgery* 2011; 31: 479-483.
- 12) WEN G, WANG CY, CHAI YM, CHENG L, CHEN M, YI-MIN L. Distally based saphenous neurocutaneous perforator flap combined with vac therapy for soft tissue reconstruction and hardware salvage in the lower extremities. *Microsurgery* 2013; 33: 625-630.
- 13) ZHANG F, ZHANG CC, LIN S, ZHANG G, ZHENG H. Distally based saphenous nerve-great saphenous veno-fasciocutaneous compound flap with nutrient vessels: microdissection and clinical application. *Ann Plast Surg* 2009; 63: 81-88.
- 14) VIOL A, PRADKA SP, BAUMEISTER SP, WANG D, MOYER KE, ZURA RD, OLSON SA, ZENN MR, LEVIN SL, ERDMANN D. Soft-tissue defects and exposed hardware: a review of indications for soft-tissue reconstruction and hardware preservation. *Plast Reconstr Surg* 2009; 123: 1256-1263.
- 15) PU LL. Soft-tissue coverage of an extensive mid-tibial wound with the combined medial gastrocnemius and medial hemisoleus muscle flaps: the role of local muscle flaps revisited. *J Plast Reconstr Aesthet Surg* 2010; 63: e605-610.
- 16) TAN KJ, LIM CT, LIM AY. The use of muscle flaps in the salvage of infected exposed implants for internal fixation. *J Bone Joint Surg Br* 2010; 92: 401-405.
- 17) YAZAR S, LIN CH, LIN YT, ULUSAL AE, WEI FC. Outcome comparison between free muscle and free fasciocutaneous flaps for reconstruction of distal third and ankle traumatic open tibial fractures. *Plast Reconstr Surg* 2006; 117: 2468-2475; discussion 2467-2476.
- 18) PATEL KM, SERUYA M, FRANKLIN B, ATTINGER CE, DUCIC I. Factors associated with failed hardware salvage in high-risk patients after microsurgical lower extremity reconstruction. *Ann Plast Surg* 2012; 69: 399-402.
- 19) RIBUFFO D, CHIUMMARIELLO S, CIGNA E, SCUDERI N. Salvage of a free flap after late total thrombosis of the flap and revascularisation. *Scand J Plast Reconstr Surg Hand Surg* 2004; 38: 50-52.
- 20) LE NEN D, LE GUILLOU E, CARO P, DUBRANA F, POUREYRON Y, LEFEVRE C. Use of muscular flaps for the treatment of open fractures of limbs. Apropos of 42 cases. *Rev Chir Orthop Reparatrice Appar Mot* 1997; 83: 423-434.
- 21) PU LL. Soft-tissue reconstruction of an open tibial wound in the distal third of the leg: A new treatment algorithm. *Ann Plast Surg* 2007; 58: 78-83.
- 22) DEMIRTAS Y, KELAHEMETOGLU O, CIFCI M, TAYFUR V, DEMIR A, GUNEREN E. Comparison of free anterolateral thigh flaps and free muscle-musculocutaneous flaps in soft tissue reconstruction of lower extremity. *Microsurgery* 2010; 30: 24-31.
- 23) PONTÉN B. The fasciocutaneous flap: its use in soft tissue defects of the lower leg. *Br J Plast Surg* 1981; 34: 215-220.
- 24) TSAI J, LIAO HT, WANG PF, CHEN CT, LIN CH. Increasing the success of reverse sural flap from proximal part of posterior calf for traumatic foot and ankle reconstruction: Patient selection and surgical refinement. *Microsurgery* 2013; 33: 342-349.
- 25) JENTZSCH T, ERSCHBAMER M, SEELI F, FUCHS B. Extensor function after medial gastrocnemius flap reconstruction of the proximal tibia. *Clin Orthop Relat Res* 2013; 471: 2333-2339.
- 26) KRISHNAMOORTHY VP, INJA DB, ROY AC. Knee extensor loss and proximal tibial soft tissue defect managed successfully with simultaneous medial gastrocnemius flap, saphenous fasciocutaneous flap and medial hemisoleus flap: a case report. *J Med Case Rep* 2013; 7: 76.
- 27) VOCHÉ P, MERLE M, STUSSI JD. The lateral supra-malleolar flap: experience with 41 flaps. *Ann Plast Surg* 2005; 54: 49-54.
- 28) RIOS-LUNA A, FAHANDZEH-SADDI H, Villanueva-Martinez M, Lopez AG. Pearls and tips in coverage of the tibia after a high energy trauma. *Indian J Orthop* 2008; 42: 387-394.
- 29) DONG KX, XU YQ, FAN XY, XU LJ, SU XX, LONG H, XU LQ, HE XQ. Perforator pedicled propeller flaps for soft tissue coverage of lower leg and foot defects. *Orthop Surg* 2014; 6: 42-46.
- 30) VIOL A, PRADKA SP, BAUMEISTER SP, WANG D, MOYER KE, ZURA RD, OLSON SA, ZENN MR, LEVIN SL, Erdmann D. Soft-tissue defects and exposed hardware: a review of indications for soft-tissue reconstruction and hardware preservation. *Plast Reconstr Surg* 2009; 123: 1256-1263.