

*Full Length Research Paper*

# Biochemical, haematological and histopathological studies of extract of *Ageratum conyzoides* L. in Sprague Dawley rats

Abiodun Humphrey Adebayo<sup>1,2\*</sup>, Guang-Zhi Zeng<sup>1</sup>, Jun-Ting Fan<sup>1</sup>, Chang-Jiu Ji<sup>1</sup>, Wen-Jun He<sup>1</sup>, Jun-Ju Xu<sup>1</sup>, Yu-Mei Zhang<sup>1</sup>, Afolabi Akintunde Akindahunsi<sup>3</sup>, Roseline Kela<sup>4</sup> and Ning-Hua Tan<sup>1</sup>

<sup>1</sup>State Key Laboratory of Phytochemistry and Plant Resources in West China, Kunming Institute of Botany, Chinese Academy of Sciences, Kunming 650204, China.

<sup>2</sup>Department of Biological Sciences, College of Science and Technology, Covenant University, P. M. B. 1023, Canaanland, Ota, Ogun State, Nigeria.

<sup>3</sup>Department of Biochemistry, Federal University of Technology, Akure, Ondo State, Nigeria.

<sup>4</sup>Energy Commission of Nigeria, P. M. B. 358, Garki Central Area, Abuja, FCT, Nigeria.

Accepted 15 September, 2010

This study was conducted to evaluate the safety potential of the leaf extract of *Ageratum conyzoides* Linnaeus in Sprague Dawley (SD) rats using biochemical, haematological and histological indices of toxicity. Four groups of seven male SD rats per group were used for the study. To group A was administered 0.25% CMC-Na/ kg body weight and was used as the control group, while groups B, C and D were respectively administered with 500, 1000 and 1500 mg/kg body weight of the ethanolic leaf extract of *A. conyzoides* by gastric intubation for 14 days. Animals were subsequently anaesthetized, blood samples were collected for biochemical and haematological assays; organs were isolated and weighed, while the liver, kidney and spleen were processed for histopathological studies. Aspartate amino transferase, lactate dehydrogenase, creatine kinase and alkaline phosphatase were significantly ( $p < 0.05$ ) reduced in the groups treated with 1000 and 1500 mg/kg body weight of the extract. Furthermore, there was a significant ( $p < 0.05$ ) elevation in white blood cell count, mean platelet volume and % platelet distribution width. Histopathological studies indicated various degrees of hepatocellular necrosis in all the treated groups accompanied by significant increases in the weight of liver and spleen. The results showed that the ethanolic leaf extract of *A. conyzoides* significantly alters the biomarkers of cardiac and skeletal muscle disorders, and higher doses could induce liver cell injury.

**Key words:** *Ageratum conyzoides*, Asteraceae, liver markers, histopathological study, toxicological study.

## INTRODUCTION

Plants have been used in Africa for many centuries and today, almost all parts of the world use medicinal plants for the treatment of different types of diseases (Adebayo et al., 2006). *Ageratum conyzoides* Linnaeus belongs to the family and tribe of Asteraceae and Eupatoriaceae

respectively. The plant is native to Central America, Caribbean, Florida (USA), Southeast Asia, South China, India, West Africa (including Nigeria), Australia and South America (Kong, 2006; Okunade, 2002). It is traditionally called "ufu opioko" and "otogo" by the Igedes in Benue State, Nigeria (Igoli et al., 2005). In Southwestern Nigeria, it is known as "Imí esu" (Oladejo et al., 2003). *A. conyzoides* has been used in folklore for the treatment of fever, pneumonia, cold, rheumatism, spasm, headache and curing wounds (Shirwaikar et al., 2003; Ming, 1999). Its gastroprotective (Shirwaikar et al., 2003), antibacterial,

\*Corresponding authors. E-mail: [nhtan@mail.kib.ac.cn](mailto:nhtan@mail.kib.ac.cn), [aadebayo@covenantuniversity.com](mailto:aadebayo@covenantuniversity.com). Tel: +86 871 522 3800, +234 803 635 7197. Fax: +86 871 5223800.

anti-inflammatory, antianalgesic and antipyretic (Okunade, 2002) and anticonvulsant (Whittle and Turner, 1981) properties have been reported. *A. conyzoides* has been reported to possess activities against protozoan parasites like plasmodium (Madureira et al., 2002) and trypanosomes (Freiburghaus et al., 1996). Its antischistosomal (El Sheikh et al., 1990), anticancer, antiradical (Adebayo et al., 2010) and anticocidal activities (Nweze and Obiwulu, 2009) have been reported. *A. conyzoides* has been widely reported to contain many bioactive compounds which are responsible for its diverse biological activities. Among them are flavonoids, tannins, saponins, triterpenoids, sesquiterpenes, chromenes, chromones, benzofurans, etc (Moreira et al., 2004, 2007; Okunade, 2002). Precocenes I and II are the principal components of the plant. Previous studies reported on the plant recommended for further work on the histological assessment of the plant with regards to its hepatotoxicity risk (Igboasoiyi et al., 2007; Moura et al., 2005). Thus, the insufficient information on the toxicity potential of *A. conyzoides* led to the present investigation. The study therefore is aimed at investigating the biochemical, haematological and histopathological effects of ethanolic leaf extract of *A. conyzoides* in Sprague Dawley (SD) rats.

## MATERIALS AND METHODS

### Plant material

The leaves of *A. conyzoides* L. were collected between November, 2007 and January, 2008 from Covenant University, Ota environs. A voucher specimen (PCGH 436) was deposited at the Department of Pharmacognosy, University of Lagos, Nigeria.

### Extraction of the plant

The leaves of *A. conyzoides* were collected and air dried in the laboratory for two weeks after which they were blended into fine powder. Four hundred and thirty-five grams (435 g) of the powder were extracted with 95% ethanol for 18 h at 85°C and concentrated in a rotary evaporator (Buchi 461, Switzerland) at 50°C to afford 78 g (17.9% yield) of the crude extract (Adebayo et al., 2006).

### Experimental animals

Twenty-eight male SD rats, specific pathogen free, aged 7 to 9 weeks and weighing 220 - 265 g were purchased from Vital River Laboratories, Beijing, China and transported by air to the Animal House of the Institute of Toxicology, Kunming Medical University, Kunming, China. They were kept under standard environmental conditions (25 ± 21 °C; 12/12 h light/dark cycle). Four animals were housed in each cage and fed with standard diet (obtained from Yunnan Key Laboratory of Animal Nutrition and Feed Stuff, Yunnan Agriculture University, China) and water *ad libitum*. The animals were allowed to acclimatize for two weeks before beginning the experiment. For experimentation, the animals were fasted overnight and 7 animals were included in each group. All experimental

protocols were in compliance with the Institute of Toxicology, Kunming Medical University Ethics Committee on Research in Animals as well as other internationally accepted principles for laboratory animal use and care.

### Experimental design

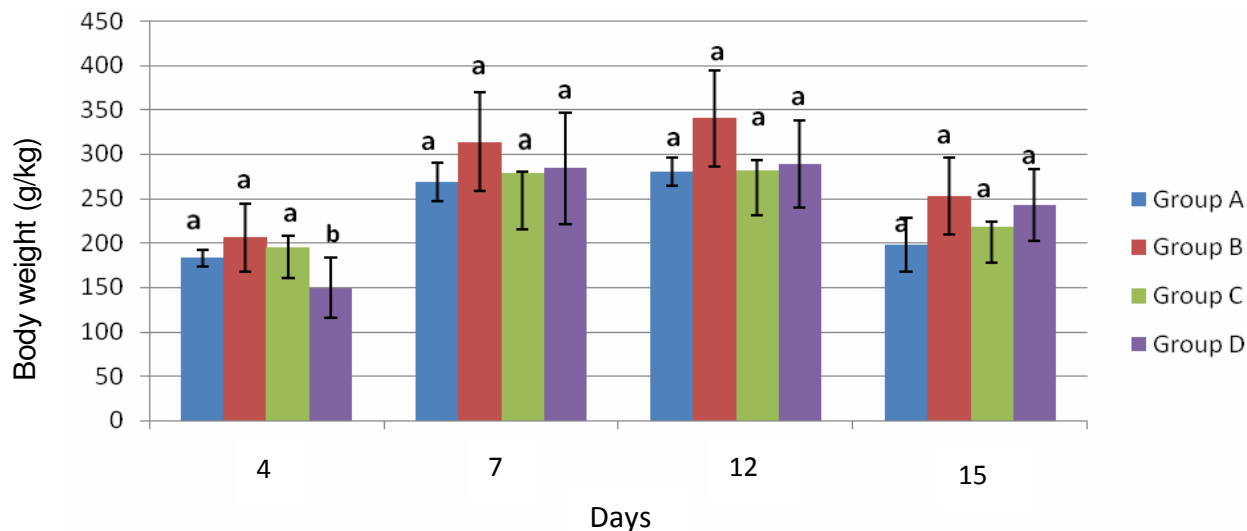
The experimental design was the modified versions of that reported by (Igboasoiyi et al., 2007; Moura et al., 2005). Four groups A, B, C and D were used for the sub-chronic experiment. Groups B, C and D were respectively administered 500, 1000 and 1500 mg/kg body weight of ethanolic leaf extract of *A. conyzoides* (dissolved in 0.25% CMC-Na) for 14 d. Group A which served as the control group was administered 0.25% CMC-Na per kg body weight. After this treatment period, animals were injected intravenously with 0.2 ml/kg body weight of phenobarbital (sedative). They were subsequently dissected from the abdominal region; blood was collected from the pulmonary vein using the vacutainer system into EDTA anti-coagulated and non anti-coagulated tubes. The organs (liver, kidney, heart, spleen, brain, lungs, thymus, testes, epididymis and adrenal gland) were also obtained for histological examination. The non-coagulated blood was allowed to clot at room temperature; the resultant clear part was centrifuged at 1500 x g for 10 min to obtain the serum; biochemical analyses were run immediately using the automated multi-item analyzer (TMS-1024, Tokyo Boeki Medical System Ltd., Japan). Similarly, the anticoagulated blood was immediately used for haematological assays using the automated haematology analyzer (ADVIA 60-OT, Bayer Corporation, Tarrytown, New York, USA).

### Biochemical and haematological assays

Commercial test kits obtained from Biosino Bio-Technology and Science Inc. Beijing, China were used for all biochemical parameters measured. Standard methods were used to estimate glucose (Trinder, 1969), aspartate aminotransferase (AST) (Bergmeyer et al., 1986a), alanine aminotransferase (ALT) (Bergmeyer et al., 1985b), alkaline phosphatase (ALP) (Tietz et al., 1983), lactate dehydrogenase (LDH), creatine kinase (CK) (Chemnitz et al., 1979), total protein (Weichselbaum, 1946), albumin (Doumas et al., 1971), total bilirubin (Doumas et al., 1973), urea (Krieg et al., 1986), creatinine (Larsen et al., 1971), triglycerides, cholesterol (Zoppi and Fellini, 1976) and HDL-cholesterol (European Atherosclerosis Society, 1992). These parameters were determined using the automated biochemical multi-item analyzer (TMS-1024; Tokyo Boeki Medical System Ltd., Japan). The whole blood was used to assay white blood cell count (WBC), red blood cell count (RBC), haemoglobin (HGB), haematocrit (HCT), mean cell volume (MCV), mean corpuscular hemoglobin (MCH), mean corpuscular hemoglobin concentration (MCHC), red cell distribution width (RDW), platelet count (PLT), mean platelet volume (MPV), percentage lymphocyte (% LYM), percentage monocyte (% MON), percentage granulocyte (% GRA), platelet distribution width (PDW) and plateletcrit (PCT). These parameters were determined by automated haematology system analyzer (ADVIA 60 Open Tube; Bayer Corporation, Tarrytown, New York, USA).

### Histopathological studies

The method as described by Aliyu et al. (2007) with slight modification was adopted. After blood collection, the liver, kidney and spleen were carefully dissected from the abdominal region. They were fixed in normal saline for 72 h and sliced into a thickness of 2.1 mm. The tissues were dehydrated with alcohol of graded concentrations. They were further treated with paraffin wax and



**Figure 1.** Weights of Sprague Dawley rats treated with ethanolic leaf extract of *A. conyzoides*. Values are represented as mean  $\pm$  SD of 7 replicates. Values on the same day with different letters differ significantly ( $p < 0.05$ ).

cast into blocks; sections of the tissues were then cut on a microtome to 5  $\mu$ m. These were later attached to a slide and allowed to dry. The sample slides were subsequently stained in haematoxylin-eosin and examined under a light microscope; photomicrographs of the samples were recorded.

### Statistical analyses

The differences among experimental and control groups were determined using SPSS for Window XP software programme (version 13.0). Group comparisons were done using the analysis of variance (ANOVA) test. Significant difference between control and experimental groups were assessed by least significant difference (LSD). All data were expressed as mean  $\pm$  deviations (SD);  $p$  values less than 0.05 were considered to be significant.

## RESULTS

### Animal weights and weight of organs

There was a considerable ( $p < 0.05$ ) weight loss on the fourth day in rats treated with extract of 1500 mg/kg body weight of *A. conyzoides*, this was later followed with an insignificant ( $p > 0.05$ ) weight gain during the remaining treatment duration (Figure 1).

There was significant increase in the weight of liver of rats in groups C ( $p < 0.01$ ) and D ( $p < 0.05$ ) treated with the leaf extract of *A. conyzoides* (Table 1). Similarly, a significantly ( $p < 0.05$ ) higher spleen was observed in group C of rats treated with the extract when compared with the control group. No significant ( $p > 0.05$ ) difference was observed in lungs, heart, thymus, adrenal cortex, brain, epididymis, kidney and testes for the groups treated with the ethanolic extract of *A. conyzoides*.

### Biochemical and haematological assays

Aspartate aminotransferase was significantly reduced in groups C ( $p < 0.01$ ) and D ( $p < 0.05$ ). There was no significant ( $p > 0.05$ ) difference in alanine aminotransferase. Alkaline phosphatase was markedly decreased in all the treated groups but group C was significantly different ( $p < 0.05$ ) from the control group (Table 2). Lactate dehydrogenase was significantly reduced ( $p < 0.05$ ) in groups C and D when compared with the control group (Table 3). Similarly, creatine kinase was significantly decreased in groups C and D ( $p < 0.05$ ) when compared with the control group. White blood cell was significantly higher ( $p < 0.05$ ) in group D than the control group.

There was a dose dependent increase in MPV concentration which was statistically significant ( $p < 0.05$ ) compared with the control group. Similarly, the % PDW showed a dose-dependent elevation in all the treated groups and significantly different ( $p < 0.05$ ) from the control group (Table 4).

### Histopathological studies

All groups treated with the ethanolic extract of *A. conyzoides* showed various degrees of hepatocellular necrosis on the liver sectioning when compared with the control group (Figure 2). Group B showed four areas of spotty hepatocellular necrosis (Figure 3).

Similarly, Group C had seven areas of spotty hepatocellular necrosis (Figure 4). Group D which was given the largest dose of 1500 mg/kg body weight of the extract had nine areas of spotty hepatocellular necrosis respectively (Figure 5). No significant damage was observed in rats kidney and spleen tissues treated with

**Table 1.** Effects of ethanolic leaf extract of *Ageratum conyzoides* on the weight of organs in SD rats.

Organs (g)	Group A	Group B	Group C	Group D
	(Control)	(500 mg/kg bw)	(1000 mg/kg bw)	(1500 mg/kg bw)
Thymus ( $\times 10^{-2}$ )	30.98 $\pm$ 3.13 <sup>a</sup> [11.11 $\pm$ 0.64] <sup>a</sup>	39.33 $\pm$ 2.96 <sup>a</sup> [13.48 $\pm$ 0.86] <sup>a</sup>	40.75 $\pm$ 5.89 <sup>a</sup> [13.70 $\pm$ 1.85] <sup>a</sup>	36.14 $\pm$ 4.83 <sup>a</sup> [13.08 $\pm$ 1.60] <sup>a</sup>
Adrenal gland ( $\times 10^{-2}$ )	5.45 $\pm$ 0.96 <sup>a</sup> [1.98 $\pm$ 0.32] <sup>a</sup>	5.19 $\pm$ 0.34 <sup>a</sup> [1.78 $\pm$ 0.10] <sup>a</sup>	5.60 $\pm$ 0.69 <sup>a</sup> [1.90 $\pm$ 0.22] <sup>a</sup>	5.11 $\pm$ 0.40 <sup>a</sup> [1.85 $\pm$ 0.12] <sup>a</sup>
Heart	0.96 $\pm$ 0.05 <sup>a</sup> [0.35 $\pm$ 0.01] <sup>a</sup>	0.95 $\pm$ 0.03 <sup>a</sup> [0.33 $\pm$ 0.01] <sup>a</sup>	0.99 $\pm$ 0.04 <sup>a</sup> [0.34 $\pm$ 0.01] <sup>a</sup>	0.94 $\pm$ 0.04 <sup>a</sup> [0.34 $\pm$ 0.01] <sup>a</sup>
Liver	7.81 $\pm$ 0.61 <sup>a</sup> [2.81 $\pm$ 0.09] <sup>a</sup>	8.84 $\pm$ 0.32 <sup>a</sup> [3.04 $\pm$ 0.06] <sup>a</sup>	10.66 $\pm$ 0.65 <sup>c</sup> [3.61 $\pm$ 0.20] <sup>c</sup>	9.54 $\pm$ 0.49 <sup>b</sup> [3.46 $\pm$ 0.14] <sup>c</sup>
Spleen	0.47 $\pm$ 0.03 <sup>a</sup> [0.17 $\pm$ 0.01] <sup>a</sup>	0.56 $\pm$ 0.03 <sup>a</sup> [0.19 $\pm$ 0.01] <sup>a</sup>	0.69 $\pm$ 0.06 <sup>b</sup> [0.23 $\pm$ 0.02] <sup>a</sup>	0.62 $\pm$ 0.09 <sup>a</sup> [0.23 $\pm$ 0.04] <sup>a</sup>
Lungs	1.14 $\pm$ 0.08 <sup>a</sup> [0.41 $\pm$ 0.02] <sup>a</sup>	1.24 $\pm$ 0.05 <sup>a</sup> [0.43 $\pm$ 0.01] <sup>a</sup>	1.29 $\pm$ 0.06 <sup>a</sup> [0.44 $\pm$ 0.01] <sup>a</sup>	1.28 $\pm$ 0.07 <sup>a</sup> [0.47 $\pm$ 0.03] <sup>b</sup>
Kidney	2.03 $\pm$ 0.12 <sup>a</sup> [0.74 $\pm$ 0.02] <sup>a</sup>	2.03 $\pm$ 0.05 <sup>a</sup> [0.70 $\pm$ 0.01] <sup>a</sup>	2.17 $\pm$ 0.05 <sup>a</sup> [0.73 $\pm$ 0.01] <sup>a</sup>	2.02 $\pm$ 0.09 <sup>a</sup> [0.73 $\pm$ 0.02] <sup>a</sup>
Brain	1.77 $\pm$ 0.05 <sup>a</sup> [0.65 $\pm$ 0.03] <sup>a</sup>	1.81 $\pm$ 0.04 <sup>a</sup> [0.62 $\pm$ 0.01] <sup>a</sup>	1.81 $\pm$ 0.03 <sup>a</sup> [0.61 $\pm$ 0.01] <sup>a</sup>	1.82 $\pm$ 0.05 <sup>a</sup> [0.66 $\pm$ 0.02] <sup>a</sup>
Testes	2.64 $\pm$ 0.11 <sup>a</sup> [0.97 $\pm$ 0.04] <sup>a</sup>	2.73 $\pm$ 0.08 <sup>a</sup> [0.94 $\pm$ 0.04] <sup>a</sup>	2.93 $\pm$ 0.10 <sup>a</sup> [0.99 $\pm$ 0.03] <sup>a</sup>	2.88 $\pm$ 0.12 <sup>a</sup> [1.04 $\pm$ 0.03] <sup>a</sup>
Epididymis	0.89 $\pm$ 0.04 <sup>a</sup> [0.32 $\pm$ 0.01] <sup>a</sup>	0.84 $\pm$ 0.04 <sup>a</sup> [0.29 $\pm$ 0.02] <sup>a</sup>	0.90 $\pm$ 0.02 <sup>a</sup> [0.31 $\pm$ 0.01] <sup>a</sup>	0.87 $\pm$ 0.06 <sup>a</sup> [0.31 $\pm$ 0.02] <sup>a</sup>

Values are represented as mean  $\pm$  SD of 7 replicates; values in parenthesis are % weight of organ with respect to the body weight of rats; Values on the same row followed by different superscript letters differ significantly (<sup>a</sup> p > 0.05, <sup>b</sup> p < 0.05, <sup>c</sup> p < 0.01 vs control).

**Table 2.** Levels of biochemical markers of liver injury in Sprague Dawley rats on ethanolic leaf extract of *A. conyzoides*.

Parameter	Group A	Group B	Group C	Group D
	(Control)	(500 mg/kg bw)	(1000 mg/kg bw)	(1500 mg/kg bw)
ALT (U/L)	48.60 $\pm$ 3.03 <sup>a</sup>	52.92 $\pm$ 3.17 <sup>a</sup>	49.40 $\pm$ 1.59 <sup>a</sup>	49.85 $\pm$ 4.62 <sup>a</sup>
AST (U/L)	109.66 $\pm$ 4.83 <sup>a</sup>	108.15 $\pm$ 4.49 <sup>a</sup>	89.49 $\pm$ 6.08 <sup>c</sup>	92.94 $\pm$ 3.95 <sup>b</sup>
ALP (U/L)	280.26 $\pm$ 12.20 <sup>a</sup>	245.66 $\pm$ 12.55 <sup>a</sup>	210.80 $\pm$ 17.06 <sup>b</sup>	255.75 $\pm$ 12.53 <sup>a</sup>
Total bilirubin ( $\mu$ mol/L)	3.06 $\pm$ 0.26 <sup>a</sup>	3.02 $\pm$ 0.43 <sup>a</sup>	2.80 $\pm$ 0.58 <sup>a</sup>	3.49 $\pm$ 0.25 <sup>a</sup>
Albumin (g/L)	36.81 $\pm$ 0.82 <sup>a</sup>	36.91 $\pm$ 0.34 <sup>a</sup>	36.74 $\pm$ 0.57 <sup>a</sup>	36.63 $\pm$ 0.63 <sup>a</sup>
Total protein (g/L)	58.51 $\pm$ 0.72 <sup>a</sup>	56.84 $\pm$ 0.78 <sup>a</sup>	57.71 $\pm$ 0.99 <sup>a</sup>	57.16 $\pm$ 1.18 <sup>a</sup>
Albumin/Globulin	1.72 $\pm$ 0.10 <sup>a</sup>	1.86 $\pm$ 0.05 <sup>a</sup>	1.76 $\pm$ 0.05 <sup>a</sup>	1.82 $\pm$ 0.10 <sup>a</sup>

Values represent mean  $\pm$  SD of 7 replicates. Values on the same row followed by different superscript letters differ significantly (<sup>a</sup> p > 0.005, <sup>b</sup> p < 0.05, <sup>c</sup> p < 0.01 vs control).

extracts of *A. conyzoides*.

## DISCUSSION

The safety of drugs and plant products for human use can

be determined using toxicological evaluation which is usually carried out in various experimental animals to predict toxicity and to provide guidelines for selecting a safe dose in humans. Analysis of blood parameters is relevant in risk evaluation as changes in the haematological system have higher predictive value for studies

**Table 3.** Some biochemical markers in sprague dawley rats on ethanolic leaf extract of *A. conyzoides*.

Parameter	Group A	Group B	Group C	Group D
	(Control)	(500 mg/kg bw)	(1000 mg/kg bw)	(1500 mg/kg bw)
LDH (U/gprot)	1010.47 ± 106.60 <sup>a</sup>	1105.59 ± 144.89 <sup>a</sup>	710.39 ± 130.48 <sup>b</sup>	630.85 ± 41.35 <sup>b</sup>
Creatine kinase (U/L)	588.167 ± 24.94 <sup>a</sup>	589.85 ± 49.29 <sup>a</sup>	443.93 ± 96.38 <sup>b</sup>	407.16 ± 41.85 <sup>b</sup>
Urea (mmol/L)	6.46 ± 0.18 <sup>a</sup>	6.89 ± 0.40 <sup>a</sup>	7.53 ± 0.34 <sup>a</sup>	7.14 ± 0.41 <sup>a</sup>
Creatinine (µmol/L)	24.77 ± 0.94 <sup>a</sup>	25.99 ± 0.72 <sup>a</sup>	26.18 ± 1.66 <sup>a</sup>	26.12 ± 0.99 <sup>a</sup>
Total Cholesterol (mmol/L)	1.45 ± 0.12 <sup>a</sup>	1.45 ± 0.09 <sup>a</sup>	1.41 ± 0.10 <sup>a</sup>	1.48 ± 0.07 <sup>a</sup>
HDL-Cholesterol (mmol/L)	1.05 ± 0.04 <sup>a</sup>	1.06 ± 0.08 <sup>a</sup>	1.01 ± 0.19 <sup>a</sup>	1.13 ± 0.08 <sup>a</sup>
Triglyceride (mmol/L)	0.38 ± 0.02 <sup>a</sup>	0.34 ± 0.05 <sup>a</sup>	0.30 ± 0.01 <sup>a</sup>	0.27 ± 0.05 <sup>a</sup>
Glucose (mmol/L)	6.01 ± 0.34 <sup>a</sup>	5.57 ± 0.51 <sup>a</sup>	6.64 ± 0.42 <sup>a</sup>	5.49 ± 0.33 <sup>a</sup>

Values represent mean ± SD of 7 replicates. Values on the same row followed by different superscript letters differ significantly (<sup>a</sup> p > 0.05, <sup>b</sup> p < 0.05 vs control).

**Table 4.** Haematological parameters in Sprague Dawley rats on ethanolic leaf extract of *A. conyzoides*.

Parameter	Group A	Group B	Group C	Group D
	(Control)	(500 mg/kg bw)	(1000 mg/kg bw)	(1500 mg/kg bw)
WBC (x 10 <sup>12</sup> /L)	4.73 ± 0.55 <sup>a</sup>	6.00 ± 0.47 <sup>a</sup>	5.73 ± 0.98 <sup>a</sup>	6.97 ± 0.76 <sup>b</sup>
RBC (x 10 <sup>12</sup> /L)	6.65 ± 0.16 <sup>a</sup>	6.48 ± 0.09 <sup>a</sup>	6.49 ± 0.12 <sup>a</sup>	6.33 ± 0.13 <sup>a</sup>
HGB (g/L)	140.00 ± 2.25 <sup>a</sup>	140.86 ± 2.61 <sup>a</sup>	140.00 ± 1.86 <sup>a</sup>	138.00 ± 3.32 <sup>a</sup>
HCT (L/L)	0.34 ± 0.01 <sup>a</sup>	0.33 ± 0.01 <sup>a</sup>	0.34 ± 0.0 <sup>a</sup>	0.32 ± 0.02 <sup>a</sup>
PLT (x 10 <sup>9</sup> /L)	989.00 ± 39.34 <sup>a</sup>	941.71 ± 47.54 <sup>a</sup>	953.00 ± 29.83 <sup>a</sup>	964.29 ± 38.83 <sup>a</sup>
PCT (x 10 <sup>-2</sup> L/L)	0.61 ± 0.03 <sup>a</sup>	0.57 ± 0.02 <sup>a</sup>	0.59 ± 0.02 <sup>a</sup>	0.60 ± 0.03 <sup>a</sup>
MCV (fL)	50.33 ± 0.49 <sup>a</sup>	51.57 ± 0.72 <sup>a</sup>	50.83 ± 0.54 <sup>a</sup>	52.14 ± 0.96 <sup>a</sup>
MCH (pg)	21.10 ± 0.30 <sup>a</sup>	21.67 ± 0.25 <sup>a</sup>	21.28 ± 0.30 <sup>a</sup>	21.81 ± 0.39 <sup>a</sup>
MCHC (g/L)	418.83 ± 3.66 <sup>a</sup>	419.43 ± 2.11 <sup>a</sup>	417.33 ± 1.67 <sup>a</sup>	418 ± 2.17 <sup>a</sup>
RDW (%)	12.93 ± 0.30 <sup>a</sup>	13.63 ± 0.17 <sup>a</sup>	13.50 ± 0.16 <sup>a</sup>	13.59 ± 0.26 <sup>a</sup>
MPV (fL)	5.89 ± 0.07 <sup>a</sup>	6.06 ± 0.10 <sup>a</sup>	6.17 ± 0.07 <sup>b</sup>	6.23 ± 0.12 <sup>b</sup>
PDW (%)	7.43 ± 0.08 <sup>a</sup>	7.93 ± 0.11 <sup>b</sup>	7.98 ± 0.08 <sup>b</sup>	8.13 ± 0.19 <sup>b</sup>
Lymphocyte (%)	87.12 ± 1.74 <sup>a</sup>	80.70 ± 2.74 <sup>a</sup>	87.93 ± 2.04 <sup>a</sup>	78.41 ± 4.44 <sup>a</sup>
Monocyte (%)	11.08 ± 1.32 <sup>a</sup>	16.99 ± 2.31 <sup>a</sup>	10.68 ± 1.71 <sup>a</sup>	17.16 ± 2.62 <sup>a</sup>
Granulocyte (%)	1.80 ± 0.58 <sup>a</sup>	2.31 ± 0.46 <sup>a</sup>	1.38 ± 0.35 <sup>a</sup>	4.43 ± 1.91 <sup>a</sup>

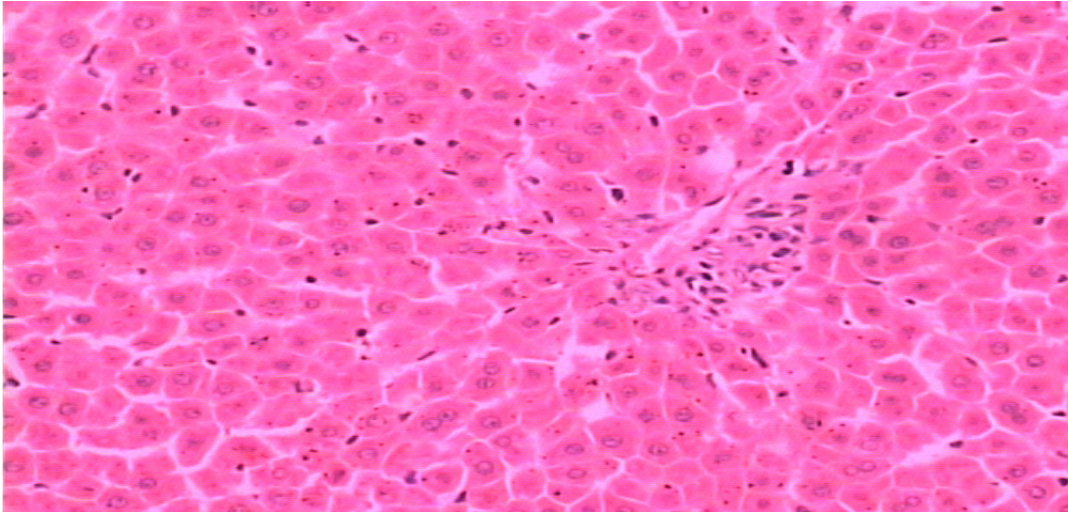
Values are represented as mean ± SD of 7 replicates. Values on the same row followed by different superscript letters differ significantly (<sup>a</sup> p > 0.05, <sup>b</sup> p < 0.05 vs control). White blood cell count (WBC), red blood cell count (RBC), haemoglobin (HGB), haematocrit (HCT), mean cell volume (MCV), mean corpuscular hemoglobin (MCH), mean corpuscular hemoglobin concentration (MCHC), red cell distribution width (RDW), platelet count (PLT), mean platelet volume (MPV), percentage lymphocyte, (% LYM), percentage monocyte (% MON), percentage granulocyte (% GRA), platelet distribution width (PDW) and plateletcrit (PCT).

(Olson et al., 2000). From the observed values of WBC, it is clear that an increase in the number of WBC is a normal reaction of rats to foreign substances, which alter their normal physiological processes. The leucocytosis observed in the present study indicates a stimulation of the immune system which protects the rats against infection that might have been caused by chemical and secondary infections. Leucocytosis, which may be directly proportional to the severity of the causative stress condition, may be attributed to an increase in leukocyte mobilization (Celik and Suzek, 2008). The elevated level, human toxicity when the data are translated from animal of MPV and PDW in the extract may be due to high rate

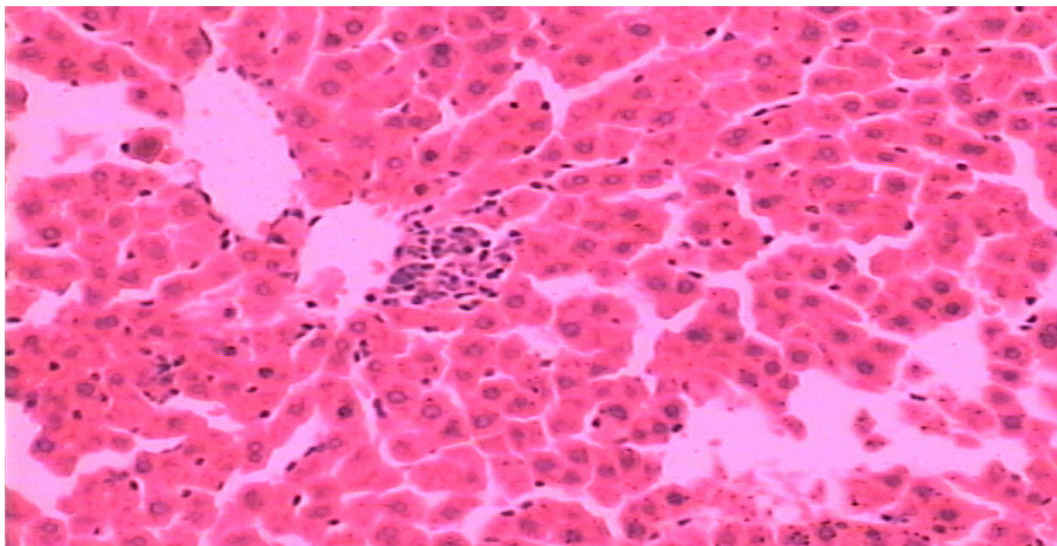
of erythropoiesis occurring in the bone marrow of the rats (Rhiouani et al., 2008). The rise in ALT in the treated groups is an indication of hepatocellular injury.

ALT is a cytoplasmic enzyme found in very high concentration in the liver (Aliyu et al., 2007), and an increase of this specific enzyme indicates hepatocellular damage, while AST is less specific than ALT as an indicator of liver function. The toxicity exerted by ethanolic leaf extract of *A. conyzoides* was confirmed from histological sectioning which indicated various degrees of spotty hepatocellular necrosis in all the treated groups. The observed damage may be due to the fact that the liver being the first target of acute toxicity and





**Figure 2.** Photomicrograph of the section of liver architecture of Sprague Dawley rats showing normal features of control group A.



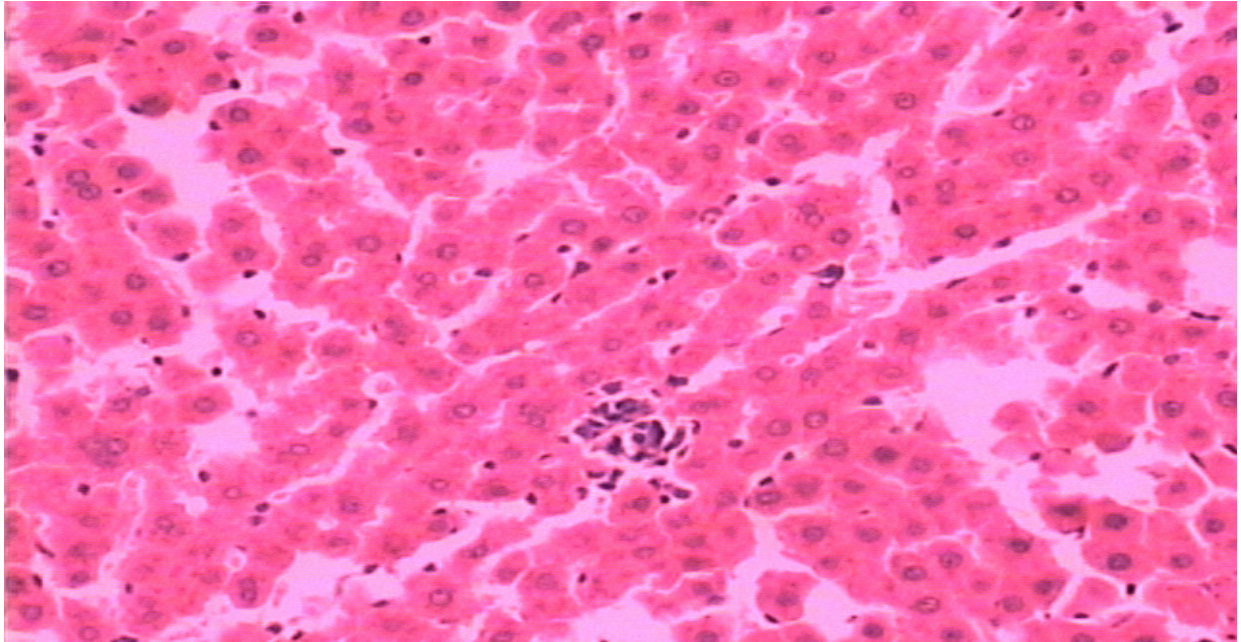
**Figure 3.** Photomicrograph of group B administered with 500 mg/kg body weight of the extract of *Ageratum conyzoides* showing hepatocellular necrosis. (HE stain, x400).

the first organ exposed to everything that is absorbed in the small intestine, may metabolize foreign substances to highly reactive metabolites which may be hepatotoxic. In addition, because of the short duration of treatment, the alterations might be incipient and reversible, and not pronounced enough to change significantly serum ALT levels (Grance et al., 2008).

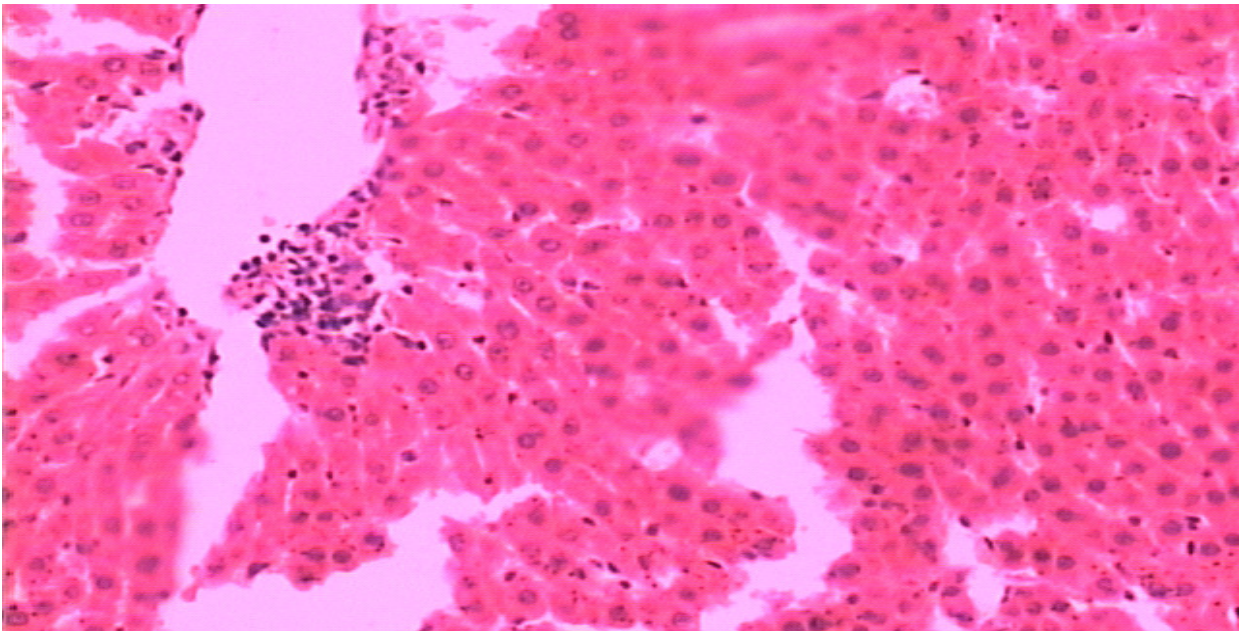
ALP, a marker of obstructive jaundice and intrahepatic cholestasis (Davern and Scharschmidt, 2002) was significantly reduced; this further supported that the observed liver damage was not connected to biliary obstruction of the liver. The result obtained was partly in agreement with the work of Moura et al., (2005) involving rats treated with the hydroalcoholic extract of

*A. conyzoides* leaves. ALT activity was high but not significant in one of the treated groups; they however, suggested that histological study be assessed in order to establish the hepatotoxicity potential of the plant. AST, LDH and CK are markers of skeletal and myocardial muscles (Laterza et al., 2008; Rasekh et al., 2008; Rosalki et al., 2004). When myocardial cells, containing LDH and CK are damaged or destroyed due to deficient oxygen supply or glucose, the cell membrane becomes permeable or may rupture, which results in the leakage of enzymes (Prince et al., 2008). The reduced significant activity of these markers suggests that the ethanolic leaf extract of *A. conyzoides* offered some protections against diseases related to the muscles. The significant reduction





**Figure 4.** Photomicrograph of group C administered with 1000 mg/kg body weight of extract of *A. conyzoides* indicating hepatocellular necrotic damage (HE stain, x400).



**Figure 5.** Photomicrograph of group D administered with 1500 mg/kg body weight of *A. conyzoides* showing different locations of spotty hepatocellular necrosis (HE stain, x400).

of AST level has further eliminated any leakage of the enzyme in the liver due to hepatic injury (since AST is a major marker of liver injury). Serum CK and LDH activities were significantly decreased in the treated rats. Urea and creatinine are considered as a suitable prognostic indicator of renal dysfunction and kidney

failure for any toxic compounds (Gnanamani et al. 2008; Ashour et al., 2006). In the present study, no significant variations in the levels of urea and creatinine was observed; however, a slight insignificant increase in the level of urea and creatinine was noticed, thus suggesting the non-toxicity of the extract to the kidney within the

treatment durations. The result from histological sectioning was in agreement as there was no apparent damage to the kidney was observed in all the treated groups when compared with the control group, this therefore confirmed that the plant extract was non toxic to the kidney within the treatment durations. Previous biochemical studies have also confirmed the non-toxicity of the plant extract of *A. conyzoides* to the kidney (Igbasooyi et al., 2007; Moura et al., 2005).

## Conclusion

In conclusion, within the treatment dose and test duration, the ethanolic leaf extract of *A. conyzoides* showed significant reductions on markers of cardiac and skeletal muscles which could be recommended for the management of cardiac and skeletal diseases. But caution need to be taken on the appropriate dosage as higher concentration could induce hepatocellular necrosis. Further work is needed to ascertain the mechanism of action of the extract on the muscles.

## ACKNOWLEDGEMENTS

The authors appreciate the Chinese Academy of Sciences (CAS) and the Academy of Sciences for the Developing World (TWAS) for their financial and material supports through the CAS-TWAS Post-Graduate Research Fellowship granted to Abiodun Humphrey Adebayo. This work was partly supported by the grant from the National Natural Science Foundation of China (30725048) to Dr. Ning-Hua Tan.

## REFERENCES

- Adebayo AH, Tan NH, Akindahunsi AA, Zeng GZ, Zhang YM (2010). Anticancer and antiradical scavenging activity of *Ageratum conyzoides* L. (Asteraceae). *Phcog. Mag.*, 6: 62-66.
- Adebayo AH, Aliyu R, Gatsing D, Garba IH (2006). The effects of ethanolic leaf extract of *Commiphora africana* (Burseraceae) on lipid profile in rats. *Int. J. Pharmacol.*, 2: 618-622.
- Aliyu R, Adebayo AH, Gatsing D, Garba IH (2007). The effects of ethanolic leaf extract of *Commiphora africana* (Burseraceae) on rat liver and kidney functions. *J. Pharmacol. Toxicol.*, 2: 373-379.
- Ashour A, Yassin M, Abu AM, Ali M (2006). Blood serum glucose and renal parameters in lead-loaded albino rats and treatment with some chelating agents and natural oils. *Turk. J. Biol.*, 31: 25-34.
- Bergmeyer HU, Horder M, Rej R (1986a). International Federation of Clinical Chemistry (IFCC) Scientific Committee, Analytical Section: Approved recommendation (1985) on IFCC methods for the measurement of catalytic concentration of enzymes. Part 2. IFCC method for aspartate aminotransferase (L-aspartate: 2-oxoglutarate aminotransferase, EC 2.6 1:1.). *J. Clin. Chem. Clin. Biochem.*, 24: 497-510.
- Bergmeyer HU, Horder M, Rej R (1986b). International Federation of Clinical Chemistry (IFCC) Scientific Committee, Analytical Section: Approved recommendation (1985) on IFCC methods for the measurement of catalytic concentration of enzymes. Part 3. IFCC method for alanine aminotransferase (L-alanine: 2-oxoglutarate aminotransferase, EC 2.6 1:2.). *J. Clin. Chem. Clin. Biochem.*, 24: 481-495.
- Celik I, Suzek H (2008). The hematological effects of methyl parathion in rats. *J. Haz. Mat.*, 153: 1117-1121.
- Chemnitz G, Schmidt E, Koller PU, Busch EW (1979). Kreatinkinase. *Deutsche Mediz. Wochen*, 104: 257.
- Davern TJ, Scharschmidt BF (2002). Biochemical liver tests. In Sleisenger and Fordtran's Gastrointestinal and Liver Disease: Pathophysiology, diagnosis, management. Feldman M, Friedman LS, Sleisenger MH (eds.), 7th ed. Saunders; Philadelphia, pp. 1227-1228.
- Doumas BT, Perry BW, Sasse EA, Straumfjord JV (1973). Standardization in bilirubin assays: Evaluation of selected methods and stability of bilirubin solutions. *Clin. Chem.*, 19: 984-993.
- Doumas BT, Watson WA, Biggs HG (1971). Albumin standards and the measurement of serum albumin with bromocresol green. *Clin. Chim. Acta*, 31: 87-96.
- El Sheikh SH, Bashir AK, Suliman SM, El Wassila M (1990). Toxicity of certain Sudanese plant extracts on cercariae and miracidia of *Schistosoma mansoni*. *Int. J. Crude Drug Res.*, 28: 241-245.
- European Atherosclerosis Society, EAS (1992). Prevention of coronary heart disease. Scientific back ground and new clinical guidelines. *Nutr. Metab. Cardio. Dis.*, 2: 113.
- Freiburghaus F, Kaminsky R, Nkunya MHH, Brun R (1996). Evaluation of African plants for their *in vitro* trypanocidal activity. *J. Ethnopharmacol.*, 55: 1-11.
- Gnanamani A, Sudha M, Deepa G, Sudha M, Deivanai K, Sadulla S (2008). Haematological and biochemical effects of polyphenolics in animal models. *Chemosphere*, 72: 1321-1326.
- Grance SRM, Teixeira MA, Leit RS, Guimarães EB, Siqueira JM, Oliveira-Filiu WF, Vasconcelos SBS, Vieira MC (2008). *Baccharis trimera*: Effect of hematological and biochemical parameters and hepatorenal evaluation in pregnant rats. *J. Ethnopharmacol.*, 117: 28-33.
- Igbasooyi AC, Eseyin OA, Ezenwa NK, Oladimeji HO (2007). Studies on the toxicity of *Ageratum conyzoides*. *J. Pharmacol. Toxicol.*, 2: 743-747.
- Igoli JO, Ogaji OG, Tor-Anyiin TA, Igoli NP (2005). Traditional medicine practice amongst the Igede people of Nigeria (Part II). *Afr. J. Trad. Comp. Alt. Med.*, 2: 134-152.
- Kong CH (2006). Allelochemicals from *Ageratum conyzoides* L. and *Oryza sativa* L. and their effects on related pathogens. In allelochemicals: Biological control of plant pathogens and diseases. Inderjit and Mukerji, KG (eds.). Springer; Netherlands, pp. 193-206.
- Krieg M, Gunsser KJ, Steinhagen-Thiessen E, Becker H (1986). Comparative quantitative clinico-chemical analysis of the characteristics of 24-hour urine and morning urine. *J. Clin. Chem. Clin. Biochem.*, 24: 863-869.
- Larsen K (1971) Creatinine assay by a reaction-kinetic principle. *Clin. Chim. Acta*, 41: 209-217.
- Laterza OF, Modur VR, Ladenson JH (2008). Biomarkers of tissue injury. *Biomarkers Med.*, 2: 81-92.
- Madureira DC, Martins AP, Gomes M, Paiva J, Da cunha AP, Do Rosario V (2002). Antimalarial activity of medicinal plants used in S. Tome and Principe Islands. *J. Ethnopharmacol.*, 81: 2-29.
- Ming LC (1999). *Ageratum conyzoides*: A tropical source of medicinal and agricultural products. In *Perspectives on New Crops and New Uses*. Janick J., Alexandria VA (eds.). ASHS Press; USA, pp. 469-473.
- Moreira MD, Picanco MC, Barbosa LCA, Guedes RNC, Barros EC, Campos MR (2007). Compounds from *Ageratum conyzoides*: Isolation, structure elucidation and insecticidal activity. *Pest Manage. Sci.*, 63: 615-621.
- Moreira MD, Picanco MC, Barbosa LCA, Guedes RNC, Silva EM (2004). Toxicity of leaf extract of *Ageratum conyzoides* to Lepidoptera pests of horticultural crops. *Biol. Agric. Hort.*, 22: 251-260.
- Moura AC, Silva EL, Fraga MC, Wanderley AG, Afiatpour P, Maia MB (2005). Antiinflammatory and chronic toxicity study of leaves of *Ageratum conyzoides* L. in rats. *Phytomedicine*, 12: 138-142.
- Nweze NE, Obiwulu IS (2009). Anticoccidial effects of *Ageratum conyzoides*. *J. Ethnopharmacol.*, 122: 6-9.
- Okunade AL (2002). Review: *Ageratum conyzoides* L. (Asteraceae). *Fitoterapia*, 73: 1-16.



- Oladejo OW, Imosemi IO, Osuagwu FC, Oluwadara OO, Aiku A, Adewoyin O, Ekpo OE, Oyedele OO, Akang EEU, (2003). Enhancement of cutaneous wound healing by methanolic extracts of *Ageratum conyzoides* in the wistar rats. *Afr. J. Biomed. Res.*, 6: 27-31.
- Olson H, Betton G, Robinson D, Thomas K, Monro A, Kolaja G, Lilly P, Sanders J, Sipes G, Bracken W, Dorato M, Deun KV, Smith P, Berger B, Heller A (2000). Concordance of toxicity of pharmaceuticals in humans and in animals. *Regul. Toxicol. Pharmacol.*, 32: 56-67.
- Prince PSM, Suman S, Devika PT, Vaithianathan M (2008). Cardioprotective effect of 'Marutham' a polyherbal formulation on isoproterenol induced myocardial infarction in Wistar rats. *Fitoterapia*, 79: 433-438.
- Rasekh HR, Nazari P, Kamli-Nejad M, Hosseinzadeh L (2008). Acute and subchronic oral toxicity of *Galega officinalis* in rats. *J. Ethnopharmacol.*, 116: 21-26.
- Rhiouani H, El-Hilaly J, Israili ZH, Lyoussi B (2008). Acute and sub-chronic toxicity of an aqueous extract of the leaves of *Herniaria glabra* in rodents. *J. Ethnopharmacol.*, 118: 378-386.
- Rosalki SB, Roberts R, Katus HA, Giannitsis E, Ladenson JH (2004). Cardiac biomarkers for detection of myocardial infarction: Perspectives from past to present. *Clin. Chem.*, 50: 2205-2213.
- Shirwaikar A, Bhilegaonkar PM, Malini S, Kumar JS (2003). The gastroprotective activity of the ethanol extract of *Ageratum conyzoides*. *J. Ethnopharmacol.*, 86: 117-121.
- Tietz NW, Rinker AD, Shaw LM (1983). International Federation of Clinical Chemistry. IFCC methods for the measurement of catalytic concentration of enzymes. Part 5. IFCC method for alkaline phosphatase (orthophosphoric-monoester phosphohydrolase, alkaline optimum, EC 3.1.3.1). *J. Clin. Chem. Clin. Biochem.*, 21: 731-748.
- Trinder P (1969). Enzymatic colorimetric glucose determination. *Ann. Clin. Biochem.*, 6: 24-27.
- Weichselbaum TE (1946). Biuret method of serum total protein estimation. *Am. J. Clin. Pathol.*, 16: 40.
- Whittle SR, Turner AJ (1981). Anticonvulsants and brain aldehyde metabolism: Inhibitory characteristics of ox brain aldehyde reductase. *Biochem. Pharmacol.*, 30: 1191-1196.
- Zoppi F, Fellini D (1976). Enzymatic colorimetric cholesterol determination. *Clin. Chem.*, 22: 690-691.