Digestive and Liver Disease 45 (2013) 969–977

Contents lists available at ScienceDirect

Digestive and Liver Disease

journal homepage: www.elsevier.com/locate/dld

Review Article

Definition and evaluation of mucosal healing in clinical practice

Silvia Mazzuoli[a], Francesco W. Guglielmi[a,*], Elisabetta Antonelli[b], Marianna Salemme[c], Gabrio Bassotti[b], Vincenzo Villanacci[c]

[a] Gastroenterology and Artificial Nutrition Department, "San Nicola Pellegrino" Hospital Trani, BT, Italy
[b] Gastroenterology and Hepatology Section, Department of Clinical & Experimental Medicine, University of Perugia, Italy
[c] Department of Pathology, Spedali Civili of Brescia, Italy

ARTICLE INFO

Article history:
Received 8 January 2013
Accepted 26 June 2013
Available online 7 August 2013

Keywords:
Endoscopic index of severity
Inflammatory bowel disease
Inflammation
Mucosal healing
Pathology

ABSTRACT

Since the introduction of biological therapy, endoscopic and histological remission, i.e. mucosal healing, has become an important therapeutic goal in Crohn's Disease and Ulcerative Colitis. Mucosal healing is associated with lower rates of hospitalization and surgery, although its role in preventing progression and changing the natural history of the disease has not been clearly demonstrated. A precise definition of mucosal healing has not yet been established, although the concept used in clinical trials is the "complete absence of all inflammatory and ulcerative lesions in all segments of gut" at endoscopy. This definition does not include mucosal improvement and does not distinguish among grades of mucosal healing. In both Crohn's Disease and Ulcerative Colitis trials, several qualitative and quantitative numeric endoscopic indices have been proposed to measure and distinguish endoscopic changes. In addition, the microscopic features associated with inflammatory bowel diseases are considerably modified by the course of the disease and the treatments adopted. However, it is not yet clear whether microscopic healing should be a primary endpoint in clinical trials. In this paper we discuss endoscopic and histological findings and the limitations of the endoscopic and histological indices as a basis for a standardised diagnosis of mucosal healing.

© 2013 Editrice Gastroenterologica Italiana S.r.l. Published by Elsevier Ltd. All rights reserved.

1. Introduction

In recent years the management of inflammatory bowel diseases (IBD) has substantially changed, due to the fact that the new treatments with anti-TNFα drugs induce not only clinical remission but also a significant endoscopic improvement, or even a total disappearance of the intestinal lesions [1]. Although conventional therapies with 5-aminosalicylic acid (5-ASA), oral steroids and immunomodulators may lead to mucosal healing (MH), the MH rate with these agents is lower than that obtained with anti-TNFα [2–7]. At present, there is significant evidence that the use of anti-TNFα drugs, such as infliximab, adalimumab, and certolizumab pegol, can induce and sustain endoscopic healing [8,9]. The mechanisms of action of the anti-TNFα therapies are largely unknown. Very recently, in 2 in vivo models Fischer found that adalimumab prevents intestinal barrier dysfunction and antagonises distinct effects of TNF on tight junction proteins and signalling pathways in intestinal epithelial cells. All these events may therefore represent a novel mechanism of action whereby antiTNF drugs participate in epithelial and tissue repair in CD and UC [10].

MH has now become an important endpoint to assess the therapeutic effect in IBD [11–13]. The definition of MH currently used in CD and UC clinical trials is the *"complete absence of all inflammatory and ulcerative lesions"*, but this definition lacks validation and does not include mucosal improvement and grading of MH [11,14–16]. Furthermore, in most studies the definition of MH in UC includes the presence of *"persistent erythema and friability at endoscopy"* without ulceration or erosions [14].

The aim of this paper is to review different definitions of endoscopic healing and to describe the endoscopic indices commonly used in clinical trials. We also point out the role of histological assessment and the need to use a standardised validated endoscopic score to avoid differences in MH rates among the various trials.

1.1. Controversies in MH definition

Controversies regarding the currently available definitions of MH are shown in Tables 1 and 2, reporting endoscopic indices, endoscopic features, MH definition, time/weeks between endoscopic re-evaluations and the percentage of patients showing MH. The different definitions of MH, such as "absence of ulcers" or

* Corresponding author at: Gastroenterology and Artificial Nutrition Department, "San Nicola Pellegrino" Hospital, 76125 Trani, BT, Italy. Tel.: +39 0883 483209; fax: +39 0883 483342.
E-mail address: guglielmifw@libero.it (F.W. Guglielmi).

1590-8658/$36.00 © 2013 Editrice Gastroenterologica Italiana S.r.l. Published by Elsevier Ltd. All rights reserved.
http://dx.doi.org/10.1016/j.dld.2013.06.010

Table 1
Endoscopic indices used in Crohn's disease and ulcerative colitis.

	Endoscopic features	Range	Proposed MH cut-off	Validated predictive cut-off
CD endoscopic indices				
Crohn's Disease Endoscopic Index of Severity (CDEIS) (1989)	Presence or absence of ulcers (superficial or deep); percentage of ulcerated or inflamed surface, stenosis (ulcerated or non ulcerated) in five intestinal segments	0–44	CDEIS > 3 CDEIS $0_{(42–46)}$	–
Simplified Endoscopic Activity Score for Crohn's Disease (SES-CD) (2004)	Presence or absence of ulcers (size); proportion of the intestinal surface affected by ulcerations and by other inflammatory lesions; narrowing (single or multiple and permitting passage or not) in five intestinal segments	0–56	SESCD 0 SESCD < $5_{(42–46)}$	–
Rutgeert's score (1990)	Presence of ulcers, diffuse inflammation and ulcers, nodules and/or narrowing	0–4	Rutgeert 0–$1_{(42–46)}$	3–4 relapse
Lemman score (2011)	Presence of stricture lesions and presence of penetrating lesions	0–10	–	–
UC endoscopic indices				
Truelove and Witts (1955)	Hyperemia and granularity	0–3	–	–
Baron score (1964)	Severity of mucosal bleeding and friability	0–3	–	–
Modified Baron Score (1964)	Vascular pattern; mucosal granularity; bleeding, mucus, fibrin, erosions and ulcers	0–4	–	–
Powell-Tuck score (1978)	Severity of mucosal bleeding and friability	0–2	–	–
Sutherland score (1987)	Severity of mucosal bleeding and friability	0–2	–	–
Rachmilewitz score (1989)	Vascular pattern; mucosal granularity; bleeding, mucus, fibrin, erosions and ulcer	0–12	–	–
Mayo score (1987)	Erythema, vascular pattern, friability, erosions, spontaneous bleeding, ulcerations	0–3	0–1 (56)	–
Ulcerative Colitis Endoscopic Index of Severity (UCEIS) (2011)	Vascular pattern (normal, patchy obliteration, obliterated); Bleeding (none, mucosal, luminal mild, luminal moderate or severe); Lesions (none, erosions, superficial ulcers, deep ulcers)	0–3 for vascular pattern 0–4 for bleeding and lesions	–	–
Ulcerative Colitis Colonoscopy Index of Severity (UCCIS) (2013)	Vascular pattern (normal, partially visible, complete loss); Granularity (normal, fine, coarse); Ulceration (normal, erosions or pinpoint ulcerations, shallow ulcers with mucopus, deep ulcerations, diffuse ulcerated with >30% involvement); Bleeding/friability (normal, friable and bleeding on touch, spontaneous bleeding)	0–2 for vascular pattern, granularity, bleeding/friability 0–4 for ulcerations	–	–

MH, mucosal healing.

"endoscopic scores improvement", as well as the duration of the biological therapy certainly interfere with the rate of MH. In fact, in CD patients the short-term re-evaluation at 10 weeks demonstrated an "absence of ulcers" ranging between 11% and 29% of patients, and this rate rose to 45%, 44%, and 73% when patients underwent endoscopy at 24–54 and 104 weeks. Instead, when MH was considered as an "endoscopic scores improvement", the short-term MH rate at endoscopic re-evaluation ranged between 64% and 90% and remained at the same rate after medium and long-term treatment. In UC patients, the endoscopic short-term re-evaluation revealed a diagnosis of MH as "absence of ulcers" (MAYO 0) in about 27% of the patients, on the contrary when MH was considered as the "endoscopic scores improvement" (MAYO 1) the rate of MH ranged between 30% and 62% both in short- and long-term endoscopic re-evaluations.

The importance of achieving MH in clinical practice is correlated to recent evidence that shows that MH is associated with long-term symptomatic remission and a longer relapse-free interval [17], as well as with a reduction in the frequency of hospitalizations, complications and surgical resections [18–20], and with a significant improvement of quality of life [21]. Furthermore, MH is associated to a reduction of cancer risk and cancer-related mortality; data suggest that colorectal cancer in IBD patients is driven by a persistent active inflammation. Controlled prospective studies are lacking but a large cohort study indicates a lower risk of colorectal cancer in the presence of MH in patients treated with azathioprine [22] and infliximab [23]. All these events seem to have a prognostic relevance, but the role of MH in preventing progression and changing the natural history of IBD has never been demonstrated [24] probably due to the late use of anti-TNF drugs.

Table 2
Mucosal healing definition and endoscopic timing in clinical trials and anti-TNF α.

Authors	Study design	Patients	Disease	Evaluation of MH	MH%	Endoscopic timing/weeks
Van Dullemen (1995)	Open-label study with a single IFX infusion	10	CD	Improvement of CDEIS (no definition of MH)	90	4
D'Haens (1999)	Multicenter randomised double blind with a single IFX infusion (5, 10, 20 mg/kg)	30	CD	Improvement of CDEIS (No definition of MH)	Non reported	4
Rutgeerts (2006)	Multicenter randomised controlled trial Inducing and scheduled IFX vs. episodic infusion (ACCENT I)	99/573	CD	Absence of mucosal ulcerations	29 vs. 3	10
					44 vs. 18	54
				CDEIS improvement	76	10
					93	54
D'Haens (2008)	Open-label randomised trial	49/133	CD	Absence of mucosal ulcerations (SES CD 0).	73	104
	Early combinational therapy with AZA + IFX vs. conventional therapy				Top-down	
					30	
					Step-up	
Schnitzler (2009)	Observational study with scheduled IFX	214/614	CD	Complete MH (absence of ulceration)	45	24
				Partial MH (improvement but still ulcerations)	22	
				No healing	33	
Colombel (2008)	Multicenter randomised controlled trial	309/508	CD	Absence of mucosal ulcerations (No score)	16	26
	AZA + placebo IFX + placebo				30	
	IFX + AZA (SONIC)				44	
Colombel (2010)	Multicenter Open label study with Certolizumab pegol (MUSIC)	89	CD	Absence of ulcers	5	10
				CDEIS <3 (Complete endoscopic remission)	11	10
					18	54
				CDEIS >4 point change (Endoscopic response)	61	10
					62	54
					42	10
				CDEIS <7 (endoscopic remission)	28	54
Rutgeerts (2009)	Randomised placebo-controlled trial with ADA (EXTENT)	129	CD	Absence of all mucosal ulcerations (endpoint)	27	12
					24	52
					52	12
				Improvement of lesions: CDEIS <4 SES CD <5	28	52
Rutgeerts (2005)	Multicenter Randomised, double-blind placebo-controlled trial with IFX (ACT1–ACT2)	726	UC	ACT1 (Mayo 0–1)	62	8
					50	30
					45	54
				ACT2 (Mayo 0–1)	60	8
				Mayo 0	46	30
					27	8
Afif (2009)	Uncontrolled Open label study with ADA	20	UC	Mayo 0–1	30	8
Reinisch (2011)	Multicenter Randomised, double-blind placebo- controlled trial with ADA	390	UC	Mayo 0–1	47	8
Sandborn (2012)		494	UC	Mayo 0–1	41	8
					25	52

MH, mucosal healing.

2. Role of endoscopy

Ileocolonoscopy in IBD patients is used to: (i) diagnose CD and UC; (ii) predict an aggressive course of disease; (iii) obtain biopsies of the intestinal mucosa for histological examination; (iv) monitor dysplasia and the risk of colorectal cancer [25]. In the last few years a new important role of ileocolonoscopy has emerged in the evaluation of the mucosal response to therapy, i.e. the grade of MH.

Correlations between histological disease activity and endoscopy are fairly good, especially when the samples are obtained during active inflammation, even though microscopic features of activity may persist in a macroscopically inactive disease [26]. Modern sophisticated techniques, such as confocal laser endomicroscopy (CLE) and chromoendoscopy (CE), have been proposed to provide a more detailed view of the mucosa [27,28] for assessing mucosal and histological healing and for the detection of intraepithelial neoplasia [29]. The potential role of CLE in the management of IBD patients is based on its capacity to evaluate, in vivo, the structural healing of chronic inflammation in IBD: crypt and vessel architecture, and cellular infiltration [30,31]. Recently, a classification of activity inflammation in UC with CLE has been proposed [32]. The latest studies show that

CLE images might offer information equivalent to conventional histology, with a good correlation between CLE and histological results. In particular, CLE is also able to assess MH after treatment with biological agents [33] and to predict disease outcome [34,35]. Specific patterns observed with CE may be important for the identification of dysplasia during surveillance of UC [36] and CD patients [37] and for the diagnosis of intraepithelial neoplasia [38]. Neumann [39] recently developed an endomicroscopic activity index, denoted "Crohn's Disease Endomicroscopic Activity Score", to graduate the severity of inflammation in this disease. This score is the first endoscopic index for Crohn's disease based on in vivo histology, but its validity has still to be confirmed. The Watson score [40] is another scoring system based on functional in vivo imaging that may be used to predict clinical relapse. A clinical trial is now ongoing to analyse the mechanism of action of infliximab at the CLE level and to analyse MH, i.e. structural and functional changes in the mucosa in IBD patients [41].

3. Endoscopic scores in the era of MH

The need to evaluate MH has confirmed the function of endoscopy in the management and follow-up of IBD patients. For this reason, endoscopic scores used to classify disease activity [11,12] have also been proposed to define MH in CD and UC. The main problem in the use of endoscopic scores is that many of these are complex and time-consuming. Another important limitation is the absence of: (a) a validated definition of MH; (b) guidelines for the correct and optimal timing of endoscopic re-evaluation during therapy; (c) agreement about cutoff values of endoscopic scores to measure MH and define endoscopic response or remission. Furthermore, the limited ability of conventional endoscopy to evaluate disease activity in the small bowel means that other tools are needed, such as capsule endoscopy or enteroscopy. The ECCO guidelines state that small bowel capsule endoscopy has an important role in the assessment of mucosal lesions or MH. However, also in this area there are no validated endoscopic indices to define remission and guide medical decision-making [42].

3.1. Endoscopic scores in Crohn's disease

The first endoscopic score for evaluating the severity of ileocolonic lesions in CD was the Crohn's Disease Endoscopic Index of Severity (CDEIS), developed and validated by the Groupe d'Etudes Thérapeutiques des Affections Inflammatoires Digestives (GETAID) in France [43]. This numerical score ranges between 0 and 44 and evaluates, in 5 bowel segments (terminal ileum, right colon, transverse, left colon and sigmoid, and rectum) on a 10-cm linear scale, the following features: (i) the presence or absence of ulcers, distinguished as superficial or deep; (ii) the presence of stenosis, classified as ulcerated or non-ulcerated; and (iii) the surface extension of disease activity, classified as ulceration or only inflammation. The score requires prior training but is highly reproducible among different operators. The time-consuming surface measurement technique (usually performed on previously recorded videos) is probably the main reason why CDEIS is only used in clinical trials and not in clinical practice. Recently, a new, simpler endoscopic score was developed by Daperno et al. [44]. This score, named "Simplified Endoscopic Activity Score for Crohn's Disease" (SES-CD), ranges from 0 to 60 and includes 4 variables: (i) the intestinal surface affected by ulcers; (ii) the intestinal surface affected by other inflammatory lesions; (iii) the presence of ulcers; (iv) the presence of narrowing (differentiated as single or multiple and permitting passage or not). Each of these variables is scored from 0 to 3 and evaluated in 5 intestinal segments (terminal ileum, right colon, transverse, left colon and sigmoid, and rectum). In this score the presence of ulcers is classified not as deep or superficial but according to size (0.1–0.5 cm; 0.5–2 cm; >2 cm), and ulcerated surfaces and intestinal surfaces affected by other inflammatory lesions are classified according to their extension (<10%; 10–30%; >30%); (<50%; 50–75%; >75%). A correlation between the SES-CD and the CDEIS [44], and between the SES-CD and clinical and laboratory parameters [44] has been reported. Fig. 1 shows representative images (A, B, C) from different endoscopic scenarios induced by biological therapy in a CD patient.

In CD patients undergoing surgery, literature data demonstrate that disease recurrence is frequent and that 90% of patients have new endoscopic lesions as early as 1 year after surgery [45]. A validated endoscopic index (Rutgeert's score [46]) measures endoscopic recurrence in the neo-terminal ileum and/or ileocolonic anastomosis. This score ranges from 0 to 4, classified as: (0) absence of lesions; (1) <5 aphthous lesions, (2) >5 more severe aphthous lesions; (3) diffuse inflammation with diffuse ulcers; (4) nodules and/or narrowing. The Rutgeert's score is the gold standard for the prognosis of postoperative recurrence; indeed, scores 3 and 4 are validated cutoff values that predict clinical relapse [47]. For this reason ileocolonoscopy is recommended within 1 year after surgical resection to orient treatment decision-making [48,49].

All the above endoscopic scores explore only the mucosal surface in CD but do not assess transmural injury and penetrating evolution, signs of progressive disease and structural bowel damage. Today, the important concept of "*cumulative bowel damage*" has emerged, and it has been included in a new index called "The Lemann score" (Crohn's Disease Digestive Damage Score). The Lemann score is a complex score that evaluates, in different gastrointestinal locations (upper gastrointestinal tract, small bowel, colon or rectum, and anal or perianal), strictures and penetrating lesions (ulceration, fistula, and abscess), as well as surgical resection or bypass of the bowel. Upper gastrointestinal endoscopy, colonoscopy, Computed Tomography Enterography (CTE) and Magnetic Resonance Imaging Enterography (MRE) are the methods used to assess transmural intestinal damage in the Lemman score. CTE and MRE visualise the precise site of intestinal lesions, mesenteric changes, and the presence of strictures, fistulae or abscesses, thus improving the detection of structural small bowel lesions. For each gastrointestinal segment, disease severity is scored from 0 (normal bowel with no history of surgery) to 3 (including progressive structural bowel lesions and resection). The Lemman score ranges from 0 (absence of damage) to 10 (complete resection of the gastrointestinal tract) [50]. This index has been developed to identify CD patients at high or low risk of rapid damage progression who would benefit from early biological treatment.

3.2. Endoscopic scores in UC

Numerous scores have been used for the assessment of endoscopic activity in UC. The first endoscopic score to evaluate disease activity in UC was proposed by Truelove and Witts [51]. With this score, the sigmoidoscopic appearance before and after corticosteroid treatment was classified on the basis of hyperaemia and mucosa granularity. In 1964, Baron [52] described endoscopic disease activity based only on the severity of bleeding and friability, while ulceration or other lesions were not considered. This score ranged from 0 to 4 and distinguished normal mucosa, abnormal but not haemorrhagic mucosa, moderately haemorrhagic mucosa with bleeding on contact, and severely haemorrhagic mucosa with spontaneous bleeding. The Powell-Tuck sigmoidoscopic score [53] and Sutherland score [54], with ranges 0–2, focused on endoscopic evaluation only by assessing bleeding without considering the presence of other inflammatory lesions. Subsequent endoscopic indices have included the presence of erosions, mucopus, granularity, and ulcers. In the Rachmilewitz Endoscopic score [55] 4

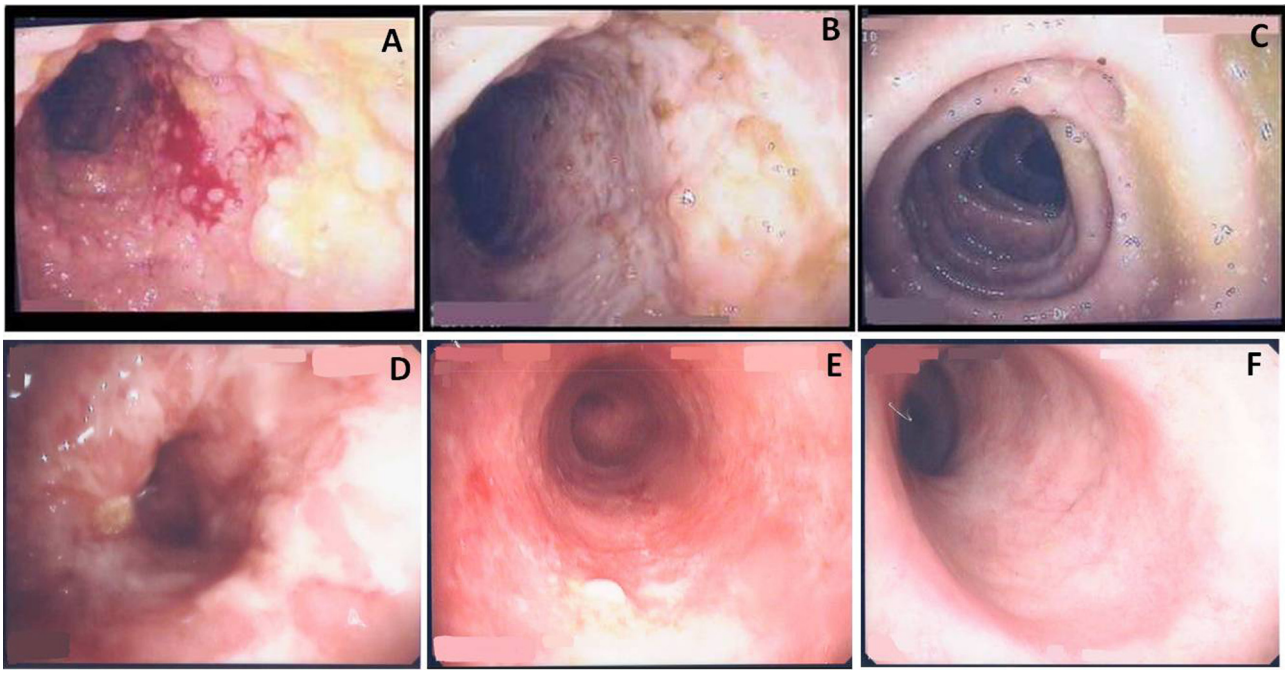

Fig. 1. Three different images from a patient with Crohn's Disease (panels A, B, C) and a patient with Ulcerative Colitis (panels D, E, F) during biological treatments. Panel A: SES-CD 23 (right, transverse, left colon and rectum involvement with large ulcers involving more than 30% of the intestinal surface and with an affected surface of between 50% and 75%). Panel B: SES-CD 6 (affected colon surface less than 50% and ulcerative surface less than 10% and aphthous ulcers in left colon). Panel C: SES-CD 0 (mucosal healing). Panel D: Mayo endoscopic subscore = 3; severe disease with spontaneous bleeding and diffuse ulceration. Panel E: Mayo endoscopic subscore = 2; moderate disease with marked erythema, friability, erosions and absent vascular patterns. Panel F: Mayo endoscopic score = 0; mucosal healing.

items are included: vascular pattern, mucosal granularity, contact or spontaneous mucosal bleeding, and mucosal damage (mucus, fibrin, erosions and ulcer). This score ranges from 0 to 12. A cut-off value for remission is also defined. In a prospective study [56] a significant correlation between the Rachmilewitz Endoscopic score and clinical and laboratory activity indices was found, identifying the following cutoffs: (i) inactive disease with score 0–4; (ii) mild activity with score 4–6; (iii) moderate activity with score 7–9; (iv) high activity with score 10–12. To date, the Mayo sub-score [57] is the score system most widely used in clinical trials to describe the degree of endoscopic activity. The Mayo score is a composite index that includes 4 sub-scores: stool frequency, rectal bleeding, endoscopic findings, physician's global assessment. Each of these sub-scores ranges from 0 to 3, while the Mayo score ranges from 0 to 12. A score $\leq$2 means remission, 3–5 indicates mild disease, 6–10 indicates moderate disease, and 11–12 indicates severe disease. The Mayo endoscopic sub-score ranges from 0 to 3: (0) inactive disease and normal mucosa; (1) mild disease (erythema and mild friability); (2) moderate disease (marked erythema, absent vascular pattern, friability, erosions), (3) severe disease (spontaneous bleeding and diffuse ulceration). The limit of this score is that it does not distinguish between deep and superficial ulcerations. In clinical trials and practice, a Mayo endoscopic sub-score of 0 or 1 is a commonly accepted criterion for MH [14] and, as far as avoiding colectomy is concerned, it predicts a better outcome than a Mayo sub-score of 2–3. More recently, another score index has been proposed to measure endoscopic severity in UC. This score, named "Ulcerative Colitis Endoscopic Index of Severity" (UCEIS), includes 3 variables: (i) vascular pattern (normal = 1, patchy obliteration = 2; complete obliteration = 3); (ii) bleeding (none = 1, mucosal = 2, luminal mild = 3, luminal severe = 4); (iii) erosions and ulcers (none = 1, erosions = 2, superficial ulcers = 3, deep ulcers = 4) [58]. This score was developed as a validated index of endoscopic severity, although the sensitivity of the index to a specific change, and the threshold for MH, have yet to be determined. The correlations of this index need further investigation before its application in clinical trials and clinical practice.

Recently, the Ulcerative Colitis Colonoscopic Index of Severity (UCCIS) has been validated in a prospective cohort of UC patients [59]. This score is a composite index that includes 4 variables: vascular pattern, granularity, ulceration, bleeding/friability and severity of damage in each colon segment and overall. The global assessment of endoscopic severity is based on a 4-point scale and a 10-cm visual analogue scale.

Table 1 summarises the endoscopic scores used in CD and UC. Fig. 1 shows representative images (D, E, F) of different endoscopic scenarios induced by biological therapy in a UC patient.

4. Histological features

4.1. Basic histopathological concepts

Like in other pathological conditions involving the large bowel, the pathologist should receive an adequate number of biopsies, correctly oriented from at least 5 sites (including the rectum and the terminal ileum). The biopsies should always be accompanied by a clinical report, including patient age, duration of the disease and duration and type of treatment [60].

The diagnostic elements for histological assessment are:

a) UC [61]:

- Architecture of the crypts: crypt branching, mucosal (crypt) distortion, decreased crypt density, irregular mucosal surface;
- Lamina propria cellularity: transmucosal inflammation, basal plasmacytosis.

b) CD [62]:

- Architecture of the crypts: segmental crypt atrophy and distortion;
- Lamina propria cellularity: granulomas, segmental inflammation, basal plasmacytosis.

The diagnostic value of the histological features of UC and CD, and the differences between the 2 diseases have been extensively studied [63]. Crypt architectural abnormalities in the colon are more common in UC (57–100% of cases) than CD (27–71% of cases). Increased basal lamina propria cellularity and basal plasmacytosis are common in both UC and CD (76–92% and 72–81%, respectively). Crypt abscesses are more common in UC (41%) than CD (19%), while granulomas are characteristic of CD, being present in 21–37% of biopsy specimens [64]. Basal plasmacytosis is present in more than 50% of IBD patients [65], in 38% of patients with symptoms for less than 2 weeks, and has disappeared in 50% of IBD patients without relapse, by 1 year after the onset of colitis [66].

Although no standardised criteria for histological response in IBD patients following therapy are available, the presence of basal plasmacytosis in quiescent UC seems to be associated with a shorter disease relapse time [67]. It is also important to consider that an endoscopic description of MH does not necessarily imply histological healing of the mucosa [68].

4.2. Effects of drugs on histological disease activity

In most of the available studies the evaluation of histological disease activity was not a treatment endpoint. Moreover, the endpoints for histological remission of disease for each patient were not defined, therefore data on this topic are relatively scarce.

4.2.1. Salicylates

In a double-blind, multicentre trial Kruis et al. [69] evaluated 3 different doses of 5-aminosalicylic acid (0.5 g three times/day, 1.0 g three times/day, and 1.5 g three times/day) in 321 active UC patients for 8 weeks. Histological improvement was defined as a reduction of the histological activity index (HI) by at least 1 point. Data analysis showed that the 3.0 g/day dose had a higher rate of endoscopic improvement (84%) as compared to the 1.5 g/day (53%) and 4.5 g/day (70%) doses, but the histological improvement rates were lower. The safety and efficacy of balsalazide (6.75 g daily), or sulfasalazine (3 g daily) were compared in an 8-week randomised, multicentre, double-blind, parallel group study that included 50 patients with mild to moderate UC [70]. The trial medication was the sole treatment and the efficacy was scored by symptom assessment, sigmoidoscopic appearance, and histology (rectal biopsies, performed at enrolment and at the final visit). Each biopsy was graded on a 4-point scale (normal to severe inflammation) and all the patients included in the study had at least mild inflammation at entry (58% severe inflammation). In this study, the inclusion of histology in the assessment of efficacy was meant to identify patients in whom clinical remission was associated with histological remission. After treatment, an improvement was observed in both groups; 61% of the patients taking balsalazide achieved clinical and sigmoidoscopic remission. Similarly, an improvement of histological grades was seen with both treatments and the number of patients with normal mucosa or minimal inflammation without active disease increased in both groups. In another study, Kruis et al. studied the efficacy and safety of 2 different treatment dosages (3 g once daily or 1 g three times a day) of mesalazine granules in 380 UC patients [71]. Endoscopy and histology were performed at baseline and the final visit (8 weeks), the total histological index being based on the most severely inflamed segment. Endoscopic remission was obtained in about 70% of the patients in both treatment groups, while histological remission was observed in 35% of patients in the once daily group and in 41% of those in the twice daily group. Endoscopy and histology revealed no statistically significant differences between the 2 dosing regimens. Prantera and colleagues evaluated the therapeutic response to slow-release mesalazine (MMx) compared with topical 5-ASA in 79 patients with active left-sided disease [72]. Endoscopic remission was achieved by 45% of the patients treated with MMx and by 37% of those treated with enemas. Histological remission (Floren score) [73] was obtained in only 15% of the patients treated with MMx and in 8% of the patients treated with enema. Malchow and colleagues investigated 264 patients with active distal UC, treated with 5-ASA foam or liquid enema [74]. After 4 weeks, in both treatment groups the overall remission rate was about 38%. Histological analysis showed an improvement in both treatment groups (46% remission in the foam group and 50% in the enema group).

Considering topical treatments, a trend in favour of mesalazine as compared to steroids is observed; 295 patients presenting with a relapse of distal UC were treated with 2 g mesalazine foam enema or 20 mg prednisolone foam enema [75]. After 4 weeks of treatment, clinical remission was achieved by 52% of mesalazine-treated patients and 31% of prednisolone-treated patients. Endoscopic remission was achieved in 40% of patients in the mesalazine group and 31% in the steroid group. Similarly, mesalazine induced histological remission in 27% of the patients whereas the same effect was induced in 21% of the steroid-treated patients.

4.2.2. Steroids

The capacity of corticosteroids to induce MH in UC patients is well recognised [76]. The seminal paper by Truelove [77] showed that hydrocortisone hemisuccinate sodium administered rectally induces rapid clinical remission in patients with mild to moderate UC. After 1 week of treatment patients showed a striking improvement in terms of endoscopic and histological variables. The steroid-treated group had a significantly better histological appearance after treatment as compared to baseline and to the placebo group.

4.2.3. Immunomodulators

Data from a few studies suggest that azathioprine causes a significant degree of endoscopic healing and histological improvement in the majority of CD patients. However, the rates of MH using azathioprine vary among studies, probably due to differences in the timing of endoscopy and the population considered. In an open label study, Sandborn et al. demonstrated, for the first time, that a loading dose of intravenous azathioprine induced complete endoscopic remission in 3 of 6 patients with active CD [78].

In a subsequent study, D'Haens et al. evaluated MH using azathioprine in a cohort of 19 patients with recurrent postoperative CD of the neoterminal ileum [79]. At least 6 months after complete weaning from steroids, 15 patients (79%) achieved clinical remission; in this group colonoscopy showed complete macroscopic healing of the neoterminal ileum in 6 patients. Comparison of biopsy specimens taken before and after taking azathioprine showed persistent mucosal architectural changes, with a complete disappearance of the inflammatory infiltrate only in patients with complete macroscopic healing.

The same authors examined a series of consecutive CD patients with colitis and ileocolitis in clinical remission treated with azathioprine for at least 9 months, and compared disease parameters with pre-azathioprine data in the same patients [80]. The patients had been previously treated with steroids for at least 3 years and the ileocolonoscopy was performed less than 1 year before the start of azathioprine. In this study a global histological CD severity score was used [81]. This score combines active inflammatory changes (epithelial damage, infiltration of mononuclear

cells, polymorphonuclear cells, presence of erosions and/or ulcers, granulomas) and chronic architectural changes, and includes a correction factor for the proportion of biopsy specimens affected by inflammation. The score ranged from 0 (normal) to 12 (severe inflammation in all biopsies). The purely "inflammatory activity score", which ranges from 0 to 7, was calculated based on the number of inflammatory cells in the epithelium and the lamina propria. Complete endoscopic healing was observed in the colon in 70% of the patients, and in 54% of the 13 patients with prior ileitis. Endoscopic healing was paralleled by a reduction in the histological score, mainly due to a reduction in the inflammatory infiltrate, but the latter was not always as "complete" as suggested by the endoscopy. In the patients with complete endoscopic healing, global histological scores decreased from 10 to 3; inflammatory scores decreased from 5 to 2. In patients without endoscopic healing during azathioprine therapy, no significant histological changes were observed. In patients with ileal healing, the microscopic changes were more complete and the global histological activity index decreased from a median of 7 to 2, whereas the inflammatory component of the score decreased from 2 to 0.

More recently, it has been demonstrated that early administration of azathioprine is effective not only in maintaining clinical remission but also in inducing higher rates of MH and histological remission than steroids (budesonide), in patients with steroid-dependent inflammatory Crohn's ileocolitis or proximal colitis who had achieved clinical remission on conventional steroids [82]. In this comparative study the primary endpoint was the rate of MH and histological remission of CD, and the average histology score was calculated by dividing the sum of individual intestinal segmental scores by the number of intestinal segments explored. At the end of 1-year treatment, 32 patients in the azathioprine group and 25 in the budesonide group were in clinical remission; complete or nearly complete healing was achieved in 83% of azathioprine-treated patients compared with only 24% of budesonide-treated patients. In patients treated with azathioprine, MH was associated with a significant histological reduction of CD activity, although complete histological remission was not achieved. Moreover, the histology score fell significantly only in the azathioprine group, and much less improvement was observed in the budesonide group. Regarding the acute histological parameters (epithelial damage, acute inflammatory cell infiltrate of the lamina propria, erosions and/or ulcers), an improvement of all of them was observed regardless of disease location. The number of biopsies affected was significantly lower in azathioprine than budesonide-treated patients (32% vs. 82%). The only histological parameters unaffected by azathioprine were the glandular architecture and the presence of chronic inflammation.

Only a few studies have investigated the effect of methotrexate on mucosal healing in IBD patients. A pilot study that evaluated the effects of adding this agent to standard treatment (steroids, mesalazine) in 14 CD patients with refractory disease, elicited a normal histology after 12 weeks of treatment in 4 patients [83]. Another study, comparing the effect of methotrexate with that of azathioprine and infliximab in 40 CD patients, did not show significant differences between the 3 groups after 3 months of treatment [84].

4.2.4. Biological therapy

The development of biological agents for the treatment of CD sparked interest in the MH field due to the potential alteration of the disease course. Endoscopic and histological response to infliximab was investigated in a multicentre, randomised, double-blind, and placebo-controlled trial including 30 patients with active CD [85]. After 4 weeks of intravenous administration of 5, 10, or 20 mg/kg of infliximab or placebo as a single infusion, the endoscopic improvement was significantly superior in infliximab-treated patients as compared to the placebo group. Histologically, a disappearance of the inflammatory infiltrate was observed only in infliximab-treated patients; however, cytoarchitectural changes persisted in most patients.

These data were confirmed by an immunohistological study conducted in 15 patients with steroid-refractory CD treated with a single infusion of infliximab (5–20 mg/kg); 5 patients were treated with placebo [86]. After 4 weeks of infliximab, but not after placebo, the total histological activity score was significantly reduced in both ileitis and colitis patients, and the total histological disease activity decreased considerably, mainly due to the decrease in the inflammatory activity scores (reduction in the number of neutrophils in the epithelium and lamina propria). Immunohistochemical staining showed a decrease of inflammatory reactions, and the number of lamina propria mononuclear cells showed a global reduction of CD4 and CD8 T lymphocytes and CD68 monocytes. In a small study of 10 CD patients, the use of etanercept (another anti-TNFα agent) did not improve histological variables after 2 weeks [87].

Regarding biologicals, it is well known that anti-TNFα therapy can lead to MH in patients with UC [84,85], but to date histological data are limited. A small study investigating 9 moderate-severe UC patients treated for 10 weeks showed a significant decrease of the histological score only in responders (67% of the entire group); however, histological normalisation was observed in only 30% of these [88]. In another study, ultrastructural colonic features were studied in 7 UC patients before and after (2 weeks) infliximab treatment. After treatment, ultramicroscopic examination showed a morphological and functional improvement of the epithelial organelles, rich mucus secretion, and recovery of the chorionic components [89].

5. Conclusion

MH is an important goal in CD and UC therapy, and is associated with a reduced disease progression and improved quality of life. Moreover, it is an important factor (especially since the advent of biological therapies) in the reduction of the risk of colorectal malignancies in UC [22]. Ileocolonoscopy has become the gold standard in the management of inflammatory bowel disease and can be used to support therapeutic decision-making. At present, the endoscopic definition of MH is considered to be the absence of all ulcerations and inflammation, even though the use of several different endoscopic scoring systems, with different cutoff values, leads to differences in MH rates. Identifying cutoff values to distinguish the endoscopic response to treatments should enable endoscopic scores to be used in clinical practice to evaluate MH as a parameter of remission or relapse.

In terms of future research, it is important to establish the value of endoscopy as a means of guiding therapeutic changes and decision-making, to continue or stop therapy, or to switch to another treatment. Endoscopic re-evaluation should be used to identify non-responder patients, in whom an increased dosage, anticipated administration, or use of other drugs should be attempted. Furthermore, to improve the follow-up of IBD patients, it should be established whether histology should be included in the definition of MH. Since ileocolonoscopy in CD evaluates only the lower gastrointestinal tract, wireless capsule endoscopy must be considered to assess MH in the upper gastrointestinal tract. Moreover, as shown in Table 2, analysis of the published studies on biological agents demonstrates that different factors affect the rate of MH: (i) the definition of MH; (ii) the type of biological drug and other associated medications; (iii) the duration of treatment.

The timing of the endoscopic evaluation and a proper definition of MH need to be defined in prospective studies. To date, MH in IBD is still an underestimated issue [90]. Discrepancies between

histological, endoscopic and clinical data exist, but are rarely assessed in therapeutic trials. This poses a problem, since normal clinical, serological and endoscopic findings are not indicative of histological absence of disease activity. Thus, it is important and advisable to plan future studies that also feature, as a key element, a comparison between endoscopic and histological variables.

Conflict of interest statement

None declared.

List of abbreviations

IBD, inflammatory bowel disease; MH, mucosal healing; CD, Crohn's disease; UC, ulcerative colitis; Anti-TNFα, antibody against tumour necrosis factor α; CDEIS, Crohn's Disease Endoscopic Index Of Severity; SES-CD, simple endoscopic score for Crohn's disease; UCEIS, Ulcerative Colitis Endoscopic Index of Severity; The Lemann score, Crohn's Disease Digestive Damage Score.

References

[1] Rutgeerts P, Vermiere S, Assche GV. Mucosal healing in inflammatory bowel disease: impossible ideal or therapeutic target. Gut 2007;56:453–5.
[2] Lichtenstein GR, Ramsey D, Rubin DT. Randomised clinical trial: delayed-release oral mesalazine 4.8 g/day vs. 2.4 g/day in endoscopic mucosal healing—ASCEND I and II combined analysis. Alimentary Pharmacology and Therapeutics 2011;33:672–8.
[3] Modigliani R, Mary JY, Simon JF, et al. Clinical, biological, and endoscopic picture of Latest studies show that images taken with the CLE might offer information equivalent to conventional histology with a good correlation between CLE and histological results attacks of Crohn's disease. Evolution on prednisolone. Groupe d'Etude Therapeutique des Affections Inflammatoires Digestives. Gastroenterology 1990;98:811–8.
[4] D'Haens G, Geboes K, Rutgeerts P. Endoscopic and histologic healing of Crohn's ileo-colitis with azathioprine. Gastrointestinal Endoscopy 1999;50:667–71.
[5] Sandborn WJ, Kamm MA, Lichtenstein GR, et al. MMX Multi Matrix System mesalazine for the induction of remission in patients with mild-to-moderate ulcerative colitis: a combined analysis of two randomized, double-blind, placebo-controlled trials. Alimentary Pharmacology and Therapeutics 2007;26:205–11.
[6] Ardizzone S, Cassinotti A, Duca P, et al. Mucosal healing predicts late outcomes after the first course of corticosteroids for newly diagnosed ulcerative colitis. Clinical Gastroenterology and Hepatology 2011;9:483–9.
[7] Ardizzone S, Maconi G, Russo A, et al. Randomised controlled trial of azathioprine and 5-aminosalicylic acid for treatment of steroid dependent ulcerative colitis. Gut 2006;55:47–53.
[8] af Bjorkesten CG, Nieminen U, Turunen U, et al. Endoscopic monitoring of infliximab therapy in Crohn's disease. Inflammatory Bowel Diseases 2011;17:947e53.
[9] Rutgeerts P, Van Assche G, Sandborn WJ, et al. Adalimumab induces and maintains mucosal healing in patients with Crohn's disease: data from the EXTEND trial. Gastroenterology 2012;142, 1102e11.e2.
[10] Fischer A, Gluth M, Pape UF, Wiedenmann B, Baumgart DC. Adalimumab prevents barrier dysfunction and antagonizes distinct effects of TNF on tight junctions and signaling pathways in intestinal epithelial cells. American Journal of Physiology: Gastrointestinal and Liver Physiology 2013;304(11):G970–9.
[11] De Chambrun G, Peryrin Biroulet L, Lemman M, Colombel JF. Clinical Implications of mucosal healing for the management of IBD. Nature Reviews Gastroenterology & Hepatology 2010;7:15–29.
[12] Pineton de Chambrun G, Peyrin-Biroulet L, Lémann M, Colombel JF. Clinical implications of mucosal healing for the management of IBD. Nature Reviews Gastroenterology & Hepatology 2010;7:15–29.
[13] Fiorino G, Cesarini M, Indriolo A, Malesci A. Mucosal healing in ulcerative colitis: where do we stand? Current Drug Targets 2011;12:1417–23.
[14] D'Haens G, Sandborn WJ, Feagan BG, et al. A review of activity indices and efficacy end points for clinical trials of medical therapy in adults with ulcerative colitis. Gastroenterology 2007;132:763–86.
[15] William J, Sandborn WJ, Brian G, et al. A review of activity indices and efficacy end points for clinical trials of medical therapy in adults with Crohn's disease. Gastroenterology 2002;122:512–30.
[16] D'Haens GR, Fedorak R, Lemann M, et al. Endpoints for clinical trials evaluating disease modification and structural damage in adults with Crohn's disease. Inflammatory Bowel Diseases 2009;15:1599–604.
[17] Solberg IC, Lygren I, Jahnsen J, Vatn M, Moum B. Mucosal healing after initial treatment may be a prognostic marker for long-term outcome in inflammatory bowel disease. Gut 2008;57(Suppl. 2):A15.
[18] D'Haens G, Norman M, Baert F, Hiele M. Endoscopic healing after infliximab treatment for Crohn's disease provides a longer time to relapse. Gastroenterology 2002;122:100A.
[19] Schnitzler F, Fidder H, Ferrante M, et al. Mucosal healing predicts long term outcome of maintenance therapy with infliximab in Crohn's disease. Inflammatory Bowel Diseases 2009;15:1295–301.
[20] Froslie KF, Jahnsen J, Moum BA. Vatn Mucosal healing in inflammatory bowel disease: results from a Norwegian population-based cohort. Gastroenterology 2007;33:412–22.
[21] Casellas F, Barreiro de Acosta M, Robles V, et al. Mucosal healing restores normal health and quality of life in patients with inflammatory bowel disease. European Journal of Gastroenterology & Hepatology 2012;24:762–9.
[22] Actis GC, Pellicano R, David E, et al. Azathioprine, mucosal healing in ulcerative colitis, and the chemoprevention of colitic cancer: a clinical-practice-based forecast. Inflammation & Allergy Drug Targets 2010;9:6e9.
[23] Magro F, Portella F. Management of inflammatory bowel disease with infliximab and other anti-tumor necrosis factor alpha therapies. Bio Drugs 2010;24(Suppl 1):3–14.
[24] Peyrin-Biroulet L, Ferrante M, Magro F, et al. Results from the 2nd Scientific Workshop of the ECCO (I): impact of mucosal healing on the course of inflammatory bowel disease. Journal of Crohn's and Colitis 2011;5:477–83.
[25] David S, Fefferman, Farrell Richard J. Endoscopy in inflammatory bowel disease: indications, surveillance, and use in clinical practice. Clinical Gastroenterology and Hepatology 2005;3:11–24.
[26] Delpre G, Avidor I, Steinherz R, Kadish U, Ben-Bassat M. Ultrastructural abnormalities in endoscopically and histologically normal and involved colon in ulcerative colitis. American Journal of Gastroenterology 1989;84:1038–46.
[27] Neumann H, Vieth M, Atreya R, et al. Prospective evaluation of the learning curve of confocal laser endomicroscopy in patients with IBD. Histology and Histopathology 2011;26:867e72.
[28] Neumann H, Neurath MF, Mudter J. New endoscopic approaches in IBD. World Journal of Gastroenterology 2011;17:63e8.
[29] Kiesslich R, Goetz M, Lammersdorf K, et al. Chromoscopyguided endomicroscopy increases the diagnostic yield of intraepithelial neoplasia in ulcerative colitis. Gastroenterology 2007;132:874e82.
[30] Li CQ, Xie XJ, Yu T, et al. Classification of inflammation activity in ulcerative colitis by confocal laser endomicroscopy. American Journal of Gastroenterology 2010;105(6):1391–6.
[31] Watanabe O, Ando T, Maeda O, et al. Confocal endomicroscopy in patients with ulcerative colitis. Journal of Gastroenterology and Hepatology 2008;23(S2):S286–90.
[32] Kudo T, Matsumoto T, Esaki M, Yao T, Iida M. Mucosal vascular pattern in ulcerative colitis: observations using narrow band imaging colonoscopy with special reference to histologic inflammation. International Journal of Colorectal Disease 2009;24:495–501.
[33] Salvatori F, Siciliano S, Maione F, et al. Confocal laser endomicroscopy in the Study of Colonic Mucosa in IBD Patients: a review. Gastroenterology Research and Practice 2012;2012:525098.
[34] Nishio Y, Ando T, Maeda O, et al. Pit patterns in rectal mucosa assessed by magnifying colonoscope are predictive of relapse in patients with quiescent ulcerative colitis. Gut 2006;55:1768–73.
[35] Fujiya M, Saitoh Y, Nomura M, et al. Minute findings by magnifying colonoscopy are useful for the evaluation of ulcerative colitis. Gastrointestinal Endoscopy 2002;56(4):535–42.
[36] Matsumoto T, Kudo T, Jo Y, Esaki M, Yao T, Iida M. Magnifying colonoscopy with narrow band imaging system for the diagnosis of dysplasia in ulcerative colitis: a pilot study. Gastrointestinal Endoscopy 2007;66:957–65.
[37] Hlavaty T, Huorka M, Koller T, et al. Colorectal cancer screening in patients with ulcerative and Crohn's colitis with use of colonoscopy, chromoendoscopy and confocal endomicroscopy. European Journal of Gastroenterology & Hepatology 2011;23:680–9.
[38] van den Broek FJ, Fockens P, van Eeden S, et al. Endoscopic tri-modal imaging for surveillance in ulcerative colitis: randomized comparison of high-resolution endoscopy and autofluorescence imaging for neoplasia detection; and evaluation of narrow-band imaging for classification of lesions. Gut 2008;57:1083–9.
[39] Neumann H, Vieth M, Atreya R, et al. Assessment of Crohn's disease activity by confocal laser endomicroscopy. Inflammatory Bowel Diseases 2012, http://dx.doi.org/10.1002/ibd.22907 [Published Online First: 16 February 2012].
[40] Kiesslich R, Duckworth CA, Moussata D, et al. Local barrier dysfunction identified by confocal laser endomicroscopy predicts relapse in inflammatory bowel disease. Gut 2012;61:114653.
[41] http://clinicaltrials.gov/ct2/show/NCTO1417728
[42] Bourreille A, Ignjatovic A, Aabakken L, et al. Role of small bowel endoscopy in the management of patients with inflammatory bowel disease: an international OMED-ECCO consensus. Endoscopy 2009;41:618–37.
[43] Mary JY, Modigliani R. Development and validation of an endoscopic index of the severity for Crohn's disease: a prospective multicenter study. Groupe d'Etudes Therapeutiques des Affections Inflammatoires du Tube Digestif (GETAID). Gut 1989;30:983–9.

[44] Daperno M, D'Haens G, Assche GV, et al. Development and validation of a new, simplified endoscopic activity score for Crohn's disease: the SES-CD. Gastrointestinal Endoscopy 2004;60:505–12.
[45] Rutgeerts P. Review article: recurrence of Crohn's disease after surgery–the need for treatment of new lesions. Alimentary Pharmacology and Therapeutics 2006;24:29–32.
[46] Rutgeerts P, Geboes K, Vantrappen G, Beyls J, Kerremans R, Hiele M. Predictability of the postoperative course of Crohn's disease. Gastroenterology 1990;99:956–63.
[47] Rutgeerts P, Geboes K, Vantrappen G, Kerremans R, Coenegrachts JL, Coremans G. Natural history of recurrent Crohn's disease at the ileocolonic anastomosis after curative surgery. Gut 2004;25:665–72.
[48] Caprilli R. European evidence based consensus on the diagnosis and management of Crohn's disease: special situation. Gut 2006;55(Suppl. 1):i36–58.
[49] Rutgeerts P, Van Assche G. What is the role of endoscopy in the postoperative management of Crohn's disease? Inflammatory Bowel Diseases 2008;14(Suppl. 2):S179–80.
[50] Pariente B, Cosnes J, Danese S, et al. Development of the Crohn's disease digestive damage score, the Lémann score. Inflammatory Bowel Diseases 2011;17:1415–22.
[51] Truelove SC, Witts LJ. Cortisone in ulcerative colitis; final report on a therapeutic trial. British Medical Journal 1955;2:1041–8.
[52] Baron JH, Connell AM, Lennard-Jones JE. Variation between observers in describing mucosal appearances in proctocolitis. British Medical Journal 1964;1:89–92.
[53] Powell-Tuck J, Bown RL, Lennard-Jones JE. A comparison of oral prednisolone given as single or multiple daily doses for active proctocolitis. Scandinavian Journal of Gastroenterology 1978;13:971–6.
[54] Sutherland LR, Martin F, Greer S, et al. 5-Aminosalicylic acid enema in the treatment of distal ulcerative colitis, proctosigmoiditis and proctitis. Gastroenterology 1987;92:1894–8.
[55] Rachmilewitz D. Coated mesalazine (5-aminosalicylic acid) versus sulphasalazine in the treatment of ulcerative colitis: randomized trials. British Medical Journal 1989;298:82–6.
[56] Schoepfer AM, Beglinger C, Straumann A, Trummler M, Renzulli P, Seilbond F. Ulcerative Colitis: correlation of the Rachmilewitz Endoscopic Activity Index with fecal calprotectin, clinical activity, C-reactive protein and blood leukocytes. Inflammatory Bowel Diseases 2009;15:1851–8.
[57] Schroeder KW, Tremaine WJ, Ilstrup DM. Coated oral 5-aminosalicylic acid therapy for mildly to moderately active ulcerative colitis. A randomizes study. New England Journal of Medicine 1987;317:1625–9.
[58] Samuel S, Loftus EV, Bruining DH, et al. Validation of the ulcerative colitis endoscopic index of severity (UCEIS) and its correlation with clinical indices and laboratory measures of disease activity. Gastroenterology 2011;140:A851.
[59] Samuel S, Bruining DH, Loftus Jr EV, et al. Validation of the ulcerative colitis colonoscopic index of severity and its correlation with disease activity measures. Clinical Gastroenterology and Hepatology 2013;11:49–54.
[60] Villanacci V, Manenti S, Antonelli E, Chiudinelli M, Giuliano V, Bassotti G. Non-IBD colitides: clinically useful histopathological clues. Revista Espanola de Enfermedades Digestivas 2011;103:366–72.
[61] Stange EF, Travis SP, Vermeire S, et al. Warren BF; for the European Crohn's and Colitis Organization (ECCO). European evidence-based Consensus on the diagnosis and management of ulcerative colitis: Definitions and diagnosis. Journal of Crohns and Colitis 2008;2:1–23.
[62] Stange EF, Travis SP, Vermeire S, et al. European evidence based consensus on the diagnosis and management of Crohn's disease: definitions and diagnosis. Gut 2006;55(Suppl. 1):i1–15.
[63] Geboes K, Dalle I. Influence of treatment on morphological features of mucosal inflammation. Gut 2002;50(Suppl. 3):III37–42.
[64] Jenkins D, Balsitis M, Gallivan S, et al. Guidelines for the initial biopsy diagnosis of suspected chronic idiopathic inflammatory bowel disease. The British Society of Gastroenterology Initiative. Journal of Clinical Pathology 1997;50: 93–105.
[65] Seldenrijk CA, Morson BC, Meuwissen SG, Schipper NW, Lindeman J, Meijer CJ. Histopathological evaluation of colonic mucosal biopsy specimens in chronic inflammatory bowel disease: diagnostic implications. Gut 1991;32: 1514–20.
[66] Schumacher G, Kollberg B, Sandstedt B. A prospective study of first attacks of inflammatory bowel disease and infectious colitis. Scandinavian Journal of Gastroenterology 1994;29:318–32.
[67] Bitton A, Peppercorn MA, Antonioli DA, et al. Clinical, biological, and histologic parameters as predictors of relapse in ulcerative colitis. Gastroenterology 2001;120:13–20.
[68] Rosenberg L, Nanda KS, Zenlea T, et al. Histologic markers of inflammation in patients with ulcerative colitis in clinical remission. Clinical Gastroenterology and Hepatology 2013;11(8):991–6.
[69] Kruis W, Bar-Meir S, Feher J, et al. The optimal dose of 5-aminosalicylic acid in active ulcerative colitis: a dose-finding study with newly developed mesalamine. Clinical Gastroenterology and Hepatology 2003;1:36–43.
[70] Mansfield JC, Giaffer MH, Cann PA, McKenna D, Thornton PC, Holdsworth CD. A double-blind comparison of balsalazide, 6.75 g, and sulfasalazine, 3 g, as sole therapy in the management of ulcerative colitis. Alimentary Pharmacology and Therapeutics 2002;16:69–77.
[71] Kruis W, Kiudelis G, Rácz I, et al. International Salofalk OD Study Group Once daily versus three times daily mesalazine granules in active ulcerative colitis: a double-blind, double-dummy, randomized, non-inferiority trial. Gut 2009;58:233–40.
[72] Prantera C, Viscido A, Biancone L, Francavilla A, Giglio L, Campieri M. A new oral delivery system for 5-ASA: preliminary clinical findings for MMx. Inflammatory Bowel Diseases 2005;11:421–7.
[73] Floren CH, Benoni C, Willen R. Histologic and colonoscopic assessment of disease extension in ulcerative colitis. Scandinavian Journal of Gastroenterology 1987;22:459–62.
[74] Malchow H, Gertz B, CLAFOAM Study group. A new mesalazine foam enema (Claversal Foam) compared with a standard liquid enema in patients with active distal ulcerative colitis. Alimentary Pharmacology and Therapeutics 2002;16:415–23.
[75] Lee FI, Jewell DP, Mani V, et al. A randomized trial comparing mesalazine and prednisolone foam enemas in patients with acute distal ulcerative colitis. Gut 1996;38:229–33.
[76] Regueiro M, Loftus Jr EV, Steinhart AH, Cohen RD. Medical management of left-sided ulcerative colitis and ulcerative proctitis: critical evaluation of therapeutic trials. Inflammatory Bowel Diseases 2006;12:979–94.
[77] Truelove SC. Treatment of ulcerative colitis with local hydrocortisone hemisuccinate sodium. A report on a controlled therapeutic trial. British Medical Journal 1958;2:1072–7.
[78] Sandborn WJ, Van OEC, Zins BJ, Tremaine WJ, Mays DC, Lipsky JJ. An intravenous loading dose of azathioprine decreases the time to response in patients with Crohn's disease. Gastroenterology 1995;109:1808–17.
[79] D'Haens G, Geboes K, Ponette E, Penninckx F, Rutgeerts P. Healing of severe recurrent ileitis with azathioprine therapy in patients with Crohn's disease. Gastroenterology 1997;112:1475–81.
[80] D'Haens G, Geboes K, Rutgeerts P. Endoscopic and histologic healing of Crohn's (ileo-) colitis with azathioprine. Gastrointestinal Endoscopy 1999;50:667–71.
[81] D'Haens G, Geboes K, Peeters M, Baert F, Penninckx F, Rutgeerts P. Early lesions caused by infusion of intestinal contents in excluded ileum in Crohn's disease. Gastroenterology 1998;114:262–7.
[82] Mantzaris GJ, Christidou A, Sfakianakis M, et al. Azathioprine is superior to budesonide in achieving and maintaining mucosal healing and histologic remission in steroid-dependent Crohn's disease. Inflammatory Bowel Diseases 2009;15:375–82.
[83] Kozarek RA, Patterson DJ, Gelfand MD, Botoman VA, Ball TJ, Wilske KR. Methotrexate induces clinical and histologic remission in patients with refractory inflammatory bowel disease. Annals of Internal Medicine 1989;110:353–6.
[84] Laharie D, Reffet A, Belleannée G, et al. Mucosal healing with methotrexate in Crohn's disease: a prospective comparative study with azathioprine and infliximab. Alimentary Pharmacology and Therapeutics 2011;33:714–21.
[85] D'Haens G, Van Deventer S, Van Hogezand R, et al. Endoscopic and histological healing with infliximab anti-tumor necrosis factor antibodies in Crohn's disease: a European multicenter trial. Gastroenterology 1999;116: 1029–34.
[86] Baert FJ, D'Haens GR, Peeters M, et al. Tumor necrosis factor alpha antibody (infliximab) therapy profoundly down-regulates the inflammation in Crohn's ileocolitis. Gastroenterology 1999;116:22–8.
[87] D'Haens G, Swijsen C, Noman M, et al. Etanercept in the treatment of active refractory Crohn's disease: a single-center pilot trial. American Journal of Gastroenterology 2001;96:2564–8.
[88] Hassan C, Ierardi E, Burattini O, et al. Tumour necrosis factor alpha down-regulation parallels inflammatory regression in ulcerative colitis patients treated with infliximab. Digestive and Liver Disease 2007;39:811–7.
[89] Fratila OC, Craciun C. Ultrastructural evidence of mucosal healing after infliximab in patients with ulcerative colitis. Journal of Gastrointestinal and Liver Diseases 2010;19:147–53.
[90] Villanacci V, Antonelli E, Geboes K, Casella G, Bassotti G. Histological healing in inflammatory bowel disease: a still unfulfilled promise. World Journal of Gastroenterology 2013;19:968–78.