Orthopaedics & Traumatology: Surgery & Research 101 (2015) S11–S17

Available online at
ScienceDirect
www.sciencedirect.com

Elsevier Masson France
EM|consulte
www.em-consulte.com/en

Review article

Adult flatfoot

E. Toullec*

Polyclinique de Bordeaux-Tondu, 151, rue du Tondu, 33082 Bordeaux, France

ARTICLE INFO

Article history:
Accepted 8 July 2014

Keywords:
Flatfoot
Posterior tibialis tendon
Calcaneal osteotomy

ABSTRACT

Adult flatfoot is defined as a flattening of the medial arch of the foot in weight-bearing and lack of a propulsive gait. The 3 lesion levels are the talonavicular, tibiotarsal and midfoot joints. The subtalar joint is damaged by the consequent rotational defects. Clinical examination determines deformity and reducibility, and assesses any posterior tibialis muscle deficit, the posterior tibialis tendon and spring ligament being frequently subject to degenerative lesions. Radiographic examination in 3 incidences in weight-bearing is essential, to determine the principal level of deformity. Tendon (posterior tibialis tendon) and ligamentous lesions (spring ligament and interosseous ligament) are analyzed on MRI or ultrasound. In fixed deformities, CT explores for arthritic evolution or specific etiologies. 3D CT reconstruction can analyze bone and joint morphology and contribute to the planning of any osteotomy. Medical management associates insoles and physiotherapy. Acute painful flatfoot requires strict cast immobilization. Surgical treatment associates numerous combinations of procedures, currently under assessment for supple flatfoot: for the hindfoot: medial slide calcaneal osteotomy, calcaneal lengthening osteotomy, or arthroereisis; for the midfoot: arthrodesis on one or several rays, or first cuneiform or first metatarsal osteotomy; for the ankle: medial collateral ligament repair with tendon transfer. Fixed deformities require arthrodesis of one or several joint-lines in the hindfoot; for the ankle, total replacement after realignment of the foot, or tibiotalocalcaneal fusion or ankle and hindfoot fusion; and, for the midfoot, cuneonavicular or cuneometatarsal fusion. Tendinous procedures are often associated. Specific etiologies may need individualized procedures. In conclusion, adult flatfoot tends to be diagnosed and managed too late, with consequent impact on the ankle, the management of which is complex and poorly codified.

1. Introduction

Flatfoot is a syndrome combining multiple static and dynamic deformities, with flattening of the medial arch. This diversity explains the difficulty of analysis and hence of treatment.

The common point in all these deformities is failure of foot-locking during gait. It is thus important to understand the factors of foot stabilization in order to know which levels treatment should target.

Clinical assessment and complementary examinations determine the deformity and its reducibility. Radiologic assessment is systematically in weight-bearing, some forms of flatfoot being completely reduced under non-weight-bearing. Other examinations complete assessment and determine the status of the posterior tibial tendon (ultrasound or MRI), the evolutive stage of secondary osteoarthritis (CT) or certain etiologies.

Indications for surgery should take on board the components of the deformity and its reducibility at 3 levels: the talonavicular, tibiotarsal and midfoot joints.

2. Pathophysiology of flatfoot

Flatfoot is a pathology of the weight-bearing foot, which may under certain conditions induce posterior tibial tendon dysfunction. Locking failure may involve different levels:

- the talocalcaneonavicular joint, or coxa pedis: it lies at the summit of the medial arch, and is subject to the pressure of the talar head in plantigrade weight-bearing, increased by the advance of the tibia. The mid-plantar tendon-ligament sling constituted by the calcaneonavicular or "spring" ligament and the posterior tibial tendon play an essential role in the elastic support of the joint complex. Bonnel [1] described a type-III morphotype in which the talus is longer than the calcaneus, thus exerting greater pressure on the tendon-ligament structures. During gait, unipedal weight bearing acceptance lateralizes the body, thus reducing

* Correspondence. Tel.: +33(0)557819010; fax: +33(0)557819020.
E-mail address: toullec.eric2@wanadoo.fr

http://dx.doi.org/10.1016/j.otsr.2014.07.030
1877-0568/

mid-plantar tension and allowing dynamic action of the posterior tibial muscle. Progressive strain on the mid-plantar sling is the most common cause of flatfoot, causing midfoot abduction;
- the medial collateral ligament (MCL) of the tibiotarsal joint: it is subjected to stress when the heel strikes the ground, due to physiological non-alignment between the calcaneus and the tibia. MCL distension induces tibiotarsal valgus, with weight-bearing progressively displaced toward the medial edge of the foot, straining the more distal medial foot joints;
- the midfoot: raising the heel automatically induces dorsiflexion of the phalanges, leading to tension in the plantar muscles and fascia, known as the "windlass mechanism". This locks the midfoot joints; locking failure, encountered in case of first-ray hypermobility, leads to elevation of the first metatarsal during medial forefoot weight-acceptance, then to locking defect during unipodal weight-bearing and hallux toe-off.

Lesions in these three levels may be degenerative, but some may have a specific cause. Long-standing trauma such as ankle sprain, with often neglected medial involvement of the tibiotarsal or midfoot joints, should be explored for.

Flatfoot assessment should thus focus on all three levels, plus the subtalar joint, which is subject to abnormal rotational stress in flatfoot.

3. Diagnosis

3.1. Pain

Flatfoot is considered pathological only when symptomatic.

Pain is generally located in the medial part of the hindfoot [2], along the posterior tibial tendon, sometimes associated with effusion into the tendon sheath. Pain may be plantar and deep, suggesting spring ligament lesion. Even so, such pain may be caused by another pathology, such as talocalcaneal synostosis coalition or talonavicular, subtalar or mediotarsal osteoarthritis.

Pain may also be lateral, due to fibulocalcaneal impingement in severe tibiotalar valgus, calcaneocuboid impingement in severe forefoot abduction, or impingement between the lateral tubercle of the talus and dorsal angle of Gissane of the anterior apophysis of the calcaneus in case of rotation and slippage of the talus.

3.2. Clinical assessment

Clinical assessment should determine the characteristics of the deformity and whether deformities of the tibiotalar and subtalar joints and Chopart and Lisfranc joint-lines are reducible.

Range of motion is assessed, and joint stiffness is screened for as it points to synostosis coalition or osteoarthritis.

3.2.1. Hindfoot

The bipedal tiptoe test normally induces hindfoot inversion. Inversion loss or eversion points to subtalar and Chopart's joint dysfunction (stiffening or hyperlaxity) and/or posterior tibial muscle deficiency.

Abduction is analyzed with the patient standing, with the examiner behind to observe the "too-many-toes sign", or else in dorsal decubitus, to observe the plantar face of the foot with a break in the lateral edge in abduction. Hallux valgus is often associated.

The posterior tibial tendon is tested in inversion against resistance starting with the foot in eversion. Note is taken of resulting pain and loss of muscle force. Complete motor assessment of the foot muscles is performed to explore for neurologic etiology.

The unipedal tiptoe test assesses posterior tibial muscle and spring ligament function:
- if the foot moves into eversion on unipedal tiptoe weight-acceptance (or the heel fails to rise) although the bipedal tiptoe position can be achieved normally, the posterior tibial tendon is involved;
- reduced active inversion may suggest a spring ligament lesion [3];
- pain along the posterior tibial tendon on repeating the test is a sign of tendinitis.

In some cases, tendon-muscle retraction may fix the deformity under weight-bearing: valgus fixed by the sural triceps and abduction by the fibular muscles. Ankle examination in plantar flexion, which relaxes these tendons, determines whether there is associated joint stiffness.

3.2.2. Tibiotalar joint

Ankle dorsiflexion deficit, with hindfoot valgus corrected, is assessed with the knee in extension and then flexed, exploring for gastrocnemial retraction (Silfverskiold test).

Hindfoot valgus under weight-bearing may be due to medial laxity of the ankle or to forefoot supination.

Medial laxity of the ankle is not always easy to detect.

Forefoot supination is analyzed with the patient in dorsal decubitus, with hindfoot valgus corrected.

The reverse Coleman test demonstrates hindfoot valgus correction by placing a 2-cm block under the first metatarsal head.

3.2.3. Midfoot

Three elements are explored for in the midfoot: supination, first-ray hypermobility, and osteoarthritic stiffness.

3.2.3.1. Supination. It is important to determine whether supination is fixed, using the Hintermann test [4], which consists in external rotation of the limb with the foot under weight-bearing. If the first metatarsal head rises, supination is fixed and, if not, is reducible.

3.2.3.2. First-ray hypermobility. Hypermobility of the first cuneometatarsal joint [5] is explored for by moving the first ray, held between thumb and index finger, downward and upward while holding the metatarsal bones in the other hand.

There may be a plantar corn under the second metatarsal head.

Gait shows first-ray elevation on forefoot weight-acceptance.

Passive hallux dorsiflexion (Jack test) explores for possible raising of the medial arch of the foot. It may be performed with or without weight-bearing; in weight-bearing, it may require passive correction of the hindfoot valgus causing excessive tension in the flexor hallucis longus tendon. Normally, first metatarsophalangeal joint dorsiflexion induces passive tension in the sesamoid muscles and flexor hallucis longus, stabilizing and thus, lowering the medial arch. In first-ray hypermobility, the foot does not arch and first metatarsophalangeal joint shows hyperdorsiflexion in non-weight-bearing, with a soft stop indicating plantar muscle locking defect.

3.2.3.3. Osteoarthritic stiffness. Osteoarthritic stiffness is indicated by dorsal swelling due to osteophytosis and impaired Lisfranc joint motion.

3.3. Complementary imaging investigations

3.3.1. X-ray

First-line assessment comprises 3 weight-bearing radiographs: dorsoplantar for abduction, lateral for flattening, and AP view with Méary cerclage for valgus.

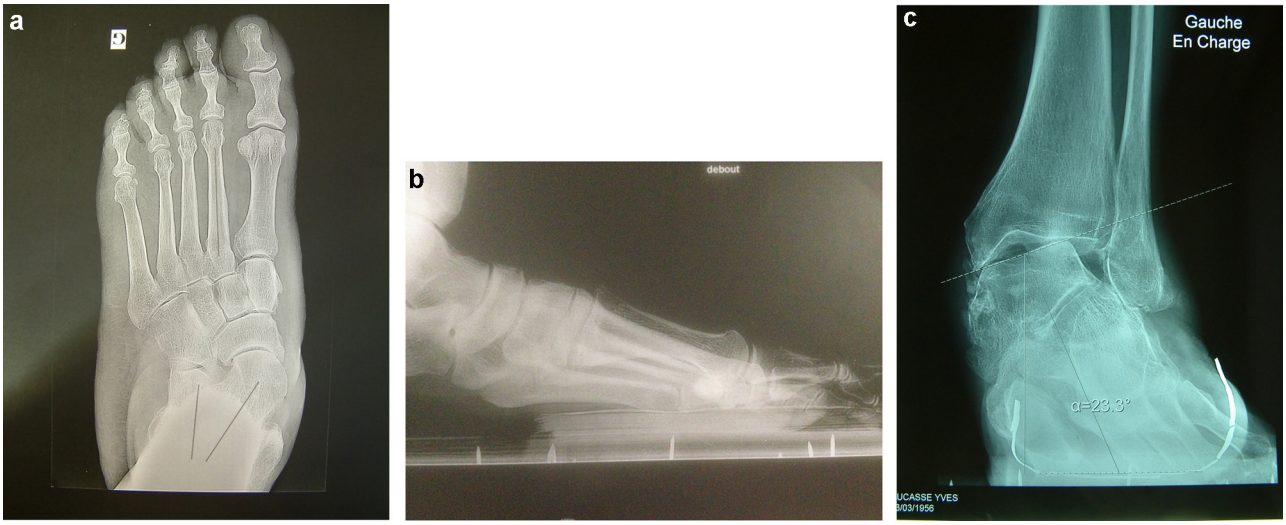

Fig. 1. Weight-bearing X-ray assessment showing lesion levels: a: AP dorsoplantar view (G = left): talonavicular subluxation by uncovering of talar head and talar-2nd metatarsal angle; b: lateral view (standing patient): first-ray hypermobility (*debout* = standing); c: AP ankle or Meary view: valgizing tibiotarsal osteoarthritis, (*gauche, en charge* = left, weight-bearing).

3.3.1.1. Abduction. Abduction is measured on dorsoplantar view as the angle subtended by the talus and first or second metatarsal, talar uncoverage and talocalcaneal divergence angle, showing the degree of talar rotation (Fig. 1a). Abduction is measured on dorsoplantar view by the talo-1srt metatarsal ou talo-2nd metatarsal angle, the talar head uncoverage and the talocalcaneal angle showing the degree of talar rotation.

3.3.1.2. Talar flattening. Talar flattening is assessed on lateral view by the angle subtended by the talus and first metatarsal (normal = 0°), and calcaneal flattening by calcaneal slope (normal = 15–20°) and talocalcaneal divergence angle (normal = 25–35°). It is important for the first ray to be in weight-bearing when this view is taken, as certain lateral views may be normal due to deformity correction (radiographic Hintermann test). This view locates medial arch breakage, dorsal impingement in case of osteoarthritis and plantar gap in case of hypermobility. Plantar gap is best detected by placing a block under the first metatarsal (Fig. 1b). Tibiotalar equinus can be measured.

3.3.1.3. Valgus. Valgus can be assessed on AP view with Méary cerclage (pathological if > 8°). It reveals tibiotalar joint morphology, very occasionally fibular fracture, tibiotalar medial laxity or osteoarthritis with lateral joint-line narrowing and talar displacement indicating grade IV (Fig. 1c).

3.3.1.4. Stress Xrays. Radiographs in forced valgus-varus for the tibiotalar joint, in abduction-adduction for the Chopart joint and elevation-lowering for the Lisfranc joint screen for joint laxity.

3.3.2. Ultrasound

Ultrasound is an inexpensive but operator-dependent investigation assessing posterior tibial tendon and spring ligament status, but also all of the tibiotalar and medial midfoot ligaments.

3.3.3. MRI

MRI also detects posterior tibial tendon, spring and interosseous ligament lesions, although certain fissures or tears may be overlooked.

In case of impingement with the lateral tubercle of the talus, it reveals cancellous bone edema and cysts in the anterior apophysis of the calcaneus.

3.3.4. CT

Stiff flatfoot is examined by CT, exploring for talocalcaneal or calcaneonavicular synostosis coalition in young patients and subtalar, tibiotalar, talonavicular or Lisfranc joint osteoarthritis in older patients.

3D reconstruction provide more precise morphologic analysis (Fig. 2a) and better analysis of the subtalar joint surface of the calcaneus by talar subtraction, to characterize the joint surface according to Bunning [6] and thereby orient Evans' osteotomy of the anterior apophysis of the calcaneus (Fig. 2b).

3.4. Characterization of clinical and imaging data

At the end of clinical and imaging assessment, the flatfoot should be classified according to severity and etiology.

3.4.1. Secondary flatfoot

In certain cases of flatfoot, history taking and complete assessment reveals some specific etiology:

- osseous origin (posttraumatic deformity, or growth disorder);
- articular origin (rheumatoid destruction, diabetic Charcot foot, or Marfan hyperlaxity);
- or tendon-muscle or neurologic origin.

Traumatic etiologies are the most frequent: neglected medial tibiotalar ligament or Lisfranc lesions or malunion of talar or calcaneal fracture.

3.4.2. Congenital flatfoot

Reducible idiopathic flatfoot is rarely symptomatic [2]. Stiffness should raise suspicion of contracted flatfoot or synostosis coalition, or congenital or neurologic bone dysplasia.

In congenital flatfoot, further morphologic changes occur during growth.

3.4.3. Degenerative flatfoot

Degenerative flatfoot usually affects overweight menopausal women. Reducible and fixed forms are to be distinguished. Bluman [7] further distinguishes valgus and abduction forms, for therapeutic purposes.

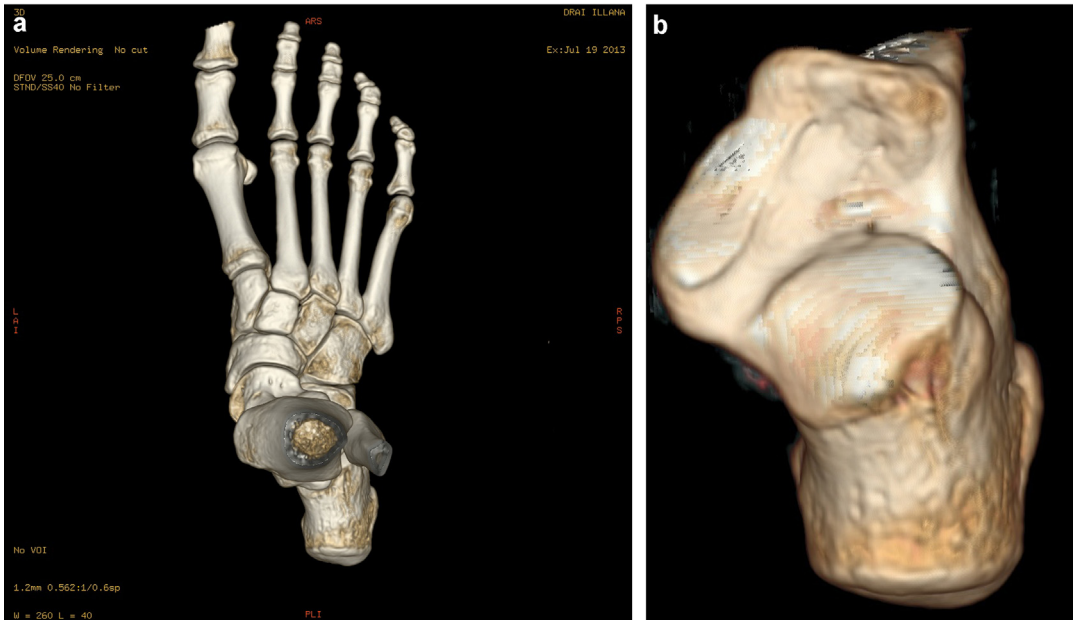

Fig. 2. 3D CT: a: enabling global analysis of foot bone deformity; b: subtalar subtalar calcaneal dorsal view, essential for planning Evans' osteotomy (Bunning type B2).

Medial tibiotarsal or first-ray hyperlaxity should be systematically explored for.

4. Treatment

Before considering surgery, medical treatments are to be prescribed. They are of varying efficacy.

4.1. Medical treatment

The medical treatment:

- insoles and shoes with rigid counters are most commonly advised. However, although they may acceptably alleviate pain, the deformity is not corrected [8];
- a supination wedge or medial support arch can correct valgus but may worsen abduction, to be compensated for by an anterior pronation wedge if the deformity is reducible;
- in severe non-operable forms, customized orthopedic shoe-wear is prescribed;
- rehabilitation should not be forgotten, to combat triceps muscle or fibular tendon retraction and reinforce the toe flexors to compensate for posterior tibial muscle weakness;
- in case of acute pain, 2–6 weeks' immobilization in inversion in resin cast or strapping can provide relief.

4.2. Surgical treatment

In case of failure of medical treatment, surgery is indicated. Raikin's RAM classification [9] distinguishes 3 levels of flatfoot: hindfoot, ankle and midfoot (Table 1).

In the hindfoot Raikin analyzes reducibility and abduction; in the ankle, valgus, medial laxity and osteoarthritis; and in the midfoot, supination, first-ray hypermobility and Lisfranc osteoarthritis.

4.2.1. Hindfoot techniques

All hindfoot techniques can be used for reducible flatfoot, but only hindfoot fusion is indicated in fixed flatfoot.

4.2.1.1. Medial translation calcaneal osteotomy. This procedure, assessed by Myerson [10], corrects hindfoot valgus by medial translation of the calcaneal tuberosity, realigning the calcaneal tendon.

The drawback lies in increased lateral rotation of the foot, which has to be compensated for by tensing the posterior tibial tendon or repairing it, if torn, by tendon transfer.

4.2.1.2. Arthroereisis or sinus tarsi implant. Arthroereisis was described in congenital childhood flatfoot; application in adults is controversial. Reduced talocalcaneal divergence is maintained by a screw fixed vertically in the anterior apophysis of the calcaneus anterior to the reduced lateral process of the talus ("calcaneo-stop" technique) or by a metal or polyethylene expansion screw in the sinus tarsi [11].

This procedure acts on the subtalar joint, but does not always fully correct flatfoot and may have to be associated to other tendon or bone procedures.

The main drawback is regular sinus tarsi pain, requiring removal of material while avoiding secondary correction loss.

4.2.1.3. Evans' calcaneal lengthening osteotomy. Lengthening the anterior apophysis of the calcaneus with a triangular bone wedge corrects abduction and automatically raises the medial arch due to the oblique position of the talar head [12,13] (Fig. 3).

The osteotomy causes the navicular bone to push against the talar head, reducing talocalcaneal divergence and partially reducing hindfoot valgus by rotation of the talus. It is essential to reduce the talar-first metatarsal axis to achieve a windlass effect in hallux dorsiflexion.

The drawback lies in increased calcaneocuboid pressure, to be corrected by lengthening the fibularis peroneus brevis tendon, with good talonavicular joint reduction. Calcaneocuboid fusion with lengthening graft is a solution, but with a risk of non-union.

Evans' osteotomy performed blind on a lateral approach may involve the anteromedial or anterolateral subtalar joint surfaces, especially in Bunning type B2 [6], without the secondary osteoarthritis described in the literature.

Z or Scarf calcaneal osteotomy, described by Malerba and Weil [14], enables displacement in several planes: lengthening, varization and translation.

Table 1
Raikin's classification of adult valgus flatfoot lesions.

	Hindfoot	Ankle	Midfoot
Ia	Tenosynovitis of PTT	Neutral alignment	Neutral alignment
Ib	PTT tendinitis	Mild valgus < 5°	Mild flexible supination
IIa	Flexible valgus flatfoot Talar coverage < 40°, Méary angle talo-1srt metatarsal angle < 30°, Talocalcaneal incongruency angle 20–45°	Valgus and deltoid insufficiency	Supination without radiologic instability
IIb	Supple valgus flatfoot Talar coverage > 40°, Méary angle talo-1srt metatarsal angle > 30°, Talocalcaneal incongruency angle > 45°	Valgus and deltoid insufficiency and tibiotarsal osteoarthritis	Supination with midfoot instability (without osteoarthritis)
IIIa	Stiff, osteoarthritic valgus flatfoot Talar coverage < 40°, Méary angle talo-1srt metatarsal angle < 30°, talo-1srt metatarsal angle Talocalcaneal incongruency angle 20–45°	Valgus secondary to bone loss in the lateral tibial plafond (normal deltoid)	Arthritic changes isolated to medial column
IIIb	Stiff, osteoarthritic valgus flatfoot Talar coverage > 40° Méary angle > 30°, vb, talo-1srt metatarsal angle Talocalcaneal incongruency angle > 45°	Valgus secondary to bone loss in the lateral tibial plafond and deltoid insufficiency	Medial and middle column midfoot arthritic changes

4.2.1.4. Hindfoot fusion. The most common procedure is subtalar and mediotarsal fusion, correcting subtalar valgus, medial arch collapse and Chopart joint supination [15] (Fig. 4).

Reduction should include talar rotation and anterior talar slide, reducing the height between the posterior edges of the calcaneus and tibia. It may, however, be very difficult, or indeed incomplete.

Calcaneocuboid fusion is not systematic, but is necessary in osteoarthritic flatfoot in abduction, and should be associated to a lengthening graft.

A dual approach is classical, but a single medial approach is recommended to limit skin tension and risk of cicatricial necrosis and to tense the posterior tibial tendon if it is not torn.

Isolated talonavicular or subtalar fusion may be indicated in case of incipient localized osteoarthritis.

4.2.2. Techniques for ankle valgus

Tibiotalar valgus is a sign of severe degenerative valgus flatfoot; it can be managed, but treatment is best codified and results are most reliable in posttraumatic valgus with medial collateral ligament lesion.

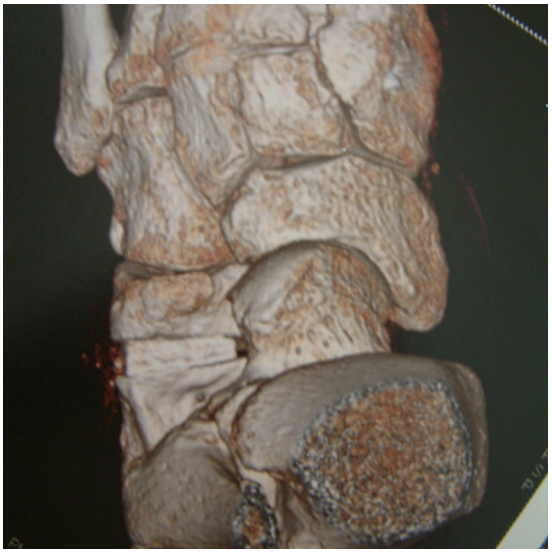

Fig. 3. Evans' calcaneal lengthening osteotomy (dorsal CT view of foot), allowing correction of abduction.

4.2.2.1. Medial ligament repair. Traumatic medial collateral ligament lesion requires retensioning by pants over vest suture or shortening suture after resection of the medial part of the distended ligament.

Valgus should systematically be corrected by associated calcaneal osteotomy.

Repair of a degenerative medial tibiotalar ligament with involvement of the spring ligament and posterior tibial tendon is difficult and is presently under assessment. Due to failure of isolated retension and transosseous reinsertion, tendon transfer is recommended (plantaris for Hintermann [16], fibularis peroneus longus for Deland [17] and heterologous tendon graft for Myerson [18]), with a non-anatomic trajectory due to the numerous medial collateral ligament bundles.

4.2.2.2. Valgizing tibiotalar osteoarthritis. The valgus may be reducible or fixed.

In moderate osteoarthritis with misalignment, supramalleolar osteotomy is feasible [19], sometimes associated to malleolar repositioning osteotomy (lowering the lateral malleolus and shortening the medial malleolus).

In severe osteoarthritis, if the foot can be realigned (usually by corrective subtalar and Chopart's joints fusion) ankle replacement [20] may be indicated if the surgeon is experienced.

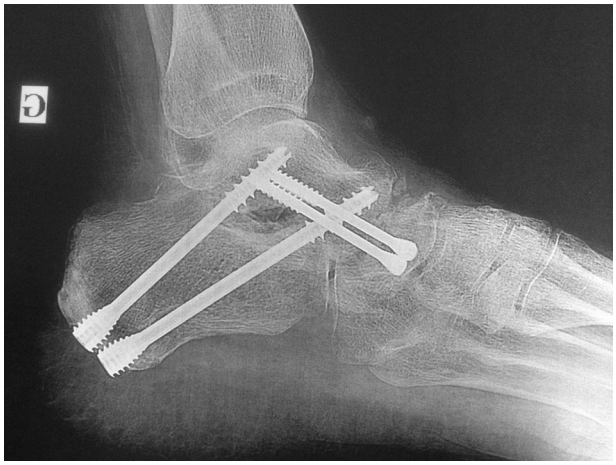

Fig. 4. Subtalar and talonavicular fusion remains the most widely indicated technique in adult flatfoot (*G* = left).

Table 2
Recommended procedures according to Raikin's adult flatfoot lesion classification.

	Hindfoot	Ankle	Midfoot
Ia	Medical tenosynovectomy	No treatment	No treatment
Ib	Posterior tibial tendon repair	No treatment	Insoles
IIa	Medial calcaneal translation osteotomy + FDB transfer + Gastrocnemius lengthening	Deltoid reconstruction	First cuneiform osteotomy (plantar subtraction or dorsal addition = Cotton)
IIb	Evans + medial arch stabilization, Calcaneocuboid fusion with lengthening	Ankle and hindfoot fusion or TAR + deltoid	Cotton, Lapidus, cuneonavicular fusion
IIIa	Joint fusion + Achilles lengthening	Tibiotalar fusion or TAR	Lapidus
IIIb	Double arthrodesis with calcaneal lengthening/medializing calcaneal osteotomy + Achilles	Tibiotalar fusion or TAR + medial collateral ligament reconstruction	Medial and central lisfranc fusion

In severe osteoarthritis, if the foot cannot be realigned, tibiotalo-calcaneal fusion [21] and ankle and hindfoot fusion relieve pain, but with imperfect function.

Given the difficulty of managing tibiotalar involvement, symptomatic flatfoot should be treated before osteoarthritis sets in.

4.2.3. *Midfoot surgery*

The midfoot should be assessed systematically after the hindfoot has been treated. Persistent postoperative supination will induce valgization, jeopardizing consolidation.

4.2.3.1. Supination: first-ray lowering osteotomy. The first ray can be lowered at several levels. Plantar subtraction of the first cuneiform induces shortening, while dorsal addition of the first cuneiform, recommended by Cotton [22], or of the first metatarsal base induces lengthening, with a stabilizing effect on hypermobility.

The drawback is a risk of tarsal hump, with difficulties of footwear.

In associated hallux valgus, lowering is achieved by Scarf or chevron first metatarsal osteotomy.

4.2.3.2. First-ray hypermobility. Dorsal addition of the first cuneiform in some cases stabilizes the first ray with a dorsal block effect.

Cuneometatarsal fusion, as described by Lapidus, and its variants, however, is the treatment of choice [23] (Fig. 5). These techniques are difficult, as the metatarsal bones have to be well-positioned to avoid metatarsalgia by transfer or hyperpressure under the first metatarsal head. Non-union is frequent, due to insufficient fixation or midfoot torsion caused by a short first metatarsal or abnormal metatarsal rotation. Bone graft may be necessary to maintain first metatarsal length, with anti-rotation fixation by axial compression screw associated to a dorsal plate.

Fig. 5. Cuneometatarsal fusion, a demanding treatment of cuneometatarsal hypermobility and medial midfoot osteoarthritis (*Gauche debout* = left standing).

4.2.3.3. Midfoot osteoarthritis. Osteoarthritis is secondary either to excessive midfoot torsion caused by supination or to midfoot hypermobility inducing dorsal cuneometatarsal or cuneonavicular joint-line narrowing. Axial midfoot hyperpressure is associated, due to first-ray insufficiency caused by hallux valgus or hypermobility.

It requires fusion of the first 3 cuneometatarsal joints and correction of the pronation-supination malalignment.

4.2.4. *Surgical management of tendon imbalance according to the selected technique*

Management of calcaneal and fibular peroneus tendon retraction depends on the severity and the technique used.

In Evans' osteotomy and some cases of arthroereisis, the fibularis peroneus brevis and, more rarely, the fibularis peroneus longus tendon are lengthened by two hemitenotomies on either side of the tendon, 3 centimeters apart.

In Evans' osteotomy, triple arthrodesis and some cases of arthroereisis, the calcaneal tendon is lengthened (percutaneously, by Strayer's procedure [24] or by release of the gastrocnemius white fibers).

Posterior tibial tendon repair associated to spring ligament repair is indicated in all hindfoot surgery except Evans' osteotomy. Various techniques may be used: fissure repair, tenosynovectomy, Kidner's transosseous retensioning of the posterior tibial tendon [25] or, in case of tear, various tendon transfers: hemi-anterior tibial (Cobb [26]), flexor digitorum longus [27] or flexor hallucis longus [28].

Posterior tibial tendon repair should be systematically associated to realignment of the foot in advanced valgus flatfoot; isolated repair is only for tears without deformity.

4.2.5. *Combined techniques*

The interest of Raikin's classification [9] is that it stresses 3-level valgus flatfoot lesion analysis, with 3-level surgery (Table 2).

Certain aspects, however, are overlooked:

- it does not cover the frequently associated hallux valgus, which can be treated at the same time as the midfoot: Scarf or chevron osteotomy, lowering the first ray;
- grade RIIIb corresponds to fixed flatfoot in severe abduction, but does not take account of talonavicular dislocation, which causes particular technical difficulties in restoring first-ray length and repositioning the talus;
- spontaneous fibula fracture, contributing to tibiotarsal osteoarthritis, calls for diagnostic and therapeutic precision.

4.2.6. *Specific etiologies*

Specific etiologies require specific treatment.

Triple arthrodesis is indicated for advanced rheumatoid evolution, posttraumatic osteoarthritis or neurologic sequelae; deviations can be corrected in the same step.

Neurologic deformities require tendon transfer or lengthening according to the muscles involved.

Certain congenital or posttraumatic deformities require axial correction by suitable osteotomy [29].

5. Conclusion

The syndrome of valgus flatfoot covers a range of diverse deformities and nosological entities all resulting in a non-propulsive gait.

Ahead of treatment, involvement at 3 joint levels needs to be determined: tibiotalar, talonavicular and mediotarsal.

The subtalar joint undergoes the rotational consequences of insufficiency of subtalar and Chopart's joints.

Surgery should treat all involved levels, and may be long and complex.

Symptomatic flatfoot surgery should preferably be indicated early, while only a single joint is involved and, above all, the tibiotalar joint is spared.

Disclosure of interest

The author declares that he has no conflicts of interest concerning this article.

References

[1] Bonnel F, Teissier P, Maestro M, Ferré B, Toullec E. Biométrie des composants osseux de l'articulation talo-naviculaire : étude cadavérique. Rev Chir Orthop 2011;97(6):S161–9.
[2] Wicart P, Toullec E. Le pied plat idiopathique. In: Seringe R, Besse JL, Wicart P, editors. Cahier d'enseignement de la SOFCOT : les déformations du pied de l'enfant et de l'adulte. Paris: Elsevier Masson; 2010. p. 157–73.
[3] Tryfonidis M, Jackson W, Mansour R, Cooke PH, Teh J, Ostlere S, et al. Acquired adult flat foot due to isolated plantar calcaneonavicular (spring) ligament insufficiency with a normal tibialis posterior tendon. Foot Ankle Surg 2008;14(2):89–95.
[4] Hintermann B, Gachter A. The first metatarsal rise sign: a simple, sensitive sign of tibialis posterior tendon dysfunction. Foot Ankle Int 1996;17(4):236–41.
[5] Cowie S, Parsons S, Scammell B, McKenzie J. Hypermobility of the first ray in patients with planovalgus feet and tarsometatarsal osteoarthritis. Foot Ankle Surg 2012;18(4):237–40.
[6] Bunning PSC, Barnett CH. Variations in the talocalcaneal articulations. J Anat 1963;97:643–8.
[7] Bluman E, Myerson M. Stage IV posterior tibial tendon rupture. Foot Ankle Clinics 2007;12:341–62.
[8] Staheli LT, Chew DE, Corbett M. The longitudinal arch: a survey of eight hundred and eighty-two feet in normal children and adults. J Bone Joint Surg 1987;69-A:426.
[9] Raikin SM, Winters BS, Daniel JN. The RAM classification: a novel, systematic approach to the adult-acquired flatfoot. Foot Ankle Clinics 2012;17:169–81.
[10] Myerson MS, Corrigan J. Treatment of posterior tibial tendon dysfunction with flexor digitorum tendon transfer and calcaneal osteotomy. Orthopedics 1996;19(5):383–8.
[11] Fernández de Retana P, Alvarez F, Bacca G. Is there a role for subtalar arthroereisis in the management of adult-acquired flatfoot? Foot Ankle Clin 2012;17(2):271–81.
[12] Evans D. Calcaneo-valgus deformity. JBJS 1975:270–8.
[13] Mosca V. Calcaneal lengthening for valgus deformity of the hindfoot. Results in children who had severe, symptomatic flatfoot and skewfoot. JBJS Am 1995;77(4):500–12.
[14] Weil LS, Roukis T. The calcaneal scarf osteotomy: operative technique. J Foot Ankle Surg 2001;40(3):178–82.
[15] Staquet V, Mehdi N, Naudi S, Maynou C, Mestdagh H. Résultats à long terme du traitement du pied plat valgus de l'adulte par arthrodèse médio-tarsienne. Rev Chir Orthop 2007;9:469–77.
[16] Hintermann B, Valderrabano V, Boss, et al. Medial ankle instability: an exploration, prospective study of fifty-two cases. Am J Sport Med 2004;32(1):183–90.
[17] Deland JT, De Asla RJ, Segal A. Reconstruction of a chronically failed deltoid ligament: a new technique. Foot Ankle Int 2004;25(11):795–9.
[18] Bluman EM, Myerson MS. Stage IV posterior tibial tendon rupture. Foot Ankle Clin N Am 2007;12:341–62.
[19] Bluman EM, Chiodo CP. Valgus ankle deformity and arthritis. Foot Ankle Clin N Am 2008;13:443–70.
[20] Coetze JC. Management of varus or valgus ankle deformity with ankle replacement. Foot Ankle Clin N Am 2008;13:509–20.
[21] Chou LB, Mann RA, Yaszay B, et al. Tibiotalocalcaneal arthrodesis. Foot Ankle Int 2000;21(10):804–8.
[22] Yarmel D. The cotton osteotomy: a technical guide. J Foot Ankle Surg 2009;48(4):506–12.
[23] McCormick JJ, Johnson JE. Medial column procedures in the correction of adult-acquired flatfoot deformity. Foot Ankle Clin 2012;17(2):283–98.
[24] Chen L, Greisberg J. Achilles lengthening procedures. Foot Ankle Clinics N Am 2009;14:627–37.
[25] Clark GC. A modified Kidner procedure for symptomatic flatfeet. Clin Orthop 1988;228:258–60.
[26] Knupp M, Hintermann B. The Cobb procedure for treatment for acquired flatfoot deformity associated with stage II insufficiency of posterior tibial tendon. Foot Ankle Int 2007;28(4):416–21.
[27] Feldman NJ. In situ tibialis posterior to flexor digitorum longus tendon transfer for tibialis posterior tendon dysfunction: a simplified surgical approach with outcome of 11 patients. J Foot Ankle Surg 2001;40(1):2–7.
[28] Sammarco GJ, Hockenbury RT. Treatment of stage II posterior tibial tendon dysfunction with flexor hallucis longus tendon transfer and medial displacement calcaneal osteotomy. Foot Ankle 2001;22(4):305–12.
[29] Mosca VS, Bevan WP. Talocalcaneal tarsal coalitions and the calcaneal lengthening osteotomy: the role of deformity correction. J Bone Joint Surg Am 2012;94(17):1584–94.

Further readings

For more information: Recommended works

Les Pieds Plats Valgus. Symposium sous la direction de C Maynou et E Toullec : monographie de l'AFCP n° 6 (JL Besse, JA Colombier, M Maestro) – Sauramps Médical 2010: 17–169.

Advances in Posterior Tibial Tendon Insufficiency. Chiodo CP, Myerson MS. Foot Ankle Clinics 2007 June, 12 (2). Saunders Elsevier.

Adult flatfoot. Raikin SM, Myerson MS. Foot Ankle Clinics 2012 June, 17(2) Saunders Elsevier.