

Endovascular abdominal aortic aneurysm repair in patients with common iliac artery aneurysms – Initial experience with the Zenith bifurcated iliac side branch device

Ferdinand Serracino-Inglott, MD, MSc, DIC, FRCSI, FRCS (GenSurg), Alan E. Bray, MD, FRACS, DDU, and Paul Myers, MBBS (Syd), FRCS (Eng), FRACS, Newcastle, New South Wales, Australia

Objective: To present our initial experience with the Zenith bifurcated iliac side branch device that preserves internal iliac artery flow whilst excluding aorto-iliac aneurysms.

Methods: Between November 2005 and October 2006, data was prospectively collected on 8 patients in whom this device was used; 2 aorto-bi-iliac aneurysms, 3 aorto-uni-iliac aneurysms, 1 solitary common iliac aneurysm, 1 distal type 1 endoleak, and 1 internal iliac aneurysm.

Results: No mortality or major complications resulted from use of this device. The median fluoroscopy time was 53 minutes (range 38 to 105) and a median of 102 g of iodine (range 84 to 130) as contrast were used. One patient required a blood transfusion and only one of the eight side branches occluded. There has been no endoleak related to the device in the median follow-up period of 6 months (1 to 14 months).

Conclusion: This device provides an alternative for the management of patients with aorto-iliac aneurysms that is safe and less complex than, previously described, hybrid procedures that preserve internal iliac flow. (*J Vasc Surg* 2007;46:211-7.)

A significant proportion of patients presenting for endovascular abdominal aortic aneurysm repair (EVAR), are found to have ectatic or aneurysmal common iliac arteries. In a number of these patients, one or both distal common iliac arteries are unsuitable for use as a distal landing zone, despite the development of “bellbottom” techniques.¹ In such patients, EVAR usually necessitates the occlusion of one or both internal iliac arteries and extension of the stent graft into the external iliac artery. Various series have estimated that this is necessary in 15% to 30% of cases.²⁻⁶ Occlusion of one internal iliac artery is usually achieved by coil embolization or the use of an occluder device. Such procedures are usually well tolerated, but may result in buttock claudication,^{2,4,7-10} postprocedure sexual dysfunction,^{7,8,10} and colonic ischemia.^{4,11} Complications are more likely and more serious after bilateral internal iliac artery occlusion. Sloughing of the scrotal skin,¹² non-healing decubitus ulcers,² and ischemia to the lumbosacral plexus¹³ resulting in weakness and numbness to both lower limbs with bowel and bladder incontinence, have all been reported following bilateral internal iliac occlusions as part of EVAR. Although buttock claudication following unilateral internal iliac occlusion is usually thought of as mild and transient, symptoms fail to improve in around half the

patients⁸ and are sufficiently debilitating that some authors¹⁴ have combined the procedure with external-to-internal iliac artery bypass to prevent this occurrence. Cook (Australia) has recently introduced the Zenith bifurcated iliac side branch device (IBD) to preserve internal iliac artery flow following EVAR in such patients. We here describe our initial experience with this device.

METHODS

Between November 2005 and October 2006, all patients who were being considered for EVAR and were going to require coverage of at least one of their internal iliac artery origins by the stent graft to obtain a seal were offered the IBD. Informed consent, stressing the as yet unknown long-term outcome of the device, was obtained from all patients. All eight patients to whom this treatment modality was offered accepted to have an IBD device as opposed to losing an internal iliac artery. In two patients (cases 1 and 2 in [Tables I and II](#)), the IBD was used in conjunction with a standard Zenith Flex main body, a Zenith side branch occluder, and extension grafts to exclude an infra-renal aortic aneurysm with bilateral common iliac artery aneurysms. In another four patients, it was used in conjunction with a standard Zenith Flex main body, and extension grafts to exclude an infra-renal aortic aneurysm with a single common iliac artery aneurysm in three patients (cases 3 to 5 in [Tables I and II](#)) and a solitary common iliac aneurysm in one patient (case 6 in [Tables I and II](#)). In another patient (case 7 in [Tables I and II](#)), a juxta-renal abdominal aortic aneurysm with bilateral common iliac aneurysms had already been previously managed using a two-vessel fenestrated Zenith graft, and a Zenith side branch occluder in the larger common iliac artery. The

From the John Hunter Hospital and Lake Macquarie Private Hospital. Dr Serracino-Inglott has been appointed as the European proctor for the Zenith Iliac Bifurcation Device by Cook Europe.

Reprint requests: Ferdinand Serracino-Inglott, MD, Department of Vascular and Endovascular Surgery, Manchester Royal Infirmary, Oxford Road, Manchester M13 9WL, United Kingdom (e-mail: surgeon.vascular@gmail.com).

0741-5214/\$32.00

Copyright © 2007 by The Society for Vascular Surgery.

doi:10.1016/j.jvs.2007.03.040

Table I. Patient age and aneurysm dimensions pre-procedure and at last follow-up

Patient	Age (years)	Follow-up (months)	Side of IBD	AAA diameter (cm) pre-procedure	AAA diameter (cm) at last follow-up	Right common Iliac diameter (cm) pre-procedure	Right common Iliac diameter (cm) at last follow-up	Left common Iliac diameter (cm) pre-procedure	Left common Iliac diameter (cm) at last follow-up
1	80	3	Right	5.0	4.6	3.5	3.9	3.5	3.9
2	64	8	Left	6.2	6.0	3.9	3.9	2.6	2.7
3	77	6	Left	5.8	4.0	1.6	1.6	2.9	2.0
4	67	14	Right	5.4	2.9	3.2	1.9	2.0	2.4
5	69	1	Right	5.4	5.4	2.1	1.8	1.5	1.5
6	75	5	Right	2.0	2.0	3.7	3.4	2.4	2.4
7	65	12	Left	5.8	5.6	6.3	5.8	4.3	4.3
8	80	1	Left	2.8	3.0	3.6 [5.0]	3.4 [5.3]	3.3 [3.6]	3.3 [3.8]

For case 8, internal iliac artery diameters are also given in square brackets, since this patient also had bilateral internal iliac aneurysms which were his main pathology.

Table II. Contrast use and fluoroscopy screening time

Patient	Type of contrast (volume in ml)	Contrast used as g of Iodine	Fluoroscopy time
1	Iomeron 300 (373)	112 g	57 minutes
2	Isovue 370 (284)	105 g	49 minutes
3	Iomeron 300 (433)	130 g	48 minutes
4	Isovue 370 (237)	88 g	43 minutes
5	Isovue 370 (227)	84 g	38 minutes
6	Isovue 370 (332)	123 g	70 minutes
7	Isovue 370 (237)	88 g	105 minutes
8	Isovue 370 (264)	98 g	83 minutes

IBD was inserted as a secondary procedure to treat a distal type 1 endoleak. In another patient (case 8 in Tables I and II), it was used to treat a right 3.5 cm internal iliac aneurysm. The patient had previously had a 5 cm left internal iliac aneurysm treated with a Viabahn Excluder stent. Further patient details are given in Table I.

Device characteristics and planning. The Zenith bifurcated iliac side branch device resembles a standard Zenith limb extension but has a side branch attached to its body approximately half way down its length as shown in Fig 1. In order to use this device, the external iliac artery must not be aneurysmal in order to provide a distal fixation segment. This vessel must therefore be at least 20 mm long and have a diameter between 8 and 11 mm. The internal iliac artery must also be of normal caliber with a length of at least 10 mm to allow for proper sealing. The graft is constructed of full-thickness woven polyester fabric sewn to self-expanding stainless steel and nitinol Cook Z-stents. The graft is fully stented. This provides stability as well as the expansile force necessary to open its lumen during deployment. Nitinol rings positioned at the proximal end of the graft help maintain lumen patency during access. Additionally, the Cook Z-stents provide the necessary seal between the graft and vessel wall. Long gold markers are used to mark the outer side of the side branch, which is supported by a nitinol stent and two 7 mm reinforced rings. The inner distal diameter of the side branch is 8 mm. The

main stent has a proximal diameter of 12 mm. The device is tailored to the patient's anatomy based on the length of the common iliac artery aneurysm and the length and diameter of the external iliac artery. When planning the device, one has to keep in mind that the distal end of the side branch will lie 10 mm above the iliac bifurcation (see Fig 2) and the proximal end of the common iliac segment needs to lie as close as possible to the aortic bifurcation. The diameter of the external iliac segment is oversized by 10%. Planning of these devices was based on maximum intensity projection (MIPs) from computed tomography (CT)-angiograms and conventional angiography with a calibrated pig-tail catheter in all patients. All the devices used were custom made (Cook Australia Pty Ltd, Brisbane, Queensland, Australia) for each individual patient and loaded into a 20F sheath, with a curved indwelling catheter and guidewire through the side branch to facilitate its cannulation from the contralateral side by snaring of this wire.

Operative technique. Endovascular access is obtained through both common femoral arteries. The IBD is introduced over a Lunderquist wire, the contralateral side being used for angiography to allow correct positioning. The pre-mounted wireguide (within the side branch of the device) is exchanged for a 0.035-inch stiff shaft Glidewire (Terumo Medical Corporation, Somerset, New Jersey). The tip of this wire is advanced well into the aneurysm sac and retrieved from the contralateral access site (Fig 2, A). After partially deploying the IBD thereby allowing its side branch to open, a 12 Fr Balkin sheath is advanced over the through-and-through wire, over the aortic bifurcation, into the proximal opening of the IBD and out of its side branch (Fig 2, B and Fig 3, A). A new 0.035-inch stiff shaft Glidewire (Terumo Medical) is then advanced through the Balkin sheath to cannulate the opposite internal iliac artery (Fig 2, C). In one patient, this was unsuccessful and the internal iliac artery was cannulated with access through the left brachial artery. The wire is advanced into a distal side branch of the internal iliac artery and exchanged for an Amplatz Superstiff Guidewire (Boston Scientific, Natick, Mass). The external iliac part of the IBD is opened into place. Advanta V12 covered stents (Atrium Medical, Hud-

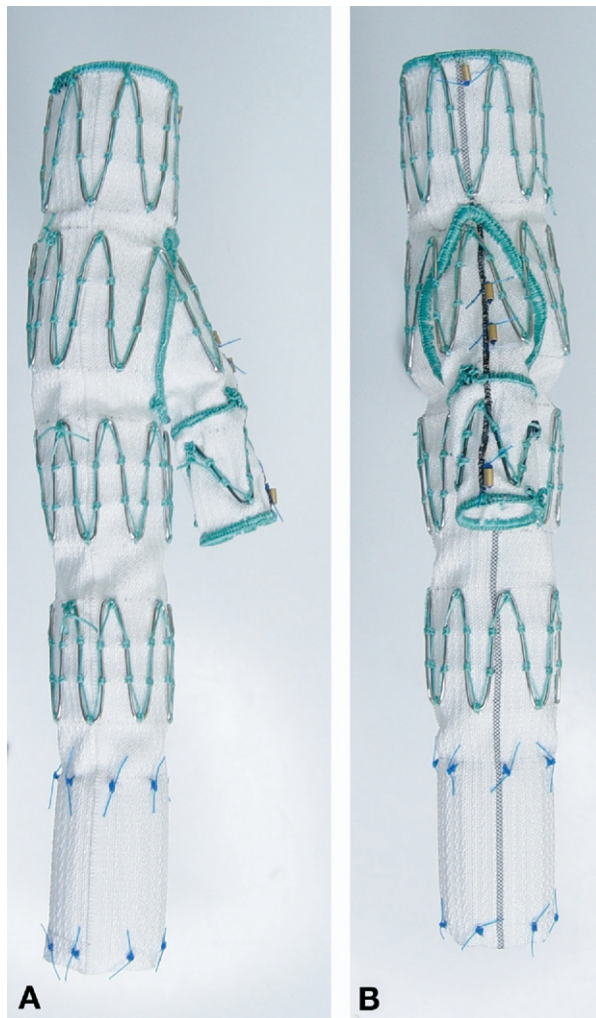


Fig 1. Photograph of the unsheathed Zenith bifurcated iliac side branch device. **A**, Anterior/posterior view; **B**, Side view to demonstrate the gold markers. The balloon expandable covered stents that are used to bridge the gap between the side branch and the internal iliac artery must not extend proximally above the third gold marker (counting from above). [Courtesy of William A. Cook Australia Pty Ltd].

son, New Hampshire) are deployed, from the internal iliac artery (or its largest normal branch [in case 8] when an internal iliac aneurysm is also present) to the side branch of the IBD, ensuring good sealing and patency (Fig 2, D and Fig 3, B). The Balkin sheath and Amplatz Superstiff Guidewire (Boston Scientific) are removed and a Zenith flex graft introduced from the side opposite the IBD over a Lunderquist wire and deployed in the standard fashion immediately distal to the origin of the renal arteries. If required, a Zenith side branch occluder is introduced and deployed to occlude the internal iliac artery on the opposite side of the IBD prior to insertion of the main body. A leg extension is introduced and deployed to bridge the ipsilateral leg of the main body device and the distal segment of the Zenith side branch occluder or native com-

mon iliac artery. Another leg extension with a distal diameter of 16 mm is introduced and deployed to bridge the contralateral leg of the main body device and the IBD.

In the patient who had the fenestrated graft, since all the other stent grafts were already in place when the IBD was inserted, cannulation of the internal iliac artery was performed via a left brachial approach.

Completion angiography is performed to assess patency and look for endoleak (Fig 3, C, Fig 4, B, and Fig 5, B). Patients were followed with clinical examination, plain abdominal x-ray, and color and power Doppler ultrasound at monthly intervals.

RESULTS

During the study period, we treated a total of 69 patients with aorto-iliac aneurysmal pathology. Twenty-one of these patients were treated by open surgery. Of these, seven required a bifurcated graft. Forty-eight patients were treated by endovascular means, eight of whom were offered an IBD since they had a common iliac artery (CIA) diameter on at least one side greater than 25 mm.

Table II gives details of the fluoroscopy time and amount of contrast used. The median operative time was 215 minutes (range 152 to 414). There was minimal blood loss, with only one patient requiring a postoperative blood product transfusion. All the stent-grafts were deployed as planned. The length of the common iliac artery component of the IBD was 41, 65, or 83 mm, and that of the external iliac artery component of the IBD was 41 or 58 mm. Seven patients required two 8 mm and one patient required two 10 mm Advanta V12 covered stents (Atrium Medical) of various lengths to obtain a good seal. Distal diameters for the external iliac artery component of the IBD were 12, 14, and 16 mm. Completion angiography showed that all the aneurysms were fully excluded with no endoleak. Postoperative in-patient stay varied between 3 and 5 days with a median value of 4. All patients are alive at follow-up with no major complications. Two patients, however, have recurrent groin lymphoceles that are being managed conservatively.

Table I gives details on the aneurysm size at follow-up (median: 6; range: 1 to 14 months). None of the aneurysms have increased significantly in size since intervention. The patient who had a previous fenestrated graft has been found to have a type 2 endoleak from the inferior mesenteric artery. This is being closely observed with a view to intervention only if the aneurysm increases in size. To date, none of the other seven patients have demonstrated any endoleak. There was only one occlusion of an IBD, in the patient who had an internal iliac artery aneurysm. This resulted in no significant symptoms. All the other side branches remain patent with good velocities in the preserved internal iliac artery on duplex ultrasound. There were no cases of colonic ischemia and none of the patients complained of new claudication symptoms or new onset impotence at follow-up.

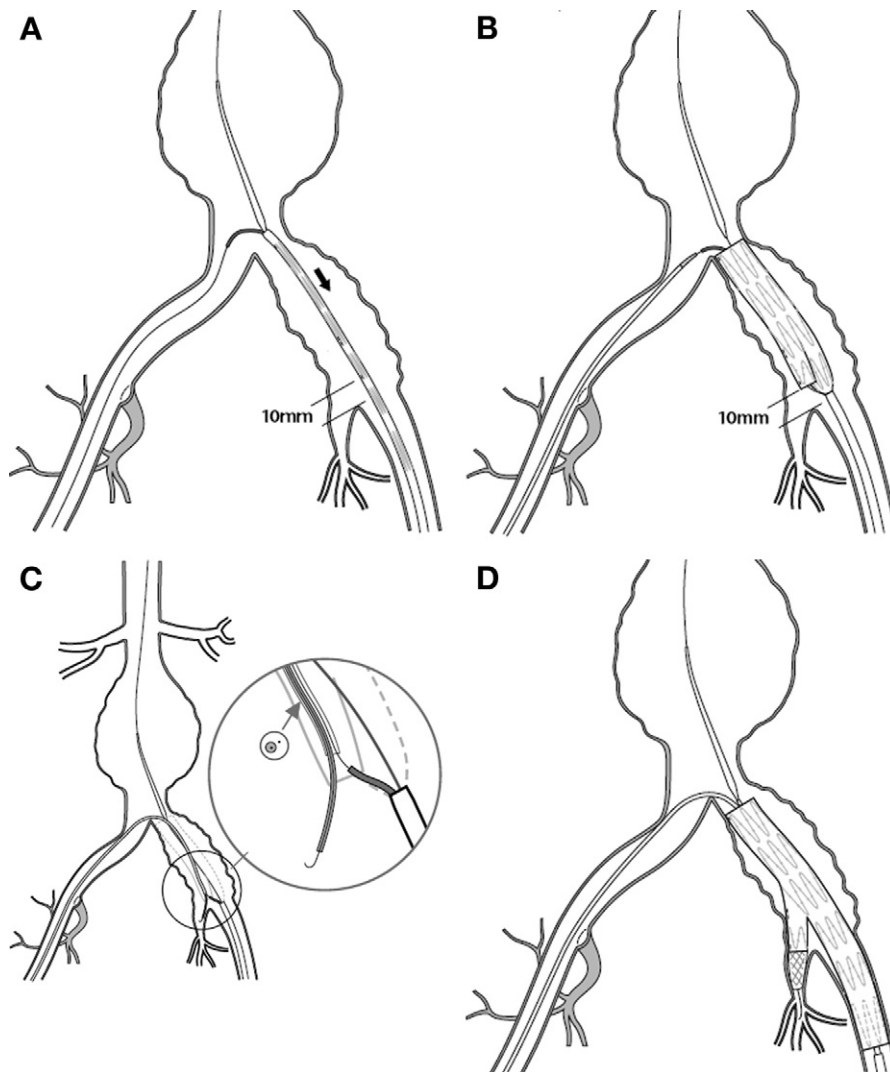


Fig 2. Line diagrams depicting deployment of the Zenith bifurcated iliac side branch device (IBD): **A**, The indwelling catheter is snared within the aortic aneurysm sac and brought out via the contralateral femoral artery. **B**, The IBD is partly deployed to open up its side branch prior to advancing the Balkin sheath over the through-and-through wire, into the proximal segment of the IBD and out of its side branch. **C**, Another 0.035 wire is then introduced through the Balkin sheath to allow cannulation of the internal iliac artery. **D**, This wire is then changed to a stiffer wire over which covered stents are introduced and later deployed after fully unsheathing the IBD. [Line diagrams used with permission of William A. Cook Australia Pty Ltd.]

DISCUSSION

As a result of the decreased morbidity following EVAR when compared with open aneurysm repair, there has been an increase in the demand for endovascular treatment of patients with aorto-iliac aneurysms. To this effect, a number of reports on how to treat patients with aorto-bi-iliac aneurysms with EVAR whilst at the same time preserving one internal iliac artery have appeared in recent literature. Parodi and Ferreira¹⁵ were the first to propose surgically relocating the origin of the internal iliac artery further distally on the external iliac artery. This procedure is, however, technically demanding, especially in patients with

large iliac aneurysms, takes time, and requires significant retroperitoneal exposure. It therefore defeats the whole purpose of the minimally invasive nature by which EVAR benefits patients. As a result, a number of authors have used stent-grafts in combination with EVAR to preserve internal iliac artery flow on one side. Until recently, however, these procedures also necessitated a femoro-femoral crossover graft. Bergamini and colleagues¹⁶ used a custom-made aorto-uni-iliac device on the side where they embolized the internal iliac artery, performed a femoro-femoral crossover, and on the contralateral side, used a custom-made covered stent or a Wallgraft (Boston Scientific) to retrogradely

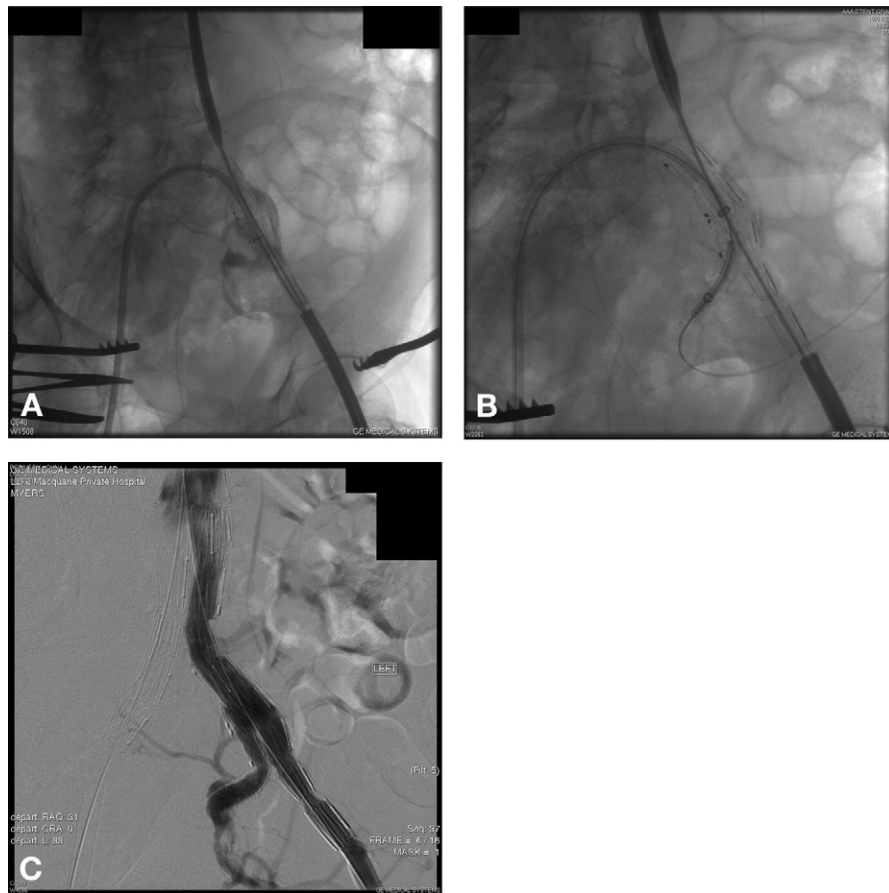


Fig 3. Intraoperative fluoroscopy and digital subtraction images from case 3. **A**, Balkin sheath advanced over the aortic bifurcation, into the side branch of the partially deployed Zenith bifurcated iliac side branch device (IBD); **B**, The internal iliac artery has been cannulated and the wire advanced well into one of its branches, the IBD has been completely deployed, one covered stent has also been deployed, and a second one is about to be deployed; **C**, Completion angiograph at the end of the procedure (the right limb is not filling since no suction was applied to the sheath in the right groin to better visualize the left side).

perfuse the internal iliac artery from the ipsilateral external iliac artery and at the same time exclude the common iliac artery aneurysm proximal to it. Delle and coworkers¹⁷ used an excluder bifurcated stent-graft (WL Gore & Associates, Flagstaff, Ariz). They inserted the main device through the same side where the internal iliac artery was coiled and used a standard limb extender to seal in the external iliac artery on this side. On the contralateral side, they used various covered stent grafts, usually Hemobahn (WL Gore & Associates) to bridge the gap between the distal end of the main body's limb and the internal iliac artery. The procedure was then completed by performing a femoro-femoral crossover graft and ligating the external iliac artery.

The IBD is a novel endovascular device that enables the exclusion of aorto-bi-iliac aneurysms, whilst simultaneously preserving at least one internal iliac artery without the need for an additional open surgical procedure. In this series, we only used unilateral IBDs. In case 1 and 2 with bilateral common iliac aneurysms, we occluded the contralateral

internal iliac artery with a Zenith side branch occluder, since we believed that it was impossible to obtain a safe seal proximal to its origin. In case 1, there was no anatomical difference between either one of the common iliac arteries and, so, we put the IBD on the right side as opposed to the left for no specific reason. In case 2, we decided to deploy the IBD in the smaller of the two common iliac aneurysms, as we believed that this would result in a shorter length of covered stent to bridge the side branch of the IBD and the origin of the internal iliac artery. Although we could have elected to use bilateral IBDs, we felt that at this stage when our experience with this novel device is still limited, the increase in need for fluoroscopy time, the increased usage of contrast, the longer anesthetic time, as well as the additional need for vascular access from the arm to cannulate the second IBD side branch, and internal iliac artery would have increased the risk of the procedure, possibly outweighing the benefits. Cases 7 and 8 had an internal iliac artery previously occluded to treat previous contralateral

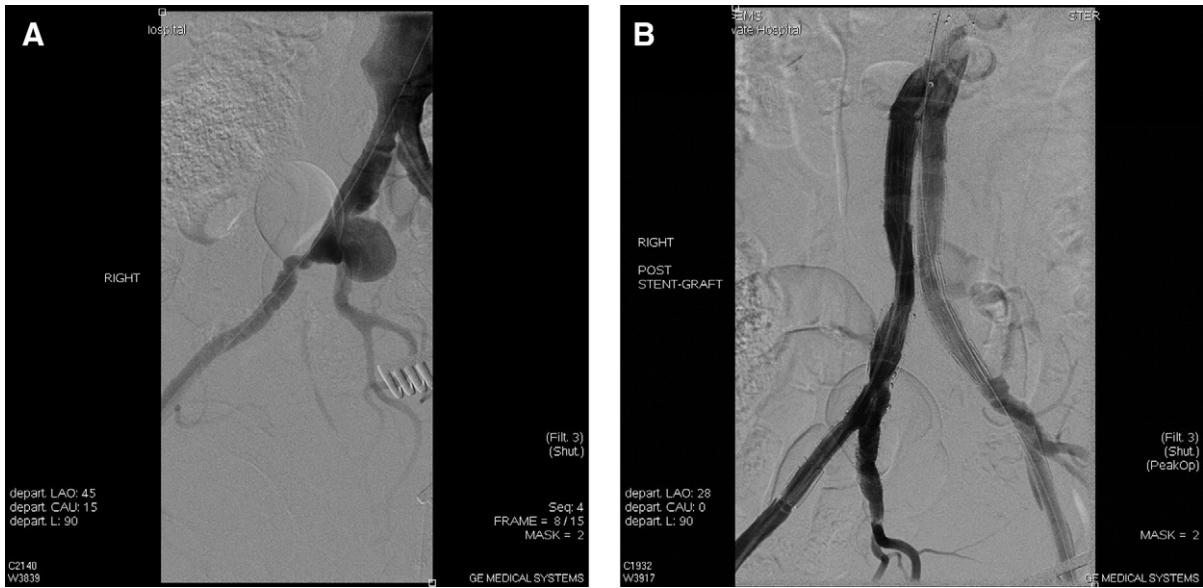

Fig 4. Intraoperative digital subtraction images from case 5. **A**, Before stent insertion and deployment; **B**, At completion.

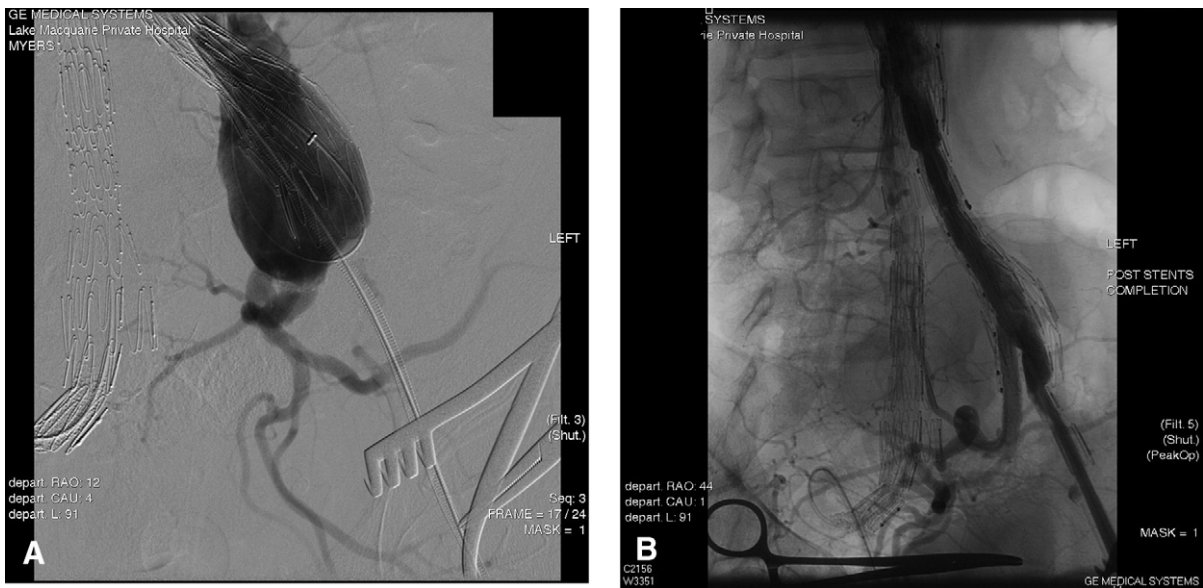

Fig 5. Intraoperative digital subtraction images from case 7: **A**, before stent insertion and deployment, demonstrating a distal type 1 endoleak despite the previous use of a “bell-bottom” technique and **B**, at completion demonstrating no endoleak after deployment of the Zenith bifurcated iliac side branch device and Advanta V12 stents.

pathology, and there would have been no choice other than to occlude the other IIA as well had the IBD device not been used.

This report, compliments that of Malina’s group from Sweden¹⁸ in confirming that the IBD may be used to completely exclude aorto-iliac aneurysms with minimal morbidity and excellent short-term results. Although our data shows that contrast usage and fluoroscopy times are

considerably higher than published data for conventional cases, we believe that these will decrease as familiarity with the procedure increases. Despite the number of modular components involved, we did not observe any endoleaks related to the IBD. Malina’s group did, however, have one case of type 3 endoleak on follow-up in one of the ten patients they treated with the IBD. Greenberg and coworkers¹⁹ have also just recently published their experience with

a similar device, also based on a Zenith (Cook) platform. Their common iliac aneurysm device resembles a conventional limb extension with a 2 cm long crimped fabric tube 6 or 8 mm in diameter anastomosed as a branch. Unlike the IBD, this branch arises from the side lateral to the internal iliac artery to assume a helical path around the device. In their series of 21 patients, they failed to access the internal iliac artery in three, and had three limb occlusions all of which were successfully treated with thrombolysis and bare stenting. Malina and coworkers¹⁸ also reported one case of late external iliac occlusion in their series. Since their patient reported no symptoms, they did not treat this. In our series, we had no case of limb occlusions. We did, however, have one case where the stented internal iliac artery occluded. This occurred in the patient who had an internal iliac aneurysm and, therefore, had the stent sealing in the largest branch of the internal iliac artery after embolization of the other branches at a previous procedure. Although the cause of the occlusion remains unclear, it may well be that this was due to a combination of the smaller diameter of this vessel when compared with normal internal iliac artery and the longer course of the covered stents to reach this vessel. Despite this, we would still consider using IBDs to treat IIA aneurysms in the future, since when one compares this with embolization and covering the IIA origin with a stent-graft (our first line treatment prior to the development of the IBD), there is nothing to be lost if the side branch occludes.

CONCLUSION

In conclusion, the IBD provides a new alternative for the management of patients with aorto-iliac aneurysms, that is not only safe, but also less complex than previous endovascular or hybrid methods that attempted to exclude these aneurysms whilst maintaining pelvic blood flow.

AUTHOR CONTRIBUTIONS

Conception and design: FSI, AB, PM

Analysis and interpretation: FSI, AB, PM

Data collection: FSI

Writing the article: FSI

Critical revision of the article: FSI, AB, PM

Final approval of the article: FSI, AB, PM

Statistical analysis: Not applicable

Obtained funding: Not applicable

Overall responsibility: PM

REFERENCES

1. Malagari K, Brontzos E, Gougoulakis A, Papatheanasiou M, Alexopoulos E, Mastorakou R, et al. Large diameter limbs for dilated common iliac arteries in endovascular aneurysm repair. Is it safe? *Cardiovasc Intervent Radiol* 2004;27:237-42.
2. Lee WA, O'Doriso J, Wolf YG, Hill BB, Fogarty TJ, Zarins CK. Outcome after unilateral hypogastric artery occlusion during endovascular aneurysm repair. *J Vasc Surg* 2001;33:921-6.
3. Tefera G, Turnipseed WD, Carr SC, Pulfer KA, Hoch JR, Acher CW. Is coil embolization of hypogastric artery necessary during endovascular treatment of aortoiliac aneurysms? *Ann Vasc Surg* 2004;18:143-6.
4. Karch LA, Hodgson KJ, Mattos MA, Bohannon WT, Ramsey DE, McLafferty RB. Adverse consequences of internal iliac artery occlusion during endovascular repair of abdominal aortic aneurysms. *J Vasc Surg* 2000;32:676-83.
5. Criado FJ, Wilson EP, Velazquez OC, Carpenter JP, Barker C, Wellons E, et al. Safety of coil embolization of the internal iliac artery in endovascular grafting of abdominal aortic aneurysms. *J Vasc Surg* 2000;32:684-8.
6. Lee CW, Kaufman JA, Fan CM, Geller SC, Brewster DC, Cambria RP, et al. Clinical outcome of internal iliac artery occlusions during endovascular treatment of aortoiliac aneurysmal diseases. *J Vasc Interv Radiol* 2000;11:567-71.
7. Razavi MK, DeGroot M, Olcott C 3rd, Sze D, Kee S, Semba CP, et al. Internal iliac artery embolization in the stent-graft treatment of aortoiliac aneurysms: analysis of outcomes and complications. *J Vasc Interv Radiol* 2000;11:561-6.
8. Lee WA, O'Doriso J, Wolf YG, Hill BB, Fogarty TJ, Zarins CK. Outcome after unilateral hypogastric artery occlusion during endovascular aneurysm repair. *J Vasc Surg* 2001;33:921-6.
9. Cynamon J, Lerer D, Veith FJ, Taragin BH, Wahl SI, Lautin JL, et al. Hypogastric artery coil embolization prior to endoluminal repair of aneurysms and fistulas: buttock claudication, a recognized but possibly preventable complication. *J Vasc Interv Radiol* 2000;11:573-7.
10. Criado FJ, Wilson EP, Velazquez OC, Carpenter JP, Barker C, Wellons E, et al. Safety of coil embolization of the internal iliac artery in endovascular grafting of abdominal aortic aneurysms. *J Vasc Surg* 2000;32:684-8.
11. Sanchez LA, Patel AV, Ohki T, Suggs WD, Wain RA, Valladares J, et al. Midterm experience with the endovascular treatment of isolated iliac aneurysms. *J Vasc Surg* 1999;30:907-13.
12. Lin PH, Bush RL, Lumsden AB. Sloughing of the scrotal skin and impotence subsequent to bilateral hypogastric artery embolization for endovascular aortoiliac aneurysm repair. *J Vasc Surg* 2001;34:748-50.
13. Engelke C, Elford J, Morgan RA, Belli AM. Internal iliac artery embolization with bilateral occlusion before endovascular aortoiliac aneurysm repair—clinical outcome of simultaneous and sequential intervention. *J Vasc Interv Radiol* 2002;13:667-76.
14. Arko FR, Lee WA, Hill BB, Fogarty TJ, Zarins CK. Hypogastric artery bypass to preserve pelvic circulation: improved outcome following endovascular abdominal aortic aneurysm repair. *J Vasc Surg* 2004;39:404-8.
15. Parodi JC, Ferreira M. Relocation of the iliac artery bifurcation to facilitate endoluminal treatment of abdominal aortic aneurysms. *J Endovasc Surg* 1999;6:342-7.
16. Bergamini TM, Rachel ES, Kinney EV, Jung MT, Kaebnick HW, Mitchell RA. External iliac artery-to-internal iliac artery endograft: a novel approach to preserve pelvic inflow in aortoiliac stent grafting. *J Vasc Surg* 2002;35:120-4.
17. Delle M, Lonn L, Wingren U, Karlstrom L, Klingenstierna H, Risberg B, et al. Preserved pelvic circulation after stent-graft treatment of complex aortoiliac artery aneurysms: a new approach. *J Endovasc Ther* 2005;12:189-95.
18. Malina M, Dirven M, Sonesson B, Resch T, Dias N, Ivancev K. Feasibility of a branched stent-graft in common iliac artery aneurysms. *J Endovasc Ther* 2006;13:496-500.
19. Greenberg RK, West K, Pfaff K, Foster J, Skender D, Haulon S, et al. Beyond the aortic bifurcation: branched endovascular grafts for thoracoabdominal and aortoiliac aneurysms. *J Vasc Surg* 2006;43:879-86.

Submitted Jan 23, 2007; accepted Mar 14, 2007.