



Noninvasive Evaluation of the Aortic Root With Multislice Computed Tomography

Implications for Transcatheter Aortic Valve Replacement

Laurens F. Tops, MD,* David A. Wood, MD,† Victoria Delgado, MD,*
Joanne D. Schuijf, MSc,* John R. Mayo, MD,† Sanjeevan Pasupati, MD,†
Frouke P. L. Lamers, MD,* Ernst E. van der Wall, MD, PhD,*
Martin J. Schalij, MD, PhD,* John G. Webb, MD,† Jeroen J. Bax, MD, PhD, FACC*

Leiden, the Netherlands; and Vancouver, Canada

OBJECTIVES In the present study, the anatomy of the aortic root was assessed noninvasively with multislice computed tomography (MSCT).

BACKGROUND Transcatheter aortic valve replacement has been proposed as an alternative to surgery in high-risk patients with severe aortic stenosis. For this procedure, detailed knowledge of aortic annulus diameters and the relation between the annulus and the coronary arteries is needed.

METHODS In 169 patients (111 men, age 54 ± 11 years), a 64-slice MSCT scan was performed for evaluation of coronary artery disease. Of these, 150 patients had no or mild aortic stenosis, and 19 patients had moderate to severe aortic stenosis. Reconstructed coronal and sagittal views were used for assessment of the aortic annulus diameter in 2 directions. In addition, the distance between the annulus and the ostium of the right and left coronary arteries and the length of the coronary leaflets were assessed. The LV outflow tract and interventricular septum were analyzed on the single oblique sagittal view at end-diastole.

RESULTS The diameter of the aortic annulus was 26.3 ± 2.8 mm on the coronal view, and 23.5 ± 2.7 mm on the sagittal view. Mean difference between the 2 diameters was 2.9 ± 1.8 mm, indicating an oval shape of the aortic annulus. Mean distance between the aortic annulus and the ostium of the right coronary artery was 17.2 ± 3.3 mm, and mean distance between the annulus and the ostium of the left coronary artery was 14.4 ± 2.9 mm. In 82 patients (49%), the length of the left coronary leaflet exceeded the distance between the annulus and the ostium of the left coronary artery. There were no significant differences in the diameter of annulus, diameter of sinus of Valsalva, or the distance between the annulus, left coronary leaflet, and the ostium of the left coronary artery, between the patient with and without severe aortic stenosis.

CONCLUSIONS The MSCT can provide detailed information on the shape of the aortic annulus and the relation between the annulus and the ostia of the coronary arteries. Thereby, MSCT may be helpful for avoiding paravalvular leakage and coronary occlusion and may facilitate the selection of candidates for transcatheter aortic valve replacement. (J Am Coll Cardiol Img 2008;1:321–30) © 2008 by the American College of Cardiology Foundation

From the *Department of Cardiology, Leiden University Medical Center, Leiden, the Netherlands; and the †Division of Cardiology, St. Paul's Hospital, University of British Columbia, Vancouver, Canada. Dr. Bax receives research grants from GE Healthcare and BMS Medical Imaging. Dr. Webb is a consultant for Edwards Lifesciences. Drs. Tops and Wood contributed equally to this article and are shared first authors.

Manuscript received December 10, 2007; accepted December 16, 2007.

Degenerative aortic stenosis (AS) is the most common native valve disease (1). Although surgical aortic valve replacement provides good long-term results and symptom relief, it is complex in high-risk patients with extensive comorbidity (2). In patients with severe, symptomatic AS and a very high risk of morbidity or mortality with conventional surgery, a percutaneous transcatheter aortic valve replacement may be preferred.

Several studies have shown the feasibility of transcatheter aortic valve replacement (3–5). Difficulties with accurate positioning of the prosthesis in the aortic annulus, prosthesis sizing, the covering of the coronary ostia by the upper part of the prosthesis (5) and even occlusion of the left coronary artery (4) are important issues in transcatheter aortic valve replacement. Therefore, detailed information on the anatomy of the aortic annulus and the relation of the annulus with the coronary arteries is important for performing these procedures.

Fluoroscopy and transesophageal echocardiography are helpful imaging modalities during percutaneous valve replacement procedures (3–5). However, these modalities are limited by their 2-dimensional character. Multislice computed tomography (MSCT) can provide 3-dimensional images with a high spatial resolution and may therefore be of great value for percutaneous valve replacement procedures.

The purpose of the present study was to assess the anatomy of the aortic root noninvasively with 64-slice MSCT. We sought to determine standardized measurements on the aortic annulus and the relation with the left coronary artery in a large cohort of patients, including patients with moderate to severe AS.

METHODS

Study population. The study population comprised 169 patients referred for MSCT coronary angiography in the period from February 2005 until January 2007 at the Leiden University Medical Center. In all patients, the aortic root could be analyzed on the acquired MSCT scan. To detect differences in aortic root anatomy between patients with and without AS, the study population was divided into 2 groups: patients with no or mild AS (n = 150) and patients with moderate to severe AS (n = 19).

MSCT. The MSCT examinations were performed with a Toshiba Multislice Aquilion 64 system

(Toshiba Medical Systems, Tokyo, Japan). Before MSCT angiography, a prospective coronary calcium scan was performed (collimation 4×3.0 mm, rotation time 500 ms, tube voltage 120 kV, and tube current 200 mA). The temporal window was set at 75% after the R-wave for electrocardiographically triggered prospective reconstruction.

For the MSCT coronary angiogram, a collimation of 64×0.5 mm and a rotation time of 400 ms were used. A multisegment reconstruction algorithm was used, resulting in a temporal resolution of <200 ms depending on heart rate and pitch. The tube current was 300 mA, at 120 kV. Nonionic contrast material (Iomeron 400, Bracco, Altana Pharma, Konstanz, Germany) was administered in the antecubital vein, in an amount of 80 to 110 ml depending on the total scan time and a flow rate of 5.0 ml/s.

Automated peak enhancement detection in the descending aorta was used for timing of the scan. After the threshold level of +100 Hounsfield units was reached, data acquisition was automatically initiated. Data acquisition was performed during an inspiratory breath-hold of approximately 8 to 10 s, while the ECG was recorded simultaneously to allow retrospective gating of the data.

The dataset of the contrast-enhanced scan was reconstructed at 30% and 75% of the RR interval for the systolic and diastolic phases, respectively. All images were reconstructed with a slice thickness of 0.5 mm and a reconstruction interval of 0.3 mm. Axial datasets were then transferred to a remote workstation (Vitrea 2, Vital Images, Plymouth, Minnesota) for post-processing and subsequent image analysis.

Image analysis. All images were analyzed by 2 experienced observers blinded to the clinical and echocardiographic information. An overview of the measured variables is shown in Table 1.

Aortic valve anatomy and calcification. The aspect of the aortic valve (tricuspid or bicuspid) and the presence of aortic valve calcifications were assessed on double oblique transverse reconstructions of the MSCT coronary angiogram. Aortic valve calcifications were then graded subjectively as previously described (6,7). The degree of aortic valve calcification was graded as follows: grade 1—no calcification; grade 2—mildly calcified (small isolated spots); grade 3—moderately calcified (multiple larger spots); grade 4—heavily calcified (extensive calcification of all cusps). Examples of the different calcification grades are shown in Figure 1. In addition, an Agatston calcium score (8) and the calcium volume for the

ABBREVIATIONS AND ACRONYMS

AS = aortic stenosis

CT = computed tomography

MSCT = multislice computed tomography

Table 1. Anatomical Analysis of the Aortic Root

Variable	MSCT View
Aortic valve	
Aspect (bicuspid/tricuspid)	Double oblique transverse*
Calcification (grades 1 to 4)	Double oblique transverse
Agatston calcium score	Prospective calcium scan
Calcium volume	Prospective calcium scan
Aortic annulus	
Diameter (diastole/systole)	Coronal† Single oblique sagittal‡
Sinus of Valsalva	
Diameter	Coronal
Distance between annulus and sinus of Valsalva	Coronal
Relation aortic annulus, coronary leaflet, ostium coronary artery	
Distance between annulus and ostium coronary artery (left and right)	Coronal
Length of coronary leaflet (left and right)	Coronal
Distance between tip of left coronary leaflet and ostium left coronary artery (diastole/systole)	Coronal
Sinotubular junction	
Diameter	Coronal
Distance between annulus and sinotubular junction	Coronal

*The double oblique transverse view is perpendicular to the aortic axis. †The coronal view has the same orientation as the anterior posterior view on aortic root angiography. ‡The single oblique sagittal view has the same orientation as the parasternal long axis view on transthoracic echocardiography and the mid-esophageal long axis view on transesophageal echocardiography.

aortic valve was obtained from the prospective calcium scan using dedicated calcium scoring software (Vitrea 2, Vital Images).

Anatomical analysis of the aortic root. Standard orthogonal axial and sagittal views were used for initial orientation on the aortic valve. Because the aortic valve is oriented obliquely to the standard axial view, a coronal and a single oblique sagittal view through the aortic valve were reconstructed. The anatomy of the aortic root and the relationship of the aortic annulus, the coronary leaflets, and the ostia of the coronary arteries was assessed on the coronal view and the reconstructed single oblique sagittal view, both in the systolic and diastolic phases. The coronal view is similar to the anterior-posterior view on aortic root angiography. The reconstructed single oblique sagittal view has the same orientation as the parasternal long-axis view on transthoracic echocardiogram and the mid-esophageal long-axis view on transesophageal echocardiogram. Care was taken to correctly orient both views by reviewing the reconstructed double oblique

transverse view at the level of the aortic valve. Examples of the coronal, single oblique sagittal, and double oblique transversal views are shown in Figure 2.

The diameter of the annulus was assessed in the systolic and diastolic phases. The orientation of the views was similar to those used for percutaneous aortic valve replacement procedures (4). In addition, the maximal diameter of the sinus of Valsalva and the sinotubular junction, and their respective distance to the level of the aortic annulus was assessed (Fig. 3). These variables are important to assess, because they may have implications for prosthesis sizing during transcatheter aortic valve replacement and paravalvular leakage after the procedure.

Furthermore, the distance between the annulus and the ostium of the left and the right coronary arteries and the coronary leaflet length were assessed. An example of these measurements for the left coronary artery is shown in Figure 4. In addition, the distance between the tip of the left coronary leaflet and the ostium of the left coronary artery was assessed in diastole and systole (Fig. 5). These variables may have implications for transcatheter aortic valve replacement, because they may

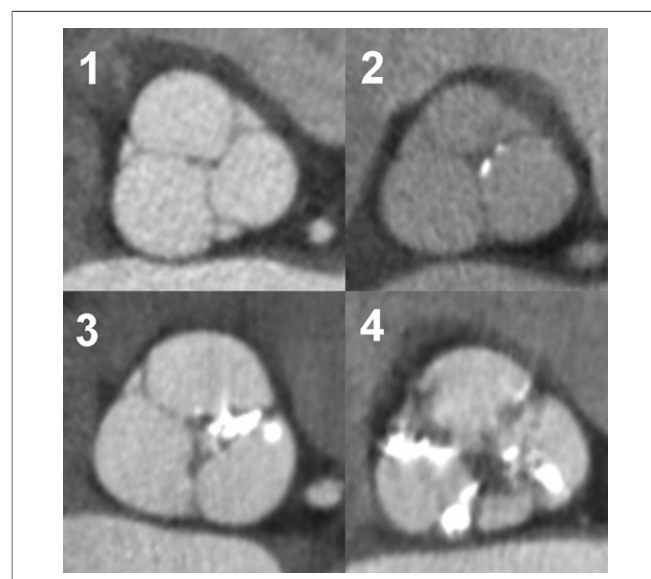


Figure 1. Assessment of Aortic Valve Calcifications

The presence and severity of aortic valve calcifications were assessed on double oblique transverse reconstructions. The degree of aortic valve calcification was graded as follows: grade 1—no calcification; grade 2—mildly calcified (small isolated spots); grade 3—moderately calcified (multiple larger spots); grade 4—heavily calcified (extensive calcification of all cusps). Extensive calcifications may hamper the ability to cross the native valve during percutaneous aortic valve replacement. Therefore, multislice computed tomography may provide important information in the selection of potential candidates.

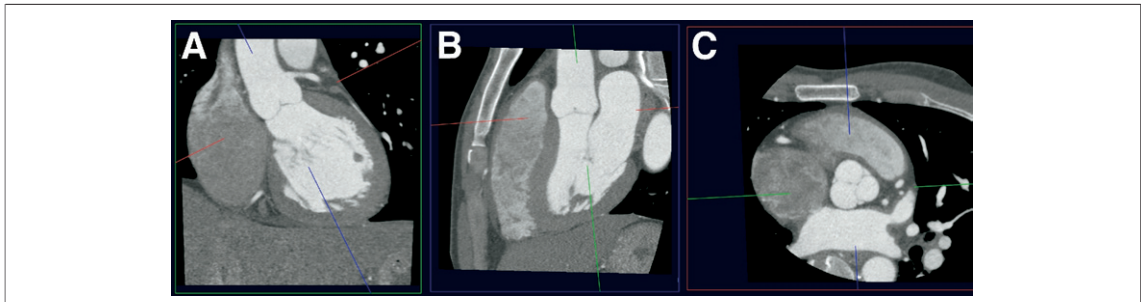


Figure 2. Anatomical Analysis of the Aortic Root

The anatomy of the aortic root was assessed on 3 reconstructed views. The coronal view (A) is similar to the anterior-posterior view on aortic root angiography. The reconstructed single oblique sagittal (B) view has the same orientation as the parasternal long-axis view on transthoracic echocardiogram and the mid-esophageal long-axis view on transesophageal echocardiogram. The reconstructed double oblique transverse view (C) is parallel to the plane of the aortic root. See Table 1 for detailed description of the variables.

determine the risk of coronary artery occlusion during the procedure, as was previously described (4).

Finally, the left ventricular outflow tract and the interventricular septum were analyzed on the single oblique sagittal view at end-diastole. The diameter of the left ventricular outflow tract was assessed parallel to the aortic valve annulus plane. The largest diameter of the interventricular septum was assessed, and the aspect of the interventricular septum was subjectively graded as normal or sig-

moid. An example of a sigmoid septum is shown in Figure 6.

Echocardiography. Two-dimensional echocardiograms were obtained with patients in the left lateral decubitus position using a commercially available system (Vingmed Vivid 7, General Electric-Vingmed, Milwaukee, Wisconsin). Images were obtained using a 3.5-MHz transducer at a depth of

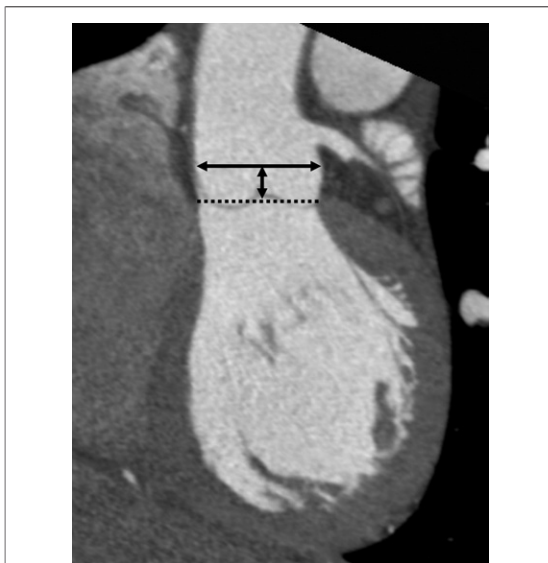

Figure 3. Anatomical Analysis: Sinus of Valsalva

On the coronal view, the maximal diameter of the sinus of Valsalva was assessed (indicated by the **double arrow**). In addition, the distance between the aortic annulus (indicated by the **dotted line**) and the level of the maximal diameter of the sinus were assessed on the coronal view. These variables are important to assess before percutaneous aortic valve replacement, because they have implications for prosthesis sizing.

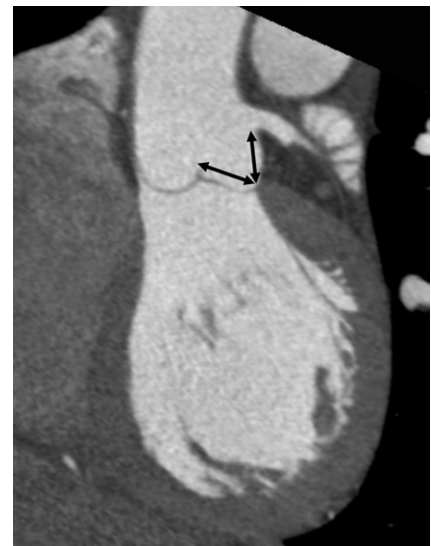

Figure 4. Anatomical Analysis: Left Coronary Ostium and Leaflet Length

Coronary ostium occlusion may occur after percutaneous aortic valve replacement. Therefore, it is important to assess the relation between the ostia of the coronary arteries and the coronary leaflet length. With the use of a coronal view, the distance between the annulus and the ostia of the coronary arteries, and the length of the coronary leaflets were assessed. This figure demonstrates the measurements of the distance between the annulus and the ostium of the left coronary artery, and the measurement of the left coronary leaflet length.

16 cm in the parasternal (long- and short-axis) and apical (2- and 4-chamber) views. Standard 2-dimensional images and color Doppler data were digitally stored in cine-loop format. Left ventricular ejection fraction was calculated from apical 2- and 4-chamber images using the biplane Simpson's rule (9). The diameter of the aortic annulus was assessed from the parasternal long-axis view. Aortic stenosis was graded according to the American College of Cardiology/American Heart Association guidelines (2): 1) mild—area >1.5 cm², mean gradient <25 mm Hg, or jet velocity <3.0 m/s; 2) moderate—area 1.0 to 1.5 cm², mean gradient 25 to 40 mm Hg, or jet velocity 3.0 to 4.0 m/s; and 3) severe—area <1.0 cm², mean gradient >40 mm Hg, or jet velocity >4.0 m/s. To detect differences in anatomical variables between patients with and without AS, the study population was divided into 2 groups: patients with no or mild AS ($n = 150$) and patients with moderate to severe AS ($n = 19$).

Statistical analysis. All continuous variables had normal distribution (as evaluated by Kolmogorov-Smirnov tests). Summary statistics for these variables are therefore presented as mean values ± 1 standard deviation. Categorical data are summarized as frequencies and percentages. Differences in aortic annulus diameter in the different views were evaluated with paired Student *t* tests. The agreement between echocardiography and MSCT for the aortic annulus measurement was assessed with Bland-Altman plot analysis. Differences in anatomical variables between patients with and without AS are evaluated using unpaired Student *t* tests (continuous variables) or chi-square tests (dichotomous variables), as appropriate. All analyses were performed using SPSS software (version 12.0, SPSS Inc., Chicago, Illinois). All statistical tests were 2-sided, and a *p* value <0.05 was considered significant.

RESULTS

Study population. A total of 169 patients were studied. Baseline characteristics of the study population are listed in Table 2. In all patients, adequate images for evaluation of the aortic root were available.

Aortic valve anatomy and calcification. In 167 patients, a tricuspid aortic valve was present, whereas 2 patients had a bicuspid aortic valve. The 2 patients with a bicuspid aortic valve were excluded from the anatomical analysis. Calcifications of the aortic valve were graded subjectively as previously

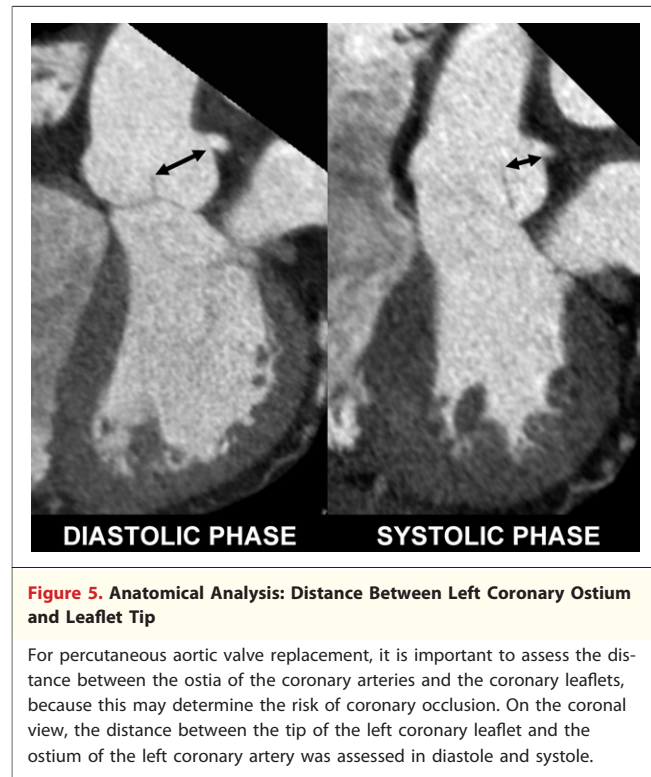

Figure 5. Anatomical Analysis: Distance Between Left Coronary Ostium and Leaflet Tip

For percutaneous aortic valve replacement, it is important to assess the distance between the ostia of the coronary arteries and the coronary leaflets, because this may determine the risk of coronary occlusion. On the coronal view, the distance between the tip of the left coronary leaflet and the ostium of the left coronary artery was assessed in diastole and systole.

described (6,7). In 123 patients (73%), no calcifications were present (grade 1). In 29 patients (17%), calcifications were characterized as grade 2; whereas 11 patients (6%) had calcifications grade 3, and 6 patients (4%) had calcifications grade 4. Calcifications were present on the left coronary cusp in 36 of the 46 patients (78%) with aortic valve calcifications, and on the right coronary cusp in 30 of the 46 patients (65%). Mean Agatston score was $819 \pm 1,245$ and mean calcium volume of the aortic valve calcifications was 663 ± 960 mm³.

Aortic root diameter and geometry. In the diastolic phase, mean diameter of the aortic annulus on the coronal view was 26.3 ± 2.8 mm; whereas the mean diameter on the reconstructed single oblique sagittal view was 23.5 ± 2.7 mm. The mean difference between the coronal and the sagittal diameter was 2.9 ± 1.8 mm. In 78 patients (47%), the difference between the 2 diameters was ≥ 3 mm, indicating an oval shape of the aortic annulus. In the systolic phase, the diameter of the aortic annulus on the coronal view was 26.5 ± 2.9 mm and the diameter on the single oblique sagittal view was 24.2 ± 2.6 mm. The mean difference between the coronal and the sagittal diameter in the systolic phase was 2.4 ± 1.9 mm. The mean diameter of the aortic annulus assessed with echocardiography was 21.6 ± 2.6

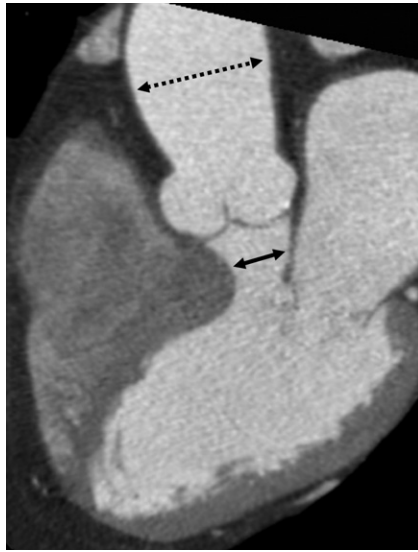

Figure 6. Example of a Patient With a Sigmoid Septum

A single oblique sagittal view was used to assess the largest diameter of the interventricular septum and to grade the aspect of the interventricular septum as normal or sigmoid. In this patient, accurate positioning of the percutaneous aortic valve may be hampered by the small diameter of the left ventricular outflow tract (indicated by the **double arrow**). Therefore, multislice computed tomography can provide valuable information on the aspect of the left ventricular outflow tract and the septum prior to percutaneous valve procedures. Also, note the post-stenotic dilatation of the ascending aorta, indicated by the **dotted arrow** in this patient.

mm. There was a good agreement between MSCT and echocardiography, as assessed with Bland-Altman plot analysis (Fig. 7).

The maximal diameter of the sinus of Valsalva in diastole on the coronal view was 32.4 ± 4.0 mm. The mean distance between the level of the annulus and the maximal diameter of the sinus of Valsalva was 17.2 ± 2.9 mm. The maximal diameter of the sinotubular junction was 28.2 ± 3.2 mm. The mean distance between the level of the annulus and the sinotubular junction was 20.3 ± 3.3 mm.

Relation aortic annulus, leaflet, and coronary artery. The relation of the aortic annulus, the coronary leaflets, and the ostia of the coronary arteries was assessed on the coronal view. The mean distance between the aortic annulus and the ostium of the left coronary artery was 14.4 ± 2.9 mm, with a range of 7.1 to 22.7 mm. The length of the left coronary leaflet was 14.2 ± 1.8 mm (range 10.0 to 21.3 mm). In 82 patients (49%), the left coronary leaflet was longer than the distance between the annulus and the ostium of the left coronary artery (mean difference 2.1 ± 1.7 mm).

Table 2. Baseline Characteristics of the Study Population

	Study Population (n = 169)
Age (yrs)	54 ± 11
Gender (M/F)	111/58
Previous myocardial infarction, n (%)	40 (24)
Previous CABG, n (%)	12 (7)
LVEF (%)	57 ± 17
Risk factors, n (%)	
Diabetes mellitus	51 (30)
Hypertension	81 (48)
Hypercholesterolemia	71 (42)
Smoking	50 (30)
Positive family history	59 (35)

CABG = coronary artery bypass grafting; LVEF = left ventricular ejection fraction.

In the remaining 85 patients (51%), the length of the left coronary leaflet was shorter than the distance between the annulus and the ostium of the left coronary artery (mean difference 2.4 ± 1.5 mm). Similarly, the mean distance between the aortic annulus and the ostium of the right coronary artery was 17.2 ± 3.3 mm, with a range of 9.2 to 26.3 mm. The length of the right coronary leaflet was 13.2 ± 1.9 mm (range 9.0 to 19.6 mm). In 17 patients (10%), the length of the coronary leaflet was longer than the distance between the annulus and the ostium of the right coronary artery (mean difference 1.5 ± 1.2 mm). In the remaining 150 patients (90%), the length

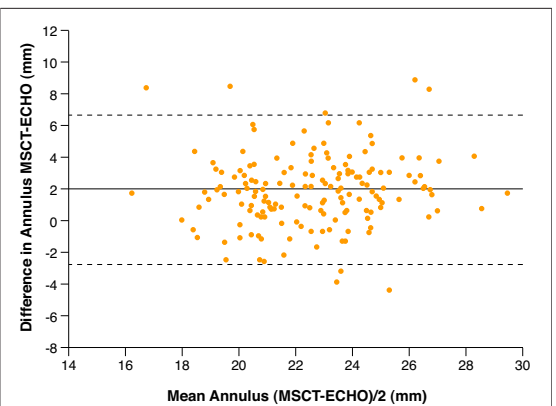


Figure 7. Agreement Between MSCT and Echocardiography

Bland-Altman plot analysis revealed a good agreement between multislice computed tomography (MSCT) and echocardiography (ECHO) for the assessment of aortic annulus diameter. The difference between each pair (y axis) is plotted against the average value of the same pair (x axis). Mean difference was 1.9 mm (solid line), 95% confidence interval -2.8 to 6.6 mm (dotted lines).

of the right coronary leaflet was shorter than the distance between the annulus and the ostium of the right coronary artery (mean difference 4.7 ± 2.7 mm).

The minimal distance from the tip of the left coronary leaflet to the left coronary ostium was measured in the diastolic and systolic phases. In diastole, the distance between the leaflet tip and the coronary ostium was 17.6 ± 2.7 mm; whereas in systole, this distance was 12.1 ± 3.4 mm ($p < 0.001$).

Left ventricular outflow tract and interventricular septum. The left ventricular outflow tract and the interventricular septum were analyzed on the single oblique sagittal view at end-diastole. Mean diameter of the left ventricular outflow tract was 21.2 ± 2.6 mm. Mean end-diastolic diameter of the interventricular septum was 12.4 ± 2.6 mm (range 7.9 to 20.9 mm). In 12 patients (7%), a sigmoid aspect of the interventricular septum was observed (Fig. 6). End-diastolic diameter in these 12 patients was 16.2 ± 1.8 mm.

Anatomic observations in aortic stenosis. Of the 169 patients, 19 patients had moderate to severe AS. In these patients, mean pressure gradient was 50 ± 21 mm Hg and mean aortic valve area was 0.8 ± 0.2 cm². In the 19 patients with AS, aortic valve calcification was characterized as grade 2 in 3 patients, as grade 3 in 10 patients, and as grade 4

in 6 patients. The severity of calcification was significantly different between the patients with AS and the patients without AS ($p < 0.001$).

To detect possible differences in aortic root anatomy between patients with and patients without AS, the patients with a bicuspid aortic valve were excluded and subsequently, the study population was divided in 2 groups: patients with no or mild AS ($n = 150$) and patients with moderate to severe AS ($n = 17$). There were no significant differences in the diameter of the annulus, the diameter of the sinus of Valsalva, or the distance between the annulus and the sinus of Valsalva between the patients with and the patients without AS (Table 3). In addition, no differences in the distance between the annulus, the left coronary leaflet, and the ostium of the left coronary artery were detected between the 2 groups (Table 3).

In 13 of the 17 patients with AS (76%), the left coronary leaflet was longer than the distance between the annulus and the ostium of the left coronary artery (mean difference 2.5 ± 2.2 mm). Of interest, the percentage of patients in which the left coronary leaflet was longer than the distance between the annulus and the ostium of the left coronary artery was significantly greater in the AS group than in the control group (76% vs. 46%, $p < 0.05$).

Table 3. Anatomical Analysis of the Aortic Root in Patients With and Without AS

Variable	Patients Without AS (n = 150)	Patients With AS (n = 17)*	p Value
Aortic annulus diameter			
Coronal view, diastole (mm)	26.3 ± 2.6	26.7 ± 3.9	0.6
Sagittal view, diastole (mm)	23.4 ± 2.7	24.2 ± 3.0	0.2
Coronal view, systole (mm)	26.4 ± 2.8	27.3 ± 3.7	0.3
Sagittal view, systole (mm)	24.0 ± 2.6	24.7 ± 3.0	0.4
Sinus of Valsalva			
Diameter (mm)	32.3 ± 3.9	33.4 ± 4.6	0.2
Distance between annulus and sinus of Valsalva (mm)	17.2 ± 2.7	17.3 ± 3.9	0.9
Relation aortic annulus, coronary leaflet, ostium coronary artery			
Distance between annulus and ostium left coronary artery (mm)	14.4 ± 2.8	14.0 ± 3.3	0.6
Length of left coronary leaflet (mm)	14.1 ± 1.7	14.7 ± 2.4	0.3
Distance between annulus and ostium right coronary artery (mm)	17.2 ± 3.3	17.2 ± 3.6	0.9
Length of right coronary leaflet (mm)	13.1 ± 1.7	14.1 ± 2.9	0.2
Distance between tip of left coronary leaflet and ostium left coronary artery, diastole (mm)	17.6 ± 2.7	17.1 ± 2.9	0.4
Distance between tip of left coronary leaflet and ostium left coronary artery, systole (mm)	11.9 ± 3.1	12.1 ± 2.4	0.9
Sinotubular junction			
Diameter (mm)	28.1 ± 3.1	28.9 ± 4.2	0.3
Distance between annulus and sinotubular junction (mm)	20.3 ± 3.1	20.7 ± 4.6	0.8

*For the anatomical analysis, 2 patients with a bicuspid aortic valve were excluded.
AS = aortic stenosis.

DISCUSSION

In the present study, the anatomy of the aortic root was assessed with the use of 64-slice MSCT in 169 patients, including 19 patients with AS. It was noted that the annulus of the aorta has an oval shape, with a larger diameter on the coronal view than on the sagittal view. In addition, a wide variability in the distance between the annulus and the ostium of the left coronary artery and a wide variability in the leaflet length was observed. A MSCT of the aortic root may be helpful in planning and performing transcatheter aortic valve replacement procedures and in the selection of potential candidates for these procedures.

Anatomical observations of the aortic root diameter and geometry. In the present study, the diameter of the aortic annulus was assessed on a coronal and a sagittal view (similar to the anterior-posterior and the parasternal long-axis views, respectively). The diameter of the annulus on the coronal view was consistently larger than on the sagittal view, indicating an oval shape of the aortic annulus. From previous anatomical studies, it has become apparent that the annulus of the aorta is not a circular structure, but rather a 3-pronged coronet (10). In addition, at the base of the right and left coronary sinuses, a crescent of ventricular musculature is incorporated, in contrast to the noncoronary sinus that is exclusively fibrous (11). These anatomical observations may explain the variations in aortic annulus diameter as found in the present study.

Detailed, noninvasive information on the aortic annulus diameter, as provided by MSCT, may be of great value in transcatheter aortic valve replacement. Kazui et al. (12) studied the anatomy of the aortic root in 25 patients without significant valvular disease using 16-slice computed tomography (CT). The reported diameter of the aortic annulus in the diastolic phase was 22.1 ± 2.2 mm (12). Similar to the results of the present study, no differences in annulus diameter were found between diastole and systole. Unfortunately, no patients with AS were studied in the study by Kazui et al. (12).

Recently, Willmann et al. (7) studied 25 patients with severe AS prior to surgical aortic valve replacement. With the use of 4-slice CT, the smallest diameter of the annulus was assessed on a reconstructed double oblique view. The mean diameter was 2.4 ± 0.2 cm, and a good agreement between noninvasive assessment of the aortic annulus with CT and the measurement during aortic valve replacement was noted (mean difference 0.7 mm) (7).

In the present study, similar results for the annulus diameter were observed (mean diameters were 26.3 ± 2.8 mm and 23.5 ± 2.7 mm on the coronal and the sagittal view, respectively). The use of a 64-slice scanner in the current study, and the use of different reconstructions may explain the subtle differences between the previously reported results (7) and the present study. By providing detailed information on variations in aortic annulus diameter, MSCT may be of great value for prosthesis sizing and avoidance of paravalvular leakage in percutaneous aortic valve replacement.

Anatomical observations of the relation between aortic annulus, leaflet, and left coronary artery. In the present study, a large variability in the relation between the aortic annulus and the left coronary artery was found, with important implications for transcatheter aortic valve replacement. Jatene et al. (13) evaluated the anatomy of the aortic root in an autopsy study of 100 structural normal hearts. The mean distance between the ostium of the left coronary artery and the base of the sinus of Valsalva was 13.3 mm (13). Unfortunately, no range in distances was reported in that study. In another anatomical study, McAlpine (14) studied 100 human hearts. The mean distance between the annulus and the right and left coronary orifices was 18.5 ± 2.5 mm (14). Abedin and Goldberg (15) studied 54 patients undergoing coronary angiography. Average distance from the base of the left coronary sinus to the origin of the left main coronary artery was 19.4 ± 2.7 mm (15). Interestingly, this distance showed a large variability and was independent of the patient's height. In the present study, mean distance between the ostium and the annulus was 14.4 ± 2.9 mm. Importantly, a wide variation in distance was found, ranging from 7.1 to 22.7 mm. In 49% of the patients, the distance between the ostium and the annulus was smaller than the left coronary leaflet length. This may increase the risk of coronary occlusion when a transcatheter aortic valve replacement is performed (4). Of note, the percentage of patients in which the left coronary leaflet was longer than the distance between the annulus and the ostium of the left coronary artery was significantly greater in the patients with AS than in the remaining patients.

Implications for transcatheter aortic valve replacement. The present study demonstrates that there is a wide variability in the anatomy of the aortic root. These findings have important implications for percutaneous aortic valve replacement procedures (Fig. 8). From the first human experience with the

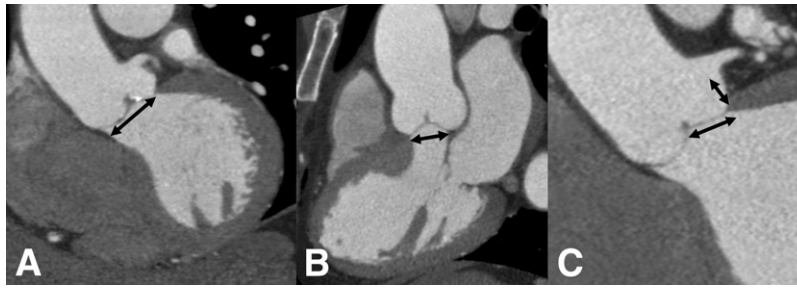


Figure 8. Representative Examples of Patients in Which Difficulties With Transcatheter Aortic Valve Replacement May Be Encountered

Panels A and B demonstrate an example of a patient with an oval shape of the aortic annulus. The diameter of the aortic annulus on the coronal view (A) was 27.3 mm, whereas the annulus diameter on the sagittal view (B) was 20.3 mm. A significant oval shape of the aortic annulus may increase the risk of paravalvular leakage after percutaneous aortic valve replacement. Panel C demonstrates a patient in which the length of the coronary leaflet exceeded the distance between the aortic annulus and the ostium of the left coronary leaflet (distances were 13.4 and 11.6 mm, respectively). There is an increased risk of coronary occlusion by the coronary leaflet or the prosthesis sealing annular cuff in these patients.

self-expanding aortic valve prosthesis (CoreValve), it has become apparent that difficulties with positioning of the device in the aortic annulus were responsible for failure of half of the procedures (5). In addition, correct prosthesis sizing is of great importance in percutaneous valve procedures. At present, prosthesis diameters range between 21 and 26 mm (3–5). Annulus-prosthesis mismatch as a consequence of inaccurate sizing of the prosthesis may result in severe paravalvular leakage. A MSCT provides detailed noninvasive information on the aortic annulus diameter before the procedure and may thereby be helpful in planning and performing of percutaneous aortic valve replacement.

Furthermore, in the present study, a variable distance between the level of the aortic annulus and the ostium of the left coronary artery was observed, ranging from 7.1 to 22.7 mm. At present, the height of the aortic valve prostheses ranges between 14.5 mm (Edwards, Irvine, California) and 50 mm (CoreValve). To avoid interference of the coronary ostia by the prosthesis stent struts, the Edwards prosthesis is preferably positioned under the level of the coronary ostia. However, occlusion of the coronary ostia with this prosthesis may still occur (4). The larger CoreValve has a design feature with a waist in the middle part to protect the coronary ostia. Zajarias et al. (16) did not observe problems accessing the coronary ostia after percutaneous aortic valve replacement. However, if the distance between the annulus and the left coronary ostium is small, it may be difficult to access the coronary ostia after transcatheter aortic valve replacement. Furthermore, the lower part of the currently available aortic prostheses incorporates a sealing annular cuff.

If the distance between the annulus and the coronary ostium is smaller than the lower two-thirds of the prosthesis, coronary occlusion may occur. With the use of MSCT, the distance between the aortic annulus and the ostium of the left coronary artery can accurately be assessed.

In addition, MSCT can provide accurate quantification of the severity and the exact location of aortic valve calcification. Heavily calcified aortic valves may hamper the ability of the prosthesis to cross the native valve in percutaneous valve replacement (5). In contrast to transthoracic and transesophageal echocardiography and magnetic resonance imaging, MSCT allows for an accurate, noninvasive evaluation of aortic valve calcification. Finally, MSCT can also provide detailed, noninvasive information on the tortuosity, diameter, and calcification of the descending aorta and femoral arteries, which is of great importance for the advancement of the sheath during transcatheter aortic valve replacement procedures (4). Therefore, MSCT may help in the selection of potential candidates for transcatheter aortic valve replacement.

Study limitations. Some limitations of the present study need to be addressed. First, the study population of the present study does not comprise AS patients referred for percutaneous aortic valve replacement. Future studies are needed to assess the value of noninvasive evaluation of the aortic root with MSCT in these patients. Second, the use of MSCT before percutaneous aortic valve replacement may be optimized by recent technical advances and newer generation MSCT scanners. The use of dual-source technology allows for a significant improvement in temporal resolution. Further-

more, radiation exposure may be significantly reduced by the use of dose modulation during scanning.

CONCLUSIONS

The anatomy of the aortic root can be assessed noninvasively with MSCT. A large variability in the aortic annulus diameter and the relation between

the annulus, the left coronary leaflet, and left coronary artery exists. A MSCT may provide useful information for the selection of potential candidates for transcatheter aortic valve replacement.

Reprint requests and correspondence: Dr. Laurens F. Tops, Department of Cardiology, Leiden University Medical Center, Albinusdreef 2, 2333 ZA Leiden, the Netherlands. *E-mail:* l.f.tops@lumc.nl.

REFERENCES

1. Iung B, Baron G, Butchart EG, et al. A prospective survey of patients with valvular heart disease in Europe: the Euro Heart Survey on Valvular Heart Disease. *Eur Heart J* 2003;24:1231-43.
2. Bonow RO, Carabello BA, Kanu C, et al. ACC/AHA 2006 guidelines for the management of patients with valvular heart disease: a report of the American College of Cardiology/American Heart Association Task Force on Practice Guidelines (Writing Committee to Revise the 1998 Guidelines for the Management of Patients With Valvular Heart Disease): developed in collaboration with the Society of Cardiovascular Anesthesiologists: endorsed by the Society for Cardiovascular Angiography and Interventions and the Society of Thoracic Surgeons. *J Am Coll Cardiol* 2006;48:e1-148.
3. Cribier A, Eltchaninoff H, Tron C, et al. Treatment of calcific aortic stenosis with the percutaneous heart valve: mid-term follow-up from the initial feasibility studies: the French experience. *J Am Coll Cardiol* 2006;47:1214-23.
4. Webb JG, Chandavimol M, Thompson CR, et al. Percutaneous aortic valve implantation retrograde from the femoral artery. *Circulation* 2006;113:842-50.
5. Grube E, Laborde JC, Gerckens U, et al. Percutaneous implantation of the CoreValve self-expanding valve prosthesis in high-risk patients with aortic valve disease: the Siegburg first-in-man study. *Circulation* 2006;114:1616-24.
6. Rosenhek R, Binder T, Porenta G, et al. Predictors of outcome in severe, asymptomatic aortic stenosis. *N Engl J Med* 2000;343:611-7.
7. Willmann JK, Weishaupt D, Lachat M, et al. Electrocardiographically gated multi-detector row CT for assessment of valvular morphology and calcification in aortic stenosis. *Radiology* 2002;225:120-8.
8. Agatston AS, Janowitz WR, Hildner FJ, Zusmer NR, Viamonte M Jr., Detrano R. Quantification of coronary artery calcium using ultrafast computed tomography. *J Am Coll Cardiol* 1990;15:827-32.
9. Schiller NB, Shah PM, Crawford M, et al. Recommendations for quantitation of the left ventricle by two-dimensional echocardiography. American Society of Echocardiography Committee on Standards, Subcommittee on Quantitation of Two-Dimensional Echocardiograms. *J Am Soc Echocardiogr* 1989;2:358-67.
10. Anderson RH, Lal M, Ho SY. Anatomy of the aortic root with particular emphasis on options for its surgical enlargement. *J Heart Valve Dis* 1996;5 Suppl 3:S249-57.
11. Anderson RH. Clinical anatomy of the aortic root. *Heart* 2000;84:670-3.
12. Kazui T, Izumoto H, Yoshioka K, Kawazoe K. Dynamic morphologic changes in the normal aortic annulus during systole and diastole. *J Heart Valve Dis* 2006;15:617-21.
13. Jatene MB, Monteiro R, Guimaraes MH, et al. Aortic valve assessment. Anatomical study of 100 healthy human hearts. *Arq Bras Cardiol* 1999;73:75-86.
14. McAlpine WA. An introduction to the aorto-ventricular unit. In: McAlpine WA, editor. *Heart and Coronary Arteries. An Anatomical Atlas for Clinical Diagnosis, Radiological Investigation, and Surgical Treatment*. Berlin: Springer-Verlag, 1975: 9-27.
15. Abedin Z, Goldberg J. Origin and length of left main coronary artery: its relation to height, weight, sex, age, pattern of coronary distribution, and presence or absence of coronary artery disease. *Cathet Cardiovasc Diagn* 1978;4:335-40.
16. Zajarias A, Eltchaninoff H, Cribier A. Successful coronary intervention after percutaneous aortic valve replacement. *Catheter Cardiovasc Interv* 2007;69:522-4.