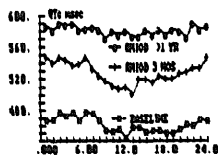
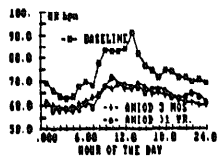


9:45

AMIODARONE ABOLISHES CIRCADIAN VARIABILITY OF QTc BUT NOT THAT OF HEART RATE: SIGNIFICANCE FOR PREVENTION OF SUDDEN DEATH

M. Antimisiaris, M. Schoenbaum, Jonnalagedda S.M. Sarma, Laurel M. Pollard, K. Venkataraman, Bramah N. Singh. Wadsworth VA and City of Hope Medical Centers, Los Angeles, CA

Amiodarone (Am), a potent Class III antiarrhythmic, has a complex pharmacologic profile but the basis of its 24-hour protection against VT/VF is unclear. The circadian rhythmicity (CR) of heart rate (HR) and QTc (QT normalized for HR using an exponential formula) were



determined from 24-hour Holter recordings before (n=8), at 3 months (n=8), and after >1 year (n=13) on Am in patients with ventricular arrhythmias. Mean data show (see figures): i) reduced HR (p<0.001), unchanged after 3 months, with intact CR, and ii) prolonged QTc (p<0.001), increasing beyond 3 months, with virtual loss of CR after 12 months.

Conclusions: 1) Effects of Am on HR and QTc have independent time courses, and the time required for QTc to attain steady state is much longer than generally thought. 2) Am provides antifibrillatory effects over 24 hours, at steady

state, during chronic therapy by uniform prolongation of ventricular refractoriness with minimal diurnal variation.

Wednesday, March 6, 1991

8:30AM-10:00AM, Room 257, West Concourse
Surgical Treatment of Cardiac Arrhythmias

8:30

ARRHYTHMOGENIC RIGHT VENTRICULAR DYSPLASIA - SURGICAL MANAGEMENT.

Kishore Nimkhedkar, Stephen S. Furniss, John P. Bourke, Brian Glenville, Janet M. McComb, Colin J. Hilton, Ronald W.F. Campbell. Departments of Cardiology and Cardiothoracic Surgery, Freeman Hospital, Newcastle upon Tyne, U.K.

Arrhythmogenic right ventricular dysplasia (ARVD) is a rare but important cause of ventricular tachycardia (VT) which is often refractory to medical treatment. Nine male patients - 5 presenting with cardiac arrest - aged 26-73 years, (mean 41 yrs) underwent surgery for life threatening VT. Pts had failed a mean of 5 drugs (minimum 3) prior to surgery. All had inducible VT preoperatively of LBBB morphology. Three had a family history compatible with ARVD. At operation, right ventricle (RV) was grossly diseased and sustained monomorphic or multimorphic tachycardias were induced and mapped in all patients. Three pts had more than one VT morphology. One underwent cryoablation of an arrhythmogenic focus situated in upper part of RV septum. Eight underwent partial (4) or total (4) RV disarticulations. During mean follow up of 20 months (range 2-59) three pts required drug treatment for VT recurrences. All RV disarticulated pts experienced right heart failure postoperatively but improved progressively with the development of systolic septal movement into the RV cavity. All 9 pts are in NYHA functional class I/II at latest follow up.

Arrhythmia surgery provides an alternative management option in patients with ARVD and drug resistant VT.

8:45

SURGICAL DIVISION OF WOLFF-PARKINSON-WHITE PATHWAYS UTILIZING THE EPICARDIAL TECHNIQUE

Mahomed, Y, King, R, Zipes, D, Miles, W, Klein, L and Brown, J. Indiana University School of Medicine, Indianapolis, IN

Highly successful results have been achieved for interruption of Kent Bundles utilizing both the endocardial and epicardial techniques. The epicardial technique, which employs surgical distribution and cryoablation, has been successfully applied to interrupt pathways in 140 consecutive patients since May of 1985. There were 96 male and 44 female patients who ranged in age from 10-67 years (mean 28 years). Distribution of the accessory pathways were as follows: 55% left freewall, 25% posterior septal, 15% right freewall and 5% anteroseptal pathways.

Pre, post and intraoperative electrophysiologic studies were performed in all patients.

All accessory pathways were initially successfully ablated without any deaths or heart block. Concomitant surgical procedures were performed in 8% of patients. Four patients required a second operation for pathways not initially identified and only two of these have had persistent pathway activity. The rest of the patients have remained free of arrhythmia recurrence.

We conclude that the epicardial technique is safe, reproducible and advantages of the technique include: continuous monitoring of cardiac rhythm, avoidance of heart block, recognition of multiple pathways and avoidance of aortic-cross clamping and cardioplegic arrest and the ability to perform concomitant cardiac surgical procedures safely.

9:00

WPW SYNDROME: MORPHOMETRIC ANALYSIS OF SURGICAL ANATOMY

William L. Holman, University of Alabama at Birmingham, Birmingham, Alabama

Qualitative descriptions of the anatomic regions of dissection for WPW syndrome currently exist. The purpose of this study was to collect data that quantitatively describe this anatomy. These new data enhance existing anatomic descriptions and quantify relationships between anatomic landmarks encountered during dissection.

Fourteen cadaveric human hearts were dissected to quantitatively describe four anatomic regions of dissection in WPW syndrome [anterior/posterior septum (A/PS); right/left free wall (R/LFW)]. Mean dimensions of the PS dissection were 27±7mm along the tricuspid annulus, 26±6mm along the mitral annulus and 27±5mm at the crux. The PS dissection reached 5±4mm anterior and 13±5mm posterior to the posteromedial mitral commissure. The AS dissection extended 29±12mm along the tricuspid annulus. The AV groove at the anterior edge of the AS is 17±4mm wide. As the dissection proceeds towards the septum the width increases to 31±9mm, then abruptly decreases where the aorta abuts the right atrium 2±1mm below the right atrial endocardium. The dimensions of the RFW and LFW were measured. In both the RFW and LFW the AV groove fat extends down over the ventricular free wall. This distance over the ventricular wall is correlated with the width of the AV groove (r=0.89 p<0.0001 RFW; r=0.87 p<0.0001 LFW).

This quantitative description of surgical anatomy in WPW syndrome may improve accuracy in electrophysiologic localization and surgical disruption of accessory AV connections.