



## International Journal of Surgery Case Reports

journal homepage: [www.casereports.com](http://www.casereports.com)

## Unusual association of Meckel's diverticulum with double appendix – A rare finding



Sangram Keshari Panda\*, C. Prasad, Roshni Tirkey, V. Rajesh, Jagadananda Mishra, Rajesh Kumar Dora

Department of General Surgery, SCB Medical College, Cuttack, Odisha 753003, India

## ARTICLE INFO

## Article history:

Received 31 July 2014

Received in revised form 28 August 2014

Accepted 7 September 2014

Available online 2 October 2014

## Keywords:

Congenital anomalies

Meckel's diverticulum

Appendiceal diverticulosis

Adenocarcinoma of the colon

## ABSTRACT

**INTRODUCTION:** Appendix duplication is an extremely rare congenital anomaly that is seen in 0.004–0.009% of appendectomy specimens. Duplicated appendix may be associated with number of congenital anomalies.

**PRESENTATION OF CASE:** In this case report, we are presenting a rare case of duplicated vermiform appendix with a co-existing Meckel's diverticulum.

**DISCUSSION:** Anomalies of appendix are rare and duplication of vermiform appendix is extremely rare. In 1936, Cave classified appendiceal duplication for the first time which was modified by Wallbridge in 1963 into three types. Concomitant malformations or duplications of the large intestine or the genitourinary system may be present, especially in types B1 and C probably due to their similar embryological origin. Here we are presenting a very rare case report of type B1 appendix anomaly associated with Meckel's diverticulum.

**CONCLUSION:** Surgeons should be aware of these conditions because of the possible clinical implications.

© 2014 The Authors. Published by Elsevier Ltd. on behalf of Surgical Associates Ltd. This is an open access article under the CC BY-NC-ND license (<http://creativecommons.org/licenses/by-nc-nd/3.0/>).

## 1. Introduction

Appendix duplication is an extremely rare congenital anomaly that is seen in 0.004–0.009% of appendectomy specimens.<sup>1</sup> Even though the abnormality is rare, the complications that might arise from an unidentified duplicate appendix may have serious, life-threatening consequences for the patient. In patients with appendix duplication, it has been reported that acute appendicitis occurred in one<sup>2</sup> or both<sup>3</sup> appendixes and as long as six years after the first appendectomy.<sup>4</sup> Pre-operative diagnosis of appendix duplication is often difficult, and it is usually determined during the operation. Duplication of the appendix is often associated with other embryological malformations such as duplications of the large intestine and genito-urinary tract which occur most commonly in type B1 and C duplications, bony malformations, imperforate anus<sup>5</sup> and in this case, a Meckel's diverticulum.

## 2. Case report

A 24-year-old Indian man presented with a 1-day history of abdominal pain that started as diffuse pain and became located in the right lower quadrant. He also experienced loss of appetite, fever, nausea and vomiting. He had undergone no previous abdominal or pelvic surgery. His physical examination revealed tachycardia, tenderness in the right iliac fossa, local guarding and rebound tenderness at the Mc Burney point, consistent with signs of acute appendicitis. His body temperature was 38 °C, pulse rate was 96 beats/min and his blood pressure was 112/64 mmHg. The urine examination result was normal. Laboratory investigations, including serum electrolyte levels and complete blood count, were within normal limits, except for a moderately elevated white cell count (13,400/mm<sup>3</sup>). Plain chest and abdominal radiography showed no abnormal signs. Ultrasonography abdomen showed a blind-ended aperistaltic tubular structure with dilated lumen and thickened wall. No appendiceal anomaly was noticed. A diagnosis of acute appendicitis was made.

The patient was taken up for surgery. With the Grid iron incision, abdomen was opened, appendix was identified by tracing the taenia coli of caecum. One more tubular structure is found adjacent to the appendix arising from the opposite side of the ileocaecal valve (Fig. 1). With the suspicion of double appendix, part of circumference of tubular structure is cut and artery forceps were inserted. The forceps were easily going to the caecum (Fig. 2).

\* Corresponding author. Mobile: +91 9776636938.

E-mail addresses: [drsangram83@gmail.com](mailto:drsangram83@gmail.com) (S.K. Panda), [prasadc\\_dr@yahoo.co.in](mailto:prasadc_dr@yahoo.co.in) (C. Prasad), [roshni939@gmail.com](mailto:roshni939@gmail.com) (R. Tirkey), [drvrajesh1@gmail.com](mailto:drvrajesh1@gmail.com) (V. Rajesh), [drjnms@gmail.com](mailto:drjnms@gmail.com) (J. Mishra), [dora.rajesh@yahoo.com](mailto:dora.rajesh@yahoo.com) (R.K. Dora).

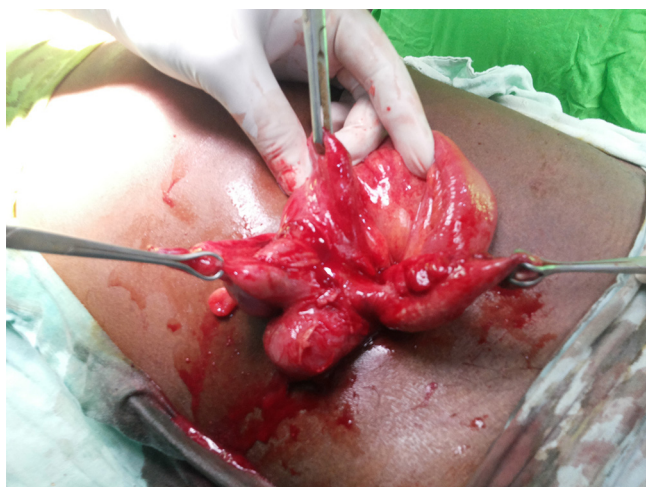

Fig. 1. Two appendices located symmetrically on either side of the ileocaecal valve.

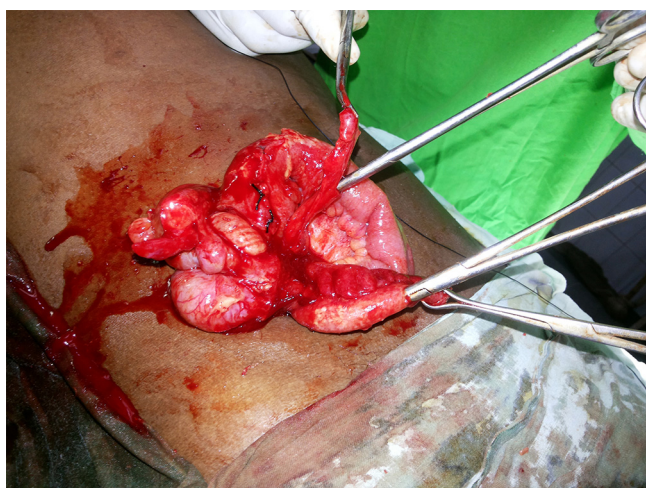

Fig. 2. Part of circumference of tubular structures is cut and artery forceps were inserted.

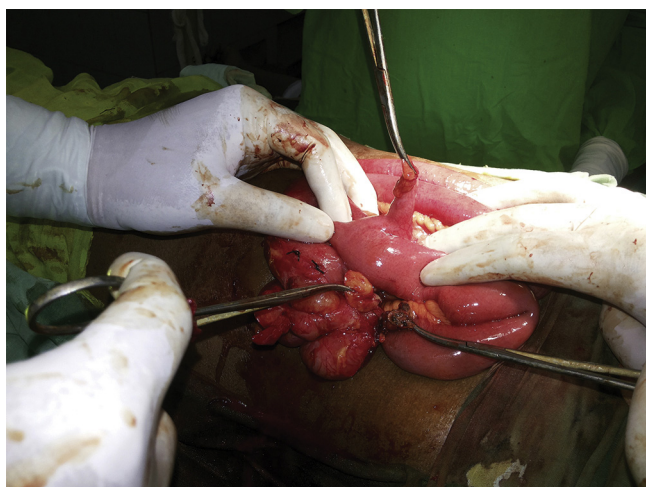

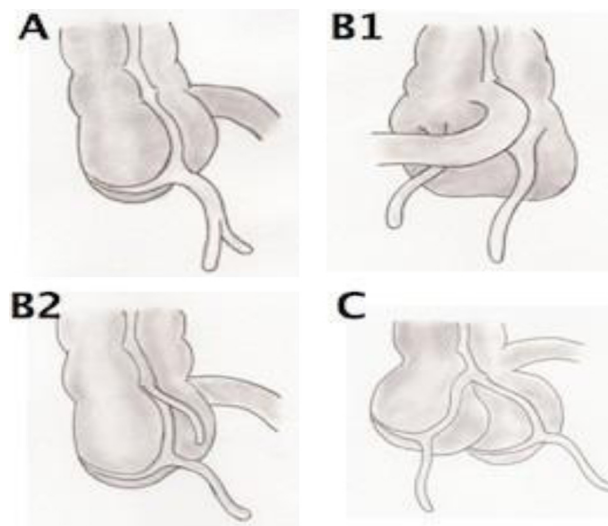
Fig. 3. Presence of Meckel's diverticulum over the antimesenteric border of ileum.

Both the appendix were removed and sent for histopathological examinations. Then we checked for presence of other anomalies, incidentally we found a Meckels diverticulum over the antimesenteric border of ileum around 2 feet from the ileocaecal junction

(Fig. 3). On gross examination, inflammation of Meckel's diverticulum was suspected. So Meckel's diverticulectomy was performed and the specimen was sent for histopathological examination. Histological analysis showed a Meckel's diverticulum lined by small bowel mucosa with presence of heterotopic rests of gastric mucosa and no active inflammation, one appendix with features of acute appendicitis and another appendix with no evidence of inflammation. Post-operative period was uneventful and the patient was discharged on 7th postoperative day.

3. Discussion

Anomalies of appendix are rare and duplication of vermiform appendix is extremely rare. Collins studied 50,000 appendectomy specimens and found appendiceal duplication in two cases (0.0004%);<sup>6</sup> however, Kjossev and Losanoff got one case in 10,956 specimens (0.009%).<sup>1</sup> Less than 100 cases of appendiceal duplication have been reported in the literature till now.<sup>1</sup> In 1936, Cave<sup>7</sup> classified appendiceal duplication for the first time which was modified by Wallbridge<sup>8</sup> in 1963 into three types as shown in figure below.<sup>9</sup>



(Cave-Wallbridge Classification: Type A: Single caecum with one normally localized appendix exhibiting partial duplication. Type B1: Two appendices located symmetrically on either side of the ileocaecal valve. Type B2: One appendix arises from the caecum at the usual site and the second branches at varying distances along the taenia from the first. Type C: Double caecum, each bearing its own appendix.)

This classification system also “enriched” by Biermann in 1993 (Table 1). More recently cases that cannot be included to the types shown in the table have been described as “the horseshoe

Table 1  
The modified Cave–Wallbridge classification.

Type A	A single cecum with various degrees of partial duplication
Type B1	Also referred to as the “bird type” in which the 2 appendices are symmetrically placed on either side of the ileocecal valve
Type B2	Also referred to as the “taenia–coli type” in which one appendix arises from the cecum at the usual site and a second appendix branches from the cecum along the lines of the taenia at various distances from the first
Type B3	The second appendix arises from the hepatic flexure
Type B4	The second appendix arises from the splenic flexure
Type C	A double cecum each with an appendix

The modified Cave–Wallbridge classification.

appendix” in which one appendix has two openings into a common caecum<sup>10</sup> and finally “the triple appendix”, an extremely rare condition with only a couple of cases reported.<sup>11</sup> In our case, a type B1 appendix anomaly (Cave-Wallbridge classification) was encountered as two appendixes symmetrically placed on either side of the ileocecal valve (Bird type).

A double appendix may be either asymptomatic or it may present with symptoms deriving from obstruction or inflammation even long after an appendectomy performed for the excision of one of the two appendixes. In children, however, concomitant malformations or duplications of the large intestine or the genitourinary system may be present, especially in types B1 and C probably due to their similar embryological origin and may serve as “alarm” signs.<sup>12</sup> In our case report, type B1 appendix anomaly was associated with Meckel’s diverticulum which is very rare.

Duplication of the appendix, as with a single appendix, can be completely asymptomatic if there is no pathology of the structure. However, it can present as acute appendicitis. In addition, it has been reported that a duplicated appendix can mimic adenocarcinoma of the colon<sup>5</sup> and can cause small bowel obstruction.<sup>3</sup> Although Barium studies can be performed to demonstrate a duplicated appendix,<sup>13</sup> such investigations are not routinely performed as appendicitis is a clinical diagnosis. Therefore most are discovered incidentally at the time of surgery or autopsy, or by histopathological analysis.<sup>14</sup> It is important not to confuse a duplicated appendix with a solitary diverticulum of the caecum or appendiceal diverticulosis. These can be distinguished by histology as the wall of the diverticulum does not contain lymphoid tissue.

This is the first reported case of a duplicated appendix associated with a Meckel’s diverticulum. The latter is thought to arise due to incomplete obliteration of the vitelline duct which in embryonic life, provides nutrition to the fetal midgut from the yolk sac. The duct normally obliterates by 7 weeks of gestation. When the duct fails to disappear fully, an outpouching of the intestine persists, known as a Meckel’s diverticulum. The embryological nature of a Meckel’s diverticulum and that of a duplicated appendix suggests a common underlying mechanism involving developmental malformation. In this case, patient was having symptoms of appendicitis. Sometimes, Meckel’s diverticulitis may mimic acute appendicitis clinically and should be considered in the differential diagnosis of a patient with right lower quadrant pain.<sup>15</sup> On laparotomy, we found double appendixes along with Meckel’s diverticulum and on gross examination, inflammation of Meckel’s diverticulum was suspected. So Meckel’s diverticulectomy was performed in this patient. Peptic ulceration of ileal mucosa due to ectopic gastric mucosa can cause diverticulitis. It may also result from diverticular torsion that causes secondary ischemia and inflammatory change. If this condition is left untreated, it usually leads to perforation and peritonitis.<sup>15</sup>

It is important for surgeons to be aware of this condition because, for example, a patient may present clinically with appendicitis but at exploration the apparently single appendix may appear normal and a second inflamed appendix may be missed which could later perforate and have fatal consequences.<sup>14</sup> However, exploration for a second appendix is not routine as it is a rare occurrence and the increased risks of further exploration do not justify its routine use. Also, if at surgery one appendix is found to be inflamed and a second one is not, then both should be removed in order to avoid diagnostic confusion<sup>16</sup> and to avoid two separate operations being carried out if the second one

subsequently becomes inflamed. The importance of this was illustrated by Maizels in 1966 in a report of a child having two appendicectomies within 5 months.<sup>17</sup>

#### 4. Conclusion

Although a rare condition, the complications that arise from an overlooked duplicate appendix can have serious, life-threatening consequences for the patient. Surgeons should be aware of these conditions because of the possible clinical implications.

#### Conflict of interest

All the authors declare that there is no conflict of interest.

#### Funding

None declared.

#### Ethical approval

Written informed consent was obtained from the patient for publication of this case report and accompanying images. A copy of the written consent is available for review by the Editor-in-Chief of this journal on request.

#### Author contributions

Sangram Keshari Panda: Study design and data collection; Roshni Tirkey: Data analysis and writing; V. Rajesh: Data collection and writing; C. Prasad: Data collection and writing; Jagadananda Mishra: Data collection and data analysis; Rajesh Kumar Dora: Data collection and data analysis.

#### References

- Kjossev KT, Losanoff JE. Duplicated vermiform appendix. *Br J Surg* 1996;**83**:1259.
- Griffiths EA, Jagadeesana J, Fasiha T, Mercer-Jones M. Bifid vermiform appendix: a case report. *Curr Surg* 2006;**63**:176–8.
- Chew DK, Borromeo JR, Gabriel YA, Holgersen LO. Duplication of the vermiform appendix. *J Pediatr Surg* 2000;**35**:617–8.
- Travis JR, Weppner JL, Paugh JC. Duplex vermiform appendix: case report of a ruptured second appendix. *J Pediatr Surg* 2008;**43**:1726–8.
- Bluett MK, Halter SA, Salhany KE. Duplication of the vermiform appendix mimicking adenocarcinoma of the colon. *Arch Surg* 1987;**122**:817–20.
- Collins DC. A study of 50,000 specimens of the human vermiform appendix. *Surg Gynecol Obstet* 1955;**101**:437–45.
- Cave AJ. Appendix vermiformis duplex. *J Anat* 1936;**70**:283–92.
- Wallbridge PH. Double appendix. *Br J Surg* 1962;**50**:346–7.
- Heetun M, Stavrinides V, Keeler B, Phillips D, Taylor A. A tale of two appendixes – an unexpected finding. *J Surg Case Rep* 2012;**2012**(3):5.
- Mesko TW, Lugo R, Breitholtz T. Horseshoe anomaly of the appendix: a previously undescribed entity. *Surgery* 1989;**106**(3):563–6.
- Urieve L, Maslovsky I, Mnouskin Y, Ben-Dor D. Triple-barreled type of appendiceal triplication. *Ann Diagn Pathol* 2006;**10**(3):160–1.
- Christodoulidis G. Acute appendicitis in a duplicated appendix. *Int J Surg Case Rep* 2012;**3**(11):559–62.
- Peddu P, Sidhu PS. Appearance of a type B duplex appendix on barium enema. *Br J Radiol* 2004;**77**(915):248–9.
- Kabay S, Yucel M, Yaylak F, Hacioglu A, Algin MC. Combined duplication of the colon and vermiform appendix in an adult patient. *World J Gastroenterol* 2008;**14**(4):641–3.
- Sharma RJ, Jain VK. Emergency surgery for Meckel’s diverticulum. *World J Emerg Surg* 2008;**3**:27.
- Kothari AA, Yagnik KR, Hathila VP. Duplication of vermiform appendix. *J Postgrad Med* 2004;**50**:285–6.
- Maizels G. Duplication of the vermiform appendix. *S Afr Med J* 1966;**40**:1123.

#### Open Access

This article is published Open Access at [sciedirect.com](http://sciedirect.com). It is distributed under the [IJSCR Supplemental terms and conditions](#), which permits unrestricted non commercial use, distribution, and reproduction in any medium, provided the original authors and source are credited.