



Contents lists available at ScienceDirect

Journal of Acute Disease

journal homepage: [www.jadweb.org](http://www.jadweb.org)

Document heading doi: 10.1016/S2221-6189(14)60041-X

# Gunshot wounds: A review of ballistics related to penetrating trauma

Panagiotis K. Stefanopoulos<sup>1\*</sup>, Georgios F. Hadjigeorgiou<sup>2</sup>, Konstantinos Filippakis<sup>3</sup>, Dimitrios Gyftokostas<sup>4</sup>

<sup>1</sup>Colonel (Ret.), Private practice (maxillofacial surgery), Athens, Greece

<sup>2</sup>Resident, Department of Neurosurgery, Red Cross Hospital, Athens, Greece

<sup>3</sup>Brigadier, Department of ENT–Head and neck surgery, 401 Army Hospital, Athens, Greece

<sup>4</sup>Vascular surgeon

## ARTICLE INFO

### Article history:

Received

Received in revised form

Accepted

Available online

### Keywords:

Wound ballistics

Gunshot wounds

Penetrating trauma

Firearms

## ABSTRACT

Civilian gunshot injuries from handgun and rifle ammunition vary in severity depending on the anatomic location involved and the different effects from the ballistic properties of the penetrating projectiles. Ballistic factors such as the impact velocity and energy should not be considered in isolation, as their specific effects are determined by the interaction between the projectile and tissues. Increased tissue damage can result from tumbling of non-deforming rifle bullets and deformation of expanding bullets. Both of these mechanisms increase substantially the energy transfer to the wound and its diameter, also producing a pulsating temporary cavity associated with pressure changes within tissue.

## 1. Introduction

Since the introduction of the term “wound ballistics”<sup>[1,2]</sup> indicating the study of the wounding mechanisms of missiles<sup>[3]</sup>, extensive experimental research on this field has been conducted by investigators with a military background<sup>[4–7]</sup>. In the context of wound ballistics, the term missile is used to denote various types of small projectiles, such as bullets and fragments, that have enough kinetic energy to penetrate a living target<sup>[8]</sup>. Civilian gunshot injuries have been studied to a lesser

extent in connection to ballistic aspects<sup>[9–10]</sup>, with major contributions by two influential forensic scientists, Beat Kneubuehl<sup>[11]</sup> in Europe, and Vincent DiMaio<sup>[12]</sup> in the US.

Whereas the severity of any penetrating injury is eventually related to the vicinity of the wound track to vital organs and large vessels, the nature of gunshot wounds (GSW) is influenced by the dynamics of the projectile and the local reaction of the penetrated tissue<sup>[13–16]</sup>. These two aspects reflect the complex projectile–tissue interaction which takes place during the penetration process<sup>[14,17,18]</sup>, accounting for the scientific approach to these injuries both from a physical (ballistic) and biological (“wound”) point of view<sup>[16]</sup>. Therefore, a complete understanding of this process requires a basic knowledge of the ballistic factors implicated in tissue wounding. This paper reviews ballistics of GSW inflicted by handgun and rifle ammunition. Shotgun injuries are not included in the

Corresponding author: Panagiotis K. Stefanopoulos, 88 Pontou Str., Athens 11527, Greece.

Tel: +302710224908, +302107713894

E-mail: [pan.stefanopoulos@gmail.com](mailto:pan.stefanopoulos@gmail.com)

present discussion as they differ from bullet injuries from a ballistic point of view.

## 2. Ballistic behavior of the bullet

The common characteristic of all firearms is a tube of variable length called barrel, with a chamber attached that receives the cartridge (the unit of ammunition) containing the bullet, the propellant, and the primer. The bullet is accelerated down the barrel to a final muzzle velocity under the high pressures built up by the expanding gases from the combustion of the propellant [19,20]. During this phase, the bullet attains a simultaneous rotatory movement (spin) as it is engaged by the spiral grooving of the interior of the gun barrel. This is an important feature called rifling, which necessitates that the diameter (caliber) of the bullet matches the internal diameter of the barrel. Since bullets are essentially axisymmetric bodies designed to afford the minimum area of presentation combined with the maximum possible mass, the spin is necessary for appropriate orientation of the bullet during flight with its tip (nose) pointing forward [2].

Projectiles are customarily classified as “low-” or “high-velocity”, roughly corresponding to the two main categories of small arms, handguns and rifles [4,21]. While low velocity is generally considered synonymous to subsonic (less than 350 m/s) [4,21], the high velocity range is less well defined. In the context of wound ballistics, high velocity is considered to start approximately at 600–700 m/s, above which “explosive effects” are commonly seen [4]. Medium or intermediate velocities (350–600 m/s) [4] are achieved by more powerful handguns, such as those using Magnum ammunition [21].

The nose contour and the mass of the bullet are important for the maintenance of its velocity and energy during flight [22]. Based on the measurements published in ballistic tables [23], the muzzle energy is considered to decrease significantly beyond 45 m for most handgun bullets, and beyond 100 m for rifle bullets [21]. Unfortunately, most civilian GSW are inflicted from an average of 10 m [24].

Modern military (assault) rifles launch their projectiles at 700–960 m/s. Military rifle bullets have a slender streamlined profile with a so-called spitzer (pointed) nose

(Figure 1), which improves their ballistic performance at the supersonic velocity range. With the exception of the newest lead-free designs, these bullets have the typical composition of a lead (“soft”) core protected against friction from the barrel by a shell (“jacket”) of harder metal such as a copper alloy or plated steel, which completely covers the lead core at the nose (but remains open at the base for manufacturing purposes) in order to prevent deformation during soft tissue penetration, a construction designated as full metal-jacketed (FMJ) [13,20,25]. FMJ handgun bullets have round or flat nose.



**Figure 1.** Examples of modern military rifle cartridges: 7.62 mm NATO (left), 5.56 mm NATO (chambered in the M16 rifle) (middle), 7.62 × 39AK–47 (Kalashnikov) (right). Military ammunition terminology uses metric system with bullet diameter expressed in mm.

During flight, bullets are subjected initially to the destabilizing effects of the escaping gases from the muzzle of the gun [26], and thereafter to the drag forces from the air resistance which increase with bullet velocity [4]. Because these forces concentrate on the anterior part of the bullet while its center of mass is located towards its rear, an overturning moment emerges, most prominent on spitzer bullets, which causes the bullet’s longitudinal axis to diverge from the line of trajectory [13,26–28]. This divergence is called yaw and is expressed by the angle between the bullet’s axis and the velocity vector [2,19,25,29,30]. Because of the spin, yawing results in a complex spiral revolution of the bullet’s tip in space about its center of mass, which

is known as precession, similar to the disturbance of a spinning top knocked sideways [26] (Figure 2). However, under the gyroscopic stabilization by the spinprecession displays a declining amplitude with distance [26].



**Figure 2.** Condensed drawing demonstrating bullet yaw with precession (left), proceeding to tumbling (right). Arrow indicates direction of bullet movement.

When an FMJ bullet penetrates tissue, the resistance encountered resulting in its retardation affects its stability and occasionally its integrity, because tissue density is about 800 times greater than that of air and the spin can no longer maintain the bullet's previous orientation [29]. Over a certain distance, which varies depending on the type of the bullet, yawing becomes irreversible, and within a sufficiently long path tumbling eventually occurs, thereafter the bullet advancing base-forward [16,17,30] (Figure 2).



**Figure 3.** Different handgun bullet construction: semi-jacketed hollow-point (SJHP) on the left, and full metal-jacketed round nose (FMJ RN) on the right. Both cartridges are 9 mm Luger.

The other major type of bullet construction is the deforming or expanding bullet which sustains an increase in diameter within the target. This includes solid lead bullets, and the specifically designed partially jacketed bullets which have the tip of the lead core either simply left exposed (jacketed soft-point bullets, JSP) or hollowed (semi-jacketed hollow-point bullets, SJHP). Upon impact

tissue resistance causes these bullets to become flattened or deform into a mushroom shape [13]. Deformed bullets do not yaw [16]. Hollow-point rifle bullets are mandatory for hunting purposes in order to produce instant “humane” killing of the animal [13], but are strictly prohibited for military purposes under the Hague Convention of 1899 as they cause “excessive” wounding [14]. Hollow-point handgun bullets (Figure 3) are in use by some police forces, because deformation of a low-velocity projectile prevents over penetration of the target, which otherwise could result in accidental wounding of bystanders.

### 3. Energy transfer characteristics of gunshot wounds

Several authors [13,15,18,31] have discussed the fallacy of describing the severity of GSW by means of the velocity characteristics of the penetrating missile. In the context of wound ballistics, “low-velocity” and “high-velocity” can only refer to the circumstances of wounding, indicating wounds from handguns and rifles respectively [32]. However, the use of such terms as estimates of the wound itself is inaccurate and potentially misleading, as it is based on the erroneous impression that the extent of wounding is directly proportional to the impact energy of the projectile, which is greatly influenced by its velocity according to the familiar kinetic energy formula ( $KE = 1/2mv^2$ ) [33]. In fact, it is only the energy deposited to the tissues that is transformed to work resulting in tissue disruption [8,14,28]. Although the effects of rifle bullets can be far more destructive compared to handguns because of their higher energy [32], almost all of these so-called “explosive” effects can be traced to the phenomenon of cavitation [3], a prominent manifestation of high-energy transfer, as described below. At the other extreme, a non-deforming (FMJ) rifle bullet traversing in stable flight a limited width of soft tissue will spend only a small fraction of its enormous kinetic energy [4]. Therefore, it is more appropriate to think in terms of energy transfer (or deposition) to the wound in order to outline its extent and severity rather than concentrating on the physical properties of the missile [4,15,29]. Moreover, the extent of tissue damage along the wound track may vary as a result of non-linear energy deposition [14,34]. The rate of energy transfer to the wound

is determined by the tissue resistance to penetration, which is affected by the frontal surface area of the bullet “presented” to the tissue [14,30]. The critical factor leading to higher amounts of energy deposition along the missile track is any increase in the presented area, which invites drag forces of greater magnitude. There are two main mechanisms responsible for such an occurrence. With yawing, the presented area of the bullet can only enlarge; as the yaw angle approaches 90 degrees both the energy transfer and the resulting wounding effect increase markedly [35], as the bullet essentially severs tissue with all its length [13,36]. The small-caliber bullets of the M16 and Kalashnikov AK-74 assault rifles yaw and tumble significantly earlier than the twice heavier bullet used by the ubiquitous AK-47 rifle, thus creating large wounds early in their path [13]. The other mechanism increasing the presented area of the projectile, and also the diameter of the wound track, is bullet deformation [15,37].

#### 4. Mechanisms of gunshot injuries

A bullet retained within the tissues has delivered all its energy, creating a blind wound with only an entrance aperture. Alternatively, a perforating (through-and-through) wound may be produced, with the bullet leaving the body through an exit wound [4]. Although a low-velocity bullet may exit the wound depending on the width and density of the tissues traversed, it has been stated that at high impact velocities, above 550 m/s, a military rifle bullet will always exit an animal the size of a man, following a relatively straight course [38]. Exit wounds tend to be larger and more irregular than entrance wounds, typically as a result of bullet tumbling [18,30].

GSW are considered a special form of blunt trauma [39]. They do not consist simply in plain tissue penetration, since they involve crushing due to overpressure in front of the projectile, and also indirect damage from temporary cavity formation in its wake region [4,12,15,18,34,40,41]. These mechanisms can be interpreted as a sequence of fluid dynamic phenomena [40], with the bullet viewed as an immersed body and the surrounding tissue with its high water content as “flowing” backwards around the

projectile’s surface [41,42]. In addition, in contact or close range GSW, the injury is aggravated by the blast effect of the escaping propellant gases into the tissue [12,31,43]. Tissue burning [4] also occurs with bullets retained in the wound.

##### 4.1. Direct tissue damage

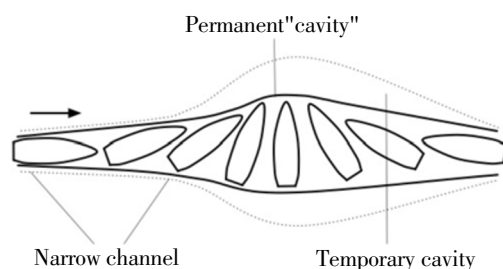
Crush injury followed by rupture of the tissue encountered by the leading edge of the advancing bullet leads to the formation of the wound track [4,7,13,18,41,43]. This combination has been called prompt damage as it occurs immediately in the direct vicinity of the projectile [44] representing the predominant mechanism of tissue injury in low-energy GSW.

The residual wound track which remains after the passage of the projectile is commonly referred to as the permanent cavity [2,4,7], although the term “cavity” should probably be reserved for the temporary cavitation phenomenon. The more comprehensive terms “permanent wound channel” [16] and “permanent wound tract” [7] have been used indicating the central defect (permanent “cavity”) together with any surrounding area of irreversible tissue damage [7], the latter resulting from the crushing effect of the overpressure mechanism and the potential disruption from cavitation. Irreversibly damaged tissue subsequently undergoes necrosis and slough contributing to the permanent “cavity” formation [4]. It is surrounded by an outer hemorrhagic area termed the extra vasation zone, which is characterized by interstitial bleeding but absence of macroscopically evident tissue destruction [4,16].

##### 4.2. Cavitation

As the projectile is moving forward, tissue detaches from the projectile–tissue interface, as a result of boundary flow separation, and is subsequently accelerated radially, the same way as a speedboat displaces water [30], while the momentum imparted to tissue particles results in the formation of a vacuum [3,16,41,42]. The underlying process called cavitation becomes clinically important at impact velocities exceeding 600 m/s [45], thus considered the most important feature in wound ballistics of high-velocity projectiles [15,16,25]. Cavitation is an extremely dynamic

phenomenon, which exceeds the capacity of the soft tissue to yield to the pressure changes created by the penetrating missile. Because of this inertia, tissue displacement lags behind the bullet, and the resultant deformity, known as the temporary cavity, reaches maximum size within several milliseconds after its passage [3,4,34,45]. Subsequently, the energy stored in any displaced tissue with enough elasticity cause the cavity walls to collapse, with a few cycles of expansion and contraction (“pulsations”) following in a waning fashion, until tissue settles in the form of the residual wound track. This short-lived character of the cavity is emphasized by the name “temporary” [16,40].



**Figure 4.** Idealized drawing of temporary cavity formation (dotted line) by military rifle bullet. The cavity expands in spindle-shaped fashion as the bullet yaws and tumbles, after the initial narrow channel. The residual wound track (permanent “cavity”) appears in solid line. Arrow indicates direction of bullet movement.

The magnitude of the cavitation phenomenon is related to the rate of energy deposition. The study of military rifle bullets in synthetic materials simulating muscle tissue suggests that as long as the bullet moves within the target without significant yawing, thus sustaining little retardation, the wound track remains “narrow”, a little wider than the bullet diameter [16]. Although this so-called narrow channel also involves a minor temporary cavitation effect [46], an expanding spindle-shaped cavity becomes evident as the yaw angle increases irreversibly, and becomes maximum in cross section when the bullet yaws at 90 degrees causing wide separation of tissue “flow” (Figure 4), consistent with a dramatic increase in energy transfer. FMJ handgun bullets may also yaw within tissue but do not elicit significant cavitation because these bullets are shorter than rifle bullets and their presented area increases only negligibly with yawing [16]. On the other hand, deforming handgun bullets depending on their velocity give rise to relatively large temporary cavities [9,47].

The damage produced by cavitation results from

stretching due to tensile strain, but also from compression of the surrounding tissue as well as shearing of fascial interfaces within it [3,40]. Although controversy still exists regarding the relative importance of these effects and the extent of the resultant necrosis in muscle tissue [4,7,34,35,48], cavitation is clearly devastating in susceptible organs such as the brain and liver [4,7]. In the extravasation zone tissue injury results from tearing of the elements most sensitive to tensile forces, namely the capillaries [4,16], and there is a direct relationship between the size of the temporary cavity and the width of the extravasation zone [16]. Moreover, the vacuum created during the expansion of the cavity causes suction of foreign material and debris into the wound [49], on top of the contamination already present from the bullet surface, which is not sterilized from heating as commonly believed [13,26]. The clinical picture of a wound channel which is bordered by contused and potentially necrotic tissue inoculated with bacteria represents the hallmark of high-energy gunshot injury [25,37,50]. The external appearance of such a wound may be deceptive with respect to the damage produced deep in the tissues. As previously mentioned, however, a military rifle bullet may induce a low-energy wound in case of a perforating wound track no longer than the narrow channel simulated for that type of bullet [46].

#### 4.3. Bone injuries

Ballistic bone injury is a more complex process than penetration of soft tissue [51]. In general, bone tissue causes marked retardation of the penetrating bullet [4,15,18], as expected by its greater density compared to soft tissue and its related mechanical properties, particularly its hardness [52,53], which may also cause the bullet to deform or break up [18,54].

Drill-hole defects, which are characteristic of low-energy ballistic penetration, are more common in the metaphyseal region of long bones because of the greater proportion of cancellous bone and the associated energy absorptive capacity which limits the extension of fracture lines [55,56]. High-energy ballistic impacts typically produce comminuted fractures [56,57] from the explosive effects of cavitation associated with the fluid properties of bone marrow [3,16,52]. Bone comminution is not uncommon with



handgun injuries [56,57] and may resemble radiologically a high-energy fracture, but the latter involves a much more severely damaged zone of soft tissue [58].

#### 4.4. Head injuries

The impact energy of the projectile, the angle of interaction with the bony surface, and the underlying bone thickness are important determinants of skull penetration [12,20]. Tangential bullet wounds of the skull are known as “gutter” wounds; they may involve only the outer table or the full thickness of the bone [30]. Bullets capable of entering the skull usually have enough remaining energy to reach the opposite side either perforating through it or becoming arrested without exiting [20]. This is commonly associated with early destabilization or deformation of the penetrating projectile, and also creation of bone fragments which may act as secondary missiles [40]. FMJ bullets are more likely to perforate the skull and this likelihood increases with the caliber. However, the size of the permanent wound channel in the brain bears no relationship to the caliber or muzzle energy of the bullet [12].

The head represents a particular structure from a wound ballistics point of view [59]. The pressure buildup by the expansion of the temporary cavity within it can only be relieved by bursting of the skull [30], as demonstrated with high-velocity projectiles penetrating either intact animal heads [3] or human skulls filled with gelatin to simulate the brain substance [50]. By contrast, in the absence of a non-compressible content with fluid properties to transmit the pressure to the braincase, the only defects produced by the same types of projectiles in the empty skull were neat entrance and exit holes with no shattering of bone [3,50]. The same mechanism of hydraulic pressure is responsible for indirect fractures of the thin orbital plates almost invariably produced by handgun bullets penetrating the head [16,30,40].

Brain tissue has little tolerance to sudden increases in pressure as it is firmly enclosed within an unyielding case, and this appears to enhance the consequences of cavitation produced even by low-velocity projectiles. Parenchymal changes extending for some distance around the permanent wound channel have been observed with fatal handgun injuries, most likely attributed to temporary cavitation [60].

Large temporary cavities from FMJ handgun bullets have been demonstrated in experimental models of ballistic brain injury [61]. Moreover, autopsy findings [62] and previous animal studies suggest that the “ordinary” pressure waves [63] associated with cavitation, rather than the early ballistic pressure wave (“shock wave”), may be important causes in the pathogenesis of respiratory arrest following low-velocity ballistic trauma of the head, in the absence of significant mass effect or direct involvement of brainstem structures by the missile track.

## 5. Conclusion

The damage produced by penetrating bullets depends on the amount of their impact energy that is delivered to the tissues, the rate at which this occurs, and the local response of the tissue zone subjected to cavitation effects from high-energy injuries. Although the complex interactions of the projectile with the various tissues result in a wide range of ballistic injury patterns, awareness of the specific mechanisms that cause increased tissue destruction, namely bullet tumbling and deformation, will assist recognition of the less common injuries involving high energy transfer, which are also associated with a higher risk of infectious complications.

## Conflict of interest statement

We declare that we have no conflict of interest

## References

- [1] Callender GR, French RW. Wound ballistics: studies in the mechanism of wound production by rifle bullets. *Mil Surg* 1935;77(4):177–201.
- [2] French RW, Callender GR. Ballistic characteristics of wounding agents. In: Beyer JC.(ed.) *Wound ballistics*. Washington, D.C.: Office of the Surgeon General, *Department of the Army*; 1962, p. 91–141.
- [3] Harvey EN, McMillen JH, Butler EG, Puckett WO. Mechanism

- of wounding. In: Beyer JC. (ed.) Wound ballistics. Washington, D.C.: Office of the Surgeon General, *Department of the Army*;1962,p.143–235.
- [4] Bellamy RF, Zajtcuk R. Conventional warfare:ballistic, blast, and burn injuries. Washington, DC: Walter Reed Army Medical Center, *Office of the Surgeon General*; 1991, p.107–162.
- [5] Wang ZG, Jiang J. Thinking on wound ballistics research. *Int Rev Armed Forces Med Serv* 2000;**73**(1): 3–6.
- [6] Payne LD. Military wound ballistics: history and renaissance. *J R Army Med Corps* 2013; **159**(4): 256–258.
- [7] Breeze J, Sedman AJ, James GR, Newbery TW, Hepper AE. Determining the wounding effects of ballistic projectiles to inform future injury models: a systematic review. *J R Army Med Corps* 2014;**160**(4):273–278.
- [8] Haywood IR. Missile injury. *Probl Gen Surg* 1989;**6**(2):330–347.
- [9] Yoganandan N, Pintar FA, Kumaresan S, Maiman DJ, Hargarten SW. Dynamic analysis of penetrating trauma. *J Trauma* 1997;**42**(2):266–272.
- [10] Zhang J, Yoganandan N, Pintar FA, Genarelli TA. Temporary cavity and pressure distribution in a brain simulant following ballistic penetration. *J Neurotrauma* 2005; **22**(11): 1335–1347.
- [11] Kneubuehl BP, Coupland RM, Rothschild MA, Thali MJ. Wundballistik: Grundlagen und Anwendungen.3rd ed.Heidelberg:Springer; 2008.
- [12] DiMaio VJ.Gunshot wounds: practical aspects of firearms, ballistics, and forensic techniques. 2nd ed. Boca Raton, FL: CRC Press; 1999.
- [13] Hollerman JJ, Fackler ML, Coldwell DM, Ben-Menachem Y. Gunshot wounds: 1. Bullets, ballistics, and mechanisms of injury. *AJR Am J Roentgenol*1990;**155**(4): 685–690.
- [14] Coupland RM, Kneubuehl BP, Rowley DI, Bowyer GW. Wound ballistics, surgery and the law of war. *Trauma* 2000; **2**(1): 1–10.
- [15] Griffiths D, Clasper J. Bullet and blast injuries: (iii) Military limb injuries/ballistic fractures. *Curr Orthop* 2006; **20**(5): 346–353.
- [16] Kneubuehl BP. General wound ballistics.In: Kneubuehl BP, Coupland RM, Rothschild MA, Thali MJ. (eds.) Wound ballistics: basics and applications(Translation of the revised 3rd German edition). Berlin: Springer;2011,p.87–161.
- [17] Fackler ML, Malinowski JA. The wound profile: a visual method for quantifying gunshot wound components. *J Trauma* 1985; **25**(6): 522–529.
- [18] Janzon B, Hull JB, Ryan JM. Projectile–material interactions: soft tissue and bone. In: Cooper GJ, Dudley HA, Gann DS, Little RA, Maynard RL. (eds.) Scientific foundations of trauma. Oxford: Butterworth–Heinemann;1997,p.37–52.
- [19] Moss GM, Leeming DW, Farrar CL. Military ballistics: a basic manual. London: Brassey's; 1995,p.9–22.
- [20] Jandial R, Reichwage B, Levy M, Duenas V, Sturdivan L. Ballistics for the neurosurgeon. *Neurosurgery* 2008; **62**(2): 472–480.
- [21] Gugala Z, Lindsey RW. Classification of gunshot injuries in civilians. *Clin Orthop Relat Res* 2003; **408**: 65–81.
- [22] DeMuth WE, Jr. Bullet velocity as applied to military rifle wounding capacity. *J Trauma* 1969; **9**(1): 27–38.
- [23] Appendix A. Tables. In: Kneubuehl BP, Coupland RM, Rothschild MA, Thali MJ. (eds.) Wound ballistics: basics and applications(Translation of the revised 3rd German edition). Berlin: Springer; 2011, p. 345–404.
- [24] Ordog GJ, Balasubramaniam S, Wasserberger J, Kram H, Bishop M, Shoemaker W. Extremity gunshot wounds: Part one – identification and treatment of patients at high risk of vascular injury. *J Trauma* 1994; **36**(3): 358–368.
- [25] Gyftokostas D, Komborozos B. The mechanism of firearm injury [article in Greek]. *Iatrika Chronika* 1986; **9**(1): 17–26.
- [26] Hopkinson DA, Marshall TK. Firearm injuries. *Br J Surg* 1967; **54**(5): 344–353.
- [27] Peters CE, Seaborn CL, Crowder HL. Wound ballistics of unstable projectiles. Part I: projectile yaw growth and retardation. *J Trauma* 1996; **40**(Suppl 3): S10–S15.
- [28] Kneubuehl BP. Basics. In: Kneubuehl BP, Coupland RM, Rothschild MA, Thali MJ. (eds.) Wound ballistics: basics and applications(Translation of the revised 3rd German edition). Berlin: Springer; 2011, p. 3–85.
- [29] Janzon B. Projectile–material interactions: simulants. In: Cooper GJ, Dudley HA, Gann DS, Little RA, Maynard RL. (eds.) Scientific foundations of trauma. Oxford: Butterworth–Heinemann; 1997, p. 26–36.
- [30] DiMaio VJM, Dana SE. Handbook of forensic pathology. 2nd ed. Boca Raton, FL: CRC Press; 2006, p. 121–154.
- [31] Fackler ML. Civilian gunshot wounds and ballistics: dispelling the myths. *Emerg Med Clin North Am* 1998; **16**(1): 17–28.
- [32] Kneubuehl BP. Wound ballistics of bullets and fragments. In: Kneubuehl BP, Coupland RM, Rothschild MA, Thali MJ. (eds.) Wound ballistics: basics and applications(Translation of the revised 3rd German edition). Berlin: Springer; 2011, p. 163–252.
- [33] Santucci RA, Chang YJ. Ballistics for physicians: myths about wound ballistics and gunshot injuries. *J Urol* 2004; **171**(4):

- 1408–1414.
- [34] Janzon B, Seeman T. Muscle devitalization in high-energy missile wounds, and its dependence on energy transfer. *J Trauma* 1985; **25**(2): 138–144.
- [35] Dziemian AJ, Mendelson JA, Lindsey D. Comparison of the wounding characteristics of some commonly encountered bullets. *J Trauma* 1961; **1**: 341–353.
- [36] Bono CM, Heary RF. Gunshot wounds to the spine. *Spine J* 2004; **4**(2): 230–240.
- [37] Bellamy RF. The medical effects of conventional weapons. *World J Surg* 1992; **16**(5): 888–892.
- [38] DeMuth WE, Jr, Smith JM. High-velocity bullet wounds of muscle and bone: the basis of rational early treatment. *J Trauma* 1966; **6**(6): 744–755.
- [39] Pollak S, Saukko PJ. Gunshot wounds. In: Jamieson A, Moenssens A. (eds.) Wiley encyclopedia of forensic science. West Sussex: Wiley; 2009, p. 1380–1401.
- [40] Karger B. Forensic ballistics. In: Tsokos M. (ed.) Forensic pathology reviews. Volume 5. Totowa, NJ: Humana Press; 2008, p. 139–172.
- [41] Davidson PL, Taylor MC, Wilson SJ, Walsh KAJ, Kieser JA. Physical components of soft-tissue ballistic wounding and their involvement in the generation of blood backspatter. *J Forensic Sci* 2012; **57**(5): 1339–1342.
- [42] Felsmann MZ, Szarek J, Felsmann M, Babinska I. Factors affecting temporary cavity generation during gunshot wound formation in animals – new aspects in the light of flow mechanics: a review. *Veterinari Medicina* 2012; **57**(11): 569–574.
- [43] Dougherty PJ, Fackler ML. Wound ballistics: the pathophysiology of wounding. In: Dougherty PJ. (ed.) Gunshot wounds. Rosemont, IL: AAOS; 2011, p. 11–18.
- [44] Peters CE, Seaborn CL. Wound ballistics of unstable projectiles. Part II: temporary cavity formation and tissue damage. *J Trauma* 1996; **40**(Suppl 3): S16–S21.
- [45] Scott R. Pathology of injuries caused by high-velocity missiles. *Clin Lab Med* 1983; **3**(2): 273–294.
- [46] Giannou C, Baldan M. War surgery: working with limited resources in armed conflict and other situations of violence. Volume 1. Geneva: International Committee of the Red Cross; 2009, p. 53–78.
- [47] Bolliger SA, Thali MJ, Bolliger MJ, Kneubuehl BP. Gunshot energy transfer profile in ballistic gelatin, determined with computed tomography using the total crack length method. *Int J Legal Med* 2010; **124**(6): 613–616.
- [48] Fackler ML, Breteau JP, Courbil LJ, Taxit R, Glas J, Flevet JP. Open wound drainage versus wound excision in treating the modern assault rifle wound. *Surgery* 1989; **105**(5): 576–584.
- [49] Große Perdekamp M, Kneubuehl BP, Serr A, Vennemann B, Pollak S. Gunshot-related transport of micro-organisms from the skin of the entrance region into the bullet path. *Int J Legal Med* 2006; **120**(5): 257–264.
- [50] Owen-Smith MS. High velocity missile wounds. London: Edward Arnold; 1981, p. 15–42.
- [51] Molde Å, Gray R. Letter to the editor. *Injury* 1995; **26**(2): 131.
- [52] Huelke DF, Buege LJ, Harger JH. Bone fractures produced by high velocity impacts. *Am J Anat* 1967; **120**(1): 123–131.
- [53] Bartlett CS. Clinical update: gunshot wound ballistics. *Clin Orthop Relat Res* 2003; **408**: 28–57.
- [54] Stefanopoulos PK, Filippakis K, Soupiou OT, Pazarakiotis VC. Wound ballistics of firearm-related injuries—Part 1: missile characteristics and mechanisms of soft tissue wounding. *Int J Oral Maxillofac Surg* 2014; **43**(12): 1445–1458.
- [55] Huelke DF, Harger JH, Buege LJ, Dingman HG, Harger DR. An experimental study in bio-ballistics: femoral fractures produced by projectiles. *J Biomech* 1968; **1**(2): 97–105.
- [56] Rose SC, Fujisaki CK, Moore EE. Incomplete fractures associated with penetrating trauma: etiology, appearance, and natural history. *J Trauma* 1988; **28**(1): 106–109.
- [57] Leffers D, Chandler RW. Tibial fractures associated with civilian gunshot injuries. *J Trauma* 1985; **25**(11): 1059–1064.
- [58] Bowyer GW, Rossiter ND. Management of gunshot wounds of the limbs. *J Bone Joint Surg Br* 1997; **79**(6): 1031–1036.
- [59] Rothschild MA. Wound ballistics and forensic medicine. In: Kneubuehl BP, Coupland RM, Rothschild MA, Thali MJ. (eds.) Wound ballistics: basics and applications. Translation of the revised 3rd German edition. Berlin: Springer; 2011, p. 252–303.
- [60] Oehmichen M, Meissner C, König HG. Brain injury after gunshot wounding: morphometric analysis of cell destruction caused by temporary cavitation. *J Neurotrauma* 2000; **17**(2): 155–162.
- [61] Zhang J, Yoganandan N, Pintar FA, Guan Y, Gennarelli TA. Experimental model for civilian ballistic brain injury biomechanics quantification. *J Biomech* 2007; **40**(10): 2341–2346.
- [62] Oehmichen M, Meissner C, König HG, Gehl HB. Gunshot injuries to the head and brain caused by low-velocity handguns and rifles: a review. *Forensic Sci Int* 2004; **146**(2–3): 111–120.
- [63] Carey ME. Experimental missile wounding of the brain. *Neurosurg Clin North Am* 1995; **6**(4): 629–642.