



Contents lists available at ScienceDirect

Journal of Clinical Gerontology & Geriatrics

journal homepage: www.e-jcgg.com

Case report

A case of giant hiatal hernia in an elderly patient: When stomach, duodenum, colon, and pancreas slide into thorax

Supakanya Wongrakpanich, MD ^{a,*}, Hilit Hassidim, MD ^a, Wikrom Chaiwatcharayut, MD ^a, Wuttiporn Manatsathit, MD ^b^a Department of Medicine, Einstein Medical Center, Philadelphia, PA, USA^b Division of Hepatology, Einstein Medical Center, Philadelphia, PA, USA

ARTICLE INFO

Article history:

Received 24 March 2015

Received in revised form

29 May 2015

Accepted 9 June 2015

Available online 9 July 2015

Keywords:

diaphragmatic hernia

giant hiatal hernia

shortness of breath

ABSTRACT

Although the incidences of hiatal hernias increase with age, respiratory symptoms caused by hiatal hernias remain extremely uncommon. We report a case of an 88-year-old female who presented with 2-months of progressive shortness of breath. Upon arrival, the patient was found to be hypoxic with oxygen saturation 90% on room air. Physical examination also showed decreased breath sounds on left basal lungs and bilateral crackles at basal lungs. Plain radiograph demonstrated an increased opacity at the left lower lobe. Subsequent computerized tomography of the chest revealed a giant hiatal hernia, containing stomach, proximal duodenum, colon, and pancreas. This case highlights the giant hiatal hernia as an unusual cause of shortness of breath, especially in elderly patients.

Copyright © 2015, Asia Pacific League of Clinical Gerontology & Geriatrics. Published by Elsevier Taiwan LLC. This is an open access article under the CC BY-NC-ND license (<http://creativecommons.org/licenses/by-nc-nd/4.0/>).

1. Introduction

A giant hiatal hernia is defined by a hernia that consists of >30% of the stomach herniating through the diaphragmatic hiatus into the thorax.¹ Generally, patients with giant hiatal hernias often present with gastrointestinal symptoms such as dysphagia and heart burn, whereas respiratory symptoms caused by hiatal hernias are extremely uncommon.^{1,2} Hence, we report a case of a patient with a giant hiatal hernia who presented with progressive shortness of breath and hypoxia.

2. Case report

An 88-year-old female presented to the emergency department with a 2-month history of worsening shortness of breath. The patient also had an extensive past medical history significant for hypertension, transient ischemic attack, moderate aortic stenosis, congestive heart failure, and coronary artery disease. At baseline, she was able to walk two blocks before experiencing shortness of breath. However, in the past 2 months, her functional status had

declined to the point that she became dyspneic with minimal activity. She denied angina, palpitation, orthopnea, paroxysmal nocturnal dyspnea, or lower extremities edema.

On arrival, she was hemodynamically stable, but hypoxic with oxygen saturation of 90% at room air, which improved to 95% with 3 L/min of oxygen. On pulmonary auscultation, breath sounds were decreased on the left basal lung with minimal bibasilar crackles. Her laboratory results including complete blood count, basic metabolic panel, and thyroid stimulating hormone were within normal reference values. Brain natriuretic peptide was 474.9 pg/mL. Arterial blood gas analysis on room air demonstrated hypoxia with pH 7.46, partial pressure of carbon dioxide 43 mmHg, and partial pressure of oxygen 48 mmHg. The 12-lead electrocardiogram showed normal sinus rhythm (61 bp/min). Chest radiograph revealed an increased opacity at the left lower lobe and lingular lobe (Figure 1). Noncontrast computerized tomography (CT) of the thorax was subsequently performed which demonstrated a large hiatal hernia containing the stomach, proximal duodenum, colon, and pancreas (Figure 2). The configuration of the stomach within the hernia suggested an organoaxial volvulus. Due to the significant hypoxia, a CT angiogram of the chest was also performed to rule out a pulmonary embolism which revealed no evidence of pulmonary embolism; however, it demonstrated mild bibasilar predominant peripheral reticulation compatible with interstitial lung disease.

* Corresponding author. 5501 Old York Road, Philadelphia, PA 19141, USA.
E-mail address: WongrakS@einstein.edu (S. Wongrakpanich).

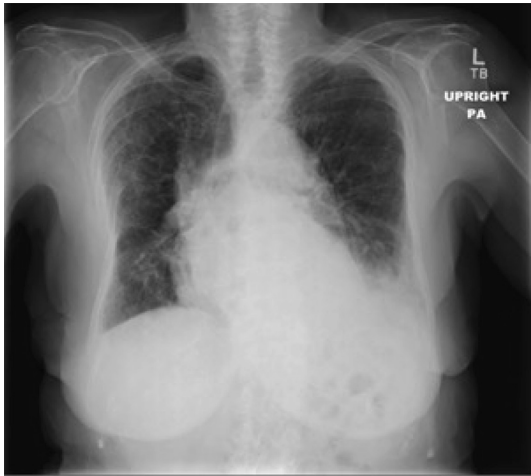

Figure 1. Plain radiography in the upright position showed a slightly enlarged heart size with a parenchymal opacity visualized in the left lower lobe, which partially silhouetted the left hemidiaphragm and obscured the cardiac apex.

Transthoracic echocardiogram 5 weeks prior to admission revealed mild aortic stenosis with the aortic valve peak velocity 2.2 m/s and the aortic valve mean gradient of 11 mmHg, mildly dilated left atrium, normal left ventricular systolic function with ejection fraction of >55%, Grade I diastolic dysfunction, and mild to moderate increase of the estimated systolic pulmonary artery pressure (50–55 mmHg). A pulmonary function test, which was done during the same period of time, showed forced expiratory volume in 1 second (FEV1)/forced vital capacity (FVC) 79% of predicted, FVC 59% and FEV1 63% of predicted, FVC 63% of predicted, total lung capacity 53% of predicted, suggestive of restrictive pattern.

Based on these findings, the patient's shortness of breath and hypoxia were multifactorial composites of conditions: large hiatal hernia, mild to moderate aortic stenosis, congestive heart failure, and interstitial lung disease. Surgery, cardiology, and pulmonary were consulted for surgical repair and pre-operative evaluation of the hernia. However, the patient refused surgery because of the

high surgical risk due to advance age and multiple comorbidities. The patient was discharged with frequent follow-ups at the cardiology and pulmonary clinics.

3. Discussion

Giant hiatal hernia is responsible for 0.3–15% of all hiatal hernias.¹ Generally, the common presentations of giant hiatal hernia include pain, heartburn, vomiting, dysphagia, and anemia.¹ Respiratory symptoms are considered a very uncommon clinical presentation.

In 2011, Alviar et al³ reported a case of bilateral Bochdalek hernias presenting with respiratory failure that required noninvasive ventilator support. Later, in 2013, Torres et al⁴ illustrated a case of an 82-year-old female who presented with dyspnea and oxygen desaturation and was found to have hiatal herniation of the stomach and pancreas. In 2014, Chou and Su⁵ reported a case of an 86-year-old female who also presented with shortness of breath caused by giant hiatal hernia followed by Takotsubo cardiomyopathy. Details of these reports are compared and displayed in Table 1. Interestingly, all reported cases were female over the age of 80 years with multiple comorbidities. None of them received surgical intervention for definite management.

In addition to shortness of breath as a rare presentation, hiatal hernia can also present with angina pectoris,⁴ arrhythmias, recurrent heart failure,³ and exercise impairment.⁶

There is an increasing incidence of hiatal hernia with age, from approximately <10% under the age of 30 years to >60% above the age of 70 years.⁷ Interestingly, most of the reported cases of hiatal hernia with atypical presentation were all elderly patients, especially over the age of 80 years.

Surgical intervention is considered the goal standard and definitive treatment for hiatal hernia. After the repair, spirometry has been shown to demonstrate an improvement of FEV1, FVC, and total lung capacity, resulting in an improvement in exercise capacity.^{6,8}

In summary, a giant hiatal hernia can be considered as an uncommon cause of shortness of breath, especially in geriatric patients. Surgical intervention is the goal standard treatment for hiatal hernia.

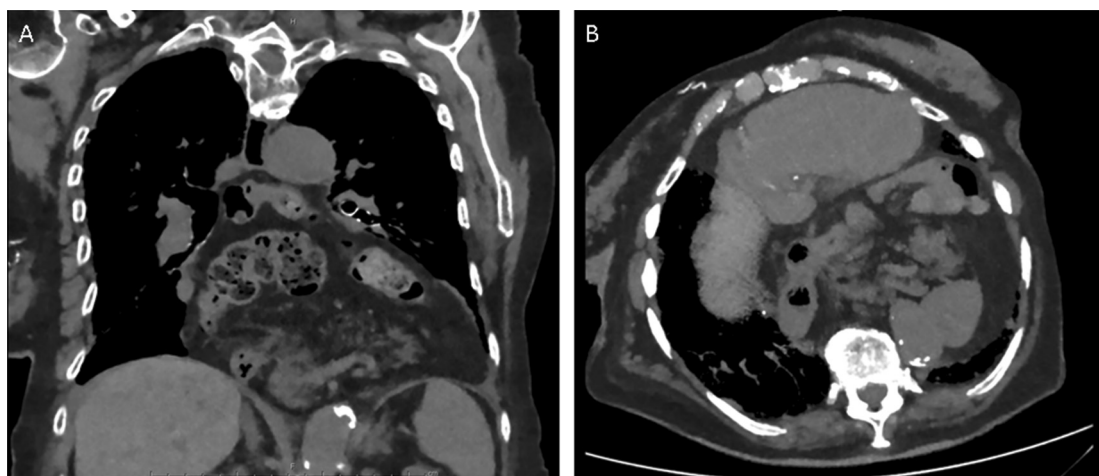


Figure 2. Computed tomography. (A) Thorax coronal view; and (B) axial view demonstrating a large hiatal hernia containing the entire stomach, proximal duodenum, a portion of the transverse and descending colon, and the pancreas.

Table 1
Previously published cases of giant hiatal hernia presented with shortness of breath.

	Case report 1	Case report 2	Case report 3
Author	Alviar et al ³	Torres et al ⁴	Chou & Su ⁵
Y of Publication	2011	2013	2014
Age at diagnosis (y)	88	82	86
Gender	Female	Female	Female
Comorbidities	Kyphoscoliosis, chronic kidney disease, chronic obstructive pulmonary disease, & diastolic heart failure	Pulmonary hypertension, essential hypertension, chronic kidney disease, kyphoscoliosis, & gastro-esophageal reflux disease	Old cerebral vascular disease, chronic obstructive pulmonary disease
Duration of shortness of breath	3 d	1 wk	1 d
Presenting symptoms	Progressive shortness of breath	Dyspnea on exertion	Shortness of breath
Associated symptoms	Poor appetite Generalized weakness	None	N/A ^a
Chest radiograph	Opacification of the left lung with prominent interstitial vessels & bilateral pleural effusions	N/A ^a	Cardiomegaly & mediastinal widening
Computed tomography of the chest	Features suggestive of congestive cardiac failure, with large bilateral Bochdalek hernias	Hiatal herniation without any structural or inflammatory lung diseases	Hiatal hernia
Content of the hernia	Fat & small-bowel loops	The stomach & pancreatic body & tail, & adipose content	Stomach & esophagus
Size of the hernia	28 cm	12 cm	N/A ^a
Management & outcome	The patient refused surgery & pulmonary rehabilitation program	The patient refused surgery. However, the patient was still followed up at the clinic after 11 mo	Initially treated as an acute exacerbation of chronic obstructive pulmonary disease, however, clinical course was complicated by Takotsubo cardiomyopathy. The patient was discharged 1 mo later with tracheostomy & feeding jejunostomy

^a N/A = not applicable.

Conflicts of interest

The authors declare no conflict of interests.

References

- Mitiek MO, Andrade RS. Giant hiatal hernia. *Ann Thorac Surg* 2010;**89**:S2168–73.
- Akdemir I, Davutoglu V, Aktaran S. Giant hiatal hernia presenting with stable angina pectoris and syncope—a case report. *Angiology* 2001;**52**:863–5.
- Alviar CL, Cordova JP, Korniyenko A, Javed F, Tsukayama M, Narayanswami G. Bilateral Bochdalek hernias presenting as respiratory failure in an elderly patient. *Respir Care* 2011;**56**:691–4.
- Torres D, Parrinello G, Cardillo M, Bellanca M, Licata G. Hiatal herniation of the stomach and pancreas in a patient with oxygen desaturations. *Libyan J Med* 2013;**8**:23288.
- Chou CJ, Su HM. An unusual cause of dyspnea: giant hiatal hernia followed by Takotsubo cardiomyopathy. *Kaohsiung J Med Sci* 2014;**30**:484–5.
- Naoom C, Falk GL, Ng AC, Lu T, Ridley L, Ing AJ, et al. Left atrial compression and the mechanism of exercise impairment in patients with a large hiatal hernia. *J Am Coll Cardiol* 2011;**58**:1624–34.
- Winans CS. Hiatus hernia. Its significance in the elderly patient. *Geriatrics* 1972;**27**:69–78.
- Khanna A, Finch G. Paraesophageal herniation: a review. *Surgeon* 2011;**9**:104–11.