

Available online at
ScienceDirect
www.sciencedirect.comElsevier Masson France
EM|consulte
www.em-consulte.com/en

Technical note

External fixation of the thalamic portion of a fractured calcaneus: A new surgical technique

T. Bégué^{a,*}, N. Mebtouche^a, J.-C. Auregan^a, G. Saintyves^a, S. Levante^a, P. Cottin^a,
A.-C. Masquelet^b^a Orthopaedic and Trauma Surgery Department, hôpital Antoine-Béclère, université Paris-Sud, 157, rue de la Porte-de-Trivaux, 92140 Clamart, France^b Service de chirurgie orthopédique et traumatologique, hôpital Avicenne, Bobigny, France

ARTICLE INFO

Article history:

Accepted 10 January 2014

Keywords:

Calcaneus
Fracture
External fixator
Bone substitute
Minimally-invasive

ABSTRACT

The optimal treatment for intra-articular calcaneus fractures remains controversial, despite internal fixation techniques providing good results. The major point of contention is the need to reconstruct the overall morphology *versus* to restore the anatomy of the subtalar joint perfectly. We will describe a two-stage technique for treating intra-articular calcaneus fractures in which the primary fracture line goes through the thalamic fragment. The first procedure focuses on the overall morphology by restoring the height and length with osteotaxis being accomplished with a medial external fixator. The second procedure consists of internal fixation through a minimally invasive lateral approach to restore the anatomy of the articular facets. Any defects are filled with injectable bone substitute. This novel technique is compared to the complication rates and radiology and anatomy outcomes in published studies. This two-stage surgical technique reduces the length of hospital stays and the number of complications.

© 2014 Elsevier Masson SAS. All rights reserved.

1. Introduction

When treating intra-articular calcaneal fractures, the intra-articular surface of the thalamic fragment and the bone morphology must be restored, preferably using dedicated internal fixation [1–3]. The congruence of the subtalar joint must be restored [2], as does the overall shape of the calcaneus to ensure good outcomes [4]. These dual treatment objectives are difficult to achieve because of surgery-related complications [5–8]. The spatial and morphological reduction of calcaneus length, height and width can be performed immediately by applying the principles of ligamentotaxis and osteotaxis [5,9]. The shape of the posterior talar articular facet of the calcaneus can be restored in a later, minimally-invasive procedure.

We have developed a two-stage surgical technique to treat intra-articular calcaneal fractures. In the first phase, the calcaneus is reduced in an emergency setting. In the second phase, secondary fixation of the posterior talar articular facet of the calcaneus is performed. This treatment concept is consistent with the damage control approach used when treating complex fractures in the arms and legs.

2. Surgical technique

The first surgical stage is performed on an emergency basis using ligamentotaxis and osteotaxis principles with a Hoffmann external fixation system (Stryker, Lyon, France). Two 4-mm diameter pins are inserted into the calcaneal tuberosity based on information from the preoperative CT scan (Fig. 1). These parallel pins are placed in the most posterior part of the tuberosity in a non-fractured area and are always located behind the depressed thalamic fragment. If the posterior part of this tuberosity is massively comminuted, the pins cannot be implanted reliably. They are inserted inside-out and perpendicular to the major longitudinal axis of the calcaneus, while making sure to avoid the inferior calcaneal nerve [10]. The plane is selected based on the separation line between the calcaneal tuberosity and thalamic fragment. It must allow for complete visualisation of the subtalar joint in lateral X-rays after the fixator rods and clamps have been inserted. The rear foot varus can be corrected and the calcaneal height and length restored by moving the pin-jaw unit. Two other 4-mm pins are inserted into the anteromedial side of the tibia along the long axis of the bone. The last two 3-mm pins are implanted in an anteromedial position in the distal metaphysis region of the first metatarsal along the major axis of the bone. The jaws are joined together to create a triangular construct on the medial side of the foot (Fig. 2). Osteotaxis principles are applied to restore the height, length and valgus of

* Corresponding author.

E-mail address: thierry.begue@abc.aphp.fr (T. Bégué).

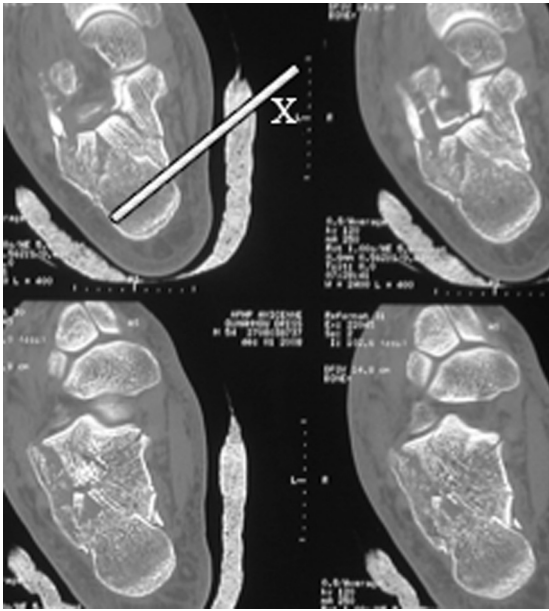


Fig. 1. Immediate pre-operative CT scan with fracture classification; this case is a Sanders type III AC fracture. (X): projection of the position of the fixator pins to allow for distraction without interfering with the secondary procedure at the subtalar joint.

the calcaneus, which are verified by fluoroscopy. The surgeon must be careful not to over-correct into valgus. This surgical procedure must be performed on an emergency basis, while the fragments can still be moved. The sole goal of this surgical phase is to move the

entirety of the calcaneus around the thalamic fragment. Intramuscular pressures are systematically measured with a suitable device (CompassTM, Eaubonne, France).

X-rays (Fig. 3) and a new CT scan are performed to determine if another surgery will be needed to raise and fix the thalamic fragment. The Sanders classification is used for this purpose [11]. If an articular step-off remains, a second surgical procedure through a lateral approach is indicated. The second stage can be performed fairly soon after the first one (2–3 days) because unfolding the soft tissues and restoring the overall morphology of the calcaneus through osteotaxis allow the oedema to resolve.

By placing the external fixator completely on the medial side, the lateral side of the calcaneus is freed up for additional fixation. An extensive surgical approach is not necessary. Instead, a small lateral incision is made under fluoroscopy guidance that provides access to the thalamic region. With simple fractures (Sanders type II), anatomical percutaneous reduction is performed and any defects filled with injectable bone substitute (Fig. 4). With type III fractures, the subtalar joint is opened to reconstruct the thalamic surface of the calcaneus and stabilize the fragment with a transverse screw. With type IV fractures, this additional surgical procedure is only performed if the fragment is large enough to be fixed.

The external fixator is left in place for two months. Weight bearing is not allowed during this period and movement is only allowed in the toes. Once the fixator has been removed, gradual weight bearing is allowed over a 30-day period, along with active rehabilitation of joints in the feet.

Later on after bone union, if there is persistent pain because of post-traumatic degradation of the subtalar joint, fusion can be easily performed because the calcaneus is in the correct anatomical position. Subtalar joint fusion has been shown to provide good outcomes [2,8].

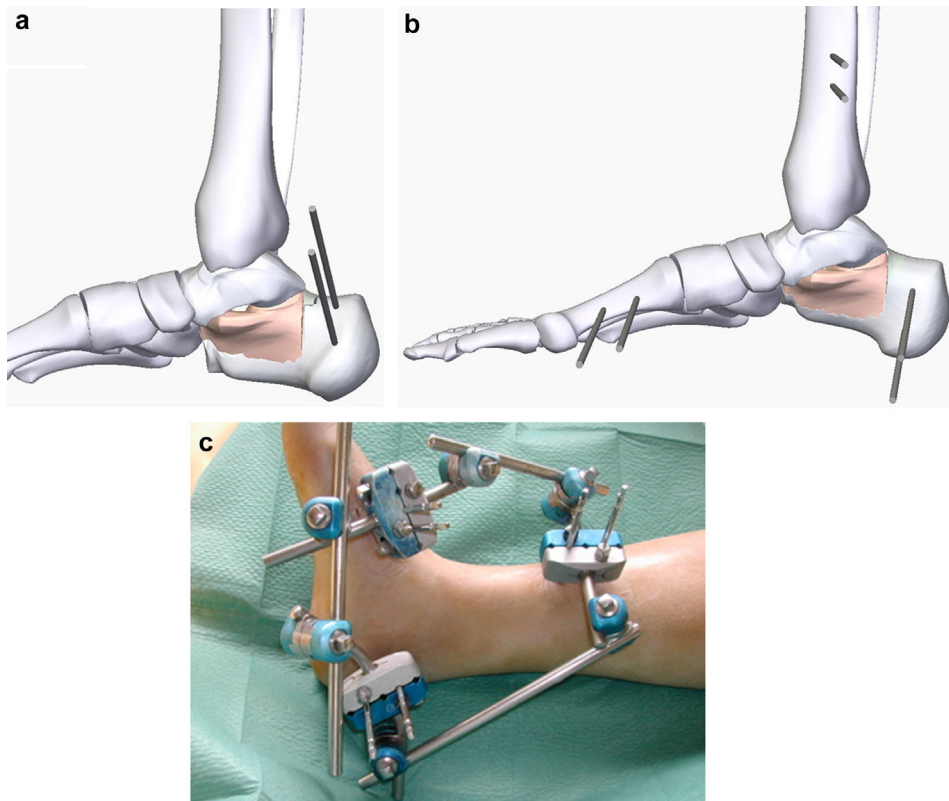


Fig. 2. a: position of the pins in the calcaneal tuberosity; b: medial triangular construct, position of pins; c: clinical appearance of fixator in medial position with triangular distraction.

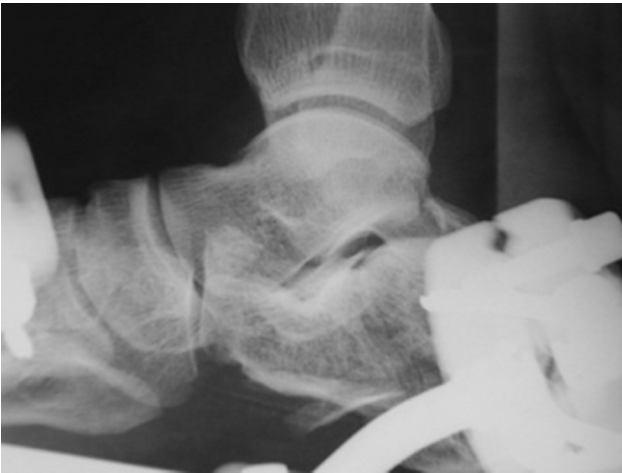

Fig. 3. Post-operative X-ray verification of the subtalar joint. The overall morphology of the calcaneus has been re-established.

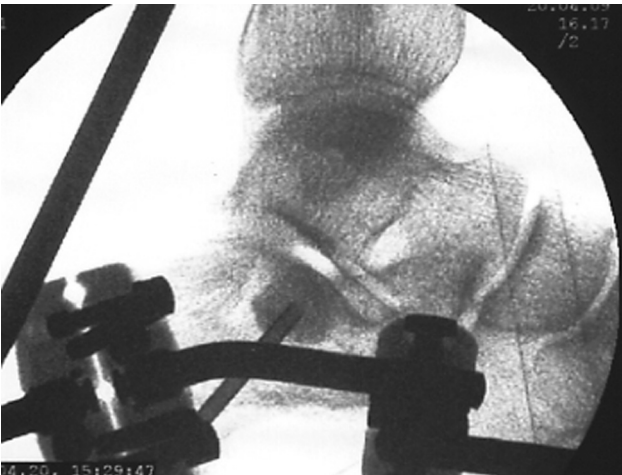

Fig. 4. Second surgical stage. Posterior talar articular facet of the calcaneus is restored with bone substitute injected to fill the bone defect after the fragment has been raised.

3. Patient series

Our pilot series consisted of 19 patients (20 fractures) who were operated on between 1997 and 2011. Included patients had a displaced intra-articular calcaneal fracture with loss of subtalar joint congruity apparent on X-rays or CT scan. Patients with extra-articular, non-displaced and tongue-type fractures were excluded. The average patient age was 41 years (range 22–71). The right calcaneus was fractured in 12 cases. All the fractures were classified using the Duparc (1 type II, 3 types III, 14 types IV, 2 types V) and Utheza (1 type A, 7 types B, 12 types C) classification systems. The 14 most recent cases were also classified using the Sanders system (1 type IIA, 5 types IIIAB, 3 types IIIBC, 5 types V).

The external fixator was able to restore calcaneal height in 13 cases, length in 17 cases and rear foot valgus in all cases. No fascia release was required for compartment syndrome. In 11 cases, additional fixation was performed four days later on average; there were six cases of screw fixation, one of calcaneal plate fixation and four pin applications. Bone substitute was needed in only two cases. There were three complications: two cases of sural nerve neuroma at the lateral scar used for the additional fixation and one case of tarsal tunnel syndrome due to the additional lateral screw being

too long. There were no pin infections and the external fixator was well tolerated in all cases for two months.

At the last follow-up (more than one year in all cases), the average AOFAS pain score was 27.5 (range 0–40) and the average overall AOFAS score was 74.6 (range 39–97). There were 15 good or excellent subjective outcomes, along with three average and two poor results. Subtalar fusion was performed in three cases later on.

4. Discussion

The use of osteotaxis principles to reduce displaced calcaneal fractures is a timely technical solution in the emergency room. It immediately restores the height and length of the bone, which is a predictor of good long-term results, independent of how well the subtalar joint anatomy is restored [4,5,12].

By restoring the overall anatomy of the rear foot, the soft tissues around the calcaneus are returned to their normal or nearly normal position. With the anatomy re-established, the foot's natural drainage pathways reduced the post-traumatic oedema in our patient series. Plantar compartment syndrome, which is one of the typical complications of calcaneus fractures [13], is avoided because the oedema is reduced. This highlights the need to measure tissue pressures in these fracture cases, which we did in every patient in our series. Since no skin complications were observed, additional fixation can be performed soon after, consistent with the damage control approach. The treatment is comprehensive, but adapted to the seriousness of the local condition.

Several authors have proposed using an external fixator system with pins that run completely through the bone [1,2,7,14–16]. Baumgaertel recommended a two-stage technique with insertion of a fixator on the medial side [14]. He insisted that the calcaneal pin be placed perpendicular to the major axis of the calcaneus in dense bone in the most posterior part of the calcaneal tuberosity. We used the same landmarks. However, he only used one medial tibocalcaneal construct, which we felt was insufficient to restore the calcaneal length without holding the forefoot. In addition, we felt it was important to restore the volume of the plantar compartment to quickly resolve the oedema after the initial emergency surgery. Besch believes that articulated external fixation should be used for calcaneal fractures associated with serious soft tissue injuries to avoid complications associated with internal fixation [15]. Walking-related outcomes were the same with external fixation in these indications as with internal fixation. Besch believes that use of external fixation is appropriate both in terms of functional outcomes and the risk of postoperative complications. However, he did not describe the time frame for the insertion of the external fixator, and as a consequence, we could not assess its ability to restore calcaneal morphology. There was also no information provided on the need for additional fixation. In our opinion, inserting the external fixator in the emergency room ensures that the morphology of the calcaneus is restored and helps the soft tissues return to normal more quickly, which in turn allows for additional minimally invasive fixation of the joint.

The most important aspect of this technique is the placement of the fixator pins in the calcaneus. The advantage of very posterior transfixation of the calcaneal tuberosity has been demonstrated by Besch in a biomechanics study [17]. The same study also included a clinical series with greater than 88% improvement in the Böhler angle. The construct is built around the virtual centre of rotation of the tibiotalar joint, which allows for immediate movement. Even if the author brings up the possibility of secondary plate fixation, the transfixing nature of the construct increases the risk of infection in our opinion. This risk is reduced in our technique because the construct only spans one side. We did not encounter any asymmetry during clinical calcaneus manipulations.

Our approach of using medial external fixation along with minimally invasive secondary fixation joins the conclusions made by Besch [12] while also reusing the treatment strategy described by Schepers [9]. Previously, either an articulating transfixing fixator [12] or one with gradual distraction [9] was used to provide temporary or permanent fixation in cases of skin-related complications or excessive risk factors, especially vascular ones. Schepers reduces the joint fragments during the same procedure as the external fixator is inserted. This may be the reason for the 15% infection rate in their study, due to secondary skin lesions. Talarico used a circular external fixator to restore the width, length and height of the calcaneus [18]. He recommended using three pre-assembled rings, but we felt this would be too difficult to carry out in the emergency room. Our medial, triangular construct was easy to work with and could be inserted quickly while the fractured calcaneus was still easy to mobilize. The transfixing nature of the pins recommended by Talarico makes his minimally-invasive lateral approach difficult to perform in addition to the ligamentotaxis induced by the circular external fixator. Nevertheless, 92% good and very good results were reported in cases with Sanders II and III fractures. McGarvey et al. [19] also advocate using a circular external fixator with open fractures. However, they had 11 complications in 33 fractures cases, including pin tract infections. They used a technique similar to the one used by Talarico and reported having technical problems during the fixator insertion, incomplete fragment reduction and fixator size.

If the patient experiences pain in the long-term or the surface of the subtalar joint is not restored completely, a fusion can easily be performed in the right position because the alignment, length and height of the rear foot have been maintained. The advantage of having the rear foot anatomy be as close to normal as possible before subtalar fusion has been demonstrated [20]. After internal fixation in cases of post-traumatic osteoarthritis, the results were better in operated patients than in those where no emergency procedure was carried out. The most satisfactory results in terms of pain or function after fusion were found in patients with a normally aligned rear foot [4,20]. The use of an external fixator on the medial side in the emergency room when the injured tissues are easy to manipulate is also relevant in cases where a secondary procedure is not performed. With the rear foot well aligned, only the fusion procedure is necessary.

Injectable calcium phosphate or calcium carbonate cements could be useful due to their resorption, biocompatibility and osteoconduction properties [21,22]. Other options are the Palmer technique [23] or *in situ* cancellous bone grafting. But these techniques have a higher morbidity rate and lead to discomfort, although the skin complication rate is low when a meticulous technique is used.

5. Conclusion

We have described a novel technique to immediately treat calcaneal fractures, which is suitable for all severity levels in the Sanders classification system [11]. This technique combines emergency osteotaxis and ligamentotaxis with an additional, minimally-invasive fixation soon after to restore the anatomy of the posterior talar facet of the calcaneus. Apart from cases with minimally-displaced fractures (Sanders I and II) and preserved Böhler angle where functional treatment is preferable, the technique

described here continues to be the standard approach for treating calcaneus fractures in our department.

Disclosure of interest

The authors declare that they have no conflicts of interest concerning this article.

References

- [1] Basile A. Operative versus nonoperative treatment of displaced intra-articular calcaneal fractures in elderly patients. *J Foot Ankle Surg* 2010;49:25–32.
- [2] Zwipp H, Rammelt S, Barthel S. Calcaneal fractures – open reduction and internal fixation (ORIF). *Injury* 2004;35(Suppl. 2):SB46–54.
- [3] Makki D, Alnajjar HM, Walkay S, et al. Osteosynthesis of displaced intra-articular fractures of the calcaneum: a long-term review of 47 cases. *J Bone Joint Surg Br* 2010;92:693–700.
- [4] Colom A, Bégué T, Masquelet AC. Traitement chirurgical des fractures thalamiques du calcaneum : analyse comparée et facteurs pronostiques. À propos de 88 cas. *Rev Chir Orthop Reparatrice Appar Mot* 1999;85:135.
- [5] Colom A, Bégué T, Masquelet AC. Ligamentotaxis et ostéotaxis par fixateur externe dans les fractures thalamiques du calcaneum : résultats préliminaires. *Rev Chir Orthop Reparatrice Appar Mot* 2000;86:61.
- [6] McBride DJ, Ramamurthy C, Laing P. The hindfoot: calcaneal and talar fractures and dislocations – part 1: fractures of the calcaneum. *Curr Orthop* 2005;19:94–100.
- [7] Early JS. Treatment protocol for the management of open intra-articular calcaneal fractures. *Tech Foot Ankle Surg* 2005;4:31–4.
- [8] Rammelt S, Zwipp H. Calcaneus fractures: facts, controversies and recent developments. *Injury* 2004;35:443–61.
- [9] Schepers T, Patka P. Treatment of displaced intra-articular calcaneal fractures by ligamentotaxis: current concepts' review. *Arch Orthop Trauma Surg* 2009;129:1677–83.
- [10] Louisia S, Masquelet AC. The medial and inferior calcaneal nerves: an anatomic study. *Surg Radiol Anat* 1999;21:169–73.
- [11] Sanders R, Fortin P, DiPasquale T, Walling A. Operative treatment in 120 displaced intraarticular calcaneal fractures. Results using a prognostic computed tomography scan classification. *Clin Orthop Relat Res* 1993;290:87–95.
- [12] Besch L, Radke B, Mueller M, et al. Dynamic and functional gait analysis of severely displaced intra-articular calcaneus fractures treated with a hinged external fixator or internal stabilization. *J Foot Ankle Surg* 2008;47:19–25.
- [13] Myerson M, Manoli A. Compartment syndromes of the foot after calcaneal fractures. *Clin Orthop Relat Res* 1993;290:142–50.
- [14] Baumgaertel FR, Gotzen L. Two-stage operative treatment of comminuted calcaneal fractures. Primary indirect reduction with medial external fixation and delayed lateral plate fixation. *Clin Orthop Relat Res* 1993;290:132–41.
- [15] Besch L, Waldschmidt JS, Daniels-Wredenhagen M, et al. The treatment of intra-articular calcaneus fractures with severe soft tissue damage with a hinged external fixator or internal stabilization: long-term results. *J Foot Ankle Surg* 2010;49:8–15.
- [16] Magnan B, Bortolazzi R, Marangon A, et al. External fixation for displaced intra-articular fractures of the calcaneum. *J Bone Joint Surg Br* 2006;88:1474–9.
- [17] Besch L, Schmidt I, Mueller M, et al. A biomechanical evaluation to optimize the configuration of a hinged external fixator for the primary treatment of severely displaced intraarticular calcaneus fractures with soft tissue damage. *J Foot Ankle Surg* 2008;47:26–33.
- [18] Talarico LM, Vito GR, Zyryanov SY. Management of displaced intraarticular calcaneal fractures by using external ring fixation, minimally invasive open reduction, and early weight bearing. *J Foot Ankle Surg* 2004;43:43–50.
- [19] McGarvey WC, Burris MW, Clanton TO, Melissinos EG. Calcaneal fractures: indirect reduction and external fixation. *Foot Ankle Int* 2006;27:494–9.
- [20] Radnay CS, Clare MP, Sanders RW. Subtalar fusion after displaced intra-articular calcaneal fractures: does initial operative treatment matter? Surgical technique. *J Bone Joint Surg Am* 2010;92(Suppl. 1 Pt 1):32–43.
- [21] Thordarson DB, Bollinger M. SRS cancellous bone cement augmentation of calcaneal fracture fixation. *Foot Ankle Int* 2005;26:347–52.
- [22] Elsner A, Jubel A, Prokop A, et al. Augmentation of intraarticular calcaneal fractures with injectable calcium phosphate cement: densitometry, histology, and functional outcome of 18 patients. *J Foot Ankle Surg* 2005;44:390–5.
- [23] Di Schino M, Bensaida M, Vandenbussche E, Augereau B, Nich C. Results of open reduction and cortico-cancellous autograft of intra-articular calcaneal fractures according to Palmer. *Rev Chir Orthop Reparatrice Appar Mot* 2008;94:135–44.