



Case Report

Epileptic nystagmus: A case report and systematic review

Sun-Uk Lee ^a, Hong-Il Suh ^a, Jun Young Choi ^b, Kyun Huh ^a, Hyo-Jung Kim ^c, Ji-Soo Kim ^{d,*}^a Department of Neurology, Ajou University School of Medicine, Ajou University Hospital, Suwon, South Korea^b Department of Brain Sciences, Ajou University School of Medicine, Suwon, South Korea^c Department of Biomedical Laboratory Science, Kyungdong University, Goseong, South Korea^d Department of Neurology, Seoul National University College of Medicine, Seoul National University Bundang Hospital, Seongnam, South Korea

ARTICLE INFO

Article history:

Received 28 July 2014

Accepted 23 August 2014

Available online 18 September 2014

Keywords:

Seizure

Nystagmus

Epileptic nystagmus

Ictal nystagmus

ABSTRACT

Purpose: We aimed to define the characteristics of epileptic nystagmus and correlate those with other clinical findings in a large number of patients.

Methods: We report a patient with epileptic nystagmus and additionally reviewed the reported clinical features of 36 more patients through a systematic literature search. We analyzed the characteristics of epileptic nystagmus and attempted correlations of those with alertness of the patients and epileptic foci on EEG.

Results: All 33 patients with unilateral horizontal nystagmus showed nystagmus beating away from the side of ictal discharges. Epileptic nystagmus was preceded by gaze deviation in 21 patients, with contraversive in 19 and ipsiversive in 2. Seizures associated with epileptic nystagmus were mostly focal (25/29, 86.2%) with or without loss of awareness. Ictal discharges originated from the occipital (n = 16), parietal (n = 9), temporo-occipital (n = 6), frontal (n = 4), and temporal (n = 3) areas, and two patients had multiple epileptic foci. Seizures were usually symptomatic (24/37, 64.9%). The presence of preceding gaze deviation and midline crossing of the nystagmus did not correlate with the ictal onset zone or alertness of the patients. Recording of epileptic nystagmus was available only in 6 patients, and the epileptic nystagmus could be localized to the saccadic areas in two and to the smooth pursuit areas in another two. Two patients showed the features of epileptic nystagmus from both areas.

Conclusion: Even though the localizing value of epileptic nystagmus seems limited in previous reports, the fast phase of epileptic nystagmus was almost always directed away from the epileptic focus that mostly arose from the posterior part of the cerebral hemisphere.

© 2014 The Authors. Published by Elsevier Inc. This is an open access article under the CC BY-NC-ND license (<http://creativecommons.org/licenses/by-nc-nd/3.0/>).

1. Introduction

Even though nystagmus mostly indicates a lesion involving the peripheral vestibular labyrinth, brainstem, or cerebellum, it may occur in lesions involving the cerebral hemisphere [1–3]. Nystagmus may be observed in association with seizures or epileptiform discharges originating from the cortical areas involved in the generation of eye movements [1,4]. It has been postulated that the epileptic nystagmus stemming from the saccadic areas occurs only in the contraversive hemifield without crossing the midline and has a decreasing slow-phase velocity (SPV) [4]. In contrast, the epileptic nystagmus from the smooth pursuit regions has been proposed to have a linear SPV and corrective quick phases crossing the midline [4,5]. Even though this distinction seems reasonable in view of the anatomical correlates [4], its

clinical applicability has not been validated in a larger number of patients. Indeed, an individual patient may show co-activation of both areas or propagation of the epileptic discharges from one to the other, making the distinction difficult [2]. We also recently encountered a patient who showed epileptic nystagmus with features originating from both the saccade and smooth pursuit areas [2]. Even though there have been numerous reports on epileptic nystagmus since the first report in a patient with focal seizure [1], a systematic review on the features of epileptic nystagmus and the correlation of those with the areas of ictal discharges on EEG has not been available.

To address this issue, we describe a patient with epileptic nystagmus and analyzed the characteristics of epileptic nystagmus in the previously reported cases with a systematic review.

2. Methods

2.1. Laboratory work-ups in our patient

Our patient had continuous EEG monitoring with simultaneous recording of eye movements in the absence of visual fixation using a

* Corresponding author at: Department of Neurology, Seoul National University College of Medicine, Seoul National University Bundang Hospital, 173-82 Gumi-ro, Bundang-gu, Seongnam-si, Gyeonggi-do 463-707, South Korea. Tel.: +82 31 787 7463; fax: +82 31 719 6828.

E-mail address: jisookim@snu.ac.kr (J.-S. Kim).

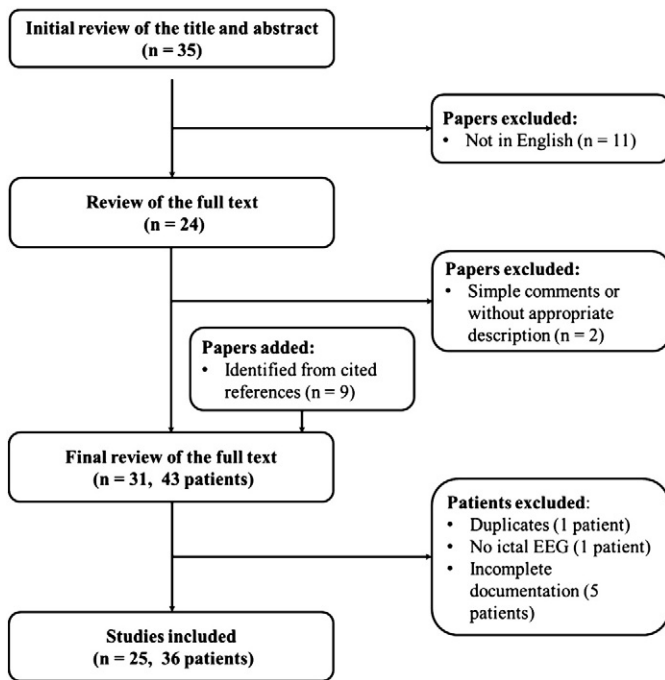


Fig. 1. A flow chart for the systematic review in this study.

video-Frenzel goggle system (SLMED, Seoul, Korea). Brain MRI was conducted with a 3.0-T scanner (Achieva, Philips, OH, USA). Ictal and interictal single photon emission computed tomography (SPECT, Infinia Hawkeye 4 SPECT-CT, GE Healthcare, Waukesha, WI, USA) were performed using a radiotracer (^{99m}Tc -HMPAO, Ceretec, Amersham, Chalfont, UK).

2.2. Literature review

Literature search was done using PubMed (upto August 2013). The keywords used for searching included *epileptic nystagmus*, *ictal nystagmus*, and *non-convulsive status epilepticus (NCSE)*. We included all the patients described in systematic reviews, clinical studies, and case reports published in English (Fig. 1). The references cited by the retrieved articles were also reviewed. The diagnosis of epileptic nystagmus was based on the following: 1) clearly documented seizure activity on the

ictal EEG, 2) occurrence of nystagmus in accordance with the epileptic discharges, and 3) documentation of the nystagmus using oculography, video clip, or periorbital electrodes.

From these reports, we analyzed the type of seizure, ictal onset zone and maximal ictal frequency on EEG. We also determined the direction and midline crossing of the nystagmus and the presence of preceding gaze deviation and its direction. We also analyzed findings of oculography even though it was available only in a small number of patients. Based on these findings, we attempted any correlation among the epileptic foci and other features of epileptic nystagmus using linear-to-linear correlation.

3. Results

3.1. Case report

A 74-year-old woman presented with aphasia for 2 weeks. She had suffered from hypertension and diabetes mellitus for seven years, and Alzheimer's disease for a few years. She had also been admitted to the hospital 4 months earlier because of myocardial infarction and cerebral infarction involving the territory of the right anterior cerebral artery. Examination at presentation showed weak left beating nystagmus without fixation (Video). Because of global aphasia and dementia, smooth pursuits and saccades could not be fully evaluated, but the reflexive saccades appeared to be intact. She was able to stay alert most of the time. However, she intermittently (10 per day) lapsed into a drowsy and lethargic state with both eyes closed and did not respond to noxious stimuli. This altered mental status lasted no more than 1 min, and she recovered to her previous alert state. During the attacks, she showed rightward deviation of both eyes followed by vigorous right-beating nystagmus without any convulsive movements or abnormal postures. Electroencephalography revealed 19- to 22-Hz polyspikes that were maximal over the left temporo-occipital region, and eye movement recording showed right beating nystagmus at 3–4 Hz, which did not cross the midline (Video).

Magnetic resonance imaging showed an edematous lesion without gadolinium enhancement on the left temporo-parieto-occipital junction, which was considered a seizure-induced change (Fig. 2A). Analysis of cerebrospinal fluid was unavailable. single photon emission computed tomography during the ictus showed hyperperfusion in the left temporo-parieto-occipital junction (Fig. 2B).

With a suspicion of seizure from a small infarction or Alzheimer's disease itself, fosphenytoin (450 mg per day) and levetiracetam (2000 mg per day) were initiated. Her neurological status gradually

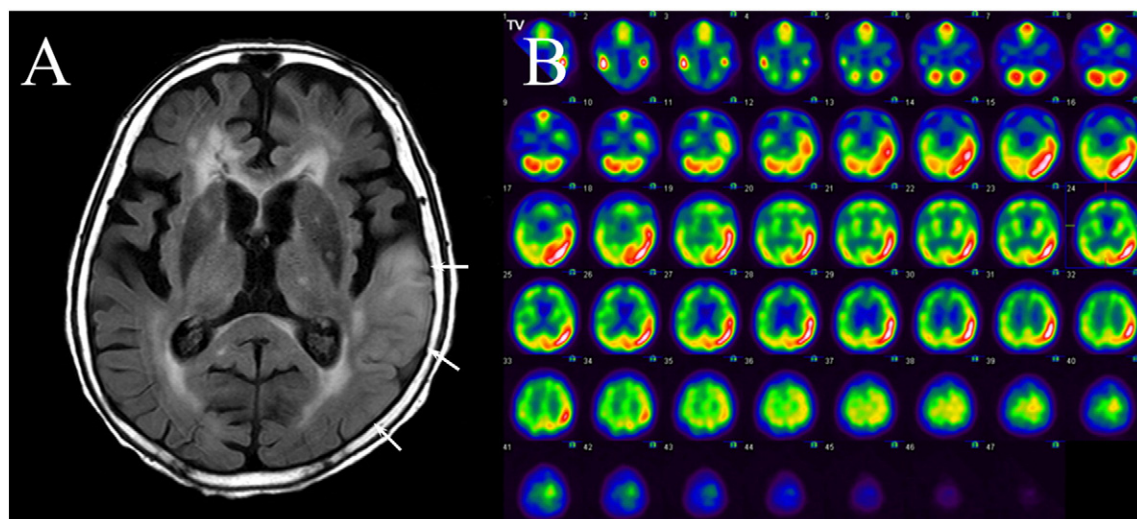


Fig. 2. A. Image shows an increased signal intensity in the left temporo-occipital region on fluid attenuated inversion recovery image (arrows). B. Ictal single photon emission computed tomography shows hyperperfusion in the left temporo-parieto-occipital junction.

improved, and follow-up video-EEG one week later showed no epileptiform discharges but regional slowing over the left temporal area. She was discharged two weeks after the admission still with aphasia but without any seizures.

3.2. Literature review

Through the literature review, we were able to additionally reviewed the reported clinical features of 36 patients (21 women, age range: 0–75 years, median age: 32 years, mean age \pm SD = 35.7 \pm 24.1, Table 1). Except for four patients [one (patient 17) with pendular nystagmus, another (patient 35) with upbeat nystagmus, another (patient 30) with generalized ictal discharges on EEG, and the remaining one (patient 36) with alternating nystagmus], all the other 33 (33/37, 89.2%) patients showed nystagmus beating away from the side of ictal discharges on EEG (Table 1). The preceding gaze deviation was described in 25 patients, and 19 of them showed contraversive deviation, while only two had ipsiversive deviation. Four patients showed no gaze deviation. Since oculography was performed in only six patients, the patterns of SPV could not be determined in most patients, but four (patients 4, 5, 10, and 15, Table 1) of the six patients showed a linear SPV, while two (patients 11 and 14) had a decreasing SPV.

Eight patients, including one with incomplete description of the seizure semiology, had more than one type of seizure in association with the epileptic nystagmus. However, the seizures were mostly focal (25/29, 86.2%) with (n = 17) or without (n = 8) loss of consciousness

(LOC). The ictal discharges originated from the occipital (n = 17), parietal (n = 9), temporo-occipital (n = 5), frontal (n = 4), and temporal (n = 3) areas, and two patients had multiple epileptic foci (patients 19 and 20, Table 1). Generalized ictal discharges were found only in 2 patients (patients 17 and 30, Table 1).

Underlying etiologies included cerebral infarction in 7 patients, cerebral hemorrhage in 3, infection in 2, cortical dysplasia in 2, and head trauma, cerebral metastasis, uremic encephalopathy, hypoglycemic encephalopathy, MELAS (mitochondrial myopathy, encephalopathy, lactic acidosis, and stroke), Sturge–Weber syndrome, arachnoid cyst, physostigmine intoxication, and birth asphyxia in one patient each. Except for one patient (patient 13) without description of the frequency of ictal discharges, almost half (16/36, 44.4%) of the previously reported patients showed ictal discharges less than 10 Hz. Even in patients who were alert, epileptic nystagmus occurred with ictal discharges of less than 10 Hz (patients 1, 8, 11, 15, 16, 29, and 34, Table 1).

The presence of preceding gaze deviation and midline crossing of the nystagmus did not correlate with the ictal onset zone ($p = 0.509$ and $p = 0.385$, respectively, linear-to-linear correlation). The presence of midline crossing of the nystagmus did not show a correlation with the seizure type either ($p \approx 1.000$, linear-to-linear correlation). However, after excluding patients who had more than one type of seizure, all patients with focal seizure and LOC showed epileptic nystagmus with preceding gaze deviation, either contraversive (n = 12) or ipsiversive (n = 2). By contrast, the focal seizures without LOC (n = 3) did not have accompanying preceded by a gaze deviation. The gaze deviation

Table 1
Characteristics of epileptic nystagmus.

Pt.	Age	Sex	MSE	GD	Epileptic nystagmus			Ictal EEG (Hz)	Seizure type	Cause	Ref.
					Direction	SPV	Midline crossing				
1	25	M	Alert	?	C	?	?	O (4–7)	Focal	Unknown	[14]
2	33	M	Alert	C	C	?	?	O (10–15)	Focal (LOC)	Unknown	–
3	68	M	Coma	C	C	?	None	F (4–6)	Focal (LOC)	Hemorrhage	[15]
4	52	F	Alert	None	C	L	?	T-O (8–16)	Focal	Unknown	[16]
5	27	M	Alert	C	C	L	None	T-O (8–10)	Focal (LOC)	MELAS	[2]
6	19	F	Coma	?	C	?	None	F (11–12)	Focal (LOC)	Infection	[17]
7	43	F	Alert	?	C	?	+	O (11)	Focal	Infarction	[18]
8	23	M	Alert	?	C	?	None	O (6–9)	Focal, focal (LOC), generalized	Trauma	–
9	51	M	Alert	?	C	?	?	P (9–10)	Focal	Sturge–Weber syndrome	[19]
10	11	M	Alert	I	C	L	None	O (12–14)	Focal (LOC)	Unknown	[4]
11	70	M	Alert	C	C	D	None	T-O (3–4)	Focal, focal (LOC), generalized NCSE	Hemorrhage	[20]
12	8	M	Alert	C	C	?	+	O (19)	Focal (LOC)	Unknown	[21]
13	75	F	Alert	None	C	?	None	T (?)	Focal	Infarction	[22]
14	70	F	Drowsy	C	C	D	?	T-O (11–14)	Focal (LOC)	Unknown	[1]
15	0	F	Alert	C	C	L	+	P (6–7)	Focal (LOC)	Cortical dysplasia	[23]
16	31	F	Drowsy	?	C	?	?	O (7–8)	Focal (LOC)	Infarction	[24]
17	10	F	Alert	?	?	?	?	Generalized (3)	Generalized	Electroclinical syndrome	[25]
18	32	F	Vegetative state	C	C	?	None	O (1–5)	Focal (LOC)	Hypoglycemic encephalopathy	[11]
19	72	M	Drowsy	C	C	?	None	F, O (4–5)	Focal (LOC)	Infarction	–
20	69	F	Drowsy	C	C	?	None	F, T, P (1–3)	Focal (LOC), generalized	Cerebral metastasis	–
21	54	M	Drowsy	C	C	?	None	P (2–4)	Focal (LOC)	–	–
22	44	M	Alert	C	C	?	None	P (10–11)	Focal (LOC)	Infarction	–
23	7	F	Stupor	C	C	?	None	P (2)	Focal (LOC)	–	–
24	25	F	Alert	C	C	?	None	P (10–12)	Focal, focal (LOC), generalized	–	–
25	58	M	Alert	C	C	?	None	O (12–15)	Focal, focal (LOC)	Infarction	[26]
26	50	F	Alert	I	C	?	+	O (9–12)	Focal (LOC)	–	[27]
27	14	F	Alert	?	C	?	?	P (10–14)	Focal	–	[28]
28	19	M	Alert	?	C	?	?	O (20)	Focal (LOC)	–	–
29	22	F	Alert	?	C	?	?	T-O (3–4)	Focal, focal (LOC)	Infection	–
30	15	F	Alert	?	?	?	?	Generalized (>10)	Generalized	–	[29]
31	6	M	Alert	None	C	?	None	T (11–12)	Focal	Arachnoid cyst	[30]
32	4	F	Alert	C	C	?	?	O (8–9)	GCSE	Infarction	[31]
33	32	F	Alert	?	C	?	?	P (12–20)	Focal	–	[32]
34	43	F	Alert	?	C	?	?	O (20–25)	Focal, focal (LOC), generalized	Cortical dysplasia	[33]
35	66	F	Stupor	?	?	?	?	O (3–4)	NCSE	Drug (physostigmine)	[34]
36	0	F	Alert	None	?	?	+	O (2–3)	?	Birth asphyxia	[35]
37	74	F	Alert	C	C	?	None	T-O (19–22)	Focal (LOC)	–	Our study

D, decreasing; F, frontal; GCSE, generalized convulsive status epilepticus; GD, gaze deviation; I, ipsilateral; L, linear; MELAS, mitochondrial myopathy, encephalopathy, lactic acidosis, and stroke; MSE, mental status exam; NCSE, nonconvulsive status epilepticus; O, occipital; P, parietal; T, temporal; T-O, temporo-occipital; focal, focal seizure without loss of consciousness; focal (LOC), focal seizure with loss of consciousness.

was mostly observed in seizures which accompanied LOC ($p = 0.027$, linear-to-linear correlation).

Of the 6 patients who had both EEG and oculography, two (patients 11 and 14, [Table 1](#)) showed the characteristics of nystagmus from involvement of the saccadic areas, while the other two (patients 4 and 15, [Table 1](#)) had the characteristic nystagmus associated with smooth pursuit areas. By contrast, two patients (patients 5 and 10, [Table 1](#)) showed epileptic nystagmus with a linear slow phase but without crossing the midline, which cannot be classified into one type based on the previous distinction [4]. All 6 patients had the ictal foci in the posterior part (temporo-occipital, parietal, or occipital areas) of the cerebral hemisphere and the frequency of ictal discharges on EEG ranged from 2 to 16 Hz.

4. Discussion

The findings in our patient and systematic review may be summarized as follows: 1) in almost all of the patients, the nystagmus beat away from the side of ictal discharges; 2) seizures were mostly symptomatic; 3) seizures mostly originated from the posterior part of the brain; and 4) the characteristics of epileptic nystagmus (presence of preceding gaze deviation and midline crossing) and patterns of SPV were poorly documented and did not correlate with the ictal onset zone.

Irritative lesions in the cerebral cortex are known to cause deviation of both eyes to the contralesional side, which was demonstrated by electrical stimulation [6]. Introduction of EEG and oculography allowed an accurate analysis of eye movements and localization of the corresponding cortical areas responsible for generating such eye movements during the epileptic events [4]. Epileptic nystagmus has been ascribed to disruption of cortical controls over saccades or smooth pursuit [1,4]. The cortical regions involved in the generation of saccades include the frontal, parietal, and supplementary eye fields [7]. It has been proposed that epileptic nystagmus from the cortical saccadic areas result in contralesional ocular deviation, has decreasing SPV, and does not cross the midline toward the ipsilesional hemifield [4].

Seizures from the middle temporal (MT) and medial superior temporal (MST) areas, which are involved in the generation of smooth pursuit are also known to generate epileptic nystagmus [4]. When the regions responsible for smooth pursuit are stimulated, the eyes drift ipsiversively to the eccentric position, and reflexive resetting quick phases beat to the contralateral side crossing the midline. Accordingly, contrary to those commencing from the saccadic areas, epileptic nystagmus from the areas involved in the generation of smooth pursuit is known to cause ipsilesional ocular deviation, has linear SPV, and crosses the midline toward the contralesional hemifield [4].

Even though the pattern of SPV and integrity of saccades or smooth pursuit could not be fully evaluated in our patient due to aphasia and underlying Alzheimer's disease, the epileptic nystagmus occurred only in the contralateral right hemifield without crossing the midline, which corresponds to the characteristics of epileptic nystagmus from the saccadic areas. However, our patient also showed interictal spontaneous nystagmus, probably pursuit-paretic, beating to the lesion side (Video) [3], and the ictal onset zone on the SPECT and EEG corresponded to the lateral occipital cortex (Brodmann area 19) and the adjacent ventrocaudal aspect of Brodmann area 39, which are known as the human homologues of MT and MST areas [5].

As in our patient, previous reports on epileptic nystagmus frequently encountered the features from both the saccadic and smooth pursuit areas. This may be explained by propagation of the ictal discharges from one to the adjacent cortices [8]. Alteration in the level of consciousness during the seizures also indicates propagation of the ictal discharges [8]. As various cortical regions responsible for ocular motility can be involved during the ictus, ictal eye movements may take various features. It seems less likely that the epileptic discharges would stimulate either the saccadic or the smooth pursuit regions only. Especially in focal seizures with LOC or generalized seizures, more than one neural

substrate may contribute to generate epileptic nystagmus. Therefore, the dichotomization of epileptic nystagmus based on the disruption of cortical control over smooth pursuit or saccades may not be applicable to most patients with epileptic nystagmus in clinical practice [2].

Although we found a correlation between the characteristics of epileptic nystagmus, the presence of accompanying gaze deviation, and seizure type, it should be interpreted with caution. Contraversive gaze deviation is known to be followed by epileptic nystagmus from the saccadic areas [4]. However, other characteristics such as midline crossing and pattern of SPV did not correlate with the seizure type. Moreover, patients who had more than one type of seizure ($n = 8$) exhibited the same semiology of preceding contraversive gaze deviation during the focal seizure without LOC (patients 8, 11, 24, and 25).

Epileptic nystagmus appears infrequent in that it was reported in only 10% of 42 patients with occipital lobe epilepsy [9]. In an epilepsy monitoring unit, epileptic nystagmus was observed in only 0.5% of 1838 patients who had been monitored for 46 months [10]. The infrequency of epileptic nystagmus has been ascribed to the rarity of the conditions that meet the following: 1) involvement of the regions responsible for epileptic nystagmus and 2) high-frequency epileptic discharges sufficient to generate epileptic nystagmus (more than 10 Hz) [11]. However, the ictal frequency required to generate nystagmus was suggested to be lower in patients with decreased mental status or in those with severe neurological impairment [11]. Yet, systematic analysis of previous literature showed that epileptic nystagmus can occur with an ictal frequency less than 10 Hz, regardless of the neurological status. Epileptic nystagmus was observed even seizures absence seizure with 3-Hz spikes (patient 17, [Table 1](#)). This implies that factors other than the ictal discharge frequency contribute to the rarity of epileptic nystagmus.

The incidence of epileptic nystagmus may have been underestimated since it may escape recognition when abnormal postures or movements are not observed. Since most epileptic nystagmus occurs in focal seizures or NCSE, the ancillary movements may be as subtle as eye blinking or head rotation. Furthermore, propagation of ictal discharges to the frontal areas may suppress the generation of epileptic nystagmus. As stated previously, most epileptic nystagmus has been observed with lesions involving the posterior part of the cerebral hemisphere. It has rarely occurred when the epileptic foci reside in the frontal lobe. The dorsolateral prefrontal cortex is known to inhibit the superior colliculus and may act as a saccadic suppressor [12,13]. Accordingly, involvement of the frontal lobe by ictal discharges may have suppressed the generation of epileptic nystagmus.

5. Conclusion

Detailed characteristics of epileptic nystagmus have rarely been sought in previous reports. Even though the localizing value of epileptic nystagmus seems limited in previous reports, the fast phase of epileptic nystagmus was almost always directed away from an epileptic focus that mostly arose from the posterior part of the cerebral hemisphere.

Supplementary data to this article can be found online at <http://dx.doi.org/10.1016/j.ebcr.2014.08.004>.

Author contributions

Dr. Lee wrote the manuscript, and analyzed and interpreted the data. Drs. Suh, Choi, Huh, and H.J. Kim analyzed and interpreted the data and revised the manuscript.

Dr. J.S. Kim conducted the design and conceptualization of the study, interpretation of the data, and drafting and revising the manuscript.

Disclosure

The authors report no disclosures. The patient gave permission for still and moving images of his eyes to be shown in this publication.

Acknowledgments

This study was supported by a grant from the Korea Healthcare technology R&D Project, Ministry of Health and Welfare, Republic of Korea (HI10C2020).

Conflict of interest

The authors declare that they have no conflict of interest.

References

- [1] Thurston SE, Leigh RJ, Osorio I. Epileptic gaze deviation and nystagmus. *Neurology* 1985;35:1518–21.
- [2] Choi SY, Kim Y, Oh SW, Jeong SH, Kim JS. Pursuit-aretic and epileptic nystagmus in MELAS. *J Neuroophthalmol* 2012;32:135–8.
- [3] Sharpe JA. Pursuit paretic nystagmus. *Ann Neurol* 1979;6:458.
- [4] Tusa RJ, Kaplan PW, Hain TC, Naidu S. Ipsiversive eye deviation and epileptic nystagmus. *Neurology* 1990;40:662–5.
- [5] Morrow MJ, Sharpe JA. Retinotopic and directional deficits of smooth pursuit initiation after posterior cerebral hemispheric lesions. *Neurology* 1993;43:595–603.
- [6] Penfield W, Rasmussen T. Vision. The cerebral cortex of man: a clinical study of localization of function. New York: Macmillan; 1950.
- [7] Leigh RJ, Zee DS. The neurology of eye movements. 4th ed. New York: Oxford University Press; 2006.
- [8] Engel J, Pedley TA. *Epilepsy: a comprehensive textbook*. 2nd ed. Philadelphia: Lippincott Williams & Wilkins; 2008.
- [9] Salanova V, Andermann F, Olivier A, Rasmussen T, Quesney LF. Occipital lobe epilepsy: electroclinical manifestations, electrocorticography, cortical stimulation and outcome in 42 patients treated between 1930 and 1991. *Surgery of occipital lobe epilepsy. Brain* 1992;115(Pt 6):1655–80.
- [10] Kellinghaus C, Skidmore C, Loddenkemper T. Lateralizing value of epileptic nystagmus. *Epilepsy Behav* 2008;13:700–2.
- [11] Kaplan PW, Tusa RJ. Neurophysiological and clinical correlations of epileptic nystagmus. *Neurology* 1993;43:2508–2508.
- [12] Condy C, Rivaud-Pechoux S, Ostendorf F, Ploner CJ, Gaymard B. Neural substrate of antisaccades: role of subcortical structures. *Neurology* 2004;63:1571–8.
- [13] Pierrot-Deseilligny C, Muri RM, Nyffeler T, Milea D. The role of the human dorsolateral prefrontal cortex in ocular motor behavior. *Ann N Y Acad Sci* 2005;1039:239–51.
- [14] Stolz SE, Chatrian GE, Spence AM. Epileptic nystagmus. *Epilepsia* 1991;32:910–8.
- [15] Kaplan PW, Lesser RP. Vertical and horizontal epileptic gaze deviation and nystagmus. *Neurology* 1989;39:1391–3.
- [16] Furman JM, Crumrine PK, Reinmuth OM. Epileptic nystagmus. *Ann Neurol* 1990;27:686–8.
- [17] Lee JH, Nam DH, Oh SY, Shin BS, Seo MW, Jeong SK, et al. Nonconvulsive status epilepticus presenting as epileptic nystagmus in a patient with herpes encephalitis. *J Neuroophthalmol* 2012;32:249–51.
- [18] Weber YG, Roesche J, Lerche H. Epileptic nystagmus: two case reports, clinical and pathophysiological review of the literature. *J Neurol* 2006;253:767–71.
- [19] Grant AC, Jain V, Bose S. Epileptic monocular nystagmus. *Neurology* 2002;59:1438–41.
- [20] Garcia-Pastor A, Lopez-Esteban P, Peraita-Adrados R. Epileptic nystagmus: a case study video-EEG correlation. *Epileptic Disord* 2002;4:23–8.
- [21] Gire C, Somma-Mauvais H, Nicaise C, Roussel M, Garnier JM, Farnarier G, et al. Epileptic nystagmus: electroclinical study of a case. *Epileptic Disord* 2001;3:33–7.
- [22] Pfefferkorn T, Holtmannspötter M, Querner V, Dudel C, Noachtar S, Strupp M, et al. Epileptic nystagmus. *Neurology* 2004;E14.
- [23] Harris CM, Boyd S, Chong K, Harkness W, Neville BG. Epileptic nystagmus in infancy. *J Neurol Sci* 1997;151:111–4.
- [24] Ramani V. Cortical blindness following ictal nystagmus. *Arch Neurol* 1985;42:191.
- [25] Watanabe K, Negoro T, Matsumoto A, Inokuma K, Takaesu E, Maehara M, et al. Epileptic nystagmus associated with typical absence seizures. *Epilepsia* 1984;25:22–4.
- [26] Kaplan P. Neurophysiological localization of epileptic nystagmus. *Am J Electroneurodiagnostic Technol* 1999;39:77–83.
- [27] Smith N, Docherty T. Nystagmus: an unusual manifestation of temporal lobe epilepsy. *J Electrophysiol Technol* 1982;8:7–13.
- [28] Beun AM, Beintema DJ, Binnie CD, Debets RM, Overweg J, Van Heycop ten Ham MW, et al. Epileptic nystagmus. *Epilepsia* 1984;25:609–14.
- [29] Jacome DE. Monocular ictal nystagmus. *Arch Neurol* 1982;39:653.
- [30] Hughes JR, Fino JJ. Epileptic nystagmus and its possible relationship with PGO spikes. *Clin Electroencephalogr* 2003;34:32–8.
- [31] Kanazawa O, Sengoku A, Kawai I. Oculoclonic status epilepticus. *Epilepsia* 1989;30:121–3.
- [32] White JC. Epileptic nystagmus. *Epilepsia* 1971;12:157–64.
- [33] Galimberti CA, Versino M, Sartori I, Manni R, Martelli A, Tartara A, et al. Epileptic skew deviation. *Neurology* 1998;50:1469–72.
- [34] Neugebauer H, Winkler T, Feddersen B, Pfister HW, Noachtar S, Straube A, et al. Upbeat nystagmus as a clinical sign of physostigmine-induced right occipital non-convulsive status epilepticus. *J Neurol* 2012;259:773–4.
- [35] Cherian PJ, Swarte RM, Blok JH, Broker-Schenk PM, Visser GH. Ictal nystagmus in a newborn baby after birth asphyxia. *Clin EEG Neurosci* 2006;37:41–5.