



ELSEVIER

Contents lists available at ScienceDirect

IDCases

journal homepage: www.elsevier.com/locate/idcr

Case Illustrated

Necrotizing fasciitis complicating snakebite in Cambodia

Pasco Hearn^{a,*}, Thyl Miliya^{a,b}, Songly Hor^b, Vuthy Sar^b, Paul Turner^{a,c}^a Cambodia-Oxford Medical Research Unit, Siem Reap, Cambodia^b Angkor Hospital for Children, Siem Reap, Cambodia^c Centre for Tropical Medicine and Global Health, Nuffield Department of Clinical Medicine, University of Oxford, Oxford, UK

ARTICLE INFO

Article history:

Received 30 July 2015

Received in revised form 1 September 2015

Accepted 1 September 2015

A nine year old boy, living in rural Cambodia, presented to a hospital two days after being bitten on the forearm by a cobra. The patient was febrile, tachycardic and complained of increasing pain and swelling to his arm. The wound had developed an infection, resulting in necrotizing fasciitis (see [Fig. 1](#)), with erythema having spread to involve the whole arm, portions of his neck and chest wall. Surgeons carried out extensive debridement (see [Fig. 2](#)) and

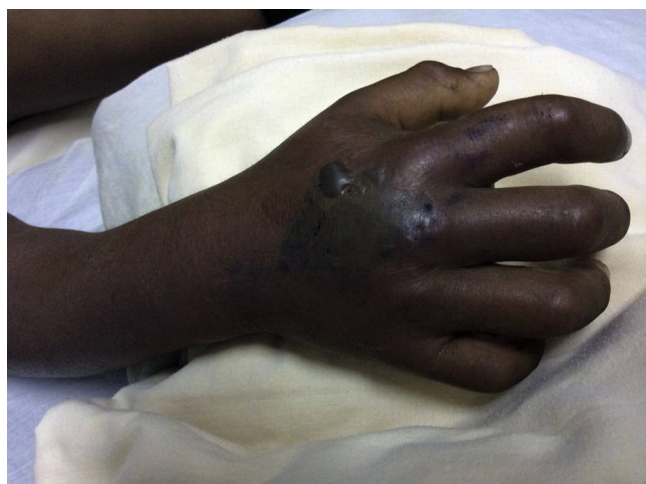

Fig. 1. Snakebite wound with associated necrotizing fasciitis.

imipenem was prescribed intravenously to provide cover against a broad spectrum of bacteria. In this case, secondary infection was caused by *Morganella morganii* and *Enterococcus faecalis*, which were isolated from debrided tissue and were both sensitive to the empirical antimicrobial choice. Following 10 days of intravenous therapy, groin flap and skin graft surgery, the child was discharged home, having made a good recovery from this uncommon but severe complication of snakebite.

Secondary infection of snakebite wounds is recognized, but occurs relatively infrequently [1]. Adequate treatment requires appropriate antimicrobial choices and early involvement of the surgical team. Localized necrosis, which is almost always present to some degree with cobra bites, renders the wound more

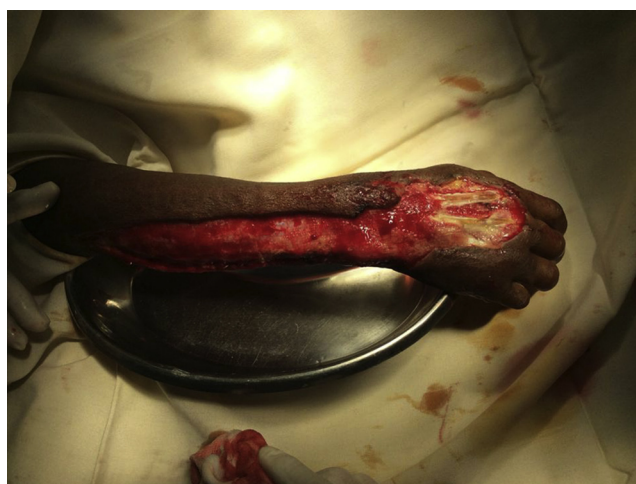


Fig. 2. Snakebite wound following surgical debridement of infected, necrotic tissue.

* Corresponding author at: Angkor Hospital for Children, Tep Vong Road & Umchhay Street, Svay Dangcum, Siem Reap, P.O. Box 50, Siem Reap, Cambodia. Tel.: +855 69724852.

E-mail address: pascohearn@hotmail.com (P. Hearn).

susceptible to infection [2]. Infections are then likely to be more severe in cobra bites than, for example, those of pit vipers (the two families of snake most commonly reported in such cases) since they harbor more pathogenic bacteria in their mouths [3]. The flora of snake mouths varies between species, but typically includes enteric Gram negative organisms (such as *Morganella morganii*, *Pseudomonas* sp. and *Escherichia coli*), some of which are likely to be resistant to commonly used antimicrobials [4], Gram positive organisms (including *Staphylococcus* sp. and *Enterococcus* sp.) and anaerobic bacteria (most commonly *Bacteroides* sp. and *Clostridium* sp.). Greater numbers of pathogenic bacteria are found in snake mouths than in their venom, which has been shown to possess some antibacterial properties, particularly against Gram-positive organisms and may explain in part why infection of these wounds is not a common occurrence overall [5].

References

- [1] Garg A, Sujatha S, Garg J, Acharya N, Parija S. Wound infections secondary to snakebite. *J Infect Dev Ctries* 2008;3:221–3.
- [2] Chen CM, Wu KG, Chen CJ, Wang CM. Bacterial infection in association with snakebite: a 10-year experience in a northern Taiwan medical center. *J Microbiol Immunol Infect* 2011;44:456–60.
- [3] Lam KK, Crow P, Ng KH, Shek KC, Fung HT, Ades G, et al. A cross-sectional survey of snake oral bacterial flora from Hong Kong, SAR, China. *Emerg Med J* 2011;28:107–14.
- [4] Colinet C, Jocktane D, Brothier E, Rossolini GN, Cournoyer B, Nazaret S. Genetic analysis of *Pseudomonas aeruginosa* isolated from healthy captive snakes: evidence of high inter- and intrasite dissemination and occurrence of antibiotic resistance genes. *Environ Microbiol* 2010;12:716–29.
- [5] Theakston RD, Phillips RE, Looareesuwan S, Echeverria P, Makin T, Warrell DA. Bacteriological studies of the venom and mouth cavities of wild Malayan pit vipers (*Calloselasma rhodostoma*) in southern Thailand. *Trans R Soc Trop Med Hyg* 1990;84:875–9.