



Incidental De Garengeot's hernia: A case report of dual pathology to remember



Thomas Whitehead-Clarke*, Umesh Parampalli, Rakesh Bhardwaj

Darent Valley Hospital, Darent Wood Road, Dartford, Kent, United Kingdom

ARTICLE INFO

Article history:

Received 1 July 2015

Received in revised form 10 October 2015

Accepted 10 October 2015

Available online 20 October 2015

Keywords:

De Garengeot

Femoral hernia

Vermiform appendix

Emergency

Surgery

ABSTRACT

INTRODUCTION: A De Garengeot's hernia is the very rare dual pathology of a vermiform appendix within a femoral hernia.

PRESENTATION OF CASE: We discuss the rare case of a 62 year old female who presented as an emergency with a strangulated femoral hernia. Within the hernia sac a partly necrotic vermiform appendix was discovered. The patient successfully underwent an appendicectomy and repair of her femoral hernia. The post-operative period was uneventful, with no further issues at follow-up.

DISCUSSION: Our case report displays the successful treatment of a De Garengeot's hernia as an emergency admission, with a shorter than average admission time, and no post-operative complications.

CONCLUSION: This is a rare case of dual pathology, of which we believe there are few published cases.

© 2015 The Authors. Published by Elsevier Ltd. on behalf of IJS Publishing Group Ltd. This is an open access article under the CC BY-NC-ND license (<http://creativecommons.org/licenses/by-nc-nd/4.0/>).

1. Introduction

First described by Rene Jacques Croissant de Garengeot in 1731 [1], De Garengeot's hernia was defined in 2005 as a femoral hernia containing part or all of the vermiform appendix [2]. Femoral hernias account for approximately 3–4% of all hernias [3], with only 1% of those femoral hernias containing a vermiform appendix [4]. The presence of an acute appendicitis is rarer still. We believe this condition has been reported less than 100 times in the literature and to our knowledge there is no published gold standard for surgical approach.

Whilst the diagnosis of an irreducible femoral hernia can be made on examination, a De Garengeot's hernia is often only made intra-operatively due to its irregular clinical presentation.

2. Presentation of case

A 62 year old female was referred to the surgical team at her local district general hospital after seeing her GP complaining of a one week history of abdominal pain, and a swollen tender right groin. The patient was afebrile, normotensive but tachycardic at 104 beats per minute. She had normal haematological and biochemical parameters, but a raised acute phase protein level, with a CRP of 62 mg/L.

On examination she had a painful, erythematous, irreducible swelling in her right groin consistent with a strangulated femoral hernia. No imaging was arranged as this may have delayed operative intervention. The patient was scheduled on the emergency theatre list and consented for a repair of this hernia, as well as the possibility of small bowel resection (Fig. 1).

McEvedy's approach was adopted in anticipation of a strangulated section of bowel, and to allow for a possible resection. Laparoscopic approach was not considered for this emergency case. The hernia was identified, the sac opened, and the contents inspected. Inside the sac was a gangrenous vermiform appendix with some turbid free fluid (Fig. 2). A timely appendicectomy was performed, and the stump buried inside the caecum. The hernia sac was excised, and the defect repaired using nylon suture without the use of a mesh.

The patient was discharged two days after admission with a total course of five days' antibiotics. Two months after this presentation the patient was seen in a follow-up clinic, and was well with no recurrence of the hernia or any wound infection. Histology confirmed the presence of appendicitis, with the distal 30 mm of the specimen showing marked necrosis.

3. Discussion

A De Garengeot's hernia most commonly presents with a right groin mass which is often painful and erythematous [5]. Raised inflammatory markers and pyrexia are also common findings. On examination, signs of appendicitis can often be ambiguous. The displacement of the appendix into the femoral hernia can ablate any right iliac fossa peritonism that one associates with appendicitis

* Corresponding author at: 79 Covesfield, Gravesend, Kent DA11 0EG, United Kingdom.

E-mail address: thomaswhitehead-clarke@doctors.org.uk (T. Whitehead-Clarke).

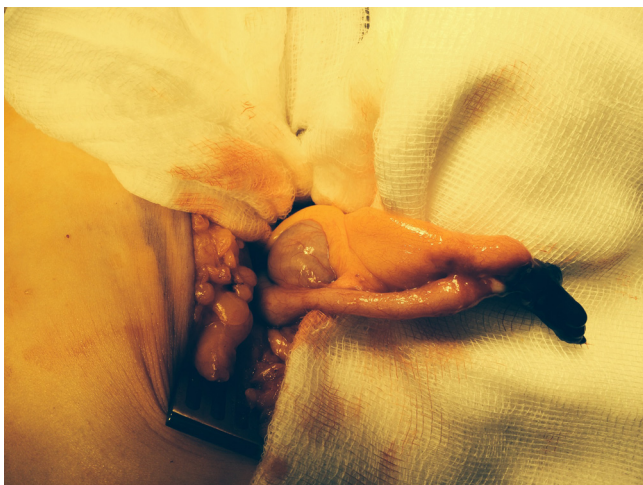

Fig. 1. The vermiform appendix delivered from McEvedy's approach.

[4]. This means this condition mostly presents like an incarcerated femoral hernia rather than an appendicitis.

Femoral hernias (and therefore De Garengeot's hernias) are more common in women, with one review showing 78% of its patients were women [5]. As with femoral hernias, the older population are also more at risk from this affliction with an average age of 71.5 years [5]. A vermiform appendix is not the only unusual structure to be found in a femoral hernia, with parts of the small intestine, colon and even stomach being reported inside the sac [6].

Two theories exist to explain why an appendix may become involved in a femoral hernia. One is that it may be secondary to an anatomically large caecum that extends down forcing the appendix into the true pelvis. Another theory surrounds abnormal intestinal rotation and caecal attachment [6,7].

Whilst femoral hernias can be diagnosed clinically, the presence of an appendix within one is very difficult to assess clinically. Computerised tomography (CT) scanning is considered an effective way to image a De Garengeot's hernia [5,6] with the use of multiplanar reformations being used to good effect in some cases [6]. Ultrasound can also be diagnostic for the condition, however lacks the accuracy of the CT scan [5].

Treatment should be with swift appendicectomy and repair of the hernia. There are currently no guidelines on whether or not a mesh is appropriate. It would seem appropriate to avoid foreign bodies such as a mesh in the presence of infection [8,5].

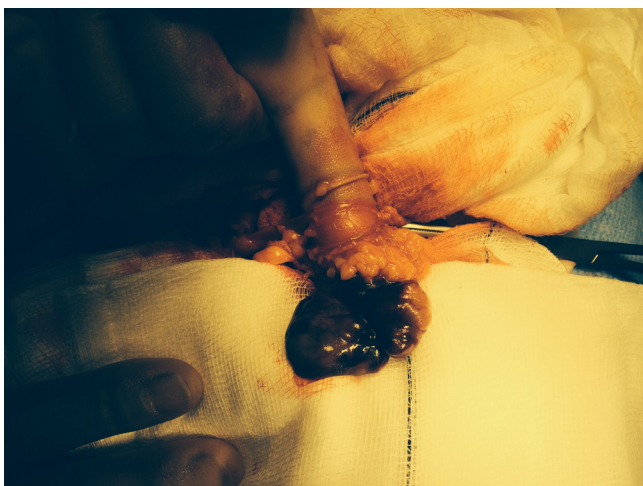


Fig. 2. The necrotic tip of the vermiform appendix.

Post-operatively, the most common complication has been documented as wound infection, infecting up to as many as 29% of patients [4]. Review of case reports suggested an average post-operative stay of just over six days. With our case we also opted to give several days antibiotics post-operatively given the gangrenous nature of the appendix.

This case report has been written in line with the CARE guidelines [9] for accurate and concise case report articles.

4. Conclusion

We present an interesting case of a De Garengeot's hernia; a rare condition with dual pathology, of which we believe there are less than 100 published cases. Our patient was managed successfully with a shorter than average hospital stay (4) and successful follow-up, free of wound infection. A single groin incision was satisfactory to repair the hernia, and undertake the appendicectomy.

Conflict of interest

We have no conflict of interest to declare.

Funding

There were no sources of funding for our case report.

Ethical approval

N/A—this was not a research study. All patient details have been anonymised.

Consent

Written informed consent was obtained from the patient for publication of this case report and accompanying images. A copy of the written consent is available for review by the Editor-in-Chief of this journal on request. No details for the patient were used, and the report is completely anonymised.

Author contribution

Thomas Whitehead-Clarke—primary author of written text. Umesh Parampalli—secondary author of written text + proofreading. Rakesh Bhardwaj—proofreading, lead consultant and approval for publication.

Research registry

N/A.

Guarantor

Thomas Whitehead-Clarke (Lead author).

Acknowledgement

There were no other contributors to this piece aside from the aforementioned authors.

References

- [1] De Garengeot R.J.C., (1731). *Traite des operations de chirurgie*, Paris, Huart.
- [2] G. Akopian, M. Alexander, de Garengeot hernia: appendicitis within a femoral hernia, *Am. Surg.* 71 (2005) 526–527.
- [3] E. Erdas, L. Sias, S. Licheri, L. Secci, S. Aresu, M. Barbossa, et al., De Garengeot Hernia with acute appendicitis, *G. Chir.* 34 (3) (2013) 86–89.

- [4] H.D. Le, S.R. Odom, A. Hsu, A. Gupta, C.J. Hauser, A combined Richter's and Garengeot's hernia, *Int. J. Surg. Case Rep.* 5 (10) (2014) 662–664.
- [5] V. Kalles, A. Mekras, D. Mekras, I. Papapanagiotou, W. Al-Harethee, G. Sotiropoulos, et al., De Garengeot's hernia a comprehensive review, *Hernia* 17 (2) (2013) 177–182.
- [6] Chang D. Fukukura, Acute appendicitis within a femoral hernia: multidetector CT findings, *Abdom. imaging* 30 (5) (2005) 620–622.
- [7] P.R. Salkade, A.Y. Chung, Y.M. Law, De Garengeot's hernia: an unusual right groin mass due to acute appendicitis in an incarcerated femoral hernia, *Hong Kong Med. J.* 18 (5) (2012) 442–445.
- [8] P. Konofaos, E. Spartalis, A. Smirnis, K. Kontzoglou, G. Kouraklis, De Garengeot's hernia in a 60 year old woman: a case report, *J. Med. Case Rep.* 30 (5) (2011) 288.
- [9] J. Gagnier, G. Kienle, D.G. Altman, D. Moher, H. Sox, D.S. Riley, CARE group, The CARE guidelines: consensus-based clinical case report guideline development, *J. Clin. Epidemiol.* 67 (1) (2013) 46–51.

Open Access

This article is published Open Access at scimedirect.com. It is distributed under the [IJSCR Supplemental terms and conditions](#), which permits unrestricted non commercial use, distribution, and reproduction in any medium, provided the original authors and source are credited.