

HUMAN GENETICS '99

Functional and Structural Brain Abnormalities Associated with a Genetic Disorder of Speech and Language

Kate E. Watkins,¹ David G. Gadian,² and Faraneh Vargha-Khadem³

¹Cognitive Neuroscience Unit, Montreal Neurological Institute, McGill University, Montreal, and ²Radiology and Physics Unit and ³Cognitive Neuroscience Unit, Institute of Child Health, University College London Medical School, London

The number of children diagnosed with developmental disorders, such as dyslexia, autism, specific language impairment, and attention deficit disorder, is increasing, as these disorders become better defined in terms of their behavioral characteristics. In many of these children, there is significant evidence for a genetic etiology. In addition to reports of families with unusually high concentrations of a particular disorder such as language impairment (Arnold 1961; Samples and Lane 1985; Hurst et al. 1990), twin studies (Bishop et al. 1995), and pedigree analyses examining the incidence of such disorders in the relatives of probands (Lewis 1992), there are genetic-linkage investigations identifying loci that cosegregate with these disorders (Grigorenko et al. 1997; Fisher et al. 1998).

It is presumed that genetic factors cause developmental cognitive disorders by influencing the development of the brain. These disorders frequently occur in the absence of a frank neurological deficit, and the nature of the underlying abnormalities in brain development is therefore intriguing. The implication of a genetic etiology is that, during neurogenesis, abnormalities may have occurred, affecting brain structure and function. The structural brain abnormalities are likely to be the result of aberrant neuronal or glial proliferation, reflected, respectively, in site-specific neuronal size and number or in degree of myelination. Such abnormalities may be detectable by morphometric analysis of the brain. Several such studies have been reported, in which, typically, postmortem methods or analysis of structural magnetic resonance imaging (MRI) scans have been used. In contrast to single-case postmortem studies, MRI analyses allow larger samples to be investigated *in vivo* along with suitable control groups.

Received June 9, 1999; accepted for publication August 31, 1999; electronically published October 8, 1999.

Address for correspondence and reprints: Dr. Kate Watkins, Cognitive Neuroscience Unit, Montreal Neurological Institute, Montreal, Quebec H3A 2B4, Canada. E-mail: kwatkins@bic.mni.mcgill.ca

This article represents the opinion of the authors and has not been peer reviewed.

© 1999 by The American Society of Human Genetics. All rights reserved.
0002-9297/1999/6505-0002\$02.00

Implicit in the notion that developmental disorders are associated with abnormal brain structure is the assumption that brain function will also be abnormal. There have been only a few functional imaging studies of developmental disorders, however, mainly because of ethical considerations arising from the use of radioisotopes as markers of cerebral blood flow. With the advent of functional MRI (fMRI), a totally noninvasive technique, it is now possible to investigate the functional brain abnormalities underlying developmental disorders in children and in appropriately matched normal control groups. These studies represent an exciting advance, since they allow both structural and functional imaging studies to be conducted longitudinally and during development. The study of the neurobiological correlates of developmental disorders should inform both behavioral models and genetic linkage analyses through identification of a neurobiological phenotype.

In this report, we review studies of brain morphometry and function in developmental language disorders and then describe our own studies, performed at the Institute of Child Health and Institute of Neurology (London), which were aimed at identification of functional and structural neurobiological correlates of an inherited disorder of speech and language. The disorder segregates as an autosomal dominant trait within a multigeneration English family, the KE family.

Background

Studies of brain morphometry were stimulated by the landmark study of Geschwind and Levitsky (1968), which provided evidence of an asymmetry in brain structure that correlated with the well-established functional asymmetry and dominance of the left hemisphere for language. These researchers measured, at autopsy, the length of the planum temporale in 100 normal brains and found it to be longer on the left in 65%, symmetrical in 25%, and shorter on the left in only 10% of the sample. The planum temporale is a region of cortex that falls within Wernicke's area, which is known to be associated with language disorders when damaged in

adulthood. On the basis of these findings, Geschwind and Levitsky proposed that a macroscopic structural feature—namely, asymmetry of the *plana temporale*—could be used as an indicator of functional specialization for language. This pattern of asymmetry has since been replicated in adults and has been found to be present in human fetuses and neonates (Witelson and Pallie 1973; Wada et al. 1975; Chi et al. 1977).

Elaborating on the significance of the asymmetry in the *plana temporale*, Galaburda et al. (1978) showed that the gross asymmetry was associated with microscopic cytoarchitectonic differences between the hemispheres. Subsequent findings, by Galaburda et al. (1985), of symmetric *plana temporale* in the brains of individuals with dyslexia provided much of the impetus for morphometric studies of developmental disorders. It is interesting that the observed symmetry in individuals with dyslexia resulted from enlargement of the right *plana temporale*, relative to that in normal brains, rather than from a reduction on the left. Galaburda (1988) suggested that this enlargement reflected anomalous brain development during the later stages of corticogenesis, potentially leading to abnormally high levels of neuronal survival and subsequent redefinition of cortical architecture.

Established and Emerging Neuroimaging Techniques

Even though the use of MRI for studies of brain morphometry has many obvious advantages over postmortem methods, attempts to replicate the postmortem asymmetry findings for the *plana temporale* have been hampered by contradictory results (Hynd et al. 1990; see Larsen et al. 1990). These contradictions may have resulted from the use of different methods of data acquisition, such as slice orientation or thickness, but they also may be due to difficulties in visualizing and measuring the *plana temporale* on MRI scans (see Westbury et al. 1999). Normal variation in anatomy can make identification of sulcal landmarks difficult. In the early MRI studies of brain morphometry, researchers circumvented the problem of defining the anatomical boundaries of small regions of interest by measuring large en bloc regions of brain. In short, this technique involves division of each hemisphere into large areas, roughly corresponding to the lobes, with the corpus callosum usually used as the major landmark to produce these divisions. This approach has been used by Filipek and colleagues in a number of studies of brain morphometry in developmental disorders (for further methodological details, see Filipek et al. 1989).

Plante and colleagues (1991) and Jernigan and colleagues (1991) have used en bloc methods to analyze structural MRI scans of children with language impairment. Abnormal perisylvian asymmetry was identified in children and their relatives with language impairment (Plante et al. 1991). Jernigan et al. (1991) also found

brain abnormalities in children with language impairment, in the form of bilateral volume reduction in the posterior perisylvian region and subcortical structures including the caudate nucleus.

As the resolution of MRI scans improves, new techniques are emerging to produce more sophisticated analyses. A number of studies have examined the normal variation in the volume and location of sulcal landmarks (Paus et al. 1996; Westbury et al. 1999). Similar analyses could be applied to studies of developmental disorders in known regions of interest.

In our study of the KE family, we used a whole-brain morphometric analysis that is completely reproducible and that does not require interactions by the user. The analysis is designed to identify regions of anatomical variation between groups of subjects who may differ with respect to disease state, sex, or age (see Paus et al. 1999). Because this method allows analysis of the whole brain, it is of particular use in guiding the investigator's attention to regions of specific interest.

Most functional neuroimaging studies of children with developmental language disorders have used single-photon-emission computed tomography (SPECT) to reveal abnormal patterns of activation during language tasks (e.g., Tzourio et al. 1994). Comparisons have been made within or between clinical populations rather than with normal control subjects (see Lou et al. 1990), because of ethical considerations concerning the use of radioisotopes in children. Another approach to investigating functional abnormalities related to developmental disorders is through studies of adults with a history of such disorders. The use of radioisotopes is permissible in these individuals with their informed consent. Even so, there are very few such studies. Paulesu et al. (1996) used positron-emission tomography (PET) to examine adults who had been diagnosed with developmental dyslexia in childhood but who were able to read at adult literacy levels. During a phonological task (rhyming), those with developmental dyslexia activated only a subset of the brain regions that were activated in control subjects. Eden et al. (1996) used fMRI to assess men with dyslexia during viewing of a moving visual stimulus. These subjects failed to show activation of an area of cortex that is associated with visual motion.

The use of fMRI in studies of children with developmental disorders will no doubt increase because of the noninvasive nature of this powerful technique. In our study of the KE family, however, we used the well-established PET approach. With fMRI we will be able to examine other family members, including the children, and to conduct longitudinal studies.

The KE Family

The KE family is a large family spanning four generations (see fig. 1). Half the members of the first three

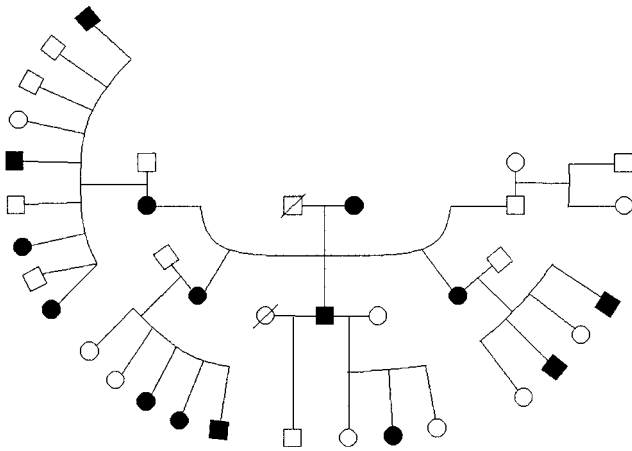


Figure 1 Pedigree of the KE family

generations are affected by a severe disorder of speech and language, which often makes their speech unintelligible. The fourth-generation children (not shown in fig. 1) were all born to unaffected parents and do not demonstrate the disorder. The affected family members of the third generation do not, at present, have any children.

Of the 15 affected members, 9 are female and 6 are male, suggesting that the disorder is not sex linked, although, without evidence of male-to-male transmission, this could not be ruled out. The initial reports by Hurst et al. (1990) and by Pembrey (1992) identified the pattern of inheritance as autosomal dominant, most likely as a result of a single-gene mutation. Fisher et al. (1998) conducted a genomewide search for linkage in the KE family and identified a locus on chromosome 7 that co-segregated with the disorder. This locus, designated SPCH1, has been localized to a 5.6-cM interval on 7q31. Genes in 7q31 that appear to be promising candidates include those for a G-protein-activated phosphoinositide-3 kinase, the interferon-related protein PC4 (which may play a role in differentiative pathways induced by nerve growth factor), Bravo/Nr-CAM (a neuronal cell-adhesion molecule), and WNT-2 (a putative signaling molecule involved in development). At this stage, however, the possibility that the KE family segregates a contiguous microdeletion that affects several genes in 7q31 cannot definitely be ruled out.

The nature of the behavioral phenotype shared by the 15 affected members of the KE family has been the subject of some debate. The initial report (Hurst et al. 1990) described a severe form of developmental verbal apraxia and summarized the main impairment as affecting the organization and coordination of high-speed movements necessary to produce intelligible speech. Subsequent reports by Gopnik and colleagues (Gopnik 1990; Gopnik and Crago 1991) focused on the linguistic deficits of the

affected family members—in particular, their deficit in the use of inflectional morphosyntactic rules (e.g., changing word endings to reflect past tense, by adding an “-ed,” or to indicate a plural, by adding an “-s”). This deficit was described as selective and led to some speculation that the KE family provides evidence for the existence of grammar genes. However, the first and later reports of the KE family (Hurst et al. 1990; Vargha-Khadem et al. 1995) indicated that the disorder is not selective to inflectional morphosyntax but, rather, affects the processing and expression of phonology and syntax as well as nonlinguistic oral praxis (i.e., the coordination and execution of movements of the face and mouth that are unrelated to speech, such as licking the lips). In addition, affected family members have significantly lower nonverbal intelligence quotients than the unaffected family members. All the studies agree that the affected family members are impaired on tests of morphosyntax, but the relationship between this impairment and the deficits in other language and cognitive domains is unclear. The crucial question is whether the full range of deficits merely co-occur or are causally related.

To address this question, we have used a discriminant function analysis to analyze the data on a number of linguistic and nonlinguistic tests. The affected family members were successfully and completely distinguished from the unaffected members by one variable: the score on a test of repetition of nonwords with complex articulation patterns. We suggest that the articulation deficit renders the production of morphological suffixes difficult, which could account for the deficit in morphosyntax previously described. Furthermore, in a developmental context, such a deficit could also give rise to impoverished language representation, which would, in turn, be reflected in impairment on many other tests of language function. It is possible that such a seemingly low-level impairment could lead to higher-order deficits in cognitive domains, such as nonverbal intelligence, which appear to be unrelated to language ability. Nevertheless, the alternative possibility that a genetic abnormality results in a more general developmental delay cannot be ruled out.

Neural Correlates of the Disorder in the KE Family

Brain Function

In our PET investigations (see Vargha-Khadem et al. 1998), we studied two affected KE family members to identify functional neurological abnormalities. We compared brain-activation patterns in two conditions: listening to and repeating words spoken over headphones versus listening to reversed speech and repeating one word: “crime.” In normal, right-handed volunteers, this test reveals the major speech and language areas of the left hemisphere (Price et al. 1996). The patterns of brain

activity seen in the two affected family members were compared with those of four normal controls. The affected family members failed to activate a number of areas in the medial wall of the left hemisphere—namely, the supplementary motor area, underlying cingulate cortex, and adjacent cortices (see fig. 2*A*)—areas that are consistently activated in control subjects. In addition, the affected family members showed significantly less activation than the controls in a region of the left primary sensorimotor cortex associated with movement of the face and mouth (see fig. 2*B*). Finally, the affected family members showed significantly more activation than the controls in the left caudate nucleus (see fig. 2*C*),

a region of the left premotor cortex extending into Broca's area and a region of the left inferior frontal cortex more anterior to Broca's area (see fig. 2*D*).

It is likely that these abnormal patterns of activation are related to the poor motor control of speech that impairs the performance of these individuals in tests of articulation, expressive language, and oral praxis.

Brain Structure

We have also used MRI scanning to examine the brain structure of affected and unaffected family members. Visual inspection of the images by a neuroradiologist did

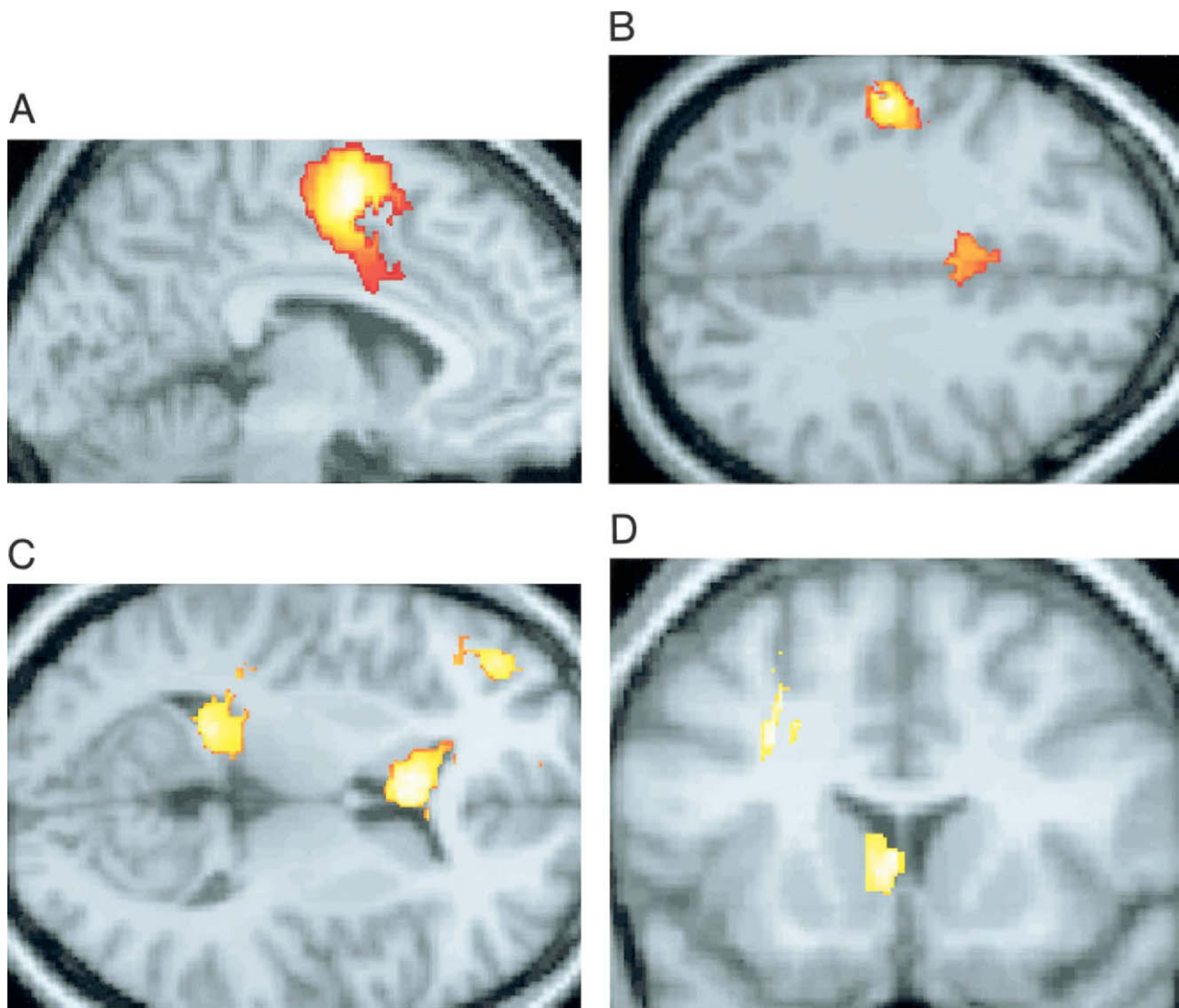


Figure 2 Results of analysis of PET data. Colored areas are regions that are either underactive (*A* and *B*) or overactive (*C* and *D*) in the affected family members, compared to the activation seen in the control subjects. *A*, Supplementary motor area and cingulate cortex. Parasagittal section through left hemisphere, 6 mm from midline. *B*, Left sensorimotor cortex and cingulate cortex. Transverse section, 36 mm above the transverse plane through the anterior commissure (AC). *C*, Left caudate nucleus (head and tail) and prefrontal cortex. Transverse section, 12 mm above the transverse plane through the AC. *D*, Left premotor cortex and caudate nucleus. Coronal section, 14 mm in front of the coronal plane through the AC. (Panels *A* and *D* reprinted, with permission, from Vargha-Khadem et al. [1998])

not reveal any overt brain abnormalities that correlate with the disorder. However, differences emerged when we applied a new method of analysis—voxel-based morphometry (by means of SPM '96 Wellcome Department of Cognitive Neurology)—to compare regional amounts of gray matter in the brains of the affected and unaffected family members. We observed differences in a number of brain regions (Vargha-Khadem et al. 1998). Affected members had significantly less gray matter than unaffected members, in the caudate nuclei bilaterally (see fig. 3A), in a region within the left medial frontal cortex

(see fig. 3B), and in the left inferior frontal cortex, dorsal to the operculum. However, they had significantly more gray matter than the unaffected family members in the putamen bilaterally (see fig. 3C), in the frontal operculum (area 44 and the anterior insula), and in the superior temporal cortex, including the planum temporale bilaterally (see fig. 3D). One of these findings, that of significantly less gray matter in the caudate nucleus of affected family members, was verified, with the use of pixel-counting methods, by direct volumetric measurement of this well-defined structure. The average volume

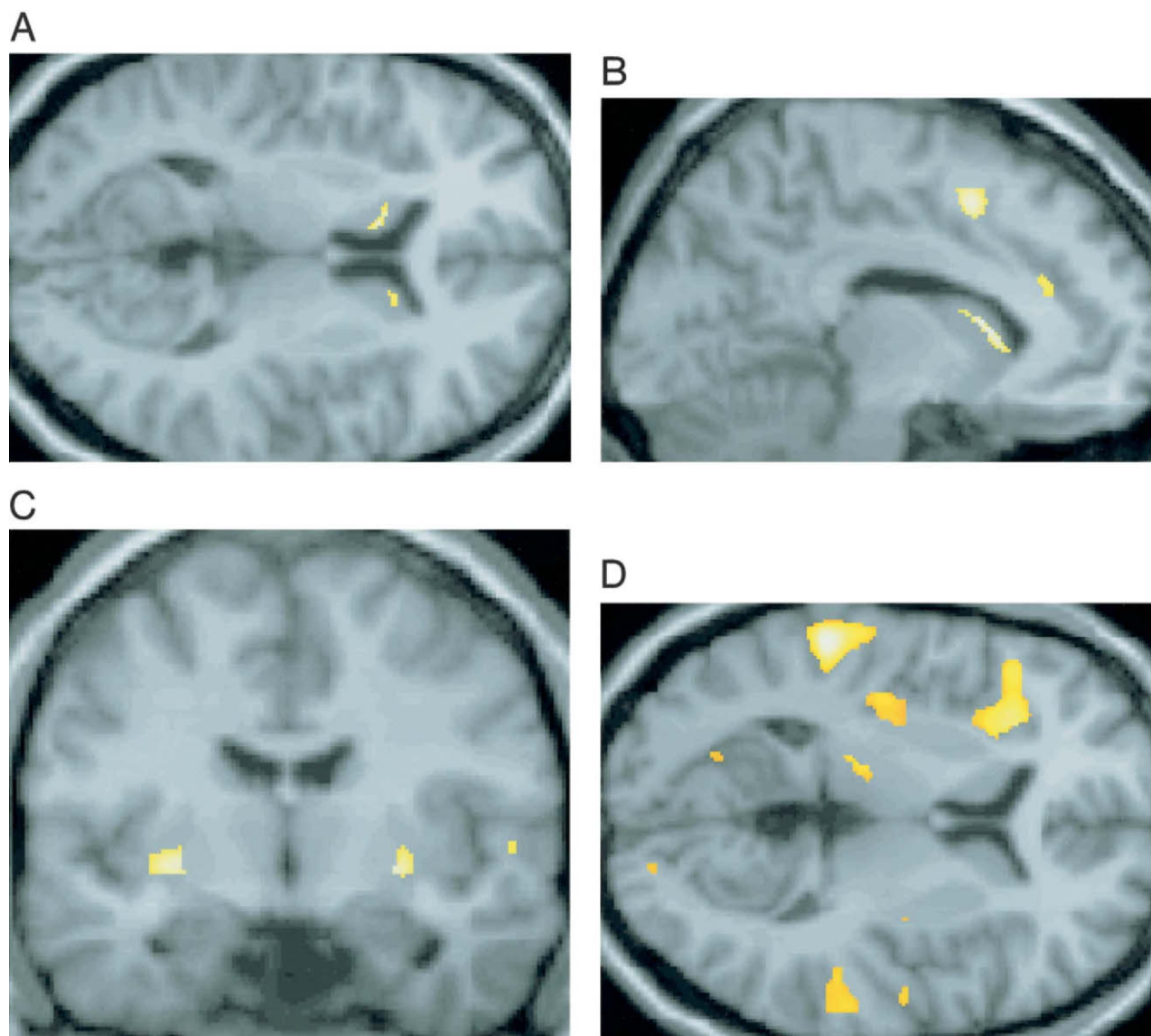


Figure 3 Results of morphometric analyses. Colored areas are regions that have either less (A and B) or more (C and D) gray matter in the affected family members compared to the unaffected. A, Left and right caudate nucleus. Transverse section, 9 mm above the transverse plane through the AC. B, Left medial frontal cortex and caudate nucleus. Parasagittal section through the left hemisphere, 10 mm from midline. C, Left and right putamen. Coronal section, 8 mm posterior to the coronal plane through the AC. D, Left inferior frontal cortex (BA45), left anterior insula, and right and left planum temporale. Transverse section, 4 mm above the transverse plane through the AC. (Panel A reprinted, with permission, from Vargha-Khadem et al. [1998])

of this nucleus in affected family members was reduced by 20% relative to that of the unaffected family members, a statistically significant difference.

These morphometric data accord well with the results from the PET study. Of particular interest was the finding that the caudate nucleus had less gray matter bilaterally in the affected family members. Importantly, the caudate nucleus was also found to be “overactive” in the PET study, as were areas within inferior frontal and sensorimotor cortices, which were also revealed to be structurally abnormal. A simple explanation for this correlation is that areas with less than the normal amount of gray matter increase neuronal activity to greater-than-normal levels to subserve function similar to that produced by the normal area. However, the general relationship between the amount of gray matter in a region and its relative activity remains to be investigated. Another possible explanation is that a behavioral impairment could result in underdevelopment of a region, thereby rendering its gray-matter volume abnormally small.

The finding that structural and functional abnormalities of the basal ganglia (caudate nucleus and putamen) are associated with developmental language disorder is corroborated by other studies. Jernigan et al. (1991) performed a morphometric analysis with MRI scans and reported that the caudate nucleus was bilaterally reduced in volume in a group of children with language impairment compared to matched controls. In addition, Tallal et al. (1994) reported bilateral damage to the head of the caudate nucleus in a 10-year-old boy with impairments in expressive language and articulation.

Pathology of the putamen and caudate nuclei has also been associated with aphasic symptoms in adult patients (Pickett et al. 1998). Some patients with this combined pathology also show oral and verbal dyspraxias (e.g., Aglioti et al. 1996). Further evidence of basal ganglia involvement—in particular, of the putamen—in the articulation and motor control of speech comes from functional imaging studies. In normal healthy volunteers who were bilingual but had acquired their second language at >5 years of age, Klein et al. (1994) reported increased PET activation of the left putamen during repetition in the second language and during translation from the first language to the second. These authors attributed this increased activation to the increased articulatory demands—in particular, motor timing of word repetition and word generation in the second language compared to the first.

On the basis of these findings, we suggest that the genetic abnormality in the KE family might directly and selectively affect the development of the caudate nucleus or, perhaps, that of the basal ganglia more generally, resulting in both structural and functional abnormalities of the caudate nuclei bilaterally. The development of

cortical areas that project to the caudate nucleus and the thalamocortical loops that originate in the caudate nucleus would also be affected by this abnormal development. This, in turn, might prevent normal development of motor learning specifically related to articulation, thereby giving rise to the range of deficits seen in the behavioral profile of the affected family members. Impaired language representation might itself also give rise ultimately to a restriction in nonverbal cognitive development.

Our studies of the KE family are ongoing with respect to all aspects of the research described. The genetic analyses are aimed at isolating the SPCH1 locus. In the behavioral and cognitive studies, we hope to further elucidate the developmental interactions between different cognitive processes. Finally, in the imaging studies, we aim to refine and extend our analyses and to validate the results reported in this study with more detailed studies of specific regions of the brain.

Acknowledgments

We are indebted to the KE family for their continued cooperation with our research program. We thank our collaborators at the Wellcome Department of Cognitive Neurology, Institute of Neurology, London, for assistance with the PET study and morphometric analyses, and our colleagues in the Cognitive Neuroscience Unit and Radiology and Physics Unit at the Institute of Child Health, London, for assistance with data collection and analysis. We thank Drs. Mortimer Mishkin, Marcus Pembrey, Tomáš Paus, and Gabriel Leonard, for useful discussion and for comments on the manuscript.

References

- Aglioti S, Beltramello A, Girardi F, Fabbro F (1996) Neuro-linguistic and follow-up study of an unusual pattern of recovery from bilingual subcortical aphasia. *Brain* 119:1551–1564
- Arnold GE (1961) The genetic background of developmental language disorders. *Folia Phoniatr* 13:246–254
- Bishop DV, North T, Donlan C (1995) Genetic basis of specific language impairment: evidence from a twin study. *Dev Med Child Neurol* 37:56–71
- Chi JG, Dooling EC, Gilles FH (1977) Left-right asymmetries of the temporal speech areas of the human fetus. *Arch Neurol* 34:346–348
- Eden GF, VanMeter JW, Rumsey JM, Maisog JM, Woods RP, Zeffiro TA (1996) Abnormal processing of visual motion in dyslexia revealed by functional brain imaging. *Nature* 382:66–69
- Filipek PA, Kennedy DN, Caviness VS Jr, Rossnick SL, Spraggins TA, Starewicz PM (1989) Magnetic resonance imaging-based brain morphometry: development and application to normal subjects. *Ann Neurol* 25:61–67
- Fisher SE, Vargha-Khadem F, Watkins KE, Monaco AP, Pembrey ME (1998) Localisation of a gene implicated in a severe speech and language disorder. *Nat Genet* 18:168–170

- Galaburda AM (1988) The pathogenesis of childhood dyslexia. *Res Publ Assoc Res Nerv Ment Dis* 66:127–137
- Galaburda AM, Sanides F, Geschwind N (1978) Human brain: cytoarchitectonic left-right asymmetries in the temporal speech region. *Arch Neurol* 35:812–817
- Galaburda AM, Sherman GF, Rosen GD, Aboitiz F, Geschwind N (1985) Developmental dyslexia: four consecutive patients with cortical anomalies. *Ann Neurol* 18:222–233
- Geschwind N, Levitsky W (1968) Human brain: left-right asymmetries in temporal speech region. *Science* 161:186–187
- Gopnik M (1990) Feature-blind grammar and dysphagia. *Nature* 344:715
- Gopnik M, Crago MB (1991) Familial aggregation of a developmental language disorder. *Cognition* 39:1–50
- Grigorenko EL, Wood FB, Meyer MS, Hart LA, Speed WC, Shuster A, Pauls DL (1997) Susceptibility loci for distinct components of developmental dyslexia on chromosomes 6 and 15. *Am J Hum Genet* 60:27–39
- Hurst JA, Baraitser M, Auger E, Graham F, Norell S (1990) An extended family with a dominantly inherited speech disorder. *Dev Med Child Neurol* 32:347–355
- Hynd GW, Semrud Clikeman M, Lorys AR, Novey ES, Eliopoulos D (1990) Brain morphology in developmental dyslexia and attention deficit disorder/hyperactivity. *Arch Neurol* 47:919–926
- Jernigan TL, Hesselink JR, Sowell E, Tallal PA (1991) Cerebral structure on magnetic resonance imaging in language- and learning-impaired children. *Arch Neurol* 48:539–545
- Klein D, Zatorre RJ, Milner B, Meyer E, Evans AC (1994) Left putaminal activation when speaking a second language: evidence from PET. *Neuroreport* 5:2295–2297
- Larsen JP, Høien T, Lundberg I, Odegaard H (1990) MRI evaluation of the size and symmetry of the planum temporale in adolescents with developmental dyslexia. *Brain Lang* 39:289–301
- Lewis BA (1992) Pedigree analysis of children with phonology disorders. *J Learn Disabil* 25:586–597
- Lou HC, Henriksen L, Bruhn P (1990) Focal cerebral dysfunction in developmental learning disabilities. *Lancet* 335:8–11
- Paulesu E, Frith U, Snowling M, Gallagher A, Morton J, Frackowiak RS, Frith CD (1996) Is developmental dyslexia a disconnection syndrome? Evidence from PET scanning. *Brain* 119:143–157
- Paus T, Otaky N, Caramanos Z, MacDonald D, Zijdenbos A, D'Avirro D, Gutmans D, et al (1996) In vivo morphometry of the intrasulcal gray matter in the human cingulate, paracingulate, and superior-rostral sulci: hemispheric asymmetries, gender differences and probability maps. *J Comp Neurol* 376:664–673
- Paus T, Zijdenbos A, Worsley K, Collins DL, Blumenthal J, Giedd JN, Rapoport JL, et al (1999) Structural maturation of neural pathways in children and adolescents: in vivo study. *Science* 283:1908–1911
- Pembrey ME (1992) Genetics and language disorder. In: Fletcher P, Hall D (eds) *Specific speech and language disorders in children: correlates, characteristics and outcomes*. Whurr, London, pp 51–62
- Pickett ER, Kuniholm E, Protopapas A, Friedman J, Lieberman P (1998) Selective speech motor syntax and cognitive deficits associated with bilateral damage to the putamen and the head of the caudate nucleus: a case study. *Neuropsychologia* 36:173–188
- Plante E, Swisher L, Vance R, Rapcsak S (1991) MRI findings in boys with specific language impairment. *Brain Lang* 41:52–66
- Price CJ, Wise RJ, Warburton EA, Moore CJ, Howard D, Patterson K, Frackowiak RS, et al (1996) Hearing and saying: the functional neuro-anatomy of auditory word processing. *Brain* 119:919–931
- Samples JM, Lane VW (1985) Genetic possibilities in six siblings with specific language learning disorders. *ASHA* 27:27–32
- Tallal P, Jernigan T, Trauner D (1994) Developmental bilateral damage to the head of the caudate nuclei: implications for speech-language pathology. *J Med Speech-Lang Pathol* 2:23–28
- Tzourio N, Heim A, Zilbovicius M, Gerard C, Mazoyer BM (1994) Abnormal regional CBF response in left hemisphere of dysphasic children during a language task. *Pediatr Neurol* 10:20–26
- Vargha-Khadem F, Watkins K, Alcock K, Fletcher P, Passingham R (1995) Praxic and nonverbal cognitive deficits in a large family with a genetically transmitted speech and language disorder. *Proc Natl Acad Sci USA* 92:930–933
- Vargha-Khadem F, Watkins KE, Price CJ, Ashburner J, Alcock K, Connelly A, Frackowiak RSJ, et al (1998) Neural basis of an inherited speech and language disorder. *Proc Natl Acad Sci USA* 95:12695–12700
- Wada JA, Clarke R, Hamm A (1975) Cerebral hemispheric asymmetry in humans: cortical speech zones in 100 adults and 100 infant brains. *Arch Neurol* 32:239–246
- Westbury CF, Zatorre RJ, Evans AC (1999) Quantifying variability in the planum temporale: a probability map. *Cereb Cortex* 9:392–405
- Witelson SF, Pallie W (1973) Left hemisphere specialization for language in the newborn. Neuroanatomical evidence of asymmetry. *Brain* 96:641–646