


Contents lists available at [ScienceDirect](http://ScienceDirect.com)

Journal of Orthopaedics, Trauma and Rehabilitation

Journal homepages: www.e-jotr.com & www.ejotr.org

Case Report

Congenital Thenar Hypoplasia with Absent Radial Artery: A Case Report



先天性大魚際肌發育不全和缺失橈動脈 - 病例報告

Wan Keith Hay-Man*, Pang Ivan C.H.

Department of Orthopaedics and Traumatology, Kwong Wah Hospital, Kowloon, Hong Kong Special Administrative Region

ARTICLE INFO

Article history:

Received 9 April 2013

Received in revised form

22 July 2013

Accepted 26 July 2013

Keywords:

Cavanagh syndrome

paediatric orthopaedics

congenital thenar hypoplasia

radial artery

ABSTRACT

The thenar eminence is made up of the intrinsic muscles of the hand that are responsible for complex movement and finite motor functions of the hand. The wasting of these muscles can be associated with various clinical conditions. Cavanagh syndrome is a rare, isolated congenital thenar hypoplasia with characteristic clinical, radiological, and electrophysiological features. Congenital absence of the radial artery is a rare anatomic variant. We report a case of a boy with isolated right-sided congenital thenar hypoplasia meeting the clinical and radiological characteristics of Cavanagh syndrome with concurrent absence of the right radial artery.

中文摘要

大魚際是由手部內附肌組成的，負責複雜的手部運動和細緻的活動功能。多種疾病可以引致這些肌肉的發育不全。卡瓦納綜合症是一種罕見的，先天性單一魚際肌發育不全的疾病，具有臨床上，造影上和電生理上的特徵。先天性缺失橈動脈

動脈是當一種罕見的解剖變異。我們報告了一個患有卡瓦納綜合症的男孩，同時有先天性缺失右橈動脈的病例。

Introduction

Congenital abnormality of the thenar muscle is not commonly encountered in our daily practice and such condition can be associated with numerous clinical conditions that warrant detailed investigations and managements.

We present an unusual case of congenital thenar hypoplasia with absent radial artery on the ipsilateral side. This case highlights that proper correlation of clinical and radiological findings could make a diagnosis of such a rare clinical syndrome.

Case report

H.L. was first presented to us at the age of 2 months and noticed to have radial deviation of the right wrist. He was subsequently followed-up at our clinic for more than 1 year and was noticed to have a reduced muscle bulk of the right thenar eminence when compared to the left. He did not complain of any pain in his right

hand. He was noticed to have a weaker gripping function with his right hand. His right thumb abduction was weaker when compared to the left thumb ([Figure 1](#)). The right thumb carpometacarpal joint and interphalangeal joint were stable. The metacarpophalangeal joint (MCPJ) was unstable. The right ulnar collateral ligament of the MCPJ was unstable. There was mild narrowing of the right first web space. Sensation was intact on both hands. Neurological examination including tone, reflexes, and cranial nerves was within the normal range for his age. He did not have any dysmorphic features or any skeletal or spinal deformity. He did not have any features suggestive of hemiparesis. His right radial pulse was absent. The rest of the cardiovascular examination including the peripheral pulses was normal.

H.L. was born at term with normal spontaneous delivery to nonconsanguineous Chinese parents. The perinatal period was unremarkable and apart from a brief period of neonatal jaundice he enjoyed good past health. His immunizations, including polio, were up-to-date. There was no family history of any congenital anomaly.

Doppler ultrasonography was done and showed absence of the right radial artery. Radiography revealed hypoplasia of the right first metacarpal with normal carpal, phalangeal, and metacarpal

* Corresponding author. E-mail: keithayman@hotmail.com.

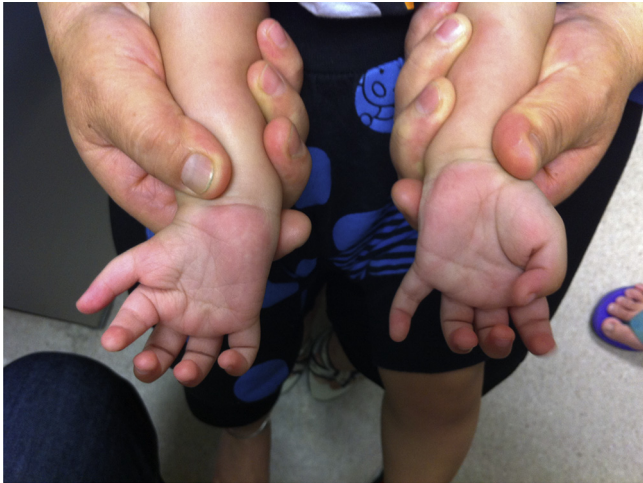

Figure 1. A clinical photo of H.L. showing wasting of the right thenar eminence.

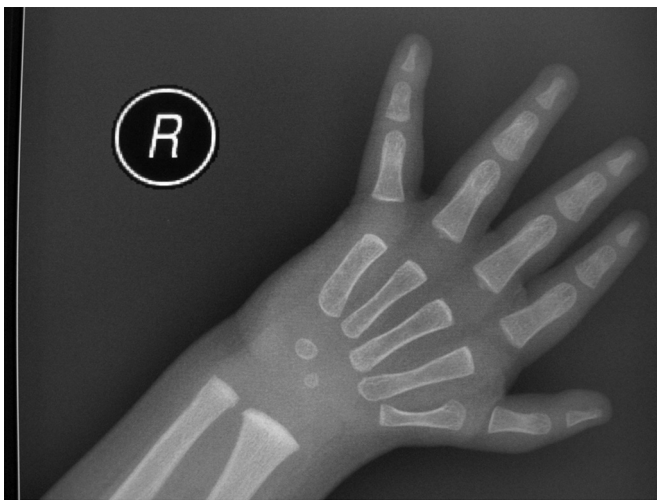


Figure 2. Radiography of the right hand of H.L. showing hypoplasia of the right first metacarpal shaft.

configuration of the second to fifth digits (Figure 2). The rest of the forearm including the radius, ulna, and distal radioulnar joints were normal and there was no vertebral anomaly detected. The radiological findings were in keeping with congenital thenar hypoplasia.

Discussion

According to the classification for congenital anomalies of the hand by the International Federation of Societies for Surgery of the Hand, congenital thenar hypoplasia belongs to type 5 congenital hand anomaly.¹ Blauth et al^{2,3} further classified thumb hypoplasia into five grades of severity. Hypoplasia of the metacarpal shaft with thenar muscle hypoplasia, together with narrowing of the web

space and MCPJ instability, as in our case, belongs to grade IIIB severity.

Cavanagh syndrome is a rare anomaly of the upper limb with unilateral or bilateral hypoplasia of the thenar eminence with typical clinical, radiological, and electrophysiological features.⁴ Cavanagh et al⁴ in 1979 first reported a series of five patients with thenar hypoplasia and described their characteristic clinical, radiological, and electrophysiological features. Our patient fulfilled the clinical and radiological features of Cavanagh's syndrome. Ideally an electrophysiological study including the nerve conduction velocity of the median nerve should be performed but it was not available for our case due to the technical difficulty of performing a nerve conduction velocity on a young toddler (H.L. was aged 15 months at the time of reporting).

Apart from its characteristic clinical features, thenar hypoplasia may be associated with other congenital anomalies. It may be associated with cardiac anomalies as in Holt–Oram syndrome, Duane anomaly of the eyes and deafness as in Okihiro syndrome or Duane-radial ray syndrome, haematological problems as in Fanconi pancytopenia, or as part of VACTERL association. Vascular malformations have been reported in Okihiro syndrome.^{5–7}

Fallon et al⁸ presented a case of Cavanagh's syndrome with concurrent absent radial artery in the UK. Apart from that, we are not aware of any report of concurrence of Cavanagh syndrome and absent radial artery in the literature. Lee et al⁹ speculated that the thenar hypoplasia may be due aberrant radial artery.

In conclusion, we report the first case of Cavanagh syndrome with ipsilateral absence of the radial artery in Asia. We suggest that patients with Cavanagh syndrome should be examined carefully to look for other congenital anomalies. We will closely follow-up the patient in our case to observe for any functional problem as he grows up.

Conflicts of interest

The authors declare that they have no financial or non-financial conflicts of interest related to the subject matter or materials discussed in the manuscript.

References

1. Tay SC, Moran SL, Shin AY, et al. The hypoplastic thumb. *J Am Acad Orthop Surg* 2006;**14**:354–6.
2. Blauth W. Der hypoplastische Daumen. *Arch Orthop Unfall Chir* 1967;**62**:225–46.
3. Blauth W, Schneider-Sickert F. In: *Congenital deformities of the hand: an atlas of their surgical treatment*. Berlin: Springer-Verlag; 1981. Numerical variations; p. 120–1.
4. Cavanagh NPC, Yates DAH, Sutcliffe J. Thenar hypoplasia with associated radiologic abnormalities. *Muscle Nerve* 1979;**2**:431–6.
5. Sonel B, Senbil N, Yavus Gurer YK, et al. Cavanagh's syndrome (congenital thenar hypoplasia). *J Child Neurol* 2002;**17**:51–4.
6. Hayes A, Costa T, Polomeno RC. The Okihiro syndrome of Duane anomaly, radial ray abnormalities, and deafness. *Am J Med Genet* 1984;**22**:273–80.
7. Okihiro MM, Tasaki T, Nakano KK, et al. Duane syndrome and congenital upper limb anomalies. *Arch Neurol* 1997;**34**:174–9.
8. Fallon P, Fernandez D, Gupta S. Congenital thenar hypoplasia with absent radial artery—a case report. *Eur J Paediatr Neurol* 2009;**13**:277–9.
9. Lee WT, Wang PJ, Young C, et al. Thenar hypoplasia in Klippel–Feil syndrome due to aberrant radial artery. *Paediatr Neurol* 1995;**13**:343–5.