




ELSEVIER

Contents lists available at [ScienceDirect](http://ScienceDirect)

## Urology Case Reports

journal homepage: [www.elsevier.com/locate/eucr](http://www.elsevier.com/locate/eucr)

## Trauma and Reconstruction

## Ureteric Obstruction Caused by a Migrated Intrauterine Device

Xuesong Yang<sup>a</sup>, Xi Duan<sup>b</sup>, Tao Wu<sup>a,\*</sup><sup>a</sup> Department of Urology, Affiliated Hospital of North Sichuan Medical College, Nanchong, China<sup>b</sup> Department of Dermatovenereology, Affiliated Hospital of North Sichuan Medical College, Nanchong, China

## ARTICLE INFO

## Article history:

Received 8 November 2016

Accepted 9 November 2016

## Keywords:

Ureteric obstruction  
Intrauterine device  
Hydronephrosis

## ABSTRACT

We present an extremely rare case of ureteric obstruction caused by a migrated intrauterine device. A 36-year-old female with complaints of almost 10 months left flank pain presented to our hospital. She used an IUD for contraception for 6 months after the birth of her first child. The IUD was not visible then. Ultrasonography (US) revealed that left severe hydronephrosis and upper ureterectasis. Pelvic computed tomography (CT) found that IUD was located very close to the lower ureter which was adjacent to the third anatomize physiological narrow. Laparoscopy was performed to remove the migrated IUD. After 5 months of surgery, left hydronephrosis was exacerbated. This time we chose to perform the ureterocystostomy to relieve the hydronephrosis. We reported this rare case to remind that we must keep alert to the loss of the IUD to prevent it may cause severe injury of the nearby organs. IUD must be carefully researched for possible perforation of the uterus and migration to the pelvic organs.

© 2016 The Authors. Published by Elsevier Inc. This is an open access article under the CC BY-NC-ND license (<http://creativecommons.org/licenses/by-nc-nd/4.0/>).

## Introduction

Uterine perforation remains the most serious complication of intrauterine devices (IUDs) that was first described in 1933 by Murphy.<sup>1</sup> The incidence of uterine perforation has been reported to be between 0.05% and 0.13%.<sup>2, 3</sup> Perforation may be asymptomatic or may cause pain, abnormal bleeding, bowel or bladder perforation, or fistula formation.<sup>3</sup> The most common migration of IUD is into the bladder in the urinary system. However, migration of IUD to the ureter and it caused ureteric obstruction is extremely rare.

## Case report

A 36-year-old women with complaints of almost 10 months left flank pain presented to our hospital. She used an IUD for contraception for 6 months after the birth of her first child in 2006. When she went to hospital to ask to remove the IUD, there was no IUD found in uterus in 2013. Then she got pregnancy and gave birth to her second child without complications. The IUD was not visible on gynecologic examination and transvaginal ultrasonography by the gynecologist failed to detect the IUD. So it was assumed that it had fallen out.

Physical examination revealed no pathological findings. Ultrasonography (US) revealed that left severe hydronephrosis and

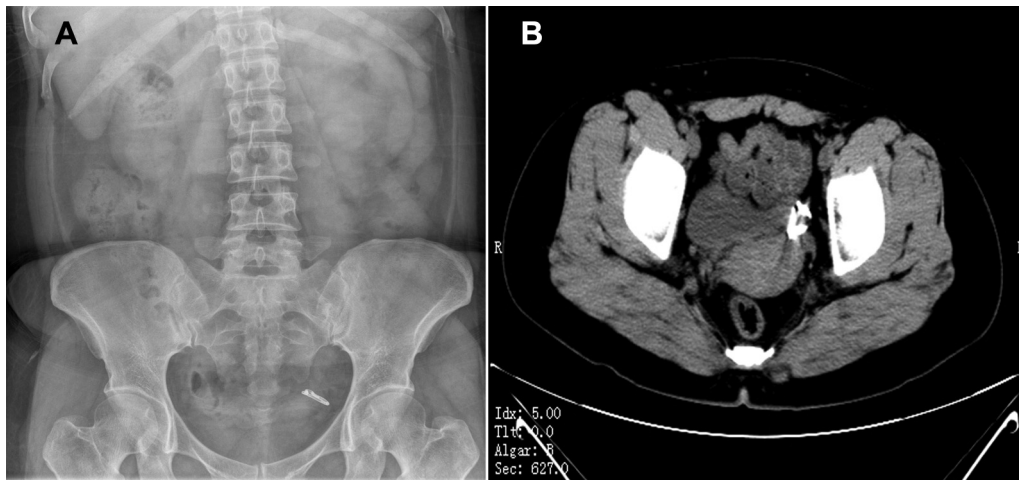
upper ureterectasis. Abdominal X-ray (KUB) showed there was an IUD in the left side of pelvic cavity (Fig. 1A). Pelvic computed tomography (CT) found that IUD was located very close to the lower ureter which was adjacent to the third anatomize physiological narrow (Fig. 1B). Before the surgery, the double-J stent was placed into the left ureter. Laparoscopy was performed to identify the relationship between the migrated IUD and adjacent anatomic structures in the pelvic cavity. The IUD was embedded in a dense adhesion band composed of the round ligament of uterus and left pelvic ureter (Fig. 2A). The lesion position of left ureter seemed stiff and distorted. Then we isolated the IUD and remove it (Fig. 2B). Three months later the double-J stent was took out from the left ureter. After 2 months, the patient presented to our hospital again with left flank pain. The ultrasonography and CT scan showed left hydronephrosis was exacerbated. This time we chose to perform the ureterocystostomy. After 6 months follow-up, the patient had no left flank painful symptom and the left hydronephrosis had no exacerbation.

## Discussion

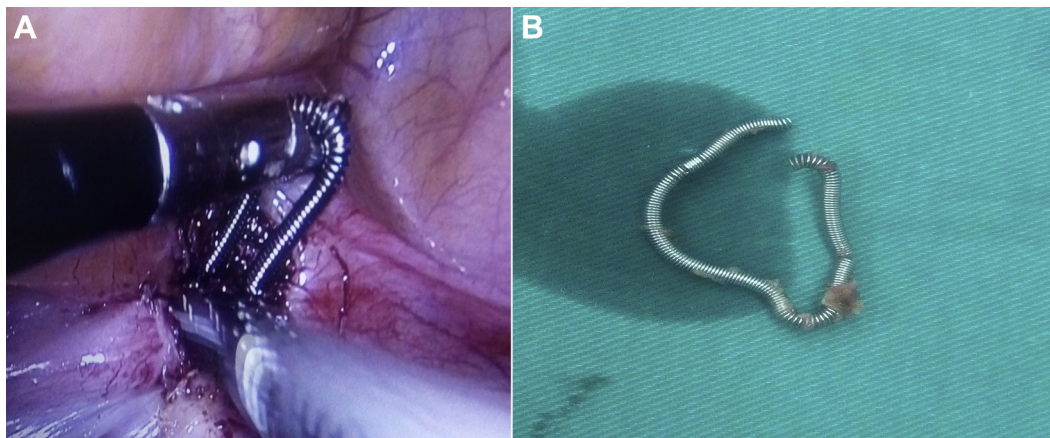
Intrauterine device is an accepted and popular worldwide contraceptive instrument especially in China. Uterine perforation and migration of the IUD into abdominal or pelvic organs is a major complication of IUD insertion.<sup>4</sup> Most uterine perforations are asymptomatic and therefore unrecognized.<sup>5</sup> The process of migration is uncommon and may occur as a result of repetitive

\* Corresponding author. Fax: +86 8172262409.

E-mail address: [wootao@163.com](mailto:wootao@163.com) (T. Wu).



**Figure 1.** (A) Abdominal X-ray (KUB) showed there was an IUD in the left side of pelvic cavity. (B) Pelvic computed tomography (CT) found that IUD was located very close to the lower ureter which was adjacent to the third anatomize physiological narrow.



**Figure 2.** (A) The IUD was embedded in a dense adhesion band composed of the round ligament of uterus and left pelvic ureter. The lesion position of left ureter seemed stiff and distorted. (B) The IUD was isolated and removed.

reactive uterine contraction. It is often asymptomatic, but may be associated with vague pelvic or abdominal pain.<sup>6</sup> Studies suggest that up to 15% of perforated IUDs may cause injury to surrounding organs, most frequently the bowel.<sup>7</sup> Several mechanisms can explain the spontaneous migration of IUDs, including overlooked iatrogenic uterine perforation, spontaneous uterine contraction, involuntary bladder contraction, gut peristalsis, and peritoneal fluid movement.<sup>8</sup> Diagnosis is achieved by gynecological examination, ultrasonography and abdominal X-ray. However, CT scan provided precise information on the abdominal migration of the IUD as well as its close relation to the adjacent tissues and viscera.<sup>6, 9</sup> With advances in laparoscopy, these situations are being increasingly managed with minimally invasive techniques. If surgery is contemplated, laparoscopic removal is the advocated method and is the first line of treatment in patients with a suspected migrated IUD.<sup>6</sup> In this case, we took out the IUD by laparoscopy. Although a double-J stent was placed into her ureter to prevent. We didn't consider that IUD could cause severe damage to ureter. So, when the left hydronephrosis was exacerbated, ureterocystostomy was performed.

IUD migrated to the ureter and caused the ureteric obstruction is very rare. There is none of case reported after reviewed in the literature. The migration of IUD oppress the ureter and caused very serious injury to it. This kind of foreign object can cause inflammation, fibrosis, and even ischemic necrosis of the ureter. In the light of our findings, the ureterocystostomy may be a better option to relieve the ureteric obstruction by migration of IUD. We reported this rare case to remind that we must keep alert to the loss of the IUD to prevent it may cause severe injury of the nearby organs. IUD must be carefully researched for possible perforation of the uterus and migration to the pelvic organs.

#### Conflict of interest

None.

#### Acknowledgement

Tao Wu has received grant from Natural Science Foundation of Sichuan Provincial Department of Education (16ZB0227).

## References

1. Murphy M. Migration of a Graefenberg ring. *Lancet*. 1933;222:1369–1370.
2. Arslan A, Kanat-Pektas M, Yesilyurt H, Bilge U. Colon penetration by a copper intrauterine device: A case report with literature review. *Arch Gynecol obstetrics*. 2009;279:395–397.
3. Kho KA, Chamsy DJ. Perforated intraperitoneal intrauterine contraceptive devices: Diagnosis, management, and clinical outcomes. *J minimally invasive Gynecol*. 2014;21:596–601.
4. Nitke S, Rabinerson D, Dekel A, et al. Lost levonorgestrel IUD: Diagnosis and therapy. *Contraception*. 2004;69:289–293.
5. Zeino MY, Wietfeldt ED, Advani V, et al. Laparoscopic removal of a copper intrauterine device from the sigmoid colon. *JSLS*. 2011;15:568–570.
6. Meshikhes AW, El-Tair M, Al-Zahir AA. Laparoscopic removal of a migrated intrauterine contraceptive device. *J Obstet Gynaecol J Inst Obstet Gynaecol*. 2010;30:317–319.
7. Zakin D, Stern WZ, Rosenblatt R. Complete and partial uterine perforation and embedding following insertion of intrauterine devices. I. Classification, complications, mechanism, incidence, and missing string. *Obstet Gynecol Surv*. 1981;36:335.
8. Shin DG, Kim TN, Lee W. Intrauterine device embedded into the bladder wall with stone formation: Laparoscopic removal is a minimally invasive alternative to open surgery. *Int Urogynecol J*. 2012;23:1129–1131.
9. Sirikci A, Sarica K, Bayram M. Ureteral displacement due to a migrated intrauterine contraceptive device. *Urologia Internationalis*. 2000;65:179–180.