



Traumatic oesophageal perforation due to haematoma



Christian Grønhøj Larsen^{a,*}, Bodil Brandt^b

^a Department of Oto-rhinolaryngology, Head and Neck Surgery and Audiology, University Hospital Rigshospitalet, Blegdamsvej 9, Copenhagen DK-2100, Denmark

^b Department of Cardiothoracic Surgery, University Hospital Rigshospitalet, Blegdamsvej 9, Copenhagen DK-2100, Denmark

ARTICLE INFO

Article history:

Received 21 October 2013

Received in revised form 26 February 2014

Accepted 5 April 2014

Available online 12 August 2014

Keywords:

Trauma

Warfarin

Oesophageal perforation

Oesophageal haematoma

ABSTRACT

INTRODUCTION: Traumatic oesophageal perforation is a rare, life-threatening emergency that requires early recognition and prompt surgical management.

PRESENTATION OF CASE: We present an unusual case of a patient on warfarin treatment developed an intramural oesophageal haematoma following blunt thoracic trauma leading to perforation on the 18th day.

DISCUSSION: In treatment of oesophageal haematoma in patients on vitamin-K antagonists, strict control of the International Normalized Ratio (INR) is essential along with total parenteral nutrition therapy and refrainment through nasogastric tubes. Three explanations postulated to be the cause for late perforation which might be due to esophageal wall ischemia from pressure built up between the hematoma, azygos vein and the lower part of thoracic trachea; or could be an immediate rupture walled-off until the patient became symptomatic; or the intramural hematoma gradually lysed and causing late perforation.

CONCLUSION: Although extremely rare, an oesophageal haematoma and late complications must be considered in patients on anti-coagulant therapy following blunt thoracic trauma and complaining only of chest pain.

© 2014 The Authors. Published by Elsevier Ltd. on behalf of Surgical Associates Ltd. This is an open access article under the CC BY-NC-ND license (<http://creativecommons.org/licenses/by-nc-nd/3.0/>).

1. Background

Oesophageal perforations are associated with high morbidity and mortality, predominantly as a result of a mediastinal leakage frequently leading to septic shock. We report a patient on warfarin therapy presenting an intramural, intrathoracic oesophageal haematoma prior to oesophagus perforation; a condition that to our knowledge is not previously reported. In our patient, an initial conservative approach was used in managing the haematoma and once perforated prompt surgical intervention was initiated. We wish to review the current approach on traumatic esophageal perforation and management.

2. Case

A 84-year-old women presented to the emergency room after she slipped and fell causing blunt traumas to the chest and face. She was conscious, hemodynamically stable and had normal blood counts besides a low albumin of 34 g/l (34–45 g/l). Her initial complaint was chest pain. The patient was on warfarin treatment due to atrial fibrillation and a history of pulmonary embolisms, and suffered furthermore from recurrent urinary tract infections and

pulmonary fibrosis. Initial Computed Tomography (CT) revealed a 4 cm × 6 cm × 15 cm paraoesophageal haematoma located in the superior and posterior mediastinum (Fig. 1a and b). Anti-coagulants were discontinued on admission. Initially the haematoma was treated conservatively but during the course of hospitalization the patient developed increasing difficulty swallowing and on the 18th day, the patient's condition rapidly deteriorated with fever, tachycardia, acidosis and leukocytosis. An immediate CT scan showed mediastinal leakage corresponding the known location of the haematoma (Fig. 2). Due to mediastinal leakage and unknown consequences of stent-treating a haematoma of this size, a right-sided muscle sparing posterolateral thoracotomy was performed. This revealed no intra- or extramural necrosis but an extremely tense haematoma and further confirmed a 3 cm longitudinal oesophageal perforation. The perforation was directly sutured; no reinforcements were applied. Until recognition of the perforation the patient was on proton pump inhibitors and soft diet, and during the post-op stay antibiotics and parenteral nutrition. The patient began full diet 10 days prior to discharge. Due to a complicated post-op stay with fungal and bacterial infection the patient was discharged on the 49th day to a rehabilitation centre.

3. Discussion

Oesophageal perforations are well known to bear severe mortality and morbidity.² We report an intramural, intrathoracic esophageal

* Corresponding author. Tel.: +45 26276374.

E-mail address: c.gronhoj@gmail.com (C. Grønhøj Larsen).

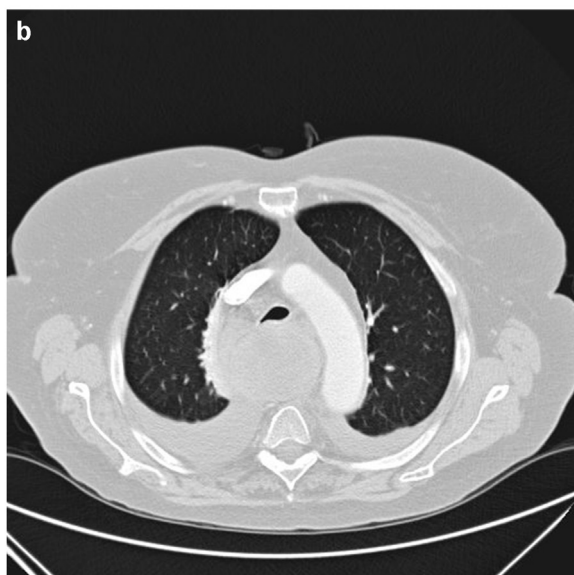
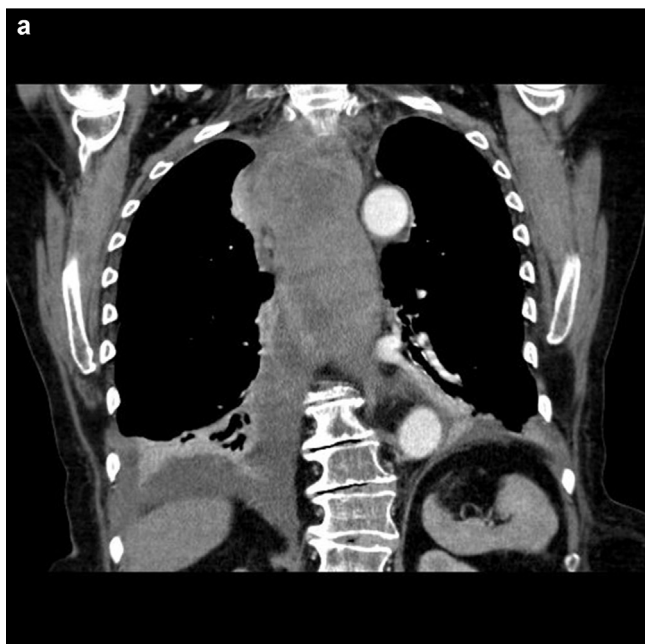


Fig. 1. (a) 4 cm × 6 cm × 15 cm paraoesophageal haematoma and right-sided moderate haemothorax. (b) 4 cm × 6 cm × 15 cm paraoesophageal haematoma.

haematoma with late rupture as a result of blunt trauma to the chest. Earlier cases describe intramural small bowel haematomas in patients using warfarin^{3,4} but our case is extremely rare. Our patient's single complaint was chest pain and although anticoagulant therapy was discontinued, late complications to haematomas are possible. Likely, the perforation might be due to ischemia from the pressure built up between the haematoma, vena azygos and the distal trachea; or the oesophageal rupture was immediate present after the trauma and the haematoma walled it off until the patient became symptomatic. Thirdly, the haematoma could gradually have lysed allowing the late perforation.

Early diagnosis and management of oesophageal perforation is difficult but imperial in reducing morbidity and mortality.^{5,6} Whether surgical or conservative treatment is indicated depends mainly on the general health of the patient, time elapsed and the size of the perforation. Thoracic oesophageal perforations are usually differentiated in those contained within the mediastinum and those noncontained that drain into the pleural space as with our

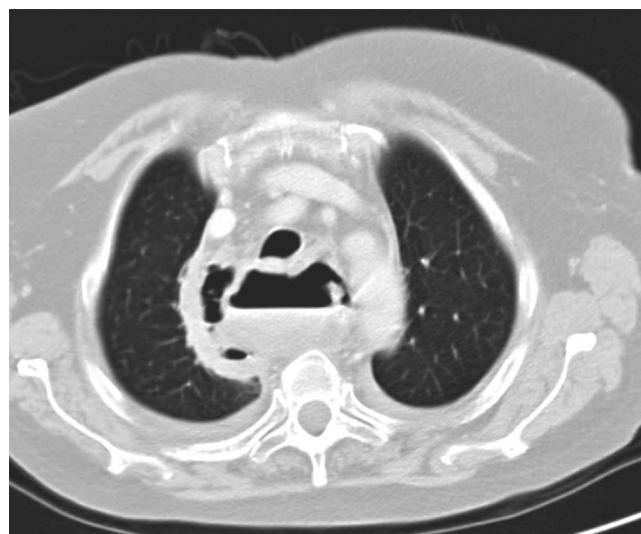

Fig. 2. Mediastinal leakage from oesophageal rupture.

patient. The later subgroup, should be operatively managed due to severe morbidity and mortality.

Primary stent treatment for spontaneous esophageal perforations especially in iatrogenic perforations has proven effective but outcomes for stent treating haematomas are unknown and require close radiographic and endoscopic follow-up.^{7,8} As to our knowledge, no guidelines on traumatic blunt perforations with haematomas are available, and we believe as indicated by others,⁹ that stent treatment should be reserved for patients not fit to undergo major surgery like thoracotomy, or as 2nd line management in persistent leak or sepsis

Once a perforation is verified management should always include antibiotics, proton pump inhibitors and parenteral nutrition as vital therapeutic measures. If choosing to treat an oesophageal hematoma conservatively we advise to stop anticoagulants or lead strict control of International Normalised Ratio (INR) when prescribing vitamin-K-antagonists. To prevent esophageal lesions, it is advisable to refrain from gastric tubes and instead consider parenteral nutrition. As with our patient, chest pain is the most frequent symptom but other symptoms such as fever, dyspnoea and dysphagia might dominate.

4. Conclusion

Late, spontaneous, intrathoracic esophageal perforations due to blunt trauma is to our knowledge not described previously. Such haematomas can be treated conservatively but if the esophageal wall ruptures prompt surgically management must be taken, especially if uncontained. Stent treatment is reserved only for patients not suitable for thoracotomy.

Conflict of interest

None declared.

Funding

None.

Ethical approval

None.

Author contribution

All authors contributed equally.

References

2. Jones 2nd WG, Ginsberg RJ. Esophageal perforation: a continuing challenge. *Ann Thorac Surg* 1992;**53**(March (3)):534–43.
3. Altıkaya N, Parlakgumus A, Demir S, Alkan O, Yildirim T. Small bowel obstruction caused by intramural hematoma secondary to warfarin therapy: a report of two cases. *Turk J Gastroenterol* 2011;**22**(2):199–202.
4. Cheng J, Vemula N, Gendler S. Small bowel obstruction caused by intramural hemorrhage secondary to anticoagulant therapy. *Acta Gastroenterol Belg* 2008;**71**(July–September (3)):342–4.
5. Ryom P, Ravn JB, Penninga L, Schmidt S, Iversen MG, Skov-Olsen P, et al. Aetiology, treatment and mortality after oesophageal perforation in Denmark. *Dan Med Bull* 2011;**58**(May (5)):A4267.
6. Lin Y, Jiang G, Liu L, Jiang JX, Chen L, Zhao Y, et al. Management of thoracic esophageal perforation. *World J Surg* 2013;(December).
7. Dasari BV, Neely D, Kennedy A, Spence G, Rice P, Mackle E, et al. The role of esophageal stents in the management of esophageal anastomotic leaks and benign esophageal perforations. *Ann Surg* 2014;(February).
8. Blackmon SH, Santora R, Schwarz P, Barroso A, Dunkin BJ. Utility of removable esophageal covered self-expanding metal stents for leak and fistula management. *Ann Thorac Surg* 2010;**89**(March (3)):931–6, discussion 936–937.
9. Rohatgi A, Papanikitas J, Sutcliffe R, Forshaw M, Mason R. The role of oesophageal diversion and exclusion in the management of oesophageal perforations. *Int J Surg* 2009;**7**(April (2)):142–4.

Open Access

This article is published Open Access at scimedirect.com. It is distributed under the [IJSCR Supplemental terms and conditions](#), which permits unrestricted non commercial use, distribution, and reproduction in any medium, provided the original authors and source are credited.