

Radiology Case Reports

Volume 4, Issue 4, 2009

Subperiosteal recurrence of chondroblastoma

Sumanth Reddy, DO; Michael Deavers, MD; Patrick Lin, MD; and Tamara Miner Haygood, PhD, MD

We present a case of subperiosteal recurrence of chondroblastoma adjacent to the greater trochanter that was initially thought to represent septic arthritis of the hip in a 10-year-old girl. Soft-tissue recurrence of chondroblastoma is very rare, with fewer than ten cases reported in the literature. We demonstrate the recurrence on both CT and MRI. The MRI clearly demonstrates the soft-tissue recurrence and the associated inflammatory changes, with signal characteristics not unlike the primary tumor.

Case report

A 10-year-old girl initially presented at an outside institution with right hip and knee pain. At that time, the patient and her family were told that her hip and knee x-rays were normal. The pain continued, and MRI of the hip without contrast was performed at the outside institution approximately nine months after initial presentation. This study revealed a focal, well-defined lesion that was hypointense on both the T1 and STIR sequences, with edema in the adjacent bone and soft tissues (Fig. 1). The patient was then referred to our institution for evaluation and treatment.

At the time of presentation to our institution, the patient was a well-developed girl with a benign past medical history. Physical exam revealed limited range of motion and weakness of the right hip musculature secondary to pain. The patient also had tenderness overlying the greater trochanter. Re-interpretation of hip radiographs from the outside institution revealed a well-defined lytic lesion within the greater trochanter (Fig. 2). The patient subsequently underwent CT-guided biopsy of the greater trochanteric lesion. Biopsy revealed chondroblastoma. The patient then underwent curettage and bone-grafting of the lesion. The

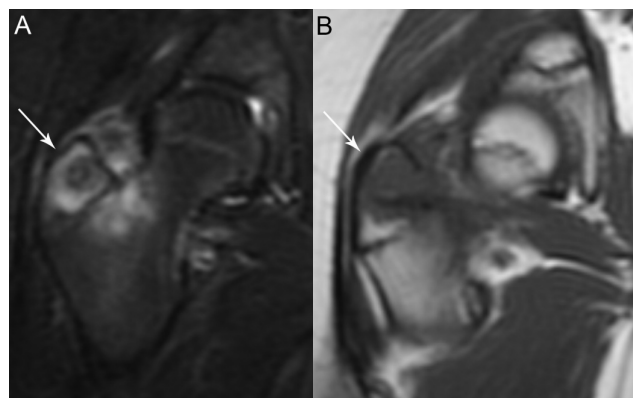


Figure 1. 10-year-old girl with recurrence of chondroblastoma. MRI of the right hip. (A) Coronal STIR (TR 5250/TE 55/TI 150) and (B) coronal T1 (TR 516/TE 12) weighted MR images of the right hip. Hypointense STIR and T1 lesion (arrow) within the greater trochanter surrounded by inflammatory changes in the adjacent bone and soft tissues.

patient's postoperative recovery and clinical course were uneventful for the next eleven months.

At that time, the patient again presented with increasing right hip pain. MRI of the hip showed a small joint effusion, with edema in the femoral head and surrounding soft tissues (Fig. 3). A small mass in the soft tissues just medial to the posterior greater trochanter was not recognized. The study was interpreted as possible septic arthritis. The patient then underwent ultrasound-guided aspiration of the joint effusion. Laboratory evaluation of the fluid was negative for infection. At that time, it was thought the patient may have injured herself. The patient continued to have increased pain, to the point that she was not able to bear weight. At that time, a CT-guided biopsy of the greater trochanter was performed. A soft-tissue mass surrounded

Citation: Reddy S, Deavers M, Lin P, Haygood TM. Subperiosteal recurrence of chondroblastoma. *Radiology Case Reports*. [Online] 2009;4:328.

Copyright: © 2009 The Authors. This is an open-access article distributed under the terms of the Creative Commons Attribution-NonCommercial-NoDerivs 2.5 License, which permits reproduction and distribution, provided the original work is properly cited. Commercial use and derivative works are not permitted.

Dr. Reddy and Dr. Haygood are in the Department of Diagnostic Radiology, Dr. Deavers is in the Department of Pathology, and Dr. Lin is in the Department of Orthopedic Oncology, University of Texas M.D. Anderson Cancer Center, Houston TX, USA.

Competing Interests: The authors have declared that no competing interests exist.

DOI: 10.2484/rcr.v4i4.328

Subperiosteal recurrence of chondroblastoma

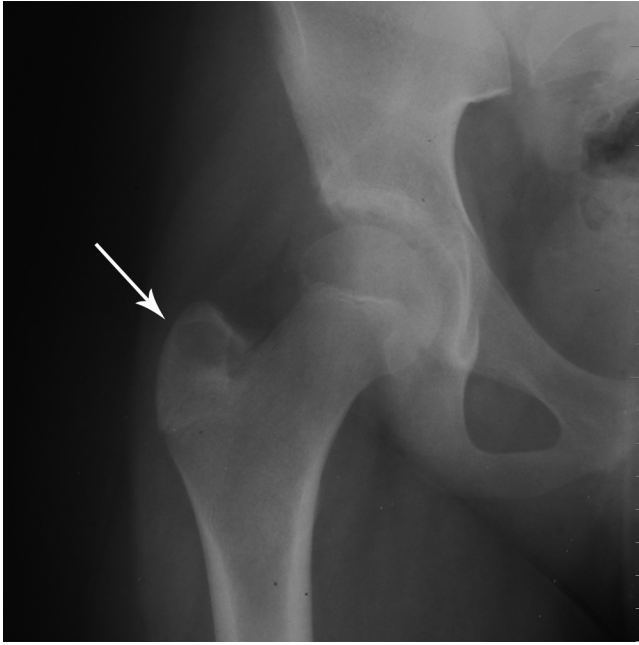


Figure 2. 10-year-old girl with recurrence of chondroblastoma. Right hip radiograph. Frontal view of the right hip reveals a well-circumscribed lytic lesion (arrow) in the greater trochanter.

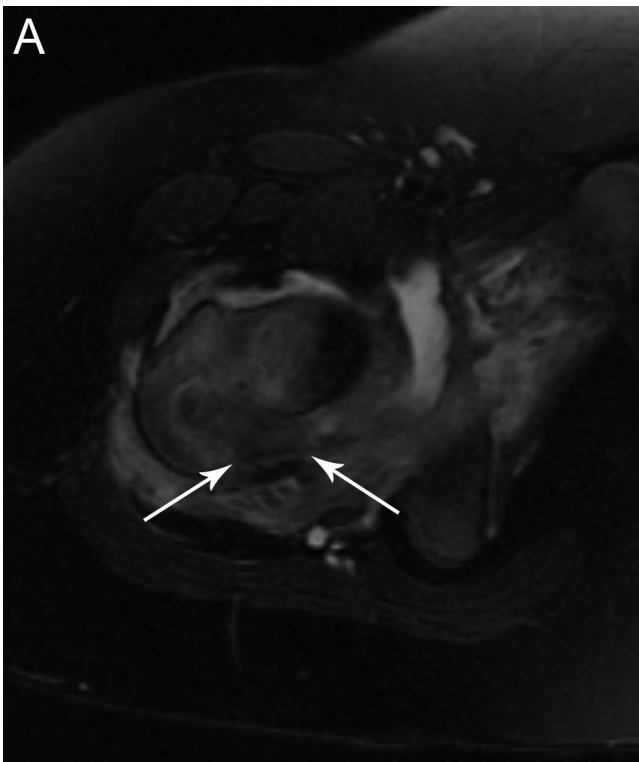


Figure 3. 10-year-old girl with recurrence of chondroblastoma. MRI of the right hip. (A) Axial fat-saturated T2 (TR 4000/TE 81)

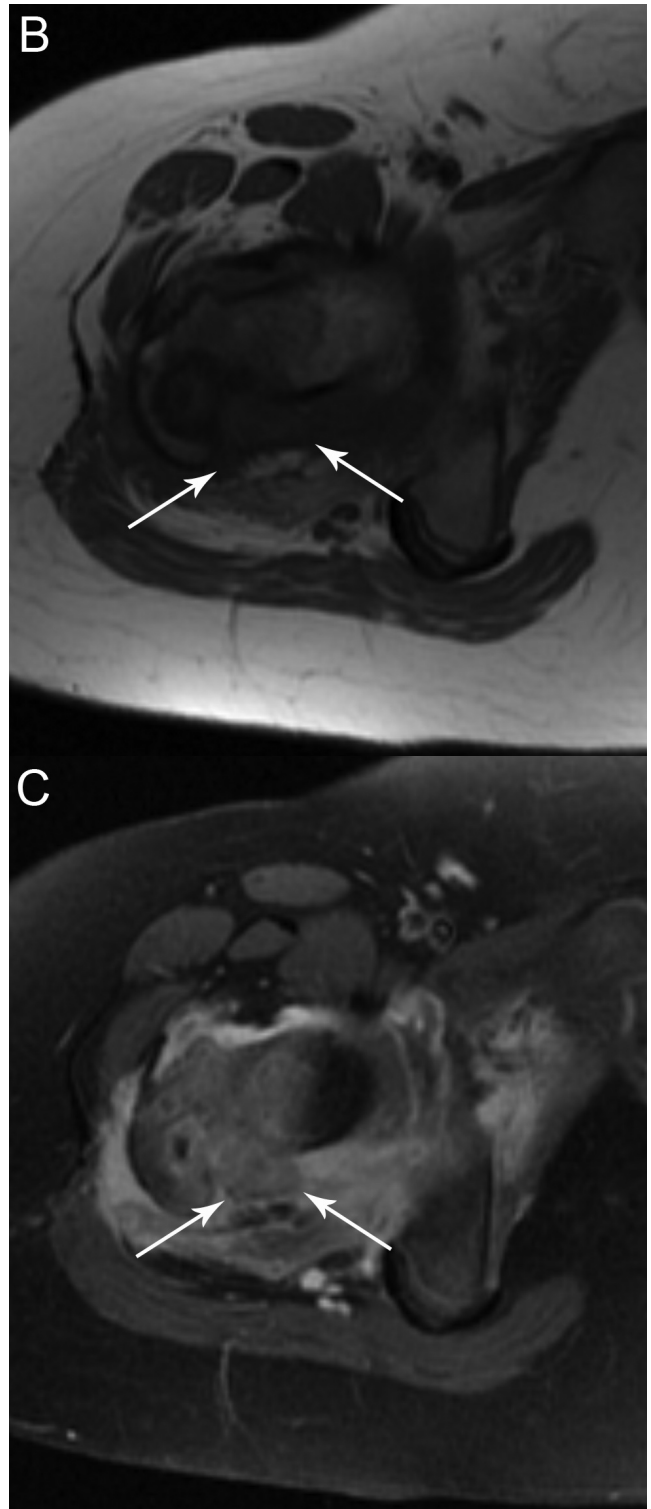


Figure 3. 10-year-old girl with recurrence of chondroblastoma. MRI of the right hip. (B) axial T1 (TR 550/TE 513), and (C) axial postgadolinium fat-saturated T1 (TR 500/TE 13) MR images of the right hip. Relatively hypointense T2 and T1 lesion (arrows) in the soft tissues posteromedial to the greater trochanter, with an associated joint effusion and inflammatory changes in the soft tissues and bone.

Subperiosteal recurrence of chondroblastoma

by a thin rim of interrupted periosteum posteromedial to the greater trochanter (Fig. 4) went undetected. The biopsy of the greater trochanter was nondiagnostic.

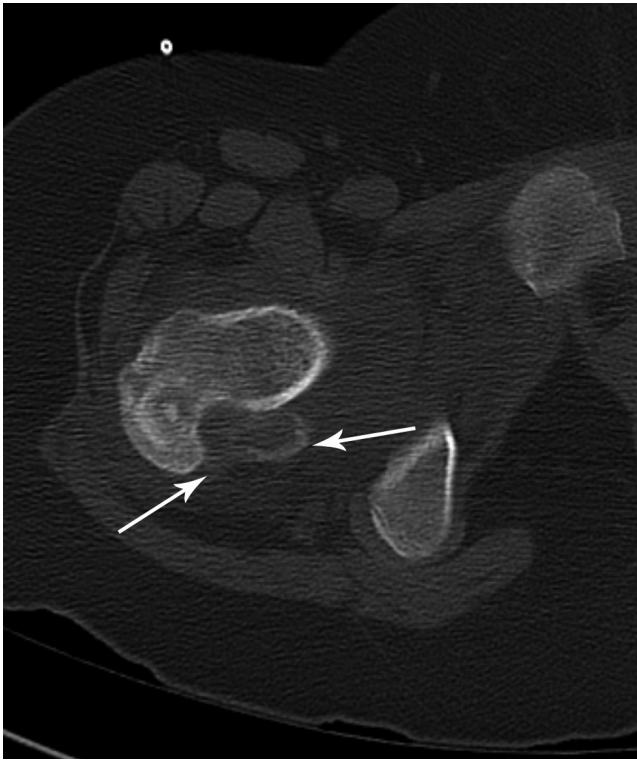

Figure 4. 10-year-old girl with recurrence of chondroblastoma. CT of the right hip obtained in conjunction with biopsy, depicted on the bone window. Soft-tissue mass posteromedial to the greater trochanter surrounded by a thin interrupted rim of calcification (arrows).

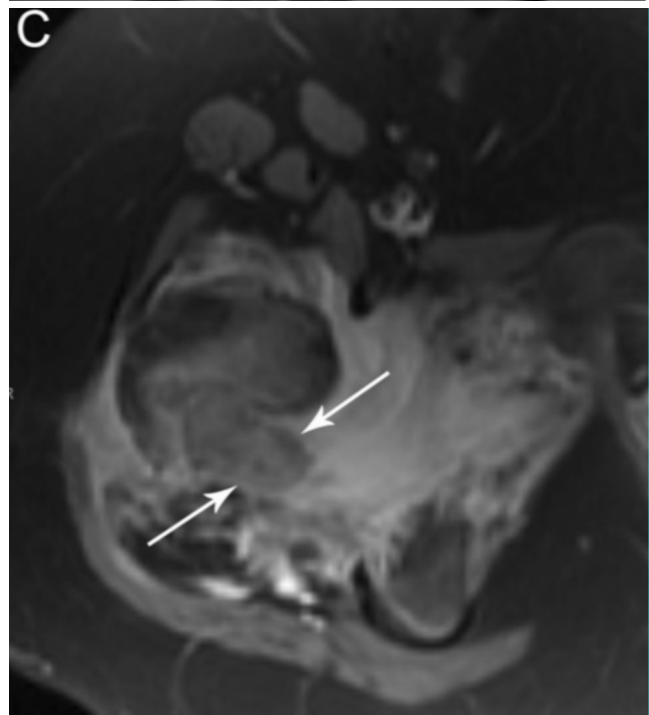
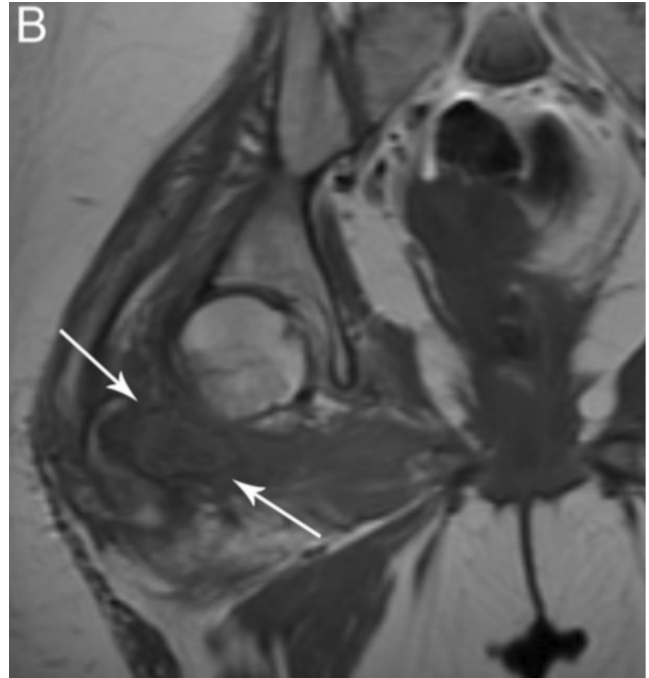
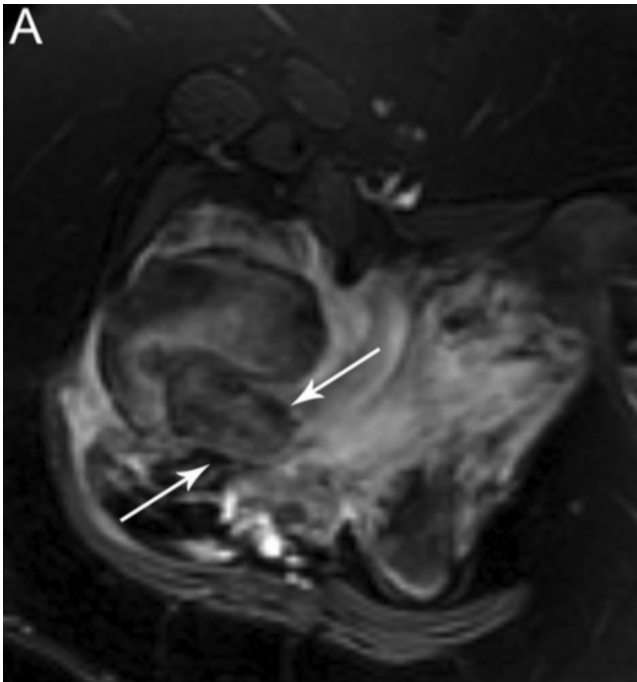


Figure 5. 10-year-old girl with recurrence of chondroblastoma. MRI of the right hip. (A) Axial fat-saturated T2 (TR 4000/TE 89), (B) coronal T1 (TR 650/TE 13), and (C) axial postgadolinium fat-saturated T1 (TR 566/TE 13) MR images of the right hip. Enlarging relatively hypointense T2 and T1 lesion (arrows) in the soft tissues posteromedial to the greater trochanter, with an associated joint effusion and inflammatory changes in the soft tissues and bone. Post-gadolinium, the lesion demonstrates enhancement that is less intense than the surrounding inflammatory changes in soft tissues and bone.

Subperiosteal recurrence of chondroblastoma

The patient continued with pain and inability to bear weight, despite aggressive physical therapy. A repeat MRI was performed and revealed intense increased signal on fat-saturated T2-weighted and on postcontrast fat-saturated T1-weighted images throughout the soft tissues around the right hip. Embedded in this inflammatory edematous reaction was an oval, 3-cm mass posteromedial to the greater trochanter that enhanced less than the surrounding tissue and therefore was visible as an island of relatively low signal (Fig. 5). The patient was taken to the operating room for an open biopsy. The tumor was identified in a subperiosteal location outside of the cortical bone. The frozen section was consistent with recurrent chondroblastoma. Therefore, the surgeon proceeded to excise the soft-tissue mass and perform a curettage and bone-grafting of the surface of the bone. Final pathology confirmed recurrent chondroblastoma. The histological appearance was similar to the original tumor. It was composed of a diffuse proliferation of mononuclear cells with intermixed multinuclear giant cells and scattered foci of chondroid matrix, some of which had undergone calcification (Fig. 6). At followup eight months after surgery, the patient was pain-free and fully ambulatory.

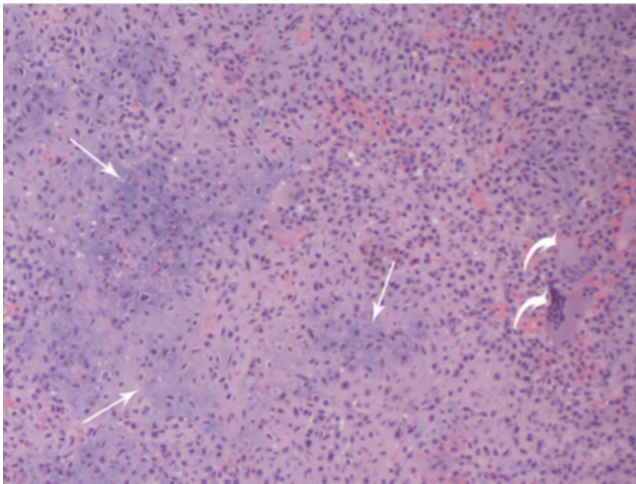


Figure 6. Blue to pink chondroid matrix (arrows) on a background of diffuse proliferation of mononuclear cells and focal giant cells (curved arrows) (100x).

Discussion

Chondroblastoma is a rare benign bone tumor accounting for approximately 1% of all benign bone tumors (1). The lesion typically presents as a well-demarcated lytic lesion in the epiphysis on radiographs. They are also well-known to occur in the apophyses, including the greater trochanter. Treatment consists of curettage and filling of the defect with either bone graft or methylmethacrylate. Recurrence rates range from 8.3% to 21.4% in the more recent literature (2-5). The single most important factor predictive of recurrence is retention of tumor material at surgery (2, 3). Lesions occurring in the region of the proxi-

mal femur and pelvis also demonstrate an increased rate of recurrence (2, 5). The reason for this higher rate of recurrence may be secondary to difficulty of curettage in this location. Given the location of our patient's lesion, our patient was at an increased risk for recurrence. Biological aggressiveness of the tumor may also play a role in recurrence (2). In our patient, there was no evidence for aggressive features either in the primary tumor or recurrent tumor.

Soft-tissue recurrence of chondroblastoma has been reported, although it is rare. The first case was reported in 1966 (6). To our knowledge, a total of eight soft-tissue recurrences have been reported in the literature (6-11). Our patient presented with subperiosteal recurrence of tumor along the posteromedial aspect of the greater trochanter. Therefore, the plain films of the hip were not particularly helpful, as there was no osteolysis to suggest tumor recurrence. On the CT performed at the time of the second biopsy, the soft-tissue mass surrounded by a thin periosteal shell remained unrecognized but was similar in appearance to a reported case of primary cortical chondroblastoma (12). The MRI in this case clearly depicted the recurrence and surrounding inflammatory change. The low-to-intermediate T2-signal intensity and lobular margin used to describe primary chondroblastoma was also present in our case of subperiosteal recurrence (13).

Our patient presented with significant edema within the adjacent soft tissues and bone marrow, a finding that is also common in primary chondroblastoma (13,14). In fact, the surrounding inflammatory reaction can be used as sign of recurrence, as the inflammatory change resolves after removal of a lesion (14). In our case, the initial MRI after the return of the patient's symptoms was thought to represent septic arthritis, given the extensive marrow and soft-tissue edema, and joint effusion. Although infection was a reasonable consideration, had the recurrent mass in the soft tissues been recognized, this might have allowed more timely initiation of definitive treatment. To our knowledge, this is the first case report of an MRI demonstrating subperiosteal recurrence of chondroblastoma.

In summary, persistent or increasing inflammatory changes on MRI in a patient with previous removal of a chondroblastoma should lead to a careful search for recurrent tumor. Although this typically occurs in bone, it may on occasion also develop in soft tissue, which can be subtler and harder to recognize.

Acknowledgment

The authors thank Dr. John Madewell for helpful suggestions regarding this case in the early phases of writing.

References

1. Dahlin DC, Ivins JC. Benign chondroblastoma. a study of 125 cases. *Cancer*. 1972 Aug;30(2):401-13. [PubMed]
2. Lin PP, Thenappan A, Deavers MT, Lewis VO, Yasko AW. Treatment and prognosis of chondroblastoma. *Clin Orthop Relat Res*. 2005 Sep;438:103-9. [PubMed]

Subperiosteal recurrence of chondroblastoma

3. Suneja R, Grimer RJ, Belthur M, Jeys L, Carter SR, Tilman RM, Davies AM. Chondroblastoma of bone: long-term results and functional outcome after intralesional curettage. *J Bone Joint Surg Br.* 2005 Jul;87(7):974-8. [\[PubMed\]](#)
4. Atalar H, Basarir K, Yildiz Y, Erekul S, Saglik, Y. Management of chondroblastoma: retrospective review of 28 patients. *J Orthop Sci.* 2007 Jul;12(4):334-40. [\[PubMed\]](#)
5. Ramappa AJ, Lee FY, Tang P, Carlson JR, Gebhardt MC, Mankin HJ. Chondroblastoma of bone. *J Bone Joint Surg Am.* 2000;82:1140-5. [\[PubMed\]](#)
6. Coleman SS. Benign chondroblastoma with recurrent soft-tissue and intra-articular lesions. *J Bone Joint Surg Am.* 1966 Dec;48(8):1554-60. [\[PubMed\]](#)
7. Shoji H, Miller TR. Benign chondroblastoma with soft tissue recurrence. *N Y State J Med.* 1971 Dec 1;71(23):2786-9. [\[PubMed\]](#)
8. Corsat JP, Tomeno B, Forest M, Vinh TS. Benign chondroblastoma. A review of 30 cases. *Rev Chir Orthop Reparatrice Appar Mot.* 1989;75(3):179-87. [\[PubMed\]](#)
9. Accadbled F, Brouchet A, Salmeron F, Darodes P, Cahuzac JP, Sales De Gauzy J. Recurrent aggressive chondroblastoma: two cases and a review of the literature. *Rev Chir Orthop Reparatrice Appar Mot.* 2001 Nov;87(7):718-23. [\[PubMed\]](#)
10. Hammond GW, Gu M, Tehranzadeh J, Hoang BH. Periprosthetic soft tissue recurrence of chondroblastoma after attempted en bloc excision from the proximal humerus. *Skeletal Radiol.* 2006 Jan;35(1):53-7. [\[PubMed\]](#)
11. Zafatayeff-Hasbani S, Ducou Le Pointe H, Josset P, Dasmin JP, Montagne JP. Intra-articular recurrence of benign chondroblastoma with articular involvement at initial presentation--a case report. *Eur J Pediatr Surg.* 2006 Aug;16(4):291-3. [\[PubMed\]](#)
12. Hameed MR, Blacksin M, Das K, Patterson F, Benevenia J, Aisner S. Cortical chondroblastoma: report of a case and literature review of this lesion reported in unusual locations. *Skeletal Radiol.* 2006 May;35(5):295-7. [\[PubMed\]](#)
13. Weatherall PT, Maale GE, Mendelsohn DB, Sherry CS, Erdman WE, Pascoe HR. Chondroblastoma: Classic and confusing appearance at MR imaging. *Radiology.* 1994 Feb;190(2):467-74. [\[PubMed\]](#)
14. Yamamura S, Sato K, Sugiura H, Iwata, H. Inflammatory reaction in chondroblastoma. *Skeletal Radiol.* 1996 May;25(4):371-6. [\[PubMed\]](#)