



Pan African Urological Surgeons' Association

African Journal of Urology

www.ees.elsevier.com/afju
www.sciencedirect.com



Short communication

Right paratesticular abscess mimicking neonatal testicular torsion and caused by *Proteus mirabilis*

U.O. Ezomike^{a,*}, M.A. Ituen^a, S.C. Ekpemo^a, S.O. Ekenze^b

^a Department of Surgery, Federal Medical Centre Umuahia, Abia State, Nigeria

^b Sub-Department of Pediatric Surgery, University of Nigeria Teaching Hospital, Ituku/Ozalla, Enugu, Enugu State, Nigeria

Received 13 January 2013; received in revised form 7 March 2013; accepted 13 March 2013

KEYWORDS

Neonatal;
Paratesticular abscess;
Testicular torsion;
Proteus mirabilis

Abstract

The clinical presentation of neonatal paratesticular abscess may closely resemble that of, neonatal testicular torsion and the use of scrotal ultrasonography to differentiate the two has low, sensitivity. We propose early operative treatment of suspected neonatal testicular torsion to salvage, the testicle in cases of paratesticular abscesses. This is a report of the successful transinguinal, drainage of a right neonatal paratesticular abscess preoperatively diagnosed as testicular torsion and, caused by *Proteus mirabilis*. The testicle was salvaged.

© 2013 Pan African Urological Surgeons' Association. Production and hosting by Elsevier B.V.
Open access under [CC BY-NC-ND license](#).

Introduction

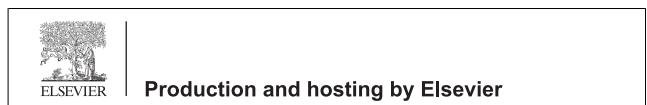Paratesticular abscess in a neonate is a rare clinical presentation. Conclusive preoperative diagnosis of this abscess may be difficult even with various imaging modalities. Most intrascrotal abscesses are drained either by percutaneous or open trans-scrotal approach. Transinguinal drainage has rarely been reported, though this approach will help assess a thickened spermatic cord and

high-ligate a patent processus vaginalis. Most commonly cultured bacterial agents in intrascrotal abscess is *Staphylococcus aureus* [2]. Other organisms like β -hemolytic streptococci [3], *Salmonella spp* [4], *Klebsiella pneumoniae* [5], *Bacteroides fragilis* [3,6] and coliforms [1,5] have also been reported as aetiological agents. To the best of our knowledge, *Proteus mirabilis* has never been reported before as a cause of this rare clinical condition.

Case report

A 3.85 kg uncircumcised male neonate delivered at term by emergency lower segment caesarean section due to prolonged rupture of membrane to a nondiabetic, HIV negative mother, presented at 14th day of life with a 5-day history of right hemiscrotal swelling. There was no fever, abdominal swelling nor vomiting. Child remained active, moved bowel and passed urine without difficulty. The right hemiscrotum was elevated (Fig. 1), not warm and mildly tender. There was minimal right hemiscrotal oedema, an enlarged right testicle, evidently thickened ipsilateral spermatic cord. There was

* Corresponding author. Tel.: +234 8037392246.
E-mail address: ezomikeuche@yahoo.com (U.O. Ezomike).
Peer review under responsibility of Pan African Urological Surgeons' Association.



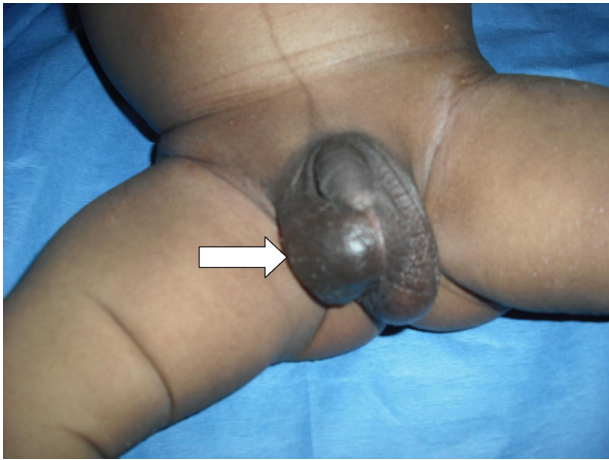


Figure 1 Picture illustrating elevated right hemiscrotum. Also note shiny appearance and loss of scrotal rugae.

however no obvious torsion of the cord on palpation. The contralateral hemiscrotum and testicle were grossly normal. A working diagnosis of neonatal testicular torsion was made. Doppler evaluation for testicular blood supply was not available in our hospital. The patient was optimised and offered urgent right hemiscrotal exploration through a right transinguinal approach under general anaesthesia. During exploration the paratesticular abscess cavity was inadvertently opened into draining about 1 ml of thick, purulent material leaving a shallow depression on the surface of the testicle. Culture of this pus yielded significant growth of *P. mirabilis*. There was no evidence of testicular torsion nor obvious patency of the processus vaginalis. Though the testicle grossly appeared inflamed and devitalized, careful assessment revealed healthy testicular tissue. This assessment involved incision of the tunica albuginea and observation of the golden yellow testicular tissue as well as good bleed. Right hemiscrotal and testicular toilet were done, testicle returned to the hemiscrotal fundus and wound closed. Parenteral broad spectrum antibiotics were empirically commenced intraoperatively and continued postoperatively. Urine microscopy and culture was not done as there were no clinical evidence of urinary tract infection nor evidence of anatomical predisposing factors like posterior urethral valve. He had an uneventful postoperative period except for superficial surgical site infection which healed with local wound dressing. The testicle is normal in size and texture six months after.

Discussion

Clinical differentiation between paratesticular abscess and testicular torsion in a neonate can be difficult [7]. Paratesticular abscess closely mimics testicular torsion [5] as the involved testicle is drawn up as in torsion probably due to spasm of cremaster muscle [2] (Fig. 1). Scrotal abscesses in the neonate commonly have less evidence of inflammation, and this limits the value of clinical assessment at this age [2]. Even diagnosis with various ultrasonographic modalities can be quite challenging [1,6,8]; hence preoperative diagnosis of paratesticular abscess is uncommon. Neonatal testicular torsion is a more common preoperative diagnosis and some authorities will offer delayed scrotal exploration in the belief that testicular salvage almost never occurs in neonatal torsions [1,9]. Existence of paratesticular abscess with similar clinical and radiological features with neonatal torsion should encourage immediate operation in suspected

torsion [7]. Immediate exploration and drainage was therefore done for our patient with salvage of his testicle. Since preoperative diagnosis of intrascrotal abscess was never entertained, no attempt was made at percutaneous transscrotal drainage. Also as the abscess cavity was inadvertently opened into during exploration direct extirpation was made impossible.

The route of drainage was trans-inguinal not trans-scrotal. This was to help assess for and possibly high-ligate a patent processus vaginalis since the cord was thickened. Furthermore, as the pre-operative diagnosis was neonatal testicular torsion, inguinal approach was logical as also corroborated by Wan and Bloom [10] who asserted that exploration in neonatal torsion should be by inguinal approach since torsion of the spermatic cord may occur within inguinal canal; hence access will be difficult through a transscrotal approach. Contralateral hemiscrotal exploration was not done to prevent contamination of the left hemiscrotum [2], moreover, there was no obvious left hemiscrotal lesion.

The patient's testicle appeared devitalized, but closer assessment with incision of tunica albuginea revealed grossly healthy testicular tissue. This is as opposed to Briggs et al. [1] where an apparently necrotic testicle was excised which on histology revealed a healthy testicular tissue. The actual source of this scrotal contamination and subsequent abscess could not be ascertained just as reported by Briggs et al. [1] and Singh et al. [3]. Others have reported transperitoneal spread via patent processus vaginalis [11], retrograde spread from urinary tract infection and hematogenous spread [5]. In the index case, there was no patency of processus vaginalis nor evidence of intraperitoneal infection. There was also no evidence of systemic bacterial infection nor urinary tract infection.

Urgent exploration and drainage of abscess was done in our patient as proposed by Briggs et al. [1] and Raveenthiran and Cenita [2]. In the largest published series on neonatal intrascrotal abscess, Raveenthiran and Cenita reported nine cases over a period seven years in India. Out of their nine cases only one testicular loss was recorded and this was in a patient presenting after twenty-eight days from onset of symptoms. From their wealth of experience, they proposed urgent exploration for all cases of neonatal testicular torsion. It is obvious from their experience that delay in presentation or in the drainage of abscess led to putrefaction of the testicle [2].

Though coliform organisms have been cultured from paratesticular abscesses [1], to the best of our knowledge this is the first report of *P. mirabilis* as an aetiological agent in paratesticular abscess.

Conclusion

Paratesticular abscess is a strong differential diagnosis for neonatal testicular torsion. *P. mirabilis* is a rare but possible cause. The testicle is usually salvaged with urgent surgical drainage of abscess and use of appropriate antibiotics. Nonoperative or delayed operative management of suspected neonatal testicular torsion may delay the diagnosis of paratesticular abscess and lead to preventable testicular loss and should therefore be discouraged. An apparently necrotic testicle after abscess drainage should be fully assessed for viability before orchidectomy is offered to prevent surgical removal of a viable testicle.

References

- [1] Briggs C, Godbole P, MacKinnon AE, Vermeulen K. Neonatal paratesticular abscess mimicking perinatal torsion. *Journal of Pediatric Surgery* 2005;40:1195–6.
- [2] Raveenthiran V, Cenita S. Scrotal abscess mimicking testicular torsion in infants and neonates. *Journal of Pediatric Surgery* 2007;42:597–8.
- [3] Singh D, Dutta S, Kumar P, Narang A. Mixed anaerobic and aerobic testicular abscess in a neonate. *Indian Journal of Pediatrics* 2001;68:561–2.
- [4] Huang CB, Chuang JH. Acute scrotal inflammation caused by *Salmonella* in young infants. *Pediatric Infectious Disease* 1997;16:1091–2.
- [5] Di Renzo D, Pappalepore N, Colangelo M, Chiesa PL. Bilateral scrotal abscess caused by *Klebsiella pneumoniae* in a newborn. *Journal of Pediatric Surgery* 2010;45:E19–20.
- [6] Srinivasan AS, Darge K. Neonatal scrotal abscess: a differential diagnostic challenge for the acute scrotum. *Pediatric Radiology* 2009;39:91.
- [7] Arias-Camison JM, Desilva HN, Panthagani I, Twohig MT, Bourque MD. Scrotal abscess mimicking testicular torsion in a premature infant. *Connecticut Medicine* 2009;73:215–6.
- [8] Zerin JM, DiPietro MA, Grignon A, Shea D. Testicular infarction in the newborn: ultrasound findings. *Pediatric Radiology* 1990;20:329–30.
- [9] Brandt MT, Sheldon CA, Wacksman J, Matthews P. Prenatal testicular torsion: principles of management. *Journal of Urology* 1992;147:670–2.
- [10] Wan J, Bloom DA. Male genital tract. In: Oldham KT, Colombani PM, Foglia RP, Skinner MA, editors. *Principles and practice of pediatric surgery*. Lippincott: Williams and Wilkins; 2005. p. 1603.
- [11] Mutlu M, Imamoglu M. Scrotal abscess in a newborn caused by extended-spectrum beta-lactamase-producing *Klebsiella pneumoniae*. *Indian Pediatrics* 2010;47:363–4.