

Contents lists available at [ScienceDirect](#)

## International Journal of Surgery Case Reports

journal homepage: [www.casereports.com](http://www.casereports.com)

# Congenital internal hernia through defect in the falciform ligament in adult: A case report and review of the literature



Simona Macina\*, Tommaso Testa, Caterina Losacco

University of study of Genoa (Italy) IRCCS, Largo Benzi 10, 16132 Genova, Italy

## ARTICLE INFO

### Article history:

Received 22 March 2016

Accepted 1 May 2016

Available online 17 May 2016

### Keywords:

Internal hernia

Falciform ligament

## ABSTRACT

**INTRODUCTION:** The incidence of occlusion syndrome caused by internal hernia is very rare, in particular when the defect is congenital discovered in adults with no previous abdominal surgery.

**PRESENTATION OF CASE:** We present a case of a 31 year-old female patient who presented with acute abdominal pain and mechanical obstruction. The patient had never undergone abdominal surgery.

**DISCUSSION:** On diagnostic laparoscopy, it was found a herniation of a loop of small bowel through a hole in the falciform ligament. The obstruction was solved by the division of part of falciform ligament without intestinal resection.

**CONCLUSION:** Internal hernia is a very uncommon pathology, most often discovered in pediatric age because of congenital abnormalities, it must be included in the differential diagnosis in adults. Preoperative diagnosis is difficult. The diagnostic laparoscopic approach has shown to be the best.

© 2016 Published by Elsevier Ltd on behalf of IJS Publishing Group Ltd. This is an open access article under the CC BY-NC-ND license (<http://creativecommons.org/licenses/by-nc-nd/4.0/>).

## 1. Introduction

An internal abdominal herniation is a protrusion of an abdominal organ, through a mesenteric or peritoneal hole [1], they have no sac and can include the colon, the omentum and most often the small bowel [2]. Internal hernia is rare, estimated to be 2% of all causes of internal obstruction [3], and among these through the falciform ligament is extremely uncommon. Internal abdominal hernia can be constitutional related to congenital defects or complete failure in the embryological development [4–6], acquired related to trauma and iatrogenic caused by surgical procedures. Except urgency, clinical presentation is often aspecific: chronic digestion disorders, pain after feeding, mild abdominal pain due to intermittent bowel obstruction [7,12]. The symptoms may mimic peptic ulcer, biliary pathologies and abdominal angina [8]. Therefore preoperative diagnosis is uncommon, Ct scan is routinely performed in Emergency Department.

## 2. Case report

31-year-old woman was admitted to the Emergency department with complaints of: epigastric pain with nausea, suddenly arised and no associated with feeding and central abdominal distension. No other relevant history, except of previous episodes of abdominal pain, treated with antispastic drugs. Per abdomen, dis-

tension and pain in the epigastrium at the palpation were present, bowel sounds were present in all quadrant of the abdomen with hyperperistaltism in epigastrium. The systemic examination was normal.

### 2.1. Investigations

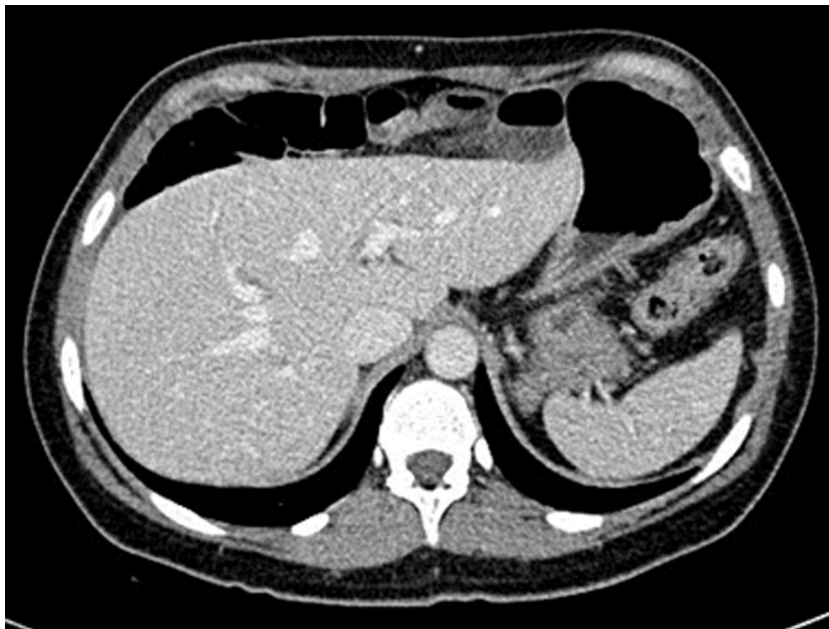Complete blood count: leukocytosis ( $12,36 \times 10E9/L$ ) with neutrophilia ( $10,90 \times 10E9/L$ ); routine biochemistry showed increased values of LDH (221 U/L) and CPK (242 U/L); X-ray, chest: negative; abdomen: gas distension of some intestinal loops in epigastric and right-hypochondriac region with a single air-fluid level in epigastric region; computed tomography: interposition of right colon between anterior abdominal wall and liver. Gas distension of some ileal loops which are located between liver and anterior abdominal wall; in left paramedian area one of these loops has thickened wall and perivisceral fluid and appears to reduce its caliber.

### 2.2. Treatment

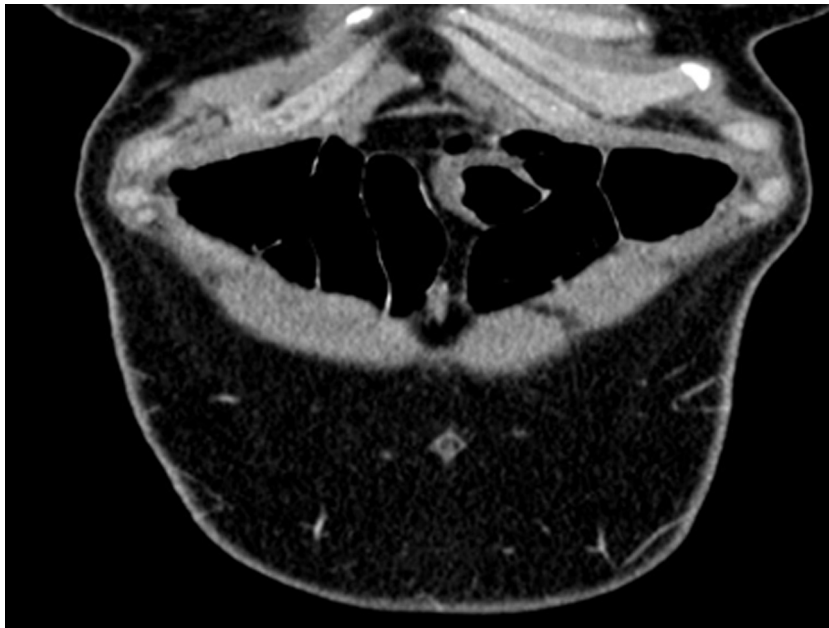
The patient was started on conservative management, i.e. nil by mouth, intravenous fluid. Pain was resistant to antispastic and analgic drugs (included Morphine intramuscular). She did not improve her condition and after 8 h the abdominal pain and the lab exams went worse, so the decision for diagnostic laparoscopy to be performed was taken, after collegial discussion with radiologists. Findings of laparoscopy: the introduction of the first trocar with open technique through the umbilicus allows the discovering of distended small bowel loops, herniated small bowel loop through a

\* Corresponding author.

E-mail addresses: [simona.macina@gmail.com](mailto:simona.macina@gmail.com) (S. Macina), [ttesta@libero.it](mailto:ttesta@libero.it) (T. Testa), [caty.losacco@gmail.com](mailto:caty.losacco@gmail.com) (C. Losacco).



**Fig. 1.** CT scan: interposition of right colon between anterior abdominal wall and liver. In left paramedian area one of these loops has thickened wall and perivisceral fluid and appears to reduce its caliber.

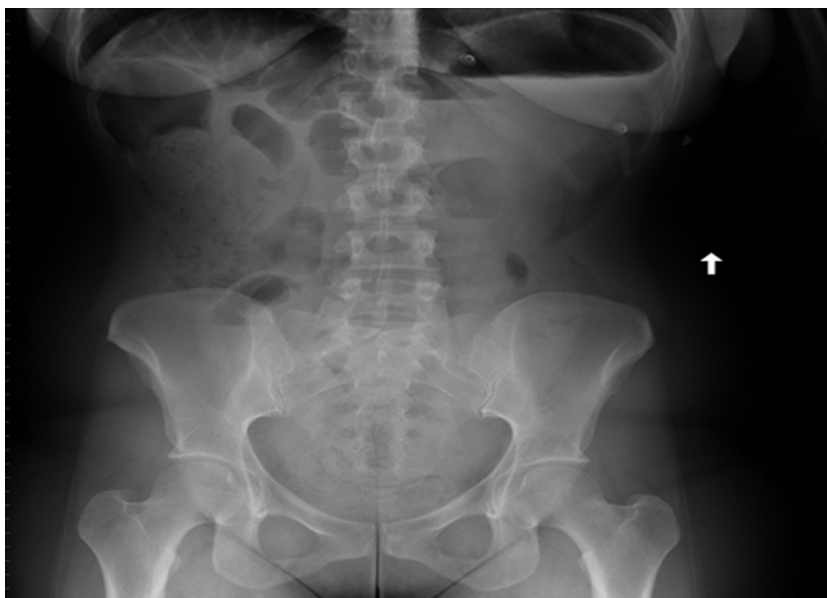

**Fig. 2.** CT scan: Gas distension of some ileal loops which are located between liver and anterior abdominal wall.

defect in the anterior part of falciform ligament causing a mechanic occlusion, the involved loop appeared to be suffering for venous stasis because of initial strangulation of the vascular axis. It was necessary to introduce other two trocars, both under-mesocolic on the transverse umbilical line on the two sides laterally to the margin of the rectus muscle. Using the monopolar crochet, the section of fibrous enveloping ring released the loop, which seems to recover with adequate vascular supply. The falciform ligament was cut and the free margin was ligated with endoloop, in order to reduce the possibility of recurrence. The patient had an uneventful post-operative recovery. She was discharged in the third post-op day (Figs. 1–3).

### 3. DISCUSSION

An internal hernia is a pathological protrusion on an abdominal organ through a normal or abnormal hole within the boundaries of the peritoneal cavity. The incidence of internal hernia is 0.2–2% [3] and among these hernia through the falciform ligament is very rare and accounts for 0.2% [9], caused by malformation and incomplete development of the falciform ligament. Most of the time this defect is discovered during pediatric age. Instead in adult the most frequent cause of abdominal hernia is iatrogenic defect created post laparoscopic surgery (in particular cholecystectomy, bariatric and gastro-esophagus procedures) during insertion of the port cannula



**Fig. 3.** X ray: gas distension of some intestinal loops in epigastric and right-hypochondriac region with a single air-fluid level in epigastric region.

[10,11]. The first case of falciform hernia was described in 1929 and each decades is characterized by an increasing number of new cases, as such as there is an ever-increasing rate of cases done laparoscopically. This evidence suggests logically the association between the two events [10,15,16]. In the above-described case, the defect did not appear to be iatrogenic because the patient had never undergone abdominal surgical procedures. The nonspecific clinical and laboratory features give to the radiological findings a big role in the diagnosis and the planning of surgical treatment [13].

Multidetector computed tomography (CT), with its thin-section axial images and high-quality multiplanar reformations currently plays an essential role in preoperative diagnosis of internal hernias. The CT findings include detection of an intestinal closed loop, identification of the hernia orifice (if it is possible) and eventually the abnormal displacement of surrounding structures and vessels around the hernia orifice and hernia sac. Detailed knowledge of the anatomy, etiology, and imaging of the various hernia types is also necessary. Familiarity with the appearances of internal hernias at multidetector CT allows accurate and specific preoperative diagnosis. In the above-described case, emergent CT imaging demonstrated between abdominal wall and liver the presence of some dilated ileal loops. One of these was dilated and edematous in the left paramedian region and reduced its caliber in the right paramedian region; the point of stricture (approximately median region) was the supposed falciform ligament site. Furthermore, that ileal loop had thickened wall, decreased contrast enhancement with perivisceral fluid: these signs are suggestive of vascular suffering. On the base of these findings was performed the suspect of an internal hernia in the site of falciform ligament [17–20]. Nevertheless, because of the preoperative diagnosis is very difficult, laparoscopic approach is mandatory and superior to other diagnostic tools, infact in up to 40% of patients it also can correct an erroneous preoperative diagnosis and exclude other abdominal pathological phenomena; plus the laparoscopic approach allows therapeutic correction of the defect during the same intervention [14].

#### 4. Conclusion

Internal hernia is a very uncommon pathology and in particular through the falciform ligament is very rare. In the past decades

it is increasing constantly associated to the always higher number of laparoscopic procedures. Most often discovered in pediatric age because of congenital abnormalities, it must be included in the differential diagnosis also in adults. Preoperative diagnosis is difficult. The diagnostic laparoscopic approach has shown to be the best associated with a safe resolution and a rapid dismissing of the patient.

#### Conflict of interest

There is no conflict of interest to declare.

#### Funding

None.

#### Ethical approval

The paper is not a research study.

#### Consent

Written informed consent was obtained from the patient for publication of this case report.

#### Author contributions

Simona Macina, ideated the study and drafted the article.  
 Simona Macina, acquisition of data, drafting the article.  
 Caterina Losacco, revising it critically for important intellectual content.  
 Tommaso Testa, revising it critically for important intellectual content.

#### Guarantor

Dr. Simona Macina.

## References

- [1] M.A. Meyers, *Dynamic Radiology of the Abdomen: Normal and Pathologic Anatomy*, 4th ed., Springer Verlag, New York, NY, 1994.
- [2] N.V. Jamieson, The falciform ligament window: an unusual site for an internal hernia causing small bowel obstruction, *J. R. Coll. Surg. Edinb.* 32 (1978) 374–375.
- [3] D. Gullino, O. Giordano, E. Gullino, Les hernies de l'abdomen. Apropos de 14 cas, *J. Chir.* 130 (1993) 179–195.
- [4] R.G. Molly, H. Ellamushi, I.S. Smith, Strangulated small bowel hernia of the falciform ligament, *Br. J. Surg.* 79 (1992) 57.
- [5] A. Blunt, G.F. Rich, Intestinal strangulation through an aperture in the falciform ligament, *Aust. N. Z. J. Surg.* 37 (1968) 310.
- [6] L.B. Svendsen, T.S. Johansen, P. Kristensen, Intestinal obstruction caused by an aberrant umbilical vein, *Acta Chir. Scand.* 143 (1977) 191–192.
- [7] D. Mathieu, A. Luciani, Internal abdominal herniation, *AJR Am. J. Roentgenol.* 183 (August (2)) (2004) 397–404 (GERMAD Group).
- [8] G.G. Ghahremani, Abdominal and pelvic hernias, in: R.M. Gore, M.S. Levine (Eds.), *Textbook of Gastrointestinal Radiology*, 2nd ed., Saunders, Philadelphia, PA, 1994.
- [9] S. Wiseman, Internal herniation through a defect in the falciform ligament: a case report and review of the world literature, *Hernia* 4 (2) (2000) 117–120.
- [10] A. Charles, A.A. Shaikh, S. Domingo, et al., Falciform ligament hernia after laparoscopic cholecystectomy: a rare case and review of the literature, *Am. Surg.* 71 (4) (2005) 359–361.
- [11] M.B. Malas, N. Katkhouda, Internal hernia as a complication of laparoscopic nissen fundoplication, *Surg. Laparosc. Endosc. Percutan. Tech.* 12 (2) (2002) 115–116.
- [12] Y. Janin, A.M. Stone, L. Wise, Mesenteric hernia, *Surg. Gynecol. Obstet.* 150 (1980) 747–754.
- [13] C.Y. Fu, W.C. Chang, H.E. Lu, C.J. Su, K.H. Tan, Pericecal hernia of the inferior ileocecal recess: CT findings, *Abdom. Imaging* 32 (2007) 81–83.
- [14] F. Agresta, I. Michelet, E. Candiotto, N. Bedin, Incarcerated internal hernia of the small intestine through a breach of the broad ligament: two cases and a literature review, *JSLs* 11 (2007) 255–257.
- [15] S. Sourtzis, C. Canizares, J.F. Thibeau, P. Philippart, N. Damry, An unusual case of small bowel through an iatrogenic defect in the falciform ligament, *Eur. Radiol.* 12 (2002) 531–533.
- [16] M. Lakdawala, S.R. Chaube, Y. Kazi, A. Bhasker, A. Kanchwala, Internal hernia through an iatrogenic defect in the falciform ligament: a case report, *Hernia* 13 (2) (2009) 217–219.
- [17] S. Doishita, T. Takeshita, Y. Uchima, et al., Internal hernias in the era of multidetector CT: correlation of imaging and surgical findings, *Radiographics* 36 (1) (2016) 88–106.
- [18] J. Egle, A. Gupta, V. Mittal, P. Orfanou, S. Silapaswan, Internal hernias through the falciform ligament: a case series and comprehensive literature review of an increasingly common pathology, *Hernia* 17 (2013) 95–100.
- [19] Hironori Shiozaki, Shintaro Sakurai, Kazuki Sudo, Gen Shimada, Hiroshi Inoue, Seiji Ohigashi, Gautam A Deshpande, Osamu Takahashi, Hisashi Onodera, Pre-operative diagnosis and successful surgery of a strangulated internal hernia through a defect in the falciform ligament: a case report, *J. Med. Case Rep.* 6 (2012) 206.
- [20] O. Armstrong, Internal hernia through the falciform ligament, *Hernia* 17 (2013) 815–816.

## Open Access

This article is published Open Access at [sciendoirect.com](http://sciendoirect.com). It is distributed under the [IJSCR Supplemental terms and conditions](#), which permits unrestricted non commercial use, distribution, and reproduction in any medium, provided the original authors and source are credited.