LICHEN STRIATUS AND LICHEN PLANUS

Report of a Case of Simultaneous Occurrence, with Discussion of Nomenclature and Mechanics of Linear and Systematized Dermatoses*

HERMANN PINKUS, M.D.

The simultaneous occurrence of lichen striatus and lichen planus is extremely rare and the resemblance of one dermatosis to the other is (in some instances) so pronounced that a differential diagnosis, based on clinical manifestations, is difficult.

The patient forming the subject of this report exhibited eruptions of lichen striatus and lichen planus at the same time, during the period in which he was under my observation. It was believed fitting at this time to dedicate this presentation to the memory of Felix Pinkus[1] who has contributed to the knowledge of both affections (1, 2) and also was much interested in the problem of linear distribution of skin diseases in general (3, 4, 5, 6).

The clinical picture, pathology and differential diagnosis of lichen striatus have been discussed completely by Senear and Caro in 1941 (7). I shall restrict myself to a short review of Felix Pinkus' early investigation of this disease in which he analyzed two of his own cases, and collected a number of similar ones from the literature (1). He suggested that these cases form a new peculiar entity which should be separated from such dermatoses as eczema (neurodermite), zoster and linear nevus. The lesions of one of his cases were situated on the left thigh and extended in a broad streak from the region of the major trochanter to that of the patella. The forearm was involved in the other case. The lesions developed fairly suddenly in adult life, caused more or less itching, and disappeared with or without treatment in a few months. The eruption had some similarity to lichen planus, but presented vesicles and crusts in addition to papules. Biopsies were studied in both cases. A particularly careful examination of serial sections of the first case and three-dimensional reconstruction of the inflammatory changes revealed the following. The pathologic changes were found in the upper corium, the papillae, and the epidermis. The inflammation involved the veins in cone shaped areas each of which corresponded to a single papule. From the tip of each cone in the middle corium one blood vessel emerged downward. Its upward ramifications in the second (deeper) and first (superficial) venous nets of Spalteholz (8), were surrounded with small round cells. Making a drawing (Figure 1) of all the involved blood vessels Pinkus found a vascular ring with spoke-like anastomoses, but few connections to

* From the Monroe Hospital, Monroe, Michigan, and The Department of Dermatology, Wayne University Medical College, Detroit, Michigan.

Received for Publication Jan. 28, 1948.

[1] It is for this reason that the bibliography refers mainly to the work of Felix Pinkus. No slight to the many other contributors to these subjects is intended.

neighboring papules. The papillary vessels which are derived from the first venous net emitted swarms of polymorphonuclear leucocytes and probably some fluid exudate into the epidermis. The connection of the epithelial cells had become loosened, and some small vesicular spaces formed. Some papillae were more involved than others, and islands of normal epidermis were found within the clinical papule. No mitoses or other evidence of progressive epidermal alteration were found, and there was no ballooning degeneration as in zoster. The horny layer was partly parakeratotic and contained some corps ronds-like, often nucleated bodies. The inflammatory process in the corium was restricted to the blood vessels. Nerves and skin appendages were not affected although the sweat ducts often were close to the areas of heaviest infiltrate. The author considered these findings sufficient to differentiate the disease from zoster and eczematous dermatitis. He called particular attention to the fact that each

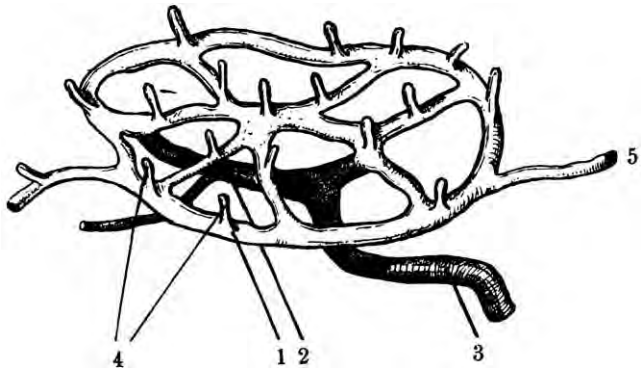

FIG. 1. Reproduction of Felix Pinkus' original Fig. 3 in Dermat. Zeitschr. **11:** 21, 1904. Drawing shows all the blood vessels of one papule which were surrounded by infiltrate. 1. superficial venous net, 2. deeper venous net, 3. vessel leaving the tip of the cone, 4. papillary vessels, 5. anastomosis with neighboring papules.

papule had a definite life cycle of approximately two months, in contrast to the more evanescent, but chronically recurrent lesions of eczematous dermatitis. Lichen planus to which he had devoted a careful histologic study two years previously (2) was not even mentioned in differential diagnosis. Pinkus apparently disagreed with Unna's designation (9) as nevus linearis, of a case in which purely inflammatory, eczema-like changes were found histologically.

CASE REPORT

G. D. E., a white man, aged 37 years, presented himself on June 11, 1945 with a pruritic eruption on his left leg which had started behind the knee some weeks previously and had spread fairly rapidly. About two weeks before his visit he had noticed some lesions on his penis. Examination showed a broad, partly double band of tiny flat somewhat scaly papules of brownish red color which extended from the fibular side of the left calf through the popliteal fossa along the flexor surface of the thigh to the gluteal region. Here the lesions formed sort of a whorl and continued in a transverse band on the glutei. No other lesions on the skin or mucous membranes were found except grayish white flat papules and small plaques on the glans penis and the inner surface of the prepuce. These were typical

of lichen planus. The lesions on the leg while resembling lichen planus were suggestive of lichen striatus, and a biopsy was taken at the distal third of the thigh. The section included a group of fairly large flat, somewhat angular papules.

Histologic examination showed the following: Specimen 3770 (June 11, 1945): The sections contain three or four distinct papules each of which takes in five to seven papillae. The papillary and subpapillary layers contain a fairly diffuse but not very heavy lymphocytic infiltrate which extends downwards as heavy mantles around the blood vessels, and apparently involves mainly the veins. This infiltrate can be followed into the midcorium.

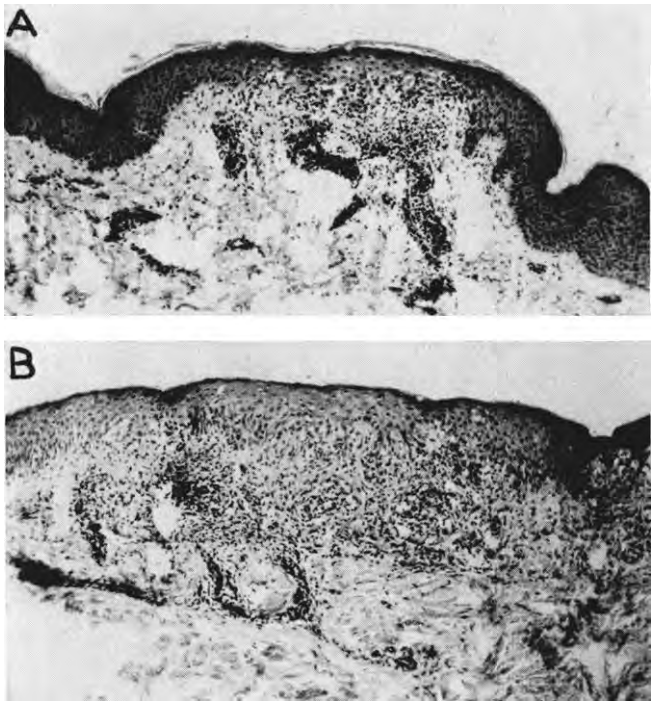

FIG. 2. A. One small papule of the first biopsy from the thigh. Section stained with hematoxylin and eosin. Heavy perivascular infiltrate extends into the midcorium. Epidermis thinned and invaded by leucocytes. B. Second biopsy from the calf. Later stage of lichen striatus. Section stained with hematoxylin and eosin. The infiltrate, though not heavy, outlines the venous nets. Number of cells in the epidermis decreased, keratohyalin layer thin.

The epidermis which covers the papules is thin. Its lower strata are more or less dissolved by edema and transmigrating leucocytes. Many basal cells are transformed into eosinophilic corpuscles with or without nuclei, others retain their basophilism, but their nuclei shrink and the cell membrane becomes denser. Some small vesicles are present in the epidermis. The granular layer is normal in some places, absent in others. The horny layer is partly normal, partly transformed into a parakeratotic scale which usually includes some of the dyskeratotic corpuscles. The papules have no definite relation to follicles or sweat ducts. These findings confirm the diagnosis of lichen striatus.

The patient was given a potent vitamin B complex mixture by mouth. When he returned 18 days later, the eruption on the thigh had undergone partial involution, particularly around the site of the biopsy, while the penile lesions were unchanged. In addition, there were a few new light brownish red, shiny angular papules on the lower abdomen near the

left groin. Another two weeks later, the eruption on the leg was fading, but there remained definite reddish brown papules. There were many new typical lichen planus papules on both sides of the abdomen and on the shaft of the penis. The lesions on the glans and prepuce had extended. Two small biopsies were taken, one near the distal end of the streak at the lower calf, the other one from the left lower abdomen. These were reported as follows:

Specimen 3884 b (July 13, 1945): Sections taken from the abdomen show the papillary and subpapillary layers occupied by a diffuse lymphocytic infiltrate. This has a definite lower border although some blood vessels farther down show some perivascular infiltrate. The epidermis forms a shallow arch over the papule, the granular layer is increased, the horny layer contains no nuclei. The epidermis is separated from the corium by a cleft except in a few places where papillae are preserved. The basal layer is dissolved, many

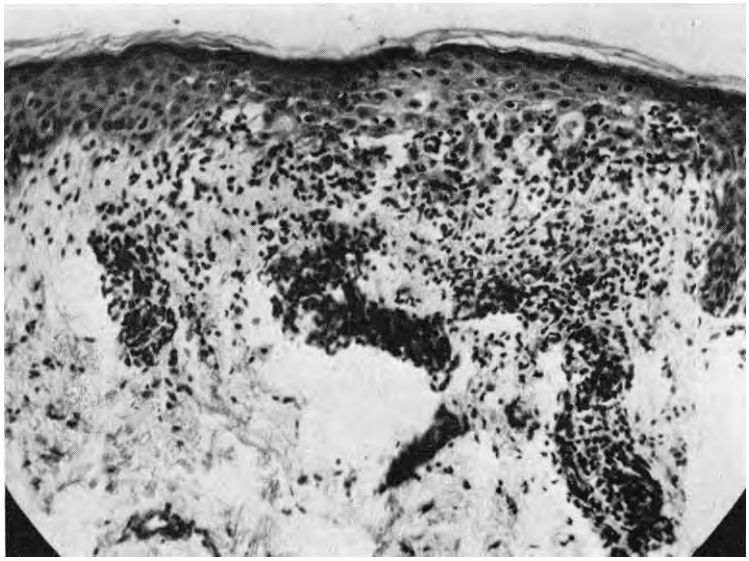

FIG. 3. Higher magnification of part of Fig. 2 A. Dissolution of the lower part of the epidermis, formation of dyskeratotic bodies one of which is seen as a light spot in the keratohyalin layer near the center of the picture. The epidermis is invaded by leucocytes. Perivascular mantles of lymphocytes well visible.

of the basal cells appear as acidophilic anuclear corpuscles in the infiltrate. An occasional such corpuscle is present within the prickle cell layer which otherwise is solid and consists of large pale staining cells without intercellular edema or vesiculation. These findings are characteristic of lichen planus.

Specimen 3884 a (July 13, 1945): Sections taken from the left calf show one fairly large papule. The intensity of the pathologic process varies within the papule. The inflammatory infiltrate surrounds mainly the subpapillary vessels and affects some of the papillae. The deeper vessels show mild lymphocytic involvement. The epidermis shows vacuolization of cells, intercellular edema, and even vesiculation in many places while other parts are more or less normal. Dyskeratotic cells are present in moderate numbers. The granular layer is normal in some places, absent in others. There is spotty parakeratosis. These findings apparently represent a later, more chronic stage of lichen striatus. They are quite different from those of the abdominal biopsy.

On August 8, almost two months after the first visit, while the patient was still taking

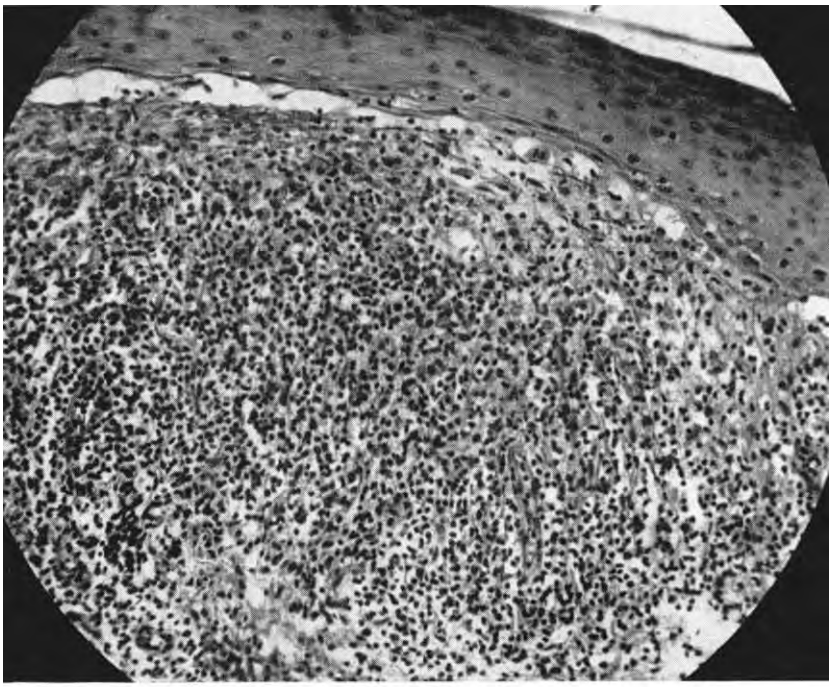

A

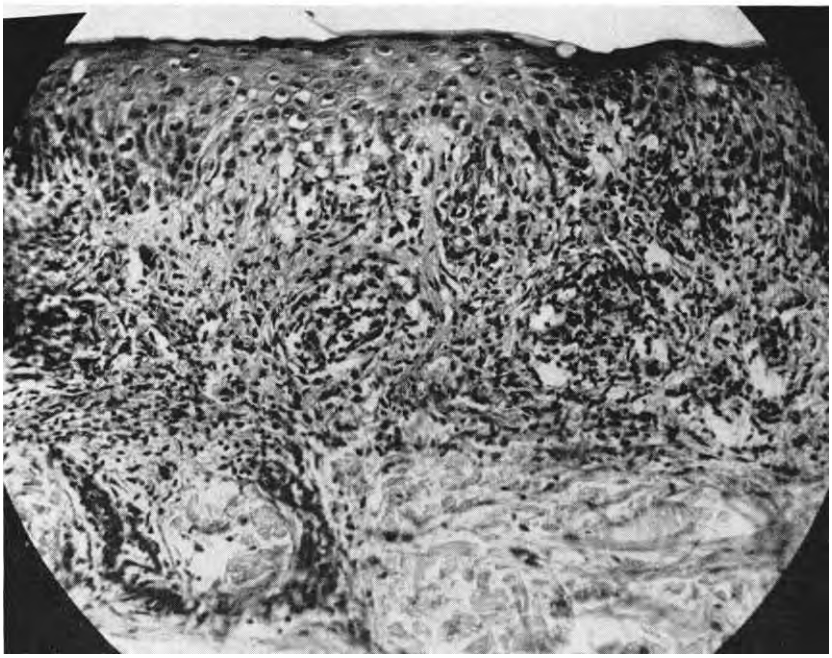

B

FIG. 4. A. AND B. SECTIONS TAKEN ON THE SAME DAY, AND PHOTOGRAPHED AT THE SAME MAGNIFICATION

A. Papule of lichen planus from the abdomen. Section stained with hematoxylin and picric acid—fuchsin S. Typical features of lichen planus as described in the text.

B. Section stained with hematoxylin and eosin. Perivascular infiltrate affects some papillae more than others. The thin epidermis shows intracellular and intercellular edema, dyskeratotic bodies at various levels of the rete, and partial absence of the keratohyalin layer. The parakeratotic horny layer has come off during the preparation of the section.

vitamin B as the only medication, the lichen planus had extended considerably on the abdomen, there were some lesions on the back, and two thirds of the glans and inner surface of the prepuce were solidly covered. The band on the back of the left lower extremity also was again more prominent, but now presented angular brownish red papules fairly typical of lichen planus. The scar of the first biopsy on the thigh had become elevated: it had become the site of a typical small plaque of lichen planus exhibiting Wickham's striation. The patient complained of marked itching.

The patient was now given arsenic by mouth in s'owly increasing doses, and after one week of this medication began to show improvement. This therapy was later supplemented with small doses of filtered roentgen rays to the thoracic and lumbar spine. Two doses of 50 r each at 140 KvP filtered through .25 mm of copper and 1 mm of aluminum were given to the lumbo-sacral spine and one similar dose was given to the thoracic spine. The patient was seen once more on November 9, 1945 at which time the lesions were fading rapidly leaving pigmented spots. The patient returned on October 17, 1947 and reported that all the lesions had disappeared completely except for the pigmentation, but that he now had a recurrence. There were dark purple papules and plaques on both shins, typical lichen planus in both localization and appearance. The previously involved area on the flexor surface of the left leg had remained clear.

COMMENT

These observations leave no doubt that the patient had not only lichen planus, but at the same time the dermatosis which F. Pinkus sought to distinguish from other eruptions and which later was called lichen striatus. It was a fortunate circumstance that a biopsy was taken at the patient's first visit, because lichen planus later developed at the very sites which had before been involved with lichen striatus. I do not believe that this speaks for the identity of the two diseases, nor as evidence of transformation of one into the other. While the latter possibility was considered in the course of the disease it was ruled out by two observations. First, a later biopsy was taken from a lesion which clinically resembled lichen planus considerably, and at a time when new lichen planus papules were developing profusely on other parts of the skin. This section showed only the characteristic picture of lichen striatus. A biopsy taken on the same day from the abdomen showed lichen planus. Second, lichen planus developed in the scar of the first biopsy, and it had been noted that the lichen striatus had disappeared in the neighborhood of this incision earlier and more completely than in other places. It may be asked why lichen planus developed at the sites of the linear dermatosis. Two explanations offer themselves. It may be that the same mechanisms which caused the first eruption also determined the location of the second. Or the first eruption created an area of decreased resistance comparable to those caused by scratching and other injuries which lead to the well known Koebner phenomenon. The latter explanation is suggested by the development of a plaque of lichen planus in the biopsy scar.

The histologic changes in both biopsies corresponded well to Felix Pinkus' detailed description, and also to a case which I examined through the kindness of Dr. Loren Shaffer several years ago (10). These changes are not only different from lichen planus, and certainly from zoster, but do not have much similarity with either eczematous dermatitis or neurodermatitis. The pathologic process

involves the blood vessels principally; the epidermal changes appear to be secondary and quite characteristic. The absence of acanthosis in the presence of considerable spongiosis, even vesiculation, and particularly the peculiar benign dyskeratosis in addition to parakeratosis are not easily found in this combination elsewhere. The heavy mantles of perivascular infiltration were also seen by Senear and Caro who state, however, that the histologic changes are those of eczematous dermatitis.

A few words may be said about the therapeutic aspects of the case. It has been the general experience that lichen striatus develops and disappears spontaneously within some weeks or months, and it is not believed that vitamin B was of benefit in this case. It was surprising, however, to witness the rapid spread of the lichen planus under this therapy. Vitamin B complex was probably first advocated by Epstein (11) as beneficial in lichen planus and it is mentioned in several textbooks. My own experience has shown excellent results in several cases, but had been disappointing in others. In a few, of which this is the most notable instance, it actually seemed to provoke, or at least favor the spread of the eruption.

A feature of exceptional interest is *linear distribution.* This so-called "systematization" of certain dermatoses, both congenital and acquired, has fascinated many authors. Senear and Caro have presented the various facts and theories in their paper in such clear fashion that repetition is superfluous. However, I want to mention two aspects of the problem to both of which Felix Pinkus has contributed in his publications. One concerns nomenclature, the other one the predilection of linear dermatoses for certain localities, particularly for the flexor surface of thigh and leg, as in this patient.

It has become a widespread habit to use the term "linear" and "zoniform" or "zosteriform" almost synonymously. The last terms refer to the well known fact that zoster (zona) involves those areas of skin which are supplied by fibers from one (occasionally several) spinal segments and therefore usually follows a more or less bandlike pattern according to the distribution of the nerves which contain fibers of that segment. That zoniform does not necessarily mean linear is well exemplified by a case of zoniform lichen planus published by Felix Pinkus in 1904 (4). The distribution which was strictly unilateral and corresponded to the distribution of the anastomosing cutaneous branches of the fourth and ninth spinal segments covered a roughly rhomboid area on the right side of the neck and upper chest. On the other hand, there are many linear dermatoses which do not follow segmental distribution at all. Apparently none of the various structural systems of linear distribution which affect the skin can be made responsible for all cases of linear arrangement. Senear and Caro concluded that all one can safely say is that certain fragile zones exist in the skin without attempting to specify their cause. It may be best to retain the old term "systematized" for such cases which are not plainly "linear", but which suggest that they are arranged according to some determining system.

There is no doubt that the flexor surface of the lower extremity is one of the

sites of predilection for systematized dermatoses. It was suggested a long time ago that these lesions follow the so-called Voigt's internal boundary line which separates the distribution of nerves from the lumbar and sacral plexus. Fischel and Pinkus (3) published three cases, one of lichen planus, one of lichen chronicus (neurodermite), and one in which opinion was divided between lichen planus and lichen scrofulosorum. All of these deviated from Voigt's line by extending from the knee on the posterior and lateral surface of the leg to the region of the small toe rather than to the medial side and the big toe. The eruption in my case apparently followed the same pattern although it did not extend beyond the calf. The most distal lesions were on the fibular, not on the tibial side.

Fischel and Pinkus stated that these eruptions follow in general the distribution of the second (in some instances also the first) sacral segment, as was the case in my patient. They offered, however, another possible explanation which may warrant further investigation. Pointing out that the direction of the lines conforms in general with Langer's lines of cleavage, they contended that this still does not explain the singling out of one particular line. They suggested that this line may represent a maximum or minimum of tissue-tension, a zone important to the mechanical equilibrium in the skin, and that it merely coincides with the course of the nerves which is influenced by the same mechanical factors.

SUMMARY

The case of a man is presented who exhibited lichen planus of the glans penis and a linear eruption on the flexor surface of the left lower extremity. The latter dermatosis was diagnosed as lichen striatus on the basis of the histologic findings which are held to be distinctive. The linear eruption faded gradually while the lichen planus spread on the penis and abdomen and later occupied the area of the linear dermatosis. The possibility that this is comparable to Koebner's phenomenon is considered. No evidence of transmutation of lichen striatus into lichen planus was found. The nomenclature and mechanics of systematized dermatoses are discussed with particular reference to Felix Pinkus' contribution to this field.

REFERENCES

1. Pinkus, Felix: Ueber eine besondere Form strichfoermiger Hautausschlaege. Dermat. Zeitschr. **11:** 19–27, 1904.
2. Pinkus, Felix: Zur Kenntnis des Anfangsstadiums des Lichen ruber planus. Arch. f. Dermat. Syph. **60:** 163–178, 1902.
3. Fischel, L. und Pinkus, F.: Strichfoermige Hautausschlaege am Bein. Dermat. Zeitschr. **9:** 123–129, 1903.
4. Pinkus, Felix: Lichen planus zoniformis. Dermat. Zeitschr. **12:** 216–222, 1905.

4a. Pinkus, Felix: Beitrag zur Naevuslokalisation. Spiraliger Naevus der Thoraxgegend und gekreuzte Naevi. Dermat. Zeitschr. **16:** 483–489, 1908.

5. Pinkus, Felix und Ledermann, Reinhold: Beitrag zur Histologie und Pathogenese der Darierschen Krankheit. Arch. f. Dermat. & Syph. **131:** 360–377, 1921.
6. Pinkus, Felix: Lichen ruber moniliformis Kaposi. Arch. Dermat. & Syph. **54:** 472–474, 1946.

7. Senear, F. E. and Caro, M. R.: Lichen striatus. Arch. Dermat. & Syph. **43**: 116–133, 1941.
8. Spalteholz, Werner: Blutgefaesse der Haut. Jadassohn's Handbuch der Haut- und Geschlechtskrankheiten, vol. 1, I, pg. 418–419, 1927.
9. Unna, Paul G.: The Histopathology of the Diseases of the Skin, New York, McMillan & Co. 1896. pg. 1148.
10. Shaffer, Loren: A case for diagnosis (linear eruption). Arch. Dermat. & Syph. **40**: 305, 1939.
11. Epstein, Stephan: Discussion of a case of Lichen Planus Hypertrophicus, presented by Dr. J. F. Madden. Arch. Dermat. & Syph. **41**: 620–621, 1940.