



CLINICAL CASE

Total loss of the covering of a metallic stent during esophageal leak treatment

J.J. Villarreal-Galvan, J.A. Gonzalez-Gonzalez*, H.J. Maldonado Garza

Gastroenterology and Endoscopy Division, Hospital Universitario Jose E. Gonzalez, Monterrey, Mexico

Received 15 February 2012; accepted 16 July 2012

Available online 30 January 2013

KEYWORDS

Esophageal stent;
Benign leak;
Complication;
Mexico

PALABRAS CLAVE

Stent Esofágico;
Fuga benigna;
Complicación;
México

Abstract A 41-year-old man underwent a Heller myotomy due to achalasia. An unexpected puncture in the esophageal wall was identified during the procedure. A partially covered 15 cm stent (PSEMS) (UltraFlex) was placed at the mucosal defect. It was removed 26 days later and the endoscopic image showed esophageal tissue embedded in the covered portion of the stent. PSEMS covering loss is a rare complication that can have serious consequences.

© 2012 Asociación Mexicana de Gastroenterología. Published by Masson Doyma México S.A. All rights reserved.

Pérdida total de la cubierta del stent metálico en el tratamiento de una fuga esofágica

Resumen Se presenta el caso de un hombre de 41 años de edad al cual se le realizó una miotomía de Heller por acalasia. Durante el procedimiento se identificó una punción inadvertida de la pared del esófago. Se decide la aplicación de un stent parcialmente cubierto (PSEMS) de 15 cm (UltraFlex) sobre el defecto de la mucosa. El stent fue removido 26 días después y la imagen endoscópica mostró la presencia de crecimiento de tejido esofágico sobre la sección cubierta del stent. La pérdida de la cubierta de las PSEMS es una complicación infrecuente que, sin embargo, puede llevar a serias complicaciones.

© 2012 Asociación Mexicana de Gastroenterología. Publicado por Masson Doyma México S.A. Todos los derechos reservados.

Introduction

Covered self-expandable metallic stents, initially developed to avoid esophageal malignant tissue in- and/or over-growth, are now being used successfully to treat other disorders such as anastomotic leaks, benign strictures, caustic injury stenoses, aorto-esophageal fistula, and spontaneous perforations.^{1,2} The development of covered stents

* Corresponding author at: S/N. Mitras Centro, Monterrey, Nuevo Leon, Mexico. Tel.: +52 818 333 3664.

E-mail address: joseagonz@yahoo.com (J.A. Gonzalez-Gonzalez).

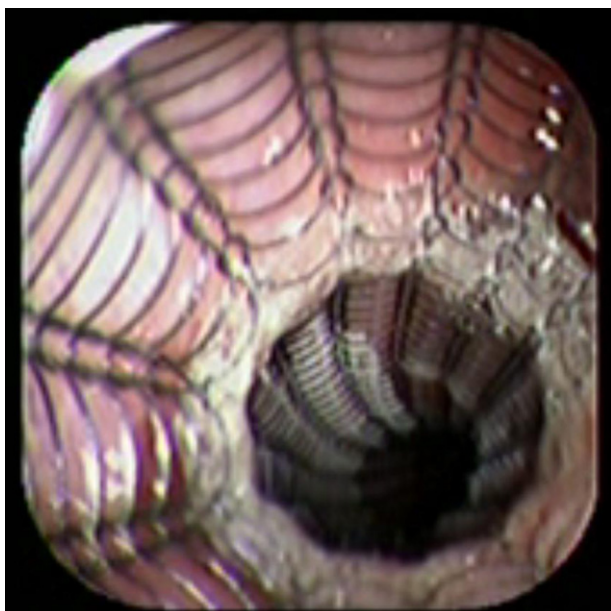


Figure 1 The image shows the stent application.

has increased the possibility to make them removable and potentially useful in benign GI disease.³⁻⁵ We present the case of a patient with an esophageal leak treated with a partially covered self expandable metallic stent (PSEMS).

Case report

A 41-year-old man underwent elective laparoscopic Heller myotomy for achalasia; during the procedure a perforation of the esophageal wall was observed, and primary closure of the defect was attempted. The patient started with PO on day three, but he complained of chest pain and fever. Immediately CT scan with oral contrast was performed. A free leakage at esophago-gastric junction was observed. A 15 cm PSEMS (Ultraflex esophageal NG covered (120 mm) stent, Boston Scientific, Natick, MA) was placed across the defect, leading to the distal 1.5 cm non cover into the stomach and the proximal 1.5 cm non cover at 30 cm from incisor (Fig. 1). A control CT scan with oral contrast showed good position of the stent, without evidence of leakage. The patient's clinical status improved and began to swallow normally, but showed numerous episodes of reflux despite PPI use. We leave the PSEMS for 26 days beside the reflux symptoms. During the endoscopic procedure to remove the stent the presence of tissue embedding along the covered portion of the PSEMS was noted (Fig. 2). The stent was pulled out with an alligator forceps with out major complications and the cover of the PSEMS was seen to be totally destroyed (Fig. 3).

Discussion

With the possible new applications of PSEMS in benign GI disease, one of the main concerns is about the duration and characteristics of the cover. The currently available esophageal stents are easy to insert and can usually be removed safely within a few weeks of the placement.⁶ Actually, the PSEMS are not FDA approved in benign GI diseases,

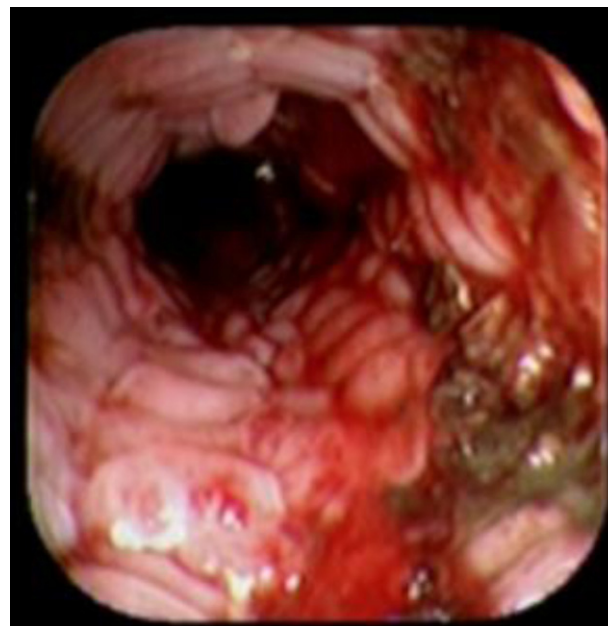

Figure 2 The image shows the presence of tissue embedment along the covered portion of the PSEMS.

but are used as alternative treatment in some particular cases.⁷

The Ultraflex covered stent is made of silicone a material with a good resistance to heat and acid exposure. The PSEMS complications are severe and expensive (stent in stent method or surgery).⁸ The used of covered self-expanding metallic stents for intra-thoracic leakage treatment after esophageal perforations had reported effectiveness of 77%, with a complications rate of 5.6–16%.^{2,9}

In a PubMed search, we found a few reports about the safety and complications (damage of the cover) of PSEMS in

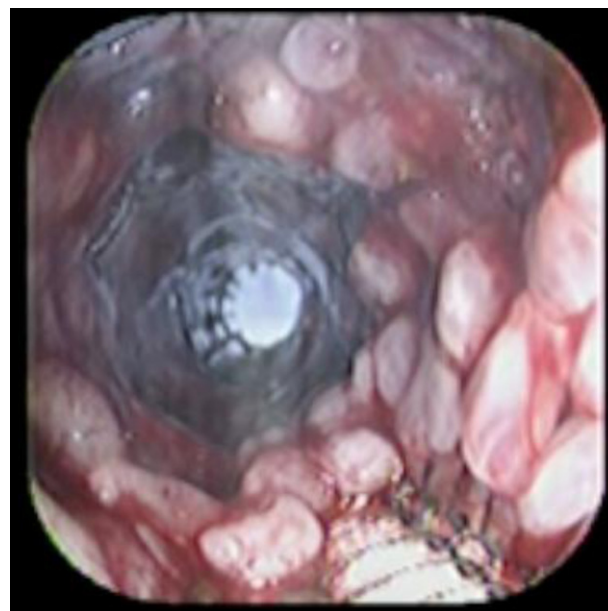


Figure 3 After removal of the stent, the image shows total destruction of the covered portion.

benign GI disease. Recently, the stent migration and tissue embedding became one of the most frequent complications of the PSEMS.¹⁰ One study about the use of PSEMS in benign GI diseases showed cover rupture (Ultraflex) in seven of twenty-three cases.¹¹ Another study, including 71 stents placement, reports a clinical effectiveness and mortality of 76% and 2% respectively. But, 19/71 stents need to be removed early because stent complications and 8/19 stents had tissue in- and/or overgrowth. However, the article does not specify whether tissue in- and/or overgrowth was on the cover or in the bare area of the stent.¹⁰

In our report, even when the PSEMS was early removed (26 days), the cover was totally destroyed. As we mentioned early, the patient suffered severe reflux episodes despite use of double doses of PPI and head bed elevation. We think that the use of PPI may totally suppress the gastric acid content and alkaline reflux was present. The alkaline content could be one important factor in damaging the stent cover. We have the theory that the tissue contact with the biliar content promotes an inflammatory and pro-thrombotic response that could be the potential explanation of early in- and/or tissue overgrowth in the bare area of the stent.¹²

More information is required about the use of PSEMS in benign esophageal disease. Several questions about the covered need to be answered: 1) the potential role of alkaline-acid reflux, 2) durability of the cover, 3) time of stent removal. In our experience we may recommend endoscopic surveillance of the stent and to removed it in less than 3 weeks.

Due to likely increase in the number indications of covered and PSEMS in benign GI diseases, we believe that a complete reevaluation of the stent composition is needed to avoid potentially fatal complications.

Funding

There was no funding for the implementation of this article.

Conflicts of interests

The authors have no conflicts of interest to declare.

References

1. Dai Y, Chopra S, Kneif S, et al. Management of esophageal anastomotic leaks, perforations, and fistulae with self-expanding plastic stents. *J Thorac Cardiovasc Surg.* 2011;141:1213–7.
2. David EA, Kim MP. Esophageal salvage with removable covered self-expanding metal stents in the setting of intrathoracic esophageal leakage. *Am J Surg.* 2011;202:796–801.
3. Thomas T, Abrams KR, Subramanian V, et al. Esophageal stents for benign refractory strictures a meta-analysis. *Endoscopy.* 2011;43:386–93.
4. García-Cano J, Jimeno-Ayllón C, Morillas-Ariño MJ, et al. Iatrogenic esophageal perforation sealed by means of a self-expanding metal stent. *Rev Esp Enferm Dig.* 2012;103:648–9.
5. Van Heel NC, Haringsma J, Wijnhoven BP, et al. *Gastrointest Endosc.* 2011;74:44–50.
6. Doniec JM, Schniewind B, Kahlk V, et al. Therapy of anastomotic leaks by means of covered self-expanding metallic stents after esophagogastrectomy. *Endoscopy.* 2003;35:652–8.
7. López-Viedma B, Lorente-Poyatos R, Domper-Bardají F, et al. Utilidad de las prótesis autoexpandibles biodegradables en el tratamiento de estenosis benignas refractarias. Estudio de una serie de casos. *Rev Gastroenterol Mex.* 2011;76:81–8.
8. Sharma P, Kozarek R. Role of esophageal stents in benign and malignant diseases. *Am J Gastroenterol.* 2010;105:258–73.
9. Yan SL, Chen CH, Yeh YH, et al. Endoscopic removal of an embedded partially covered esophageal self-expandable metallic stent by overtube technique. *Endoscopy.* 2011;43:E400–1.
10. Greenwald BD, Oosterveen S. Esophageal stents. *US Gastroenterol Rev.* 2006;24–6.
11. van Boeckel PGA, Dua KS. Fully covered self-expandable metal stents (SEMS), partially covered SEMS and self expandable plastic stents for the treatment of benign esophageal ruptures and anastomotic leaks. *BMC Gastroenterol.* 2012;12:19.
12. Cura M, Cura A. Causes of TIPS dysfunction. *AJR.* 2008;191:1751–7.