

- arteriosus and coronary artery bypass grafting. *Jpn J Thorac Cardiovasc Surg* 1998;46:1024-7.
11. Sugimoto T, Takahashi T, Inui K, Minowa T, Watanabe T, Shimazaki Y. Aneurysm of the ductus diverticulum in adults: the diagnostic value of three-dimensional computed tomographic scanning. *Jpn J Thorac Cardiovasc Surg* 2003;51:524-7.
  12. Dake MD, Miller DC, Semba CP, Mitchell RS, Walker PJ, Liddell RP. Transluminal placement of endovascular stent-grafts for the treatment of descending thoracic aortic aneurysms. *N Engl J Med* 1994; 331:1729-34.
  13. Bell RE, Taylor PR, Aukett M, Sabharwal T, Reidy JF. Mid-term results for second-generation thoracic stent grafts. *Br J Surg* 2003;90:811-7.
  14. Criado FJ, Barnatan MF, Rizk Y, Clark NS, Wang CF. Technical strategies to expand stent-graft applicability in the aortic arch and proximal descending thoracic aorta. *J Endovasc Ther* 2002;9(Suppl 2):II32-8.
  15. Saccani S, Nicolini F, Beghi C, Marcato C, Uccelli M, Larini P, et al. Thoracic aortic stents: a combined solution for complex cases. *Eur J Vasc Endovasc Surg* 2002; 24:423-7.
  16. Vos AW, Linsen MA, Wisselink W, Rauwerda JA. Endovascular grafting of complex aortic aneurysms with a modular side branch stent-graft system in a porcine model. *Eur J Vasc Endovasc Surg* 2004;27:492-7.
  17. Schneider DB, Curry TK, Reilly LM, Kang JW, Messina LM, Chuter TA. Branched endovascular repair of aortic arch aneurysm with a modular stent-graft system. *J Vasc Surg* 2003;38:855.
  18. Bley J, Schol F, Vanhandenhove I, Vercaeren P. Side-branched modular endograft system for thoracoabdominal aortic aneurysm repair. *J Endovasc Ther* 2002;9:838-41.
  19. Inoue K, Hosokawa H, Iwase T, Sato M, Yoshida Y, Ueno K, et al. Aortic arch reconstruction by transluminally placed endovascular branched stent graft. *Circulation* 1999;100(Suppl):II316-21.
  20. Inoue K, Iwase T, Sato M, Yoshida Y, Tanaka T, Kubota Y, et al. Clinical application of transluminal endovascular graft placement for aortic aneurysms. *Ann Thorac Surg* 1997;63:522-8.
  21. Inoue K, Sato M, Iwase T, Yoshida Y, Tamaki S, et al. Clinical endovascular placement of branched graft for type B aortic dissection. *J Thorac Cardiovasc Surg* 1996;112:1111-3.
  22. Imai Y, Urayama S, Uyama C, Inoue K, Ueno K, Kuribayashi S, et al. A system for computer-assisted design of stent-grafts for aortic aneurysms using 3-D morphological models. *Cardiovasc Intervent Radiol* 2001; 24:277-9.
  23. Okada K, Shinoka S, Ishikawa T, Sato H, Kuji T, Tomino T. A case report of aneurysm of the diverticulum of the ductus arteriosus. *Kyobu Geka* 1993;46:1144-7.
  24. Hattori T, Hirata K, Shimizu S. Aneurysm of the diverticulum of the ductus arteriosus. *Nippon Kyobu Geka Gakkai Zasshi* 1994;42:150-5.
  25. Shichijo T, Suehiro K, Sakakibara H, Okada M, Yoshida H, Ohba O. A case report of aneurysm of the diverticulum of the ductus arteriosus in the elderly. *Kyobu Geka* 1994;47:299-301.
  26. Jinno T, Tago M, Yoshida H, Yamane M. Aneurysm of the diverticulum of the ductus arteriosus in the adult with left pneumonectomy: report of a case. *Kyobu Geka* 2002;55:803-6.

Submitted May 17, 2004; accepted Aug 31, 2004.

### CORRECTION

In: "Flow-induced neointimal regression in baboon polytetrafluoroethylene grafts is associated with decreased cell proliferation and increased apoptosis" (Berceli SA, Davies MG, Kenagy RD, and Clowes AW. *J Vasc Surg* 2002;36:1248-55).

On page 1251, in the "Results" portion of the "Materials and Methods" section, Fig 1, C is incorrect. The black and white bars representing high and low flow were reversed. The following is the correct figure:

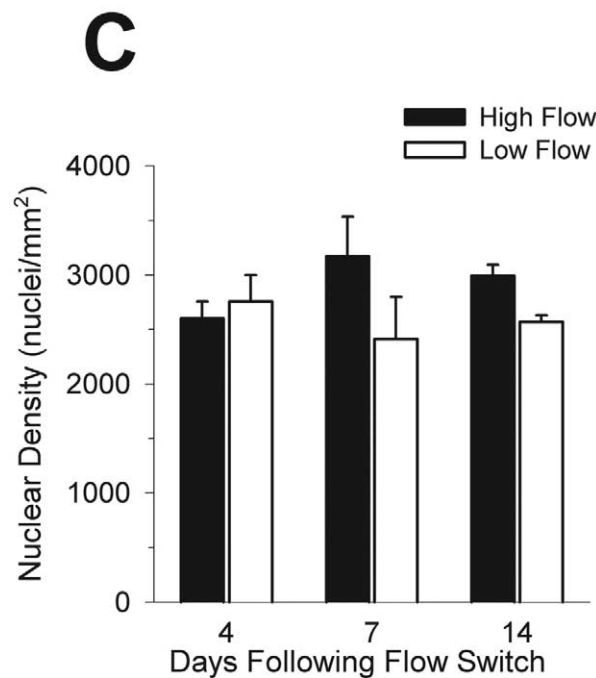


Fig 1. Neointimal SMC proliferation (BrdU labeling index; A), apoptosis (TUNEL labeling index; B), and nuclear density (C) in normal-flow and high-flow grafts after fistula placement. Values are mean  $\pm$  standard error of mean.