



Clinical letter

Focal seizure, focal dyskinesia, or both? A complex motor phenomenon reveals anti-NMDAR encephalitis



Elena Freri^a, Sara Matricardi^{a,b}, Mara Patrini^a, Simona Binelli^c, Francesca Andretta^d, Federica Teutonico^e, Nardo Nardocci^a, Tiziana Granata^{a,*}

^a Department of Pediatric Neuroscience, Foundation I.R.C.C.S. Neurological Institute C. Besta, Milan, Italy

^b Department of Pediatrics, University of Chieti, Chieti, Italy

^c Clinical Neurophysiology and Epilepsy Center, Foundation I.R.C.C.S. Neurological Institute C. Besta, Milan, Italy

^d Neuromuscular Diseases and Neuroimmunology Unit, Foundation I.R.C.C.S. Neurological Institute C. Besta, Milan, Italy

^e Child and Adolescence Neuropsychiatry Unit, "G. Salvini" Hospital, Rho, Italy

ARTICLE INFO

Article history:

Received 25 October 2014

Received in revised form 31 January 2015

Accepted 5 February 2015

1. Introduction

Encephalitis associated with anti-N-methyl-D-aspartate-receptor (NMDAR) antibodies is a potentially treatable disease characterized by the abrupt onset of a constellation of symptoms resulting from diffuse central nervous system (CNS) dysfunction. The disease may be associated with ovarian teratoma in young women, runs a multistage course, and can benefit from early immunomodulatory treatment [1].

In children, movement disorders (MD) and seizures are frequently reported to mark the disease onset, nonetheless only few papers focus on the semiology of these symptoms [2,3].

We report a young girl in whom anti-NMDAR-encephalitis presented with a complex paroxysmal motor phenomenon, which combined a focal MD and focal motor seizure.

2. Case report

A 7-year-old girl presented with right-sided focal motor seizures, while awake. The EEG recorded bilateral delta activity over the frontal regions, and left frontal sporadic epileptic abnormalities. Brain magnetic resonance imaging (MRI), performed by epilepsy protocol, was normal. Carbamazepine was started, but switched early on to valproate because of seizure persistence. The cerebrospinal fluid (CSF) analysis, 18 days after seizure-onset, was normal,

including oligoclonal bands and microbiological studies. In the following days a complex motor phenomenon, which mainly involved the right lower limb, appeared.

At our first observation, some days after seizure onset, the neurological examination revealed the presence of continuous hyperkinesias and a mild dystonic posturing of the lower limbs more prominent on the right, which impaired walking and persisted during sleep.

The video-EEG-polygraphy demonstrated that the motor phenomenon resulted from the combination of MD and seizures: sub-continuous asymmetric dystonic-hyperkinetic movements of the lower limbs, not associated with EEG changes (Fig. 1A), were intermingled with bilateral but asymmetric clonic rhythmic jerks, more evident on the right. The clonic jerks were time-related with an ictal discharge starting from vertex and left centro-parietal region, and spreading to posterior regions (Fig. 1B and Video). Interictally, the background activity was irregular, with bilateral high-voltage delta waves over the anterior regions; the sleep pattern was poorly organized. Focusing on the association of MD and epileptic seizures, we hypothesized anti-NMDAR-encephalitis. History recall revealed that insomnia, mood change, loss of interests and social interaction preceded of a few days the onset of motor disorder.

Neuropsychiatric evaluation revealed depressive mood, normal mental abilities (TIQ 106 at the WISC-IV), but deficits in sustained attention, and in semantic and phonemic verbal fluency.

Anti-NMDAR-antibodies on the previously taken CSF confirmed the diagnosis; abdominal MRI failed to detect ovarian teratoma.

One month after symptom onset, the girl was given intravenous pulses of methylprednisolone (20 mg/kg/d for 5 days), followed by oral prednisone and monthly intravenous immunoglobulins (IVIG).

Three days after steroid was started, the frequency of paroxysmal events markedly reduced. The girl was able to walk unassisted, mood improved, and the wake-sleep cycle regularized. Twenty days later, while given IVIG, symptoms completely recovered. The serial video-EEG-polygraphy confirmed the disappearance of paroxysmal symptoms, the progressive reduction of slow activity and of epileptic abnormalities. In the following

* Corresponding author at: Department of Pediatric Neuroscience, Foundation I.R.C.C.S. Neurological Institute C. Besta, Via Celoria 11, 20133 Milan, Italy. Tel.: +39 02 23942210; fax: +39 02 23942181.

E-mail address: granata@istituto-besta.it (T. Granata).

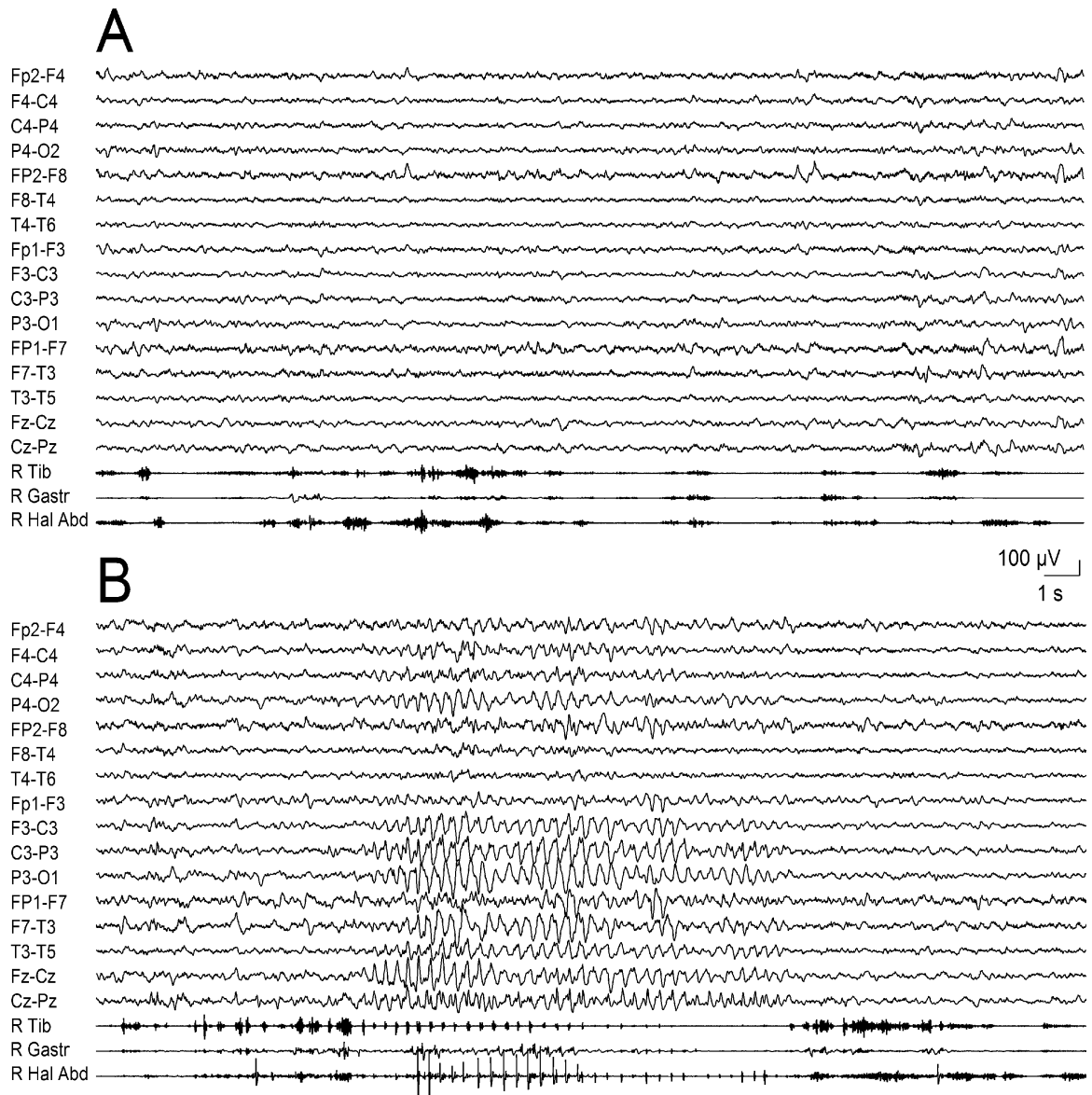


Fig. 1. EEG during drowsiness: (A) the EMG channels record the subcontinuous movement disorder not associated with EEG changes. (B) the hyperkinesias intermingle with rhythmic myoclonic jerks at 3.5 Hz, which are associated with a discharge of sharp-waves and slow waves, starting from the vertex and left centro-parietal region (C3-P3, Fz-Cz), and spreading to the posterior regions of both hemispheres. At seizure end the movement disorder recurs.

months valproate was withdrawn. At the last observation, six months after the disease onset, the girl was asymptomatic.

The neuropsychiatric re-evaluation revealed normalization of all cognitive functions, except for mild deficits in phonemic verbal fluency.

3. Discussion

Anti-NMDAR-encephalitis is increasingly recognized in adults and children. Disease onset is usually marked by psychiatric disorders in adults, whereas MD and seizures dominate in children. MD of different types and severity have been described, including repetitive and pseudo-rhythmic movements of the limbs, complex stereotypes (sometimes mimicking voluntary movements), orofacial dyskinesias, and dystonic posturing. The coexistence of different MD in a given patient and their persistence during sleep are two peculiar features of anti-NMDAR-encephalitis [3].

Motor or complex seizures, and epileptic status, are reported in the early stages particularly in younger patients [1].

In our patient, MD and seizures were strictly focal, involved the same body segment, and their combination was so tight to result in an apparently single paroxysmal event. The stereotyped semiology and the persistence of the symptom during sleep initially led to the misdiagnosis of focal epilepsy. The video-EEG-polygraphy was of paramount importance in identifying the coexistence of cortical and subcortical symptoms, and suggested the diagnosis. The persistence of dyskinesias during sleep in anti-NMDAR-encephalitis have already been described; a possible relation with status dissociatus has been suggested, given that almost invariably the sleep pattern becomes destructured in these patients [3].

In its typical presentation, anti-NMDAR-encephalitis is characterized by the association of several neuropsychiatric disorders; mild or incomplete phenotypes have been only rarely reported [4]. Although motor symptoms dominated the clinical picture, our patient was not oligosymptomatic. The careful recall of medical

history revealed that mild typical symptoms of the disease, namely sleep and mood disorders preceded the onset of motor phenomena. This is in line with previous reports on large series of patients, which underscore that the majority of patients features at least four symptoms of the clinical spectrum (seizures, MD, cognitive, behaviour, psychiatric, and sleep disturbance, autonomic symptoms, decrease of consciousness) within four weeks from the onset [1]. The bilateral anterior delta EEG activity consistently recorded in our patient and the poor sleep organization gave further evidence that the brain dysfunction was not limited to the areas involved in the motor symptoms.

Finally, the dramatic improvement of symptoms observed after treatment underscores that the rapid recognition of symptoms may prompt an early diagnosis and targeted treatment. In this respect, it is worth noting that in our patient seizures and MD did not benefit from AEDs but disappeared after immunotherapy. This is consistent with the putative inflammatory origin of symptoms: B-cell activation and production of autoantibodies induce internalization and the ensuing reduction of NMDA-receptors, which in turn may lead to altered neurotransmission (inactivation of GABAergic neurons, loss of glutamate homeostasis) and neuronal misfiring. In this view restoring receptor functioning is crucial for symptoms recovery.

4. Conclusions

Our case demonstrates that in anti-NMDAR-encephalitis MD and seizures may be intermingled, and that video-EEG-polygraphy

is mandatory in the assessment of complex paroxysmal events. Non-motor symptoms may be subtle and deserve a focused recall of medical history. A proper and early treatment may rapidly revert symptoms.

Conflict of interest statement

None of the authors has any conflict of interest to disclose.

Appendix A. Supplementary data

Supplementary data associated with this article can be found, in the online version, at <http://dx.doi.org/10.1016/j.seizure.2015.02.005>.

References

- [1] Titulaer M, McCracken L, Gabilondo I, Armangué T, Glaser C, Iizuka T, et al. Treatment and prognostic factors for long-term outcome in patients with anti-NMDA receptor encephalitis: an observational cohort study. *Lancet Neurol* 2013;12:157–65.
- [2] Gataullina S, Plouin P, Vincent A, Scalais E, Nuttin C, Dulac O. Paroxysmal EEG pattern in a child with N-methyl-D-aspartate receptor antibody encephalitis. *Dev Med Child Neurol* 2011;53:764–7.
- [3] Stamelou M, Plazzi G, Lugaresi E, Edwards MJ, Bhatia KP. The distinct movement disorder in anti-NMDA receptor encephalitis may be related to status dissociatus: a hypothesis. *Mov Disord* 2012;27:1360–3.
- [4] Hacoen Y, Dlamini N, Hedderly T, Hughes E, Woods M, Vincent A, et al. N-methyl-D-aspartate receptor antibody-associated movement disorder without encephalopathy. *Dev Med Child Neurol* 2014;56:190–3.