



Egyptian Society of Anesthesiologists
Egyptian Journal of Anaesthesia

www.elsevier.com/locate/egja
 www.sciencedirect.com



Case report

Postendovascular thoracic aortic repair subclavian steal syndrome revealed by severe headache



S. Mhamdi *, M.S. Nakhli, M. Chelly, A. Chouchene, A. Chaouch, W. Naija, R. Said

*Department of anesthesia and intensive care, Sahloul Academic Hospital, Sousse, Tunisia
 Faculty of Medicine Ibn El Jazzar, University of Sousse, Tunisia*

Received 28 August 2014; accepted 23 March 2015
 Available online 9 April 2015

KEYWORDS

Subclavian steal syndrome;
 Thoracic endovascular aortic repair;
 Left subclavian artery occlusion;
 Headache;
 Carotid-subclavian artery bypass

Abstract Subclavian steal syndrome (SCSS) has been known since 1960 in the medical literature. Its principal cause is atherosclerosis responsible of occlusion of the subclavian artery (SCA). It is the pathological process in which blood flows in reverse direction from the vertebral artery (VA) to the SCA. Usually asymptomatic, but a variety of symptoms may develop involving the vertebro-basilar and/or the carotid territories and may be precipitated by exercise of the upper extremity. In some circumstances it can be iatrogenic complicating the course of a thoracic endovascular aortic repair (TEVAR) when the left SCA is covered by the endoprosthesis, which is a necessity many times giving the frequent proximity of the acute thoracic pathologies to the origin of this vessel.

We present a case of severe headache occurring after a TEVAR with intentional coverage of the origin of the left SCA. This headache was the only symptom from which the patient complained, and which disappeared immediately after carotid-SCA bypass. Other devastating complications can happen, which gave as a concern about the management of SCA when decision to practice a TEVAR is taken.

© 2015 Production and hosting by Elsevier B.V. on behalf of Egyptian Society of Anesthesiologists.

1. Résumé

Le syndrome de l'artère sous-clavière voleuse est connu dans la littérature médicale depuis 1960. Sa principale cause est l'athérosclérose responsable de la thrombose de l'artère sous-clavière (ASC). C'est le processus pathologique dans lequel le sang circule à contre-courant de l'artère vertébrale vers l'ASC. Habituellement asymptomatique, mais plusieurs symptômes peuvent être vus allant du plus bénin jusqu'au plus

grave reflétant une souffrance dans le territoire vertébro-basilaire et/ou carotidien. Dans certaines circonstances il peut être iatrogène compliquant la mise en place de prothèse endovasculaire de l'aorte thoracique (PEVAT). Dans ce cas l'ASC gauche est souvent obturée par nécessité vu la grande fréquence des lésions au niveau de l'aorte horizontale. La possibilité de survenue de complications graves, bien que rares, nous a incité à soulever le problème de gestion de l'ASC quand une PEVAT est indiquée.

Nous présentons le cas d'une céphalée atroce survenue après PEVAT avec occlusion intentionnelle de l'ASC. Cette céphalée était le seul symptôme dont le patient se plaignait de, et a disparu après un pontage *carotido-sous clavier*.

* Corresponding author.

Peer review under responsibility of Egyptian Society of Anesthesiologists.

<http://dx.doi.org/10.1016/j.egja.2015.03.005>

1110-1849 © 2015 Production and hosting by Elsevier B.V. on behalf of Egyptian Society of Anesthesiologists.

2. Mots clés

syndrome de vol sous-clavier; prothèse endo-vasculaire de l'aorte thoracique; occlusion de l'artère *sous-clavière gauche*; *céphalée*; *pontage carotido-sous clavier*.

3. Observation

Patient B.H 63 year old, admitted to cardiovascular surgery (03/04/2014) for aneurysm of the horizontal aorta discovered when exploring a dyspnoea progressively increasing since 2 years. The patient had a history of a polytrauma in 1990 with chest injury and right ankle fracture operated by osteosynthesis. He was reoperated in 2008 for left inguinal hernia under spinal anaesthesia.

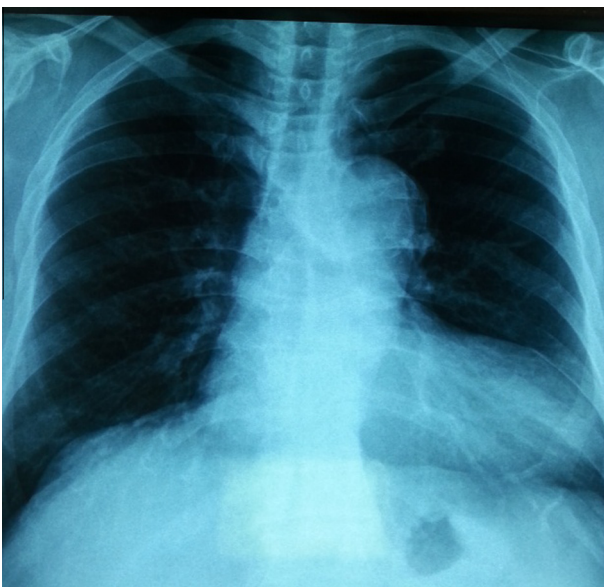The clinical examination found a dyspnoea NYHA III. The chest X-ray showed a cardiomegalia (**Photograph 1**). The electrocardiogram and the biologic screening were normal.

The angioscan showed a sacciform aneurysm with calcified wall located in the aortic isthmus measuring 6 cm at the major axis, downstream of the emergence of the left SCA (**Photograph 2**). He was proposed for TEVAR.

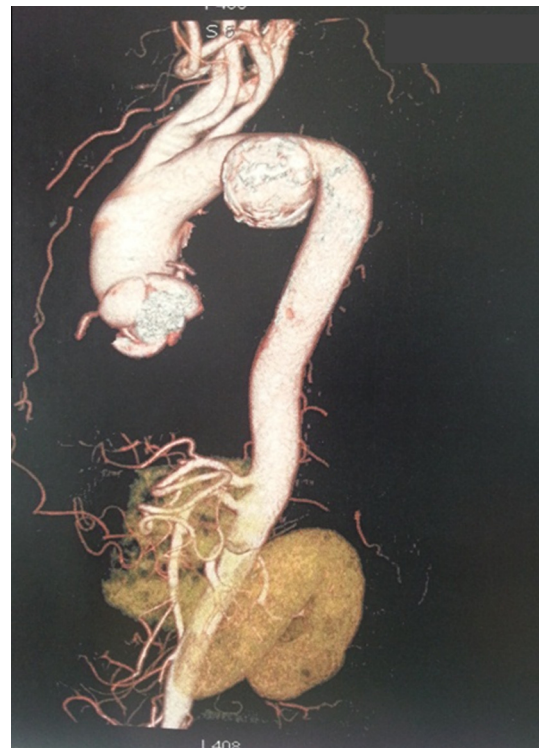The procedure was done under general anesthesia in the interventional radiological room of the radiology department (05/04/2014) and it has lasted 55 min.

The intra-operative hemodynamic profile was correct, we realized a controlled hypotension during the deployment of the prosthesis fixed with success upstream of the origin of the left SCA. Many apnea periods were necessary for radiologic image acquisitions.

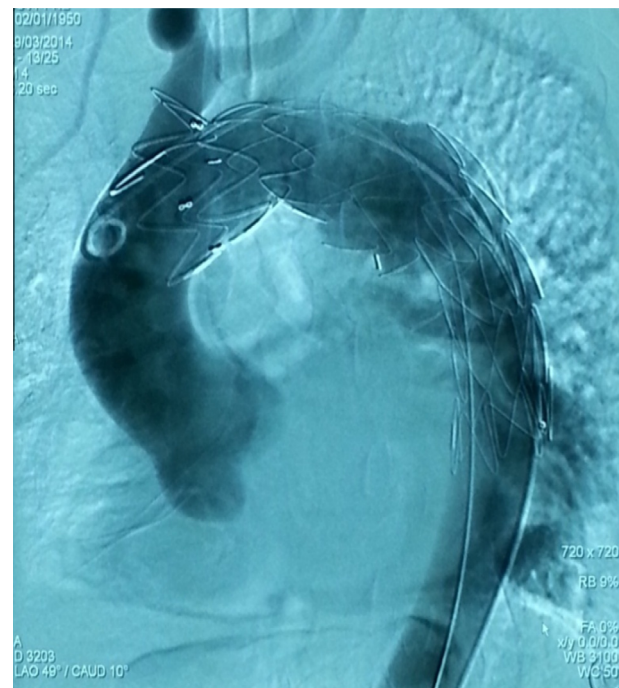
We monitored the arterial oxygen saturation (SpO₂) at the level of the two upper limbs, a desaturation (SpO₂ = 89%) was noted for twenty minutes on the left side which was normalized after (SpO₂ = 98%) testifying the obstruction of the left SCA and the eventual SCSS.



Photograph 1 Chest X-ray cardiomegalia.



Photograph 2 Sacciform aneurysm.



Photograph 3 Complete coverage of aneurysm.

The final radiological control objectified a complete coverage of the aneurysm and the ostium of the left SCA (**Photograph 3**).

The immediate post interventional evolution was simple eventless and the patient returned home after 6 days under 100 mg of aspirin per day.

Shortly after, the patient experienced a severe continuous headache happening even at rest and worsening at effort. No ischemic signs on the left upper limb.

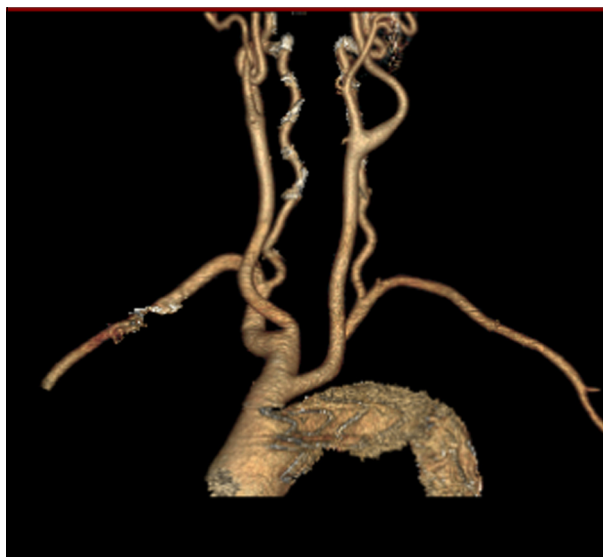A thoracic angioscan with opacification of the neck vessels showed a thrombosis of the left subclavian artery from its origin up to 45 mm above, the same vessel is reinjected in a retrograde manner from the VA defining a vertebro-subclavian steal phenomenon (Photograph 4).

The diagnosis of SCSS is confirmed and explained the symptomatology. The retrograde (reversed) flow of blood to the clogged left SCA from the VA at the expense of the vertebra-basilar circulation is responsible itself for the headache. A carotid–subclavian bypass under general anesthesia was then done giving end to the headache and the two months patient's suffering.

4. Discussion

TEVAR, as minimally invasive procedure, has changed enormously the aortic medicine treating various thoracic aortic pathologies, including aneurysm, dissection, trauma, fistula, and penetrating ulcer. It offers a valid treatment option for the elderly patients at high risk for open surgery, but also for fit patients. Particularly, in a polytrauma context where patients are multiply injured. This new technique known by its simplicity and the reduced mortality and morbidity compared to open repair encounters some challenges and difficulties facing the multidisciplinary team realizing it [1–3].

One of these problems is the management of the left SCA. In fact up to 40% of patients undergoing TEVAR have pathology that extends near the left SCA [4]. In these frequent situations the endografts are typically placed over the left SCA origin and consequently occluding this arch vessel. Robert after review of the literature mentioned that rates of SCA coverage range between 10% and 50% [5].



Photograph 4 Thrombosis of the left subclavian artery.

Covering the left SCA is not without consequences because there is less blood supplying the left arm and the VA, which plays a critical role in irrigating the posterior cerebral lobe, the cerebellum, and the spinal cord. Thus Subclavian stenosis is most often asymptomatic and therefore do not need any treatment [5,6].

Infrequent but devastating cases of neurologic and ischemic complications related to left SCA coverage have forced operators to re-examine indications for elective revascularization [5].

The term “subclavian steal syndrome” should only be used in cases where this aberrant blood flow causes symptoms, because completely reversed flow in the VA does not always indicate SCSS [7]. In general, symptoms can be separated as ischemia of the left upper extremity and/or posterior cerebral circulation and spinal cord. In the minority of patients who manifest symptoms, arm claudication is the most common complaint, consisting of exercise-induced arm pain or fatigue. Occasionally, coolness or paraesthesia in the extremity may be noted at rest or with exertion. Unilateral reversal of vertebral flow may cause vertebra-basilar transient ischemic attacks in rare circumstances. Upper extremity exercise, by reducing arterial resistance, increases blood flow to the arm and can precipitate lateralizing symptoms of vertebra-basilar insufficiency among persons without sufficient collateral flow. Similarly, a steal phenomenon may also occur in dialysis patients with an ipsilateral arteriovenous fistula. Vertebro-basilar insufficiency presents classically as “drop attacks,” but may also manifest as dizziness, diplopia, nystagmus, tinnitus, or even hearing loss. Finally, a coronary-subclavian steal phenomenon may occur in patients who have undergone coronary artery bypass graft if a stenosis occurs in the SCA proximal to the takeoff of an internal mammary artery graft utilized to perfuse the heart. If arterial flow demand is increased in another vascular bed, as with ipsilateral upper extremity exercise, a share of the coronary circulation may be “stolen”, leading to angina or even infarction [5,6].

We must bear in mind that the SCSS may have unusual presentations [8–10] and therefore the diagnosis have to be recalled and ruled out in front of any symptom reflecting insufficiency in the vertebro-basilar and or carotid territories. Our patient presented with a severe headache, although mentioned in the literature as possible presentation in SCSS [11], we did not find any reported similar case mentioning the headache as the only sign post-TEVAR and reflecting the coverage of left SCA. The headache is reported to be a sign of meningeal hemorrhage following cerebro-spinal fluid (CSF) drainage during TEVAR [12]. In fact the drainage of CSF is used by many teams to reduce the risk of SCI and related paraplegia [13].

We did not realize this prophylactic drainage for our patient and his headache is solely directly related the steal subclavian phenomenon. Also the headache is reported as one of the symptoms of an aortic dissection type A which had developed during endovascular repair of acute type B dissection [14].

Even after many years of experience in the TEVAR, there have been conflicting data in the literature with regard to intentional left SCA coverage, and there is no consensus on the management of this vessel for traumatic aortic injury [15].

Antonello et al. concluded that the coverage of the left SCA during TEVAR for traumatic aortic injuries appears to be a feasible, safe method for extending the endograft landing zone without increasing the risk of paraplegia, stroke, or left arm

ischemia [15]. Published reports mention the average risks of adverse outcomes in patients who have TEVAR and left SCA coverage: 6% arm ischemia, 4% spinal cord ischemia, 2% vertebrobasilar ischemia, 5% anterior circulation stroke, and 6% death [15].

Cooper et al. in a systematic review and meta-analysis of the literature, concluded with caution that the risk of neurologic complications is increased after coverage of the left SCA during TEVAR. Preemptive revascularization offers no protection against cerebral vascular accident, perhaps indicating an heterogeneous etiology. Revascularization may reduce the risk of spinal cord ischemia (SCI) [16].

This was not the conclusion in another systematic review and meta-analysis where Adnan et al. mentioned that very low quality evidence suggests that left SCA coverage increases the risk of arm ischemia, vertebra-basilar ischemia, possibly SCI and anterior circulation stroke [17].

Means that reduce these risks are important to consider. Several options have been described that allow patency of the left SCA to be maintained, including preoperative left SCA revascularization by elective debranching before TEVAR, the hybrid repair by combining endovascular and open repair, the chimney technique by deploying a left SCA stent parallel to the thoracic endograft, prefabricated branched endograft deployment, or surgeon modified endografts [18–22].

Disposing many of these methods of maintaining antegrade perfusion to the left SCA, the focus became on when indicating the SCA revascularization during TEVAR.

The recommendations for SCA revascularization under elective circumstances for the following conditions [5,23]:

1. Diminutive, atretic, or absent (posterior inferior cerebellar artery syndrome or vertebra-basilar discontinuity) right SCA;
2. Patent left internal mammary artery coronary bypass Graft;
3. Patent left axillary femoral bypass graft;
4. Functional (patent and usable) left arm arteriovenous shunt in a patient either already on or imminently requiring hemodialysis;
5. Left-handedness;
6. Aberrant origin of the left vertebral artery from the aortic arch; and
7. Extensive thoracic aortic coverage with history of prior abdominal aortic replacement or concomitant unrepaired abdominal aortic aneurysm.

In our hospital the experience with TEVAR is just beginning, and till now we have done four cases: three young men and our present patient who is relatively old and who is the only one to manifest neurologic complications. Is it related to the cerebral vascularization made fragile by the age? Should we perform preoperatively cervico-cerebral imaging to check the adequacy of the cerebral vascularization? And indicate then the SCA revascularization in case of abnormalities when TEVAR will need SCA coverage?

Some teams having experience in the field do so. For example at the University of Florida, they typically perform a head–neck–chest–abdomen–pelvis (from the occiput to the greater trochanter) Computed Tomography Angiography (CTA) as a single timed-bolus study using a multirow detector scanner.

Vertebral anatomy and the circle of Willis are reconstructed using three-dimensional postprocessing to determine adequacy of the contralateral circulation. Rarely, confirmatory angiography at the time of the procedure is required in cases of an equivocal or suboptimal CTA and the operator should be prepared to proceed with SCA revascularization based on these findings [5].

Ertan et al. indicated in his paper that some large series reported in the literature including patients with SCSS proven by Doppler ultrasonography have showed that most of the patients were asymptomatic and the symptoms related to vertebra-basilar ischemia were rare. Thus, these studies showed that reversal of blood in the VA does not cause neurological symptoms in the majority of patients with SCSS [8]. Furthermore, Walker et al. suggested that the majority of patients with SCSS have neurological symptoms actually due to other vascular lesions [24]. This can explain that the only patient who developed a neurologic complication is the only aged one from our four patients, with the possibility that the manifestation of the condition is probably dependent on the patency of the other cranial arteries which we should have checked as many teams do [25–27].

5. Conclusion

TEVAR has changed drastically the aortic medicine offering a valid treatment option avoiding all the difficulties and the challenges experienced when doing the traditional open repair especially when dealing with elderly or polytrauma patients. It improves the short and the mid-term mortality and morbidity. However specific complications have seen the light after many years of practice, and are still subject of controversies on how to avoid them or how to manage them when it happens. One of these is the SSS related to the coverage of the origin of the left SCA.

Usually asymptomatic, but the SSS can manifest by a variety of symptoms ranging from benign to devastating ones. Sometimes unusual presentations are in the foreground and the diagnosis has to be raised and ruled out. A great debate and a rich data in the literature covered the subject, clarifying and giving many solutions on how to manage the SCA during TEVAR.

Conflict of interest

The authors declare that there are no conflicts of interest.

References

- [1] Starnes BW. Treating blunt aortic injuries with endografts: pros and cons of a meta-analysis. *Semin Vasc Surg* 2010;23:176–81.
- [2] Tang GL, Tehrani HY, Usman A, Katariya K, Otero C, Perez E, et al. Reduced mortality, paraplegia, and stroke with stent graft repair of blunt aortic transections: a modern meta-analysis. *J Vasc Surg* 2008;47:671–5.
- [3] Fattori R, Russo V, Lovato L, Di Bartolomeo R. Optimal management of traumatic aortic injury. *Eur J Vasc Endovasc Surg* 2009;37:8–14.
- [4] Matsumura JS, Lee WA, Mitchell RS, Farber MA, Murad MH, Lumsden AB, et al. The society for vascular surgery practice guidelines: management of the left subclavian artery with thoracic endovascular aortic repair. *J Vasc Surg* 2009;50:1155–8.

- [5] Feezor RJ, Lee WA. Management of the left subclavian artery during TEVAR. *Semin Vasc Surg* 2009;22:159–64.
- [6] Potter BJ, Pinto DS. Subclavian steal syndrome. *Circulation* 2014;129:2320–3.
- [7] Chen SP, Hu YP, Fan LH, Guan LJ. Completely reversed flow in the vertebral artery does not always indicate subclavian steal phenomenon. *Ultrasound Med Biol* 2014;40:1072–82.
- [8] Ertan S, Tanriverdi T, Kiziltan G. Subclavian steal syndrome with an unusual presentation. *J Clin Neurosci* 2003;10:699–701.
- [9] Conlin S, Fenning SJ, Weir G, Raza Z, Phelps RG, Gifford FJ. Sudden, severe headache: an unexpected culprit. *Lancet* 2014;383:754.
- [10] Lim VW, Flynn CA, O'Connor M, Lyons D. 20-year-old injury: an unusual cause of stroke. *BMJ Case Rep* 2013;19:2013.
- [11] Lum CF, Ilsen PF, Kawasaki B. Subclavian steal syndrome. *Optometry* 2004;75:147–60.
- [12] Mancio J, Pires-Morais G, Bettencourt N, Oliveira M, Santos L, Melica B, et al. Meningeal haemorrhage secondary to cerebrospinal fluid drainage during thoracic endovascular aortic repair. *Oxf Med Case Rep* 2014;3:56–9.
- [13] Wong CS, Healy D, Canning C, Coffey JC, Boyle JR, Walsh SR. A systematic review of spinal cord injury and cerebrospinal fluid drainage after thoracic aortic endografting. *J Vasc Surg* 2012;56:1438–47.
- [14] Fanelli F, Salvatori FM, Marcelli G, Bezzi M, Totaro M, Vagnarelli S, et al. Type A aortic dissection developing during endovascular repair of an acute type B dissection. *J Endovasc Ther* 2003;10:254–9.
- [15] Antonello M, Menegolo M, Maturi C, Dall'antonia A, Lepidi S, Frigo AC, et al. Intentional coverage of the left subclavian artery during endovascular repair of traumatic descending thoracic aortic transection. *J Vasc Surg* 2013;57:684–90.
- [16] Cooper DG, Walsh SR, Sadat U, Noorani A, Hayes PD, Boyle JR. Neurological complications after left subclavian artery coverage during thoracic endovascular aortic repair: a systematic review and meta-analysis. *J Vasc Surg* 2009;49:1594–601.
- [17] Rizvi AZ, Murad MH, Fairman RM, Erwin PJ, Montori VM. The effect of left subclavian artery coverage on morbidity and mortality in patients undergoing endovascular thoracic aortic interventions: a systematic review and meta-analysis. *J Vasc Surg* 2009;50:1159–69.
- [18] Redlinger RE, Ahanchi SS, Panneton JM. In situ laser fenestration during emergent thoracic endovascular aortic repair is an effective method for left subclavian artery revascularization. *J Vasc Surg* 2013;58:1171–7.
- [19] Hogendoorn W, Schlösser FJ, Moll FL, Sumpio BE, Muhs BE. Thoracic endovascular aortic repair with the chimney graft technique. *J Vasc Surg* 2013;58:502–11.
- [20] Shahverdyan R, Gawenda M, Brunkwall J. Triple-barrel graft as a novel strategy to preserve supra-aortic branches in arch-TEVAR procedures: clinical study and systematic review. *Eur J Vasc Endovasc Surg* 2013;45:28–35.
- [21] Bell KE, Lopez AC. Hybrid repair of thoracoabdominal aneurysms: a combined endovascular and open approach. *J Vasc Nurs* 2008;26:101–8.
- [22] Weimann S, Willeit H, Flora G. Direct subclavian-carotid anastomosis for the subclavian steal syndrome. *Eur J Vasc Surg* 1987;1:305–10.
- [23] Kotelis D, Geisbüsch P, Hinz U, Hyhlik-Dürr A, von Tengg-Koblick H, Allenberg JR, et al. Short and midterm results after left subclavian artery coverage during endovascular repair of the thoracic aorta. *J Vasc Surg* 2009;50:1285–92.
- [24] Walker PM, Paley D, Harris KA, Thompson A, Johnston KW. What determines the symptoms associated with subclavian artery occlusive disease? *J Vasc Surg* 1985;2:154–7.
- [25] Grabenwöger M, Alfonso F, Bachel J, Bonser R, Czerny M, Eggebrecht H, et al. Thoracic Endovascular Aortic Repair (TEVAR) for the treatment of aortic diseases: a position statement from the European Association for Cardio-Thoracic Surgery (EACTS) and the European Society of Cardiology (ESC), in collaboration with the European Association of Percutaneous Cardiovascular Interventions (EAPCI). *Eur J Cardiothorac Surg* 2012;42:17–24.
- [26] Rehders TC, Petzsch M, Ince H, Kische S, Korber T, Koschik DH, et al. Intentional occlusion of the left subclavian artery during stent-graft implantation in the thoracic aorta: risk and relevance. *J Endovasc Ther* 2004;11:659–66.
- [27] Weigang E, Parker JA, Czerny M, Lonn L, Bonser RS, Carrel TP, et al. Should intentional endovascular stent-graft coverage of the left subclavian artery be preceded by prophylactic revascularisation? *Eur J Cardiothorac Surg* 2011;40:858–68.