



International Journal of Surgery Case Reports

journal homepage: www.casereports.com

Laparoscopic resection of perforated duodenal diverticulum – A case report and literature review



Ting-Chia Yeh

Division of General Surgery, Department of Surgery, Yunlin Christian Hospital, Taiwan

ARTICLE INFO

Article history:

Received 29 July 2016

Received in revised form

29 September 2016

Accepted 2 October 2016

Available online 5 October 2016

ABSTRACT

BACKGROUND: Duodenum diverticulum is the most common site for diverticular disease of small intestine. Most of duodenal diverticulum are asymptomatic, but complicated or perforated duodenal diverticulum is rare. Nonoperative management is attractive in selected patients, because of higher surgical complications. We suggest the use of a minimally invasive operative method as an alternative approach for the management of complicated duodenal diverticulum, especially when conservative treatment has failed.

CASE PRESENTATION: A 67-year-old female was admitted to Emergency Department with sudden onset of severe right upper abdominal pain and fever (38.2 °C) lasted 8 h. Abdominal computed tomographic imaging was performed and a perforated duodenal diverticulum with right-sided anterior pararenal space free air and fluid retention was identified. After assessment and resuscitation, proper treatment modality was selected taking in consideration type, location and complication of duodenal diverticulum. A emergency laparoscopic duodenal diverticulectomy with intraabdominal drainage was performed. Postoperative period was uneventful and patient was discharged on the 10th postoperative day. English literatures discussing laparoscopic management for complicated duodenal diverticulum were carefully reviewed.

CONCLUSIONS: Laparoscopic approach showed less complication, shorter hospital stay and better outcome in comparison to conservative, or open surgery. Laparoscopic approach is safe and feasible in selected cases of complicated duodenal diverticulum (laterally located and protruding duodenal diverticulum). With advances in laparoscopic instruments and techniques, complicated duodenal diverticula can be managed safely by laparoscopically.

© 2016 The Author(s). Published by Elsevier Ltd on behalf of IJS Publishing Group Ltd. This is an open access article under the CC BY-NC-ND license (<http://creativecommons.org/licenses/by-nc-nd/4.0/>).

1. Introduction

Duodenum diverticulum is the most common site for diverticular disease of small intestine. The entity was first reported by Chomel in 1710 and the first well-documented report was by Morgagni in 1762 [8]. Duodenal diverticulum is usually an acquired lesion and 60% of patients older than 40 and predominantly occurs in women [11,16]. Their incidence varies from 0.16% to 22% in among various diagnostic method and duodenal diverticulum are usually asymptomatic [6,11,18]. The most frequent location is the second (62%) and third (30%) portions of the duodenum [1,3]. The preoperative diagnosis of duodenal diverticulum can be made by upper GI barium studies, computed tomographic (CT) scan, upper GI endoscopy or endoscopic retrograde cholangiopancreatography (ERCP) [5,6,16,18].

Symptomatic duodenal diverticulum are 1% to 5%, which present with pain, bleeding, inflammation, cholestasis, obstruction, perforation, cholangitis, pancreatitis, or malignant transformation

[1,3,11]. Complications are rare (about 0.03% per year) but may be very severe, such as chronic abdominal pain, bezoar formation, biliary or pancreatic duct obstruction, hemorrhage, duodenal obstruction and perforation [1,2,18]. Elective surgical treatment of asymptomatic diverticulum is not justified. Endoscopic treatment is usually the first-line approach to biliopancreatic complications related to juxtapiillary duodenal diverticulum and also for diverticulum with hemorrhage or other intraluminal lesion related intestinal obstruction complications [1,6,8,9,15,13,17].

The definitive diagnosis and associated anatomy structure of some complicated duodenal diverticulum, such as diverticulitis, perforation, or obstructive cholangitis, were generally obtained by CT scan before surgery [5]. Perforated duodenal diverticulitis is an uncommon abdominal condition, which is mistaken clinically for acute cholecystitis, pancreatitis and perforated duodenal ulcer. The characteristic CT findings, including an extraluminal air collection and a diverticulum with a thickened wall due to inflammation or a retroperitoneal infiltration with fluid retention. Diagnosis is often delayed because clinical symptoms are not specific and the diagnosis is performed mainly by imaging studies.

E-mail address: 816314@cch.org.tw

<http://dx.doi.org/10.1016/j.ijscr.2016.10.001>

2210-2612/© 2016 The Author(s). Published by Elsevier Ltd on behalf of IJS Publishing Group Ltd. This is an open access article under the CC BY-NC-ND license (<http://creativecommons.org/licenses/by-nc-nd/4.0/>).

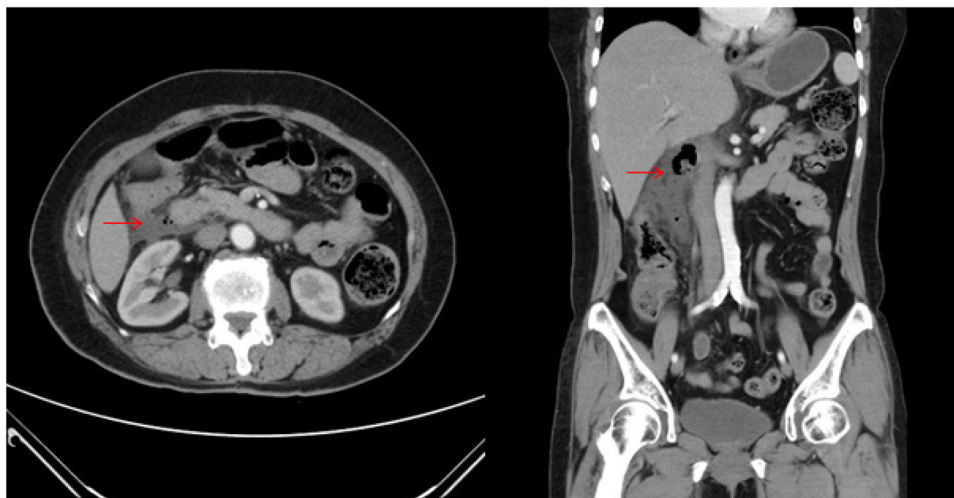


Fig. 1. CT scan evidencing a perforation of duodenum diverticulum with retroperitoneal free air and fluid retention.

The supposed causes of perforation are multiple and include diverticulitis, enterolithiasis, ulceration, iatrogenic perforation during ERCP sphincterotomy, trauma, foreign body and most frequently ischemia due to distention related to food retention inside the diverticulum [1–4,20,21]. In two-thirds of cases, the duodenal diverticulum perforates into the retroperitoneum adjacent to the second portions of the duodenum [1].

Conservative treatment of perforated duodenal diverticulum based on fasting with bowel rest with or without nasogastric suction, intravenous fluid hydration or total parenteral nutrition, and broad-spectrum antibiotics may be offered in some selected cases when diagnosis is made early in stable patients, or in elderly patients and had underlying medical problems [1,4,22]. CT-guided percutaneous drainage for any intra-abdominal abscess may be necessary to complete this conservative medical treatment plan [1,4,23].

Forsell and Cey performed the first open surgical treatment for complicated duodenal diverticulum in 1915 [8,11]. Surgical treatment is reserved for failure of endoscopic or conservative therapy [1,16]. Effective treatment of symptomatic duodenal diverticulum is simple diverticulectomy and two layer closure of the duodenum with drainage of the retroperitoneum [1,16]. Surgical intervention in complicated duodenal diverticulum has high postoperative morbidity and mortality. The main postoperative complication of diverticulectomy is duodenal leak or fistula, which carries up to a 13% to 30% mortality rate [1,16]. Late diagnosis or misdiagnosis causes perforation with a mortality rate of 90% [16].

We present a rare case of perforated diverticulum from the second part of the duodenum and its successful laparoscopic surgical management. Minimally invasive surgery has been associated with less morbidity and early return to work. The aim of this study was to review of the English language literatures of complicated duodenal diverticulum in diagnosis and treatment currently with a special focus on laparoscopic surgical management.

2. Case report

A 67 years old female patient with hypertension, hyperlipidemia, rheumatoid arthritis and insomnia, is admitted to Emergency Department with sudden onset of severe right upper abdominal pain, nausea and poor appetite for the last 8 hours. On arrival her vital signs showed auricular temperature of 38.2°C, heart rate of 84/min and blood pressure of 132/66 mmHg. She had generalized abdominal tenderness and rebounding tenderness with signs of peritoneal irritation. She had leukocytosis

(12900/mm³ with 91.2% neutrophils) and amylase of 109 U/L, with normal liver tests, renal function test, lipase level and arterial blood gases.

Abdominal X-ray showed no intra-peritoneal free air. Computed tomography (CT) of abdomen revealed ruptured extraperitoneal duodenum diverticulum. (Fig. 1)

An urgent operation was performed laparoscopically under general anesthesia with endotracheal intubation in reverse Trendelenburg position with her arms extended to sides. As the first step, abdominal access was obtained above the umbilicus with Veress needle. We created a 12-mmHg intra-abdominal pressure by insufflation of carbon dioxide (CO₂). When proper distension of the abdominal cavity, a 12-mm trocar was inserted above the umbilicus. One 10-mm trocar was inserted on the midline about 15 cm above the umbilicus. A 5-mm trocar was inserted superiorly in the right midclavicular line region and another in the right anterior axillary line region. A 30°, 10-mm camera was used for intraoperative visualization.

The abdominal exploration was performed, profuse irrigation with normal saline to clean and divided using a 5-mm laparoscopic Ligasure device to enter the lesser sac. Transverse colon and hepatic flexure were mobilized, the transverse mesocolon was identified and colonic vasculature was protected. Kocher maneuver was performed and the perforated duodenal diverticulum was grasped carefully and peridiverticular space dissected circumferentially. The neck was well exposed to ensure that no other bile or pancreatic duct structure. The endostapler (Ethicon) blue of 45 mm was inserted through a 12-mm trocar and was directed toward the neck of diverticulum. (Fig. 2) The stapler was fired and the perforated duodenal diverticulum was resected and removed out of the abdomen. A nasogastric tube was placed to the duodenum and leak test was performed. There is hemostasis was controlled and two 16 French closed-suction drain were inserted through the right upper quadrant trocar and placed in subhepatic space and Morrison's pouch. (Fig. 3) The 10- and 12-mm trocar holes were closed. The operative time was 100 minutes. Intraoperative bleeding was minimal.

This patient was admitted in a sepsis condition with empiric antibiotics treatment and the definitive laparoscopic surgical treatment with intraabdominal drainage. She resumed oral intake of food gradually on the sixth postoperative day. Postoperative period was uneventful and patient was discharged on 10th postoperative day. She was asymptomatic and had no complications during the three months follow-up.

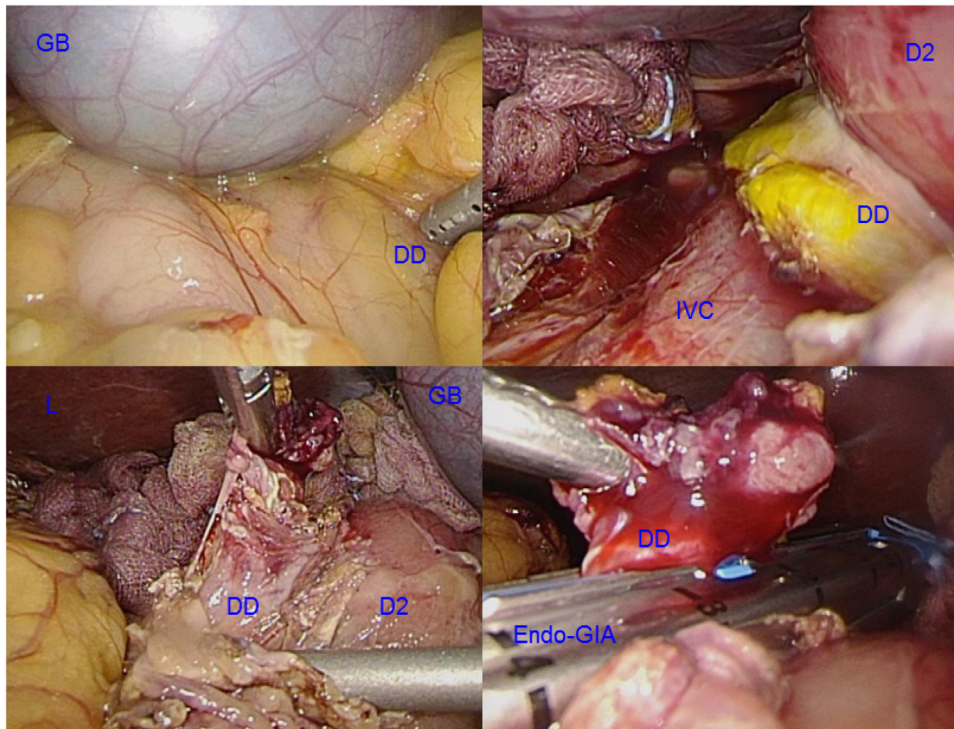


Fig. 2. The perforated duodenal diverticulum (DD) of second portion of duodenum (D2) was identified after warm N/S irrigation and Kocher maneuver. The perforated duodenal diverticulum was grasped carefully and peridiverticular space dissected circumferentially. The Endo-GIA stapler was inserted and fired, then the resected diverticulum was removed. (IVC: inferior vena cava, GB: Gallbladder, L: Liver).

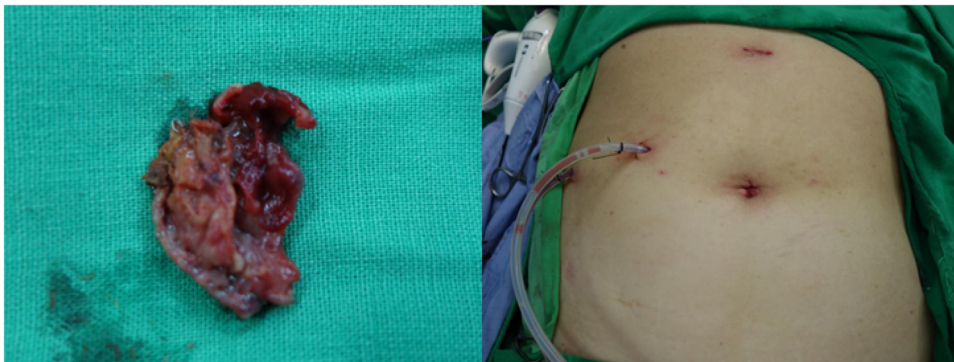


Fig. 3. Surgical specimen. Four trocar sites and two surgical drains were inserted.

3. Discussion

By using a Medline search, a review of the English literature was performed from the first report of laparoscopic surgery of a duodenal diverticulum[9] to the present time (1994 to 2016 [7–19]). We reviewed 13 studies [7–19] published since 1994 producing 14 cases, which were combined with the one at our institution for a total of 15 patients. These reports have been published regarding small patient series of laparoscopic treatment for complicated (perforation, hemorrhage, abdominal pain, bezoar formation, and bile duct or pancreatic duct obstruction) duodenal diverticulum. The data of the reviewed cases are summarized, with a description of patient characteristics, diagnostic methods, and therapeutic results (Table 1).

In the present series, the most common presenting complicated symptom was abdominal pain, seen in 11 patients (73%). The clinical operation indication were chronic abdominal pain with inflammation in eight cases (53%, one of them combined with bezoar), bleeding in three cases (20%), perforation in two cases (13%), obstructive jaundice in one case (7%), and gastric outlet

obstruction in one case (7%). Of the 15 patients who received some diagnostic imaging test during their hospitalization, 9 (60%) underwent UGI series; 7 (47%), CT scan; and 6 (40%), esophagogastroduodenoscopy (EGD). The surgical method were laparoscopic diverticulectomy in twelve cases (80%), one of them combined with Robotic surgery and choledochoduodenostomy, laparoscopic distal gastrectomy and gastrojejunostomy in two cases (13%), and laparoscopic inversion in one case (7%). In our study, the most common location were lateral wall location and second portion of duodenal diverticulum, seen in 8 patients (53%).

Laparoscopic stapled with/without hand-sewn diverticulectomy (1- or 2-layer closure) with drainage of the retroperitoneal space is the most commonly used. There were no deaths and only one mild complication (diarrhea), less hospital stay and early recovery for our series.

Although the treatment method and laparoscopic indication has not yet been conclusively established, our study confirms the safety of laparoscopic approach in treatment of complicated duodenal diverticulum. The location of the diverticulum on the lateral side of duodenum facilitates the laparoscopic treatment. Other locations of

Table 1
Reported Cases of laparoscopic surgery for duodenal diverticulum.

Source	Sex/Age,y	Chief Presenting Symptom	Operation indication	Location in Duodenum Portion/side wall	Method of Diagnosis	Treatment	Complications	Hospital stay (d)
Present study, 2016	F/67	Pain	Perforation	D2PL	CT	Laparoscopic diverticulectomy	None	10
Callery et al, 1994 [9]	M/54	Bleeding	Bleeding	D2	EGD/OR	Laparoscopic diverticulectomy	None	3
Coelho et al, 1999 [10]	M/38	Pain	Pain, Inflammation	D2L	CT/UGI	Laparoscopic inversion	None	1
Tagaya et al, 2000 [12]	M/76	Bleeding	Bleeding	D3L	UGI/EGD	Laparoscopic diverticulectomy	None	X
Gaur et al, 2005 [11]	F/35	Pain	Pain, Inflammation	D2L	UGI	Laparoscopic diverticulectomy	None	5
Mehmet et al, 2009 [19]	F/26	Pain	Pain, Inflammation	D2L	EGD/UGI	Laparoscopic diverticulectomy	None	4
Lee et al, 2010 [7]	F/61	Pain	Perforation	D2PL	CT/OR	Laparoscopic diverticulectomy	None	10
Kella et al, 2010 [13]	F/78	Jaundice	Obstructive jaundice	D2M	CT/EGD/EUS	Laparoscopic duodenal diverticulectomy and choledochoduodenostomy	Diarrhea	6
Matthijs et al, 2011 [18]	F/50	Pain	Pain, Inflammation	D2L	CT/UGI	Laparoscopic diverticulectomy	None	X
K.H. Hutson et al, 2011 [14]	X/X	Pain	Pain, Inflammation	D1	X	Laparoscopic distal gastrectomy and gastro-jejunostomy	None	X
	X/X	Pain	Pain, Inflammation	D1	X	Laparoscopic distal gastrectomy and gastro-jejunostomy	None	X
Dilip et al, 2012 [8]	F/80	Bleeding	Bleeding	D2AM	CT/UGI	Laparoscopic diverticulectomy	None	5
Ahmet et al, 2012 [15]	F/47	Pain	Pain, Inflammation, Bezoar	D2L	CT/EGD/UGI	Laparoscopic diverticulotomy and diverticulectomy	None	7
Meinke et al, 2013 [17]	X/40	Pain	Gastric outlet obstruction(IDD)	D2M	MRCP/Fluoro/UGI	Laparoscopic duodenotomy and diverticulectomy	None	X
Yahya et al, 2015 [16]	F/56	Pain	Pain, Inflammation	D2L	EGD/UGI	Laparoscopic diverticulectomy	None	4

Abbreviations: CT(computerized tomography); EGD(esophagogastroduodenoscopy); UGI(upper gastrointestinal tract series); EUS(endoscopic ultrasound); MRCP(magnetic resonance cholangiopancreatography); Fluoro(fluoroscopy); OR(operating room); D1/D2/D3(first/second/third portion of duodenum); A/P/L/M wall(anterior/posterior/lateral/medial);M(male); F(female); X(unknown).

Table 2
Reported series of Perforated duodenal diverticulum, 1907–2016.

Source	No. of Cases	Treatment: method	Morbidity	Mortality	Hospital stay (d)
All series, 1907–2016	186			16%(30/186)	
Juler et al, 1969 review 1907–1969 [20]	56			34%(19/56)	
Durate et al, 1992 review 1969–1989 [21]	47			13%(6/47)	
Present Series, 1989–2016 [2–5,25–29]	83		23%(19/83)	6%(5/83)	
		Operation(65)	28%(18/65)	8%(5/65)	
		Non-operation(18)	6%(1/18)	0%(0/18)	
Chad et al, 2012 review 1989–2011 [4]	61	Operation(47)	29.5%(18/61)	5%(3/61)	
			36%(17/47)	6%(3/47)	
			Diverticulectomy(23):22 open, 1 laparoscopic(7)Gastric diversion(10);1 Whipple, 7 pyloric exclusion with gastro-enteric anastomosis, 2 DuodenojejunostomyBilio-duodenal drain(5):2 tube duodenostomy, 3 T-tubeDrainage(8):abscess drainageOR, not discussed(7), Primary closure(2), Diverticulum inversion(2), Nutritional jejunostomy(1)		
		Non-operation(14)	7%(1/14)	0%(0/14)	
			Bowel rest, antibiotics(14):3 percutaneous drain, 1 ERCP stent removal		
Thomas de Perrot et al. 2012 [5]	7	Operation(5)	None	20%(1/5)	
		Non-operation(2)	None	None	22
			Diverticulectomy(5) Conservative treatment(2):1 elective duodenojejunostomy after conservative treatment		
Andrea Rossetti et al. 2013 [3]	7	Operation(6)	16.7%(1/6,1 post-diverticulectomy leak)	16.7%(1/6,Drain and laparostomy)	18.7
			Diverticulectomy(5), Bilio-duodenal drain(1), Nutritional jejunostomy(1), Drain and laparostomy(1)		
		Non-operation(1)	Conservative treatment(1)	None	16
Favre-Rizzo et al. 2013 [27]	1	Operation(1)	Diverticulectomy(1)	None	14
Barillaro et al. 2013 [28]	1	Operation(1)	Diverticulectomy(1), Surgical drainage(1)	None	30
Guardado-Bermúdez F et al. 2013 [29]	1	Operation(1)	Diverticulectomy(1)	None	30
Vitor Costa Simões et al. 2014 [2]	1	Operation(1)	Diverticulectomy(1), Duodenojejunostomy(1)	None	12
Haboubi et al. 2014 [26]	1	Operation(1)	Diverticulectomy(1)	None	22
Sanghyun Song et al. 2015 [25]	2	Operation(1)	Diverticulectomy(1)	None	12
		Non-operation(1)	Conservative treatment(1)	None	22
Present study. 2016	1	Operation(1)	Laparoscopic diverticulectomy(1)	None	10

Notes: Lee et al., 2010 [7] first reported laparoscopic diverticulectomy for a case of perforated duodenal diverticulum.

Notes: Laparoscopic diverticulectomy [2]: Lee et al., 2010 [7] and present study, 2016, no any morbidity-mortality, less hospital stay (10days).

Table 3

The mortality rate in the original series of perforated duodenal diverticulum.

Series	No. of Cases	Treatment: method	Morbidity-mortality
1.Juler et al, 1969 review 1907–1969 [20]	56		mortality rate 34%
2.Durate et al, 1992 review 1969–1989 [21]	47		mortality rate 13%
3.Present study 1989–2016	83		morbidity 23%(19/83); mortality 6%(5/83)
		Operation(65)	morbidity 28%(18/65); mortality 8%(5/65)
		non-operation(18)	morbidity 6%(1/18); mortality 0%(0/18)

diverticulum such as duodenal window are less accessible through laparoscopic approach [11].

On the other hand, we reviewed nine studies [2–5,25–29] published (the largest study is Chad et al.) [4] combined with the one at our institution for a total of 83 perforated duodenal diverticulum patients from 1989 to 2016.

Treatment method and result data in the most original series of perforated duodenal diverticulum were analyzed [2–5,20,21,25–29] (Table 2).

Spontaneous perforation of a duodenal diverticulum is a rare but serious complication associated with significant mortality. The causes of perforated duodenal diverticulum included diverticulitis, enterolithiasis, ulceration, foreign bodies and blunt abdominal trauma, with diverticulitis being the major etiology of this complication (71.4%) [4]. Early diagnosis is essential for successful treatment, and CT is helpful for correctly early diagnosis and identify the lesion site (Table 3).

With only 186 cases reported in the world literature since 1907 to 2016, the overall mortality rate in the original series of perforated duodenal diverticulum was 16%. The present study since 1989 to 2016, reported rates of morbidity and mortality of 23% and 6% respectively. The overall outcomes are encouraging, with a low mortality rate and acceptable morbidity. The progressive decrease in mortality and morbidity because of the fact that improvement in perioperative care, development of broad-spectrum antibiotics, proper diagnosis, and increased awareness of this rare entity [4,25]. Other complications remain high, such as duodenal fistulas, intra-abdominal abscesses, traumatic injury to the common bile duct, acute pancreatitis, persistent sepsis, and wound infections [20,21].

Chad et al. [4] suggested that nonoperative management has emerged as a safe, practical alternative to surgery in selected patients. In present series since 1989 to 2016, only 18 patients (22%) undergoing nonoperative management and most patients (65, 78%) undergoing operation. N. Oukachbi et al., reported conservative treatment of perforated duodenal diverticulum based on fasting and broad-spectrum antibiotics may be offered in some selected cases when diagnosis is made early in stable patients, or in elderly patients with comorbidities who are poor operative candidates [1]. However, nonoperative management should be considered in patients who present with mild symptoms [25]. Surgical treatment is currently reserved for failure of endoscopic or conservative treatment. In the present series, the most common surgical treatment method was diverticulectomy(40, 62%), followed by gastric diversion, and surgical drainage.

Surgical diverticulectomy is indicated for perforation that is poorly tolerated or when there has been a delay in diagnosis, and also for massive hemorrhage or failure of endoscopic hemostasis [1]. In tradition, excision of the diverticulum after Kocher maneuver and repairing the defect transversely with 1 or 2 layer closure with surgical drainage as been described most frequently [1,4,7,8,11,24]. More advanced surgery, such as the Whipple procedure may be required when significant perforation and surrounding tissue destruction were present [1,4,7,8,11,24]. Simple suture closure of the duodenal wall after diverticulectomy is associated with a risk of duodenal fistula, which carries a mortality of 20% to 30% [1].

Sometimes in association with a biliodigestive bypass to reduce the risk of duodenal leak or fistula and to reduce morbidity. Several forms of bypass for duodenal exclusion have been proposed, include gastric diversion procedure such as pyloric exclusion with gastro-enteric anastomosis, bilio-duodenal drain, or other surgical drain [1,4]. For juxtapapillary diverticulum, it is essential to correctly identify the course of the papilla and common bile duct from the outset to avoid inadvertent injury [1]. Diverticulum arising in the third and fourth portion of duodenum that develop complications can be managed by diverticulectomy or segmental duodenal resection with duodenojejunostomy on the basis of the neck of the diverticulum is narrow or large [1]. Intraluminal duodenal diverticulum are rare, but are often symptomatic requiring endoscopic or surgical treatment [1].

The laparoscopic approach has been reported rarely in the literature [7,8,11]. Callery et al. reported the first case of laparoscopic resection of a duodenal diverticulum with a stapler in 1994 [9,11]. Coelho et al. reported a case of laparoscopic inversion of a duodenal diverticulum in 1999 [10,11]. Tagaya et al. report another bleeding case treated by laparoscopic diverticulectomy in 2000 [11,12]. Graur et al. reported a case of laparoscopic diverticulectomy of a symptomatic duodenal diverticulum (chronic pain) in 2005 [11]. Mehmet et al. reported a case of laparoscopic diverticulectomy of a symptomatic duodenal diverticulum in 2009 [19]. Lee et al. reported laparoscopic diverticulectomy for a perforated duodenal diverticulum in a 61-year-old woman, where the opening of the diverticulum was closed in 2 layers using an intracorporeal hand-sewn sutures in 2010 [7,8]. Kella et al. reported a case of laparoscopic duodenal diverticulectomy and choledochoduodenostomy in a 78-year-old woman with an abnormal cholestatic liver function profile and dilated common bile duct who complained of upper abdominal pain in 2010 [8,13]. Matthijs et al. reported another case of laparoscopic diverticulectomy of a symptomatic duodenal diverticulum in 2011 [18].

K.H. Hutson et al. report two cases of symptomatic duodenal diverticulum successfully and safely treated by laparoscopic distal gastrectomy or gastric transection with gastrojejunostomy formation in 2011 [14]. Dilip et al. reported a case of laparoscopic management of a large inflamed duodenal diverticulum with massive hemorrhage, and laparoscopic diverticulectomy should be considered in managing hemorrhagic duodenal diverticula in 2012 [13]. Ahmet et al. reported that the laparoscopic approach is a feasible method in selected patients for the management of intestinal bezoars in 2012 [15]. Meinke et al. reported a case of intraluminal duodenal diverticulum related gastric outlet obstruction who to which was treated by laparoscopic duodenotomy and diverticulectomy in 2013 [17]. Yahya et al. reported another case of laparoscopic diverticulectomy of a symptomatic duodenal diverticulum in 2015 [16].

Lee et al., 2010 [7] and our study reported laparoscopic diverticulectomy for a perforated duodenal diverticulum without any morbidity and mortality. Laparoscopic approach showed less complication and shorted hospital stay in comparison to conservative, or open surgery. Despite the small number of cases, we regard laparoscopic treatment of selected patients with perforated duodenal diverticulum as a safe and preferable treatment in the near future.

In selected cases, laparoscopic approach offers good postoperative results, such as cosmetically better outcome, less tissue dissection and disruption of tissue planes, less pain postoperatively, low intra-operatively and postoperative complications, early return to work, better visualization and ability to carry out a thorough peritoneal lavage, early mobilization, and lower mortality. With advances in laparoscopic instruments and techniques, several kinds of complicated duodenal diverticulum had been successfully treated with laparoscopic approach.

4. Conclusions

Although perforated duodenal diverticulum is rare, with only 186 cases reported in the world literature, it required for timely correct diagnosis, clinical disease severity assessment, and properly treatment modality. Conservative treatment may be offered in patients who present with mild symptoms. Laparoscopic approach is easy to reach laterally located and protruding duodenal diverticulum, but it is relatively difficult to access the other parts of the duodenum due to lack of laparoscopic experience. Laparoscopic approach is safe and feasible in selected cases of complicated duodenal diverticulum, it displays shorter hospital stay and better outcome for the patient.

Conflicts of interest

No conflict of interest.

Funding for your research

There is no financial support for this study.

Ethical approval

No ethical approval needed.

Consent

Written informed consent was obtained from the patient.

Author contribution

Ting-Chia Yeh: study design, data collections, data analysis, writing.

Registration of research studies

I have not obtain my unique identifying number(UIN) of my study

Guarantor

Ting-Chia Yeh.

References

- [1] N. Oukachbi, S. Brouzes, Management of complicated duodenal diverticula, *J. Visc. Surg.* 150 (2013) 173–179.
- [2] Vitor Costa Simões, Bruno Santos, Sara Magalhães, Gil Faria, Donzília Sousa Silva, José Davide, Perforated duodenal diverticulum: surgical treatment and literature review, *Int. J. Surg. Case Rep.* 5 (2014) 547–550.
- [3] Andrea Rossetti, Nicolas Christian Buchs, Pascal Bucher, Stephane Dominguez, Philippe Morel, Perforated duodenal diverticulum, a rare complication of a

- common pathology: a seven-patient case series, *World J. Gastrointest. Surg.* 5 (March (3)) (2013) 47–50.
- [4] Chad M. Thorson, Pedro S. Paz Ruiz, Rosiane A. Roeder, Danny Sleeman, Victor J. Casillas, The perforated duodenal diverticulum, *Arch. Surg.* 147 (1) (2012) 81–88.
- [5] Thomas de Perrot, Pierre-Alexandre Poletti, Christoph D. Becker, Alexandra Plato, The complicated duodenal diverticulum: retrospective analysis of 11 cases, *Clin. Imaging* 36 (2012) 287–294.
- [6] Yang-Yuan Chen, Hsu-Heng Yen, Maw-Soan Soon, Impact of endoscopy in the management of duodenal diverticular bleeding: experience of a single medical center and a review of recent literature, *Gastrointest. Endosc.* 66 (4) (2007) 831–835.
- [7] H.H. Lee, J.Y. Hong, S.N. Oh, H.M. Jeon, C.H. Park, K.Y. Song, Laparoscopic diverticulectomy for a perforated duodenal diverticulum: a case report, *J. Laparoendosc. Adv. Surg. Technol. A* 20 (9) (2010) 757–760.
- [8] Dilip Dan, Nigel Bascombe, Ravi Maharaj, Seetharaman Hariharan, Vijay Narayansingh, Laparoscopic diverticulectomy for massive hemorrhage in a duodenal diverticulum, *Surg. Laparosc. Endosc. Percutan. Technol.* 22 (2012) e39–e41.
- [9] M.P. Callery, G. Aliperti, N.J. Soper, Laparoscopic duodenal diverticulectomy following hemorrhage, *Surg. Laparosc. Endosc.* 4 (1994) 134–138.
- [10] J.C. Coelho, G.S. Sousa, P.R. Salvalaggio, Laparoscopic treatment of duodenal diverticulum, *Surg. Laparosc. Endosc.* 9 (1999) 74–77.
- [11] F. Graur, O. Bala, R. Bodea, et al., Laparoscopic resection of duodenal diverticulum. A case report, *Rom. J. Gastroenterol.* 14 (2005) 405–408.
- [12] N. Tagaya, M. Shimoda, K. Hamada, K. Ishikawa, H. Kogure, Laparoscopic duodenal diverticulectomy, *Surg. Endosc.* 14 (June (6)) (2000) 592. Epub 2000 May 15.
- [13] V.K. Kella, E. Shacov, A. Yiengpruksawan, Laparoscopic duodenal diverticulectomy and choledochoduodenostomy: a case study and review of the literature, *J. Rob. Surg.* 3 (2010) 249–252.
- [14] K.H. Hutson, K. Devalia, K.K. Singh, E.J. Moore, Laparoscopic management of symptomatic duodenal diverticulum by distal gastrectomy and gastro-jejunostomy formation, *Int. J. Surg.* 9 (7) (2011) 545.
- [15] Ahmet Pergel, Ahmet Fikret Yucel, Ibrahim Aydin, Dursun Ali Sahin, Laparoscopic treatment of a phytobezoar in the duodenal diverticulum – report of a case, *Int. J. Surg. Case Rep.* 3 (2012) 392–394.
- [16] Yahya Ekici, Gokhan Moray, Large duodenal diverticula treated by laparoscopic surgical excision: a case report, *J. Minim. Invasive Surg. Sci.* 4 (May (2)) (2015) e30196.
- [17] A.K. Meinke, D.M. Meighan, M.E. Meinke, N. Mirza, T.M. Parris, R.K. Meinke, Intraluminal duodenal diverticula: collective review with report of a laparoscopic excision, *J. Laparoendosc. Adv. Surg. Technol. A* 23 (February (2)) (2013) 129–136.
- [18] Matthijs ter Horst, Marieke C. Hovinga-de Boer, Menno H. Raber, Joost M. Klaase, Giant diverticulum of the duodenum, *Gastroenterol. Res.* 4 (6) (2011) 289–293.
- [19] Mehmet Görgün, Taylan Özgür Sezer, Metin Karadeniz, Laparoscopic duodenal diverticulectomy: a case report, *Turk. J. Surg. Issue* 25 (3) (2009) 114–117.
- [20] G.L. Juler, J.W. List, E.A. Stemmer, et al., Perforated duodenal diverticulitis, *Arch. Surg.* 99 (1969) 572–578.
- [21] B. Duarte, K.K. Nagy, J. Cintron, Perforated duodenal diverticulum, *Br. J. Surg.* 79 (1992) 877–881.
- [22] C.F. Chen, D.C. Wu, C.W. Chen, J.S. Hsieh, C.Y. Chen, J.Y. Wang, Successful management of perforated duodenal diverticulitis with intra-abdominal drainage and feeding jejunostomy: a case report and literature review, *Kaohsiung J. Med. Sci.* 24 (August (8)) (2008) 425–429.
- [23] G. Miller, C. Mueller, D. Yim, et al., Perforated duodenal diverticulitis: a report of three cases, *Dig. Surg.* 22 (3) (2005) 198–202.
- [24] B. Schnueriger, S.A. Vorburger, V.M. Banz, A.M. Choeper, D. Candinas, Diagnosis and management of the symptomatic duodenal diverticulum: a case series and a short review of the literature, *J. Gastrointest. Surg.* 12 (2008) 1571–1576.
- [25] Sanghyun song management of perforated duodenal diverticulum: report of two cases, *Korean J. Gastroenterol.* 66 (2015) 159–163.
- [26] D. Haboubi, A. Thapar, C. Bhan, A. Oshowo, Perforated duodenal diverticulae: importance for the surgeon and gastroenterologist, *BMJ Case Rep.* (2014), <http://dx.doi.org/10.1136/bcr-2014-205859>.
- [27] J. Favre-Rizzo, E. López-Tomasetti-Fernández, J. Ceballos-Esparragón, J.R. Hernández-Hernández, Duodenal diverticulum perforated by foreign body, *Rev. Esp. Enferm. Dig.* 105 (2013) 368–369.
- [28] I. Barillaro, V. Grassi, A. De Sol, et al., Endoscopic rendez-vous after damage control surgery in treatment of retroperitoneal abscess from perforated duodenal diverticulum: a technical note and literature review, *World J. Emerg. Surg.* 8 (2013) 26.
- [29] Fernando Guardado-Bermúdez, Fernando Josafat Ardisson-Zamora, Juan Daniel Rojas-González, Alberto Medina-Benítez, Fernando Corona-Suárez, Perforated duodenal diverticula. Case report and treatment options, *Cir. Cir.* 81 (2013) 318–321.

Open Access

This article is published Open Access at sciedirect.com. It is distributed under the [IJSCR Supplemental terms and conditions](#), which permits unrestricted non commercial use, distribution, and reproduction in any medium, provided the original authors and source are credited.