

CONTINUING EDUCATION PROGRAM: FOCUS...

## Imaging inflammatory breast cancer

J.-P. Alunni

*Imagerie des Trois-Rivières, clinique du Pont-de-Chaume, 330, avenue Marcel-Unal, 82000 Montauban, France*

### KEYWORDS

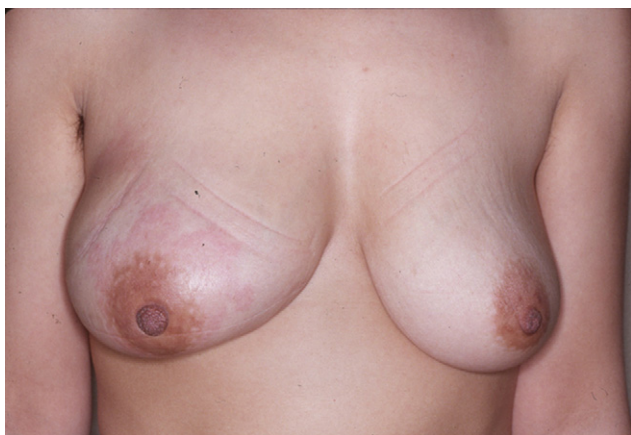Breast;  
Inflammation;  
Cancer;  
Mammography;  
Ultrasonography

**Abstract** Carcinomatous mastitis is a severe form of breast cancer and its diagnosis is essentially clinical and histological. The first examination to perform is still mammography, not only to provide evidence supporting this diagnosis but also to search for a primary intramammary lesion and assess local/regional spread. It is essential to study the contralateral breast for bilaterality. Ultrasound also provides evidence supporting inflammation, but appears to be better for detecting masses and analysing lymph node areas. The role of MRI is debatable, both from a diagnostic point of view and for monitoring during treatment, and should be reserved for selected cases. An optimal, initial radiological assessment will enable the patient to be monitored during neoadjuvant chemotherapy.

© 2011 Éditions françaises de radiologie. Published by Elsevier Masson SAS. All rights reserved.

Inflammatory breast cancer, also known as carcinomatous mastitis, T4d, or PEV 2 or 3, is the only real therapeutic emergency in breast oncology, given the high risk of metastasis, the reason for the most unfavourable prognosis of all breast cancers [1]. It must consequently be diagnosed rapidly, and imaging examinations must in no case delay therapeutic management. Let us remember that the diagnosis of this particular form of breast cancer is essentially clinical (Fig. 1) and histological [2]. Imaging nevertheless has its place in the management of this breast disease, particularly to exclude differential diagnoses, characterise intramammary lesions particularly so as to guide taking biopsies, and for assessing local/regional spread. Moreover imaging plays an important role in searching for remote metastases (a point that will not be covered here), and in evaluating the response to treatment [3,4].

E-mail address: [alunnijp@hotmail.com](mailto:alunnijp@hotmail.com)



**Figure 1.** Clinical appearance of inflammatory breast cancer associating periareolar erythema with skin thickening, an increase in breast volume and nipple retraction.

## Mammography

A mammogram is obviously still the first examination to be performed for a patient with breast inflammation. In a number of cases it will provide essential information about the breast concerned but also and above all about the contralateral breast. Indeed, even if the rate of bilaterality is still being debated, the rate of cancer in the contralateral breast is in the order of 0.9 to 4% [5].

Obtaining a mammogram in a case of acute breast inflammation can be difficult, even impossible, considering the pain caused and the difficulties of compression. In the rare situations where it is technically impossible, a mammogram at least of the contralateral breast must be obtained.

The abnormal mammogram signs in this context have been extensively described in the literature (Fig. 2), the most common being thickening of the skin, found in 84% of cases in Günhan-Bilgen's study [5]. This thickening, often more marked where breast volume is small, would seem to predominate initially in the inferior areolar region, before rapidly extending to the entire skin covering. As with most of the phenomena visible to imaging, it seems to be linked to tumoural obstruction of the lymphatics, causing defective drainage, particularly of the skin [6]. The second most common sign is trabecular thickening, found in 81% of cases and which has the same histological origin as the thickening of the skin. Moreover, there is frequently an overall increase in the density of the breast related to intramammary oedema; this increase in density adversely affects mammogram reading, in particular, searching for subadjacent masses. This overall increase in density is seen in 93.5% of cases in Tardivon's study [7]. On the other hand, contrary to the observations of Dershaw in his study from 1994 [8], according to Günhan-Bilgen's study an intramammary mass is clearly found in just 16% of cases, the lesions usually only being seen as focal asymmetric density (61% of cases). Architectural distortions are rarer and the overall increase in breast density remains isolated in 37% of cases. Microcalcifications are seen in approximately 56% of cases, which clearly distinguishes this condition from locally advanced cancer, much more frequently associated with the lesions of

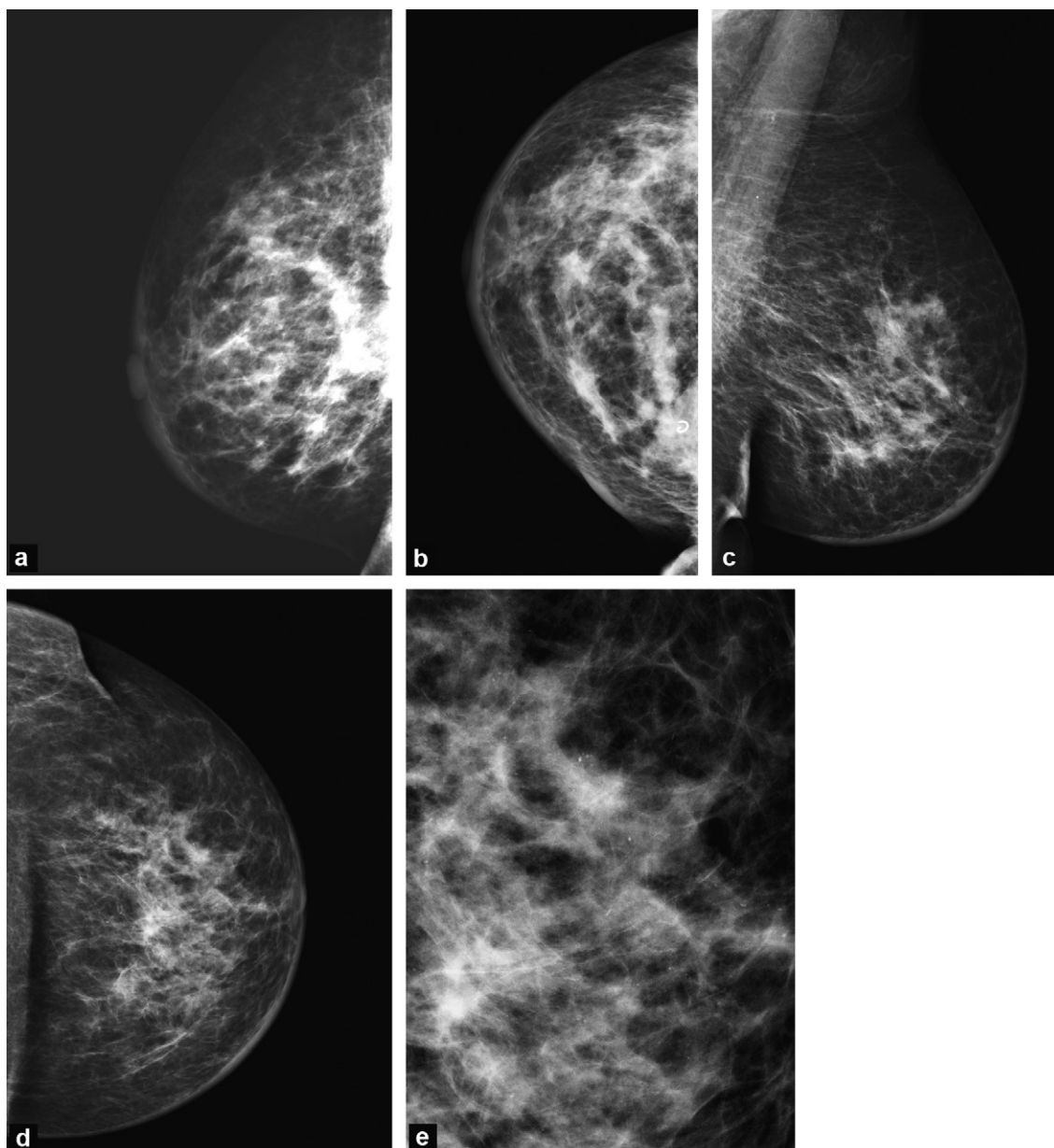
extensive intraductal carcinoma. The literature contains a wide variation as regards the percentage of masses and microcalcifications identified in this inflammatory context, with some old studies not distinguishing between primary inflammatory cancer and the secondary inflammation of advanced cancer, which much more often presents a mass and calcifications. The appearance of the microcalcifications of inflammatory cancer can be very variable, with diffuse distribution of benign microcalcifications in about 10% of cases. Nevertheless, when they are present, they are usually ACR4 or even 5 [9]. Another sign frequently observed is nipple retraction, visible in 43% of cases on the mammogram [5], which totally agrees with the rate of nipple retraction found clinically. Finally, in 24% of cases the mammogram shows axillary adenomegaly.

It should be noted that the arrival of the digital mammogram has probably considerably improved analysis of the different signs, which is partly due to better visualisation of the skin envelope of the breast [4].

However, and according to Yang, mammography is still the least sensitive technique for either looking for an intramammary lesion or for detecting any multifocal or multicentric lesions [10].

## Ultrasonography

While the usefulness of ultrasound in breast oncology often amounts to searching for biopsy targets, several studies have shown that a detailed bilateral ultrasound examination including the lymph node areas can provide additional information (Fig. 3). A high frequency probe study of the skin itself can authenticate skin thickening in 95% of cases, a higher result than the sensitivity of mammography can provide [6]. This can be vital, particularly when the mammogram is considered to be normal or when a mammogram is not possible. While some studies have attempted to determine the normal thickness of the skin [5], in the end it is the thickness of the skin of the contralateral breast, which usually serves as a reference. The second essential ultrasound sign is of an overall increase in the echogenicity of the breast parenchyma, related to the oedema and the thickened Cooper's ligaments. These two signs are found in 96% of cases of inflammatory cancer, according to Günhan-Bilgen. Of course, ultrasound can detect masses and does so in 80% of cases, the lesions being sometimes multifocal and sometimes multicentric. The rates of multifocality and multicentricity found with ultrasound vary widely in the literature, ranging from 8% for Günhan-Bilgen [5] to 62% for Yang et al. [10]. In certain situations, while no real mass is identified, isolated areas of attenuation may be seen, which we must be able to identify and biopsy [5]. Other less decisive signs may be seen, such as dilatation of the vessels and the lymphatics in 68% of cases, or pectoral involvement. Lastly, an essential item of information provided by ultrasound is very good analysis of the lymph node areas, not only the axillary but also the supra and sub-clavicular or parasternal nodes (Fig. 4). According to Yang et al. [10], there seems to be axillary node involvement (an increase in the volume of the nodes, a very hypoechoic appearance, the loss of fatty hilum) seen with ultrasound in 93% of cases, and

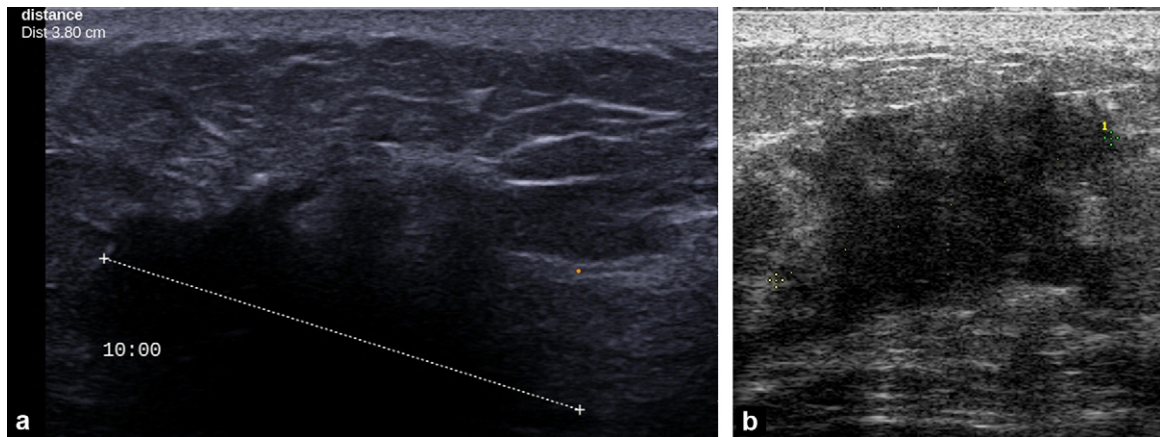


**Figure 2.** Mammographic appearance of inflammatory breast cancer. a and b: MLO (a) and CC (b) incidence showing circumferential skin thickening, trabecular thickening, an overall increase in the density of the breast, and several images of poorly defined masses including a superior medial mass (with coil). Nipple retraction can also be seen; c, d and e: MLO (c), and CC (d) incidence and enlarged CC image (e) of another patient showing predominant periareolar skin thickening, with an overall increase in the density of the breast without a very clear mass. On the magnification view (e) diffuse polymorphic microcalcifications can be seen.

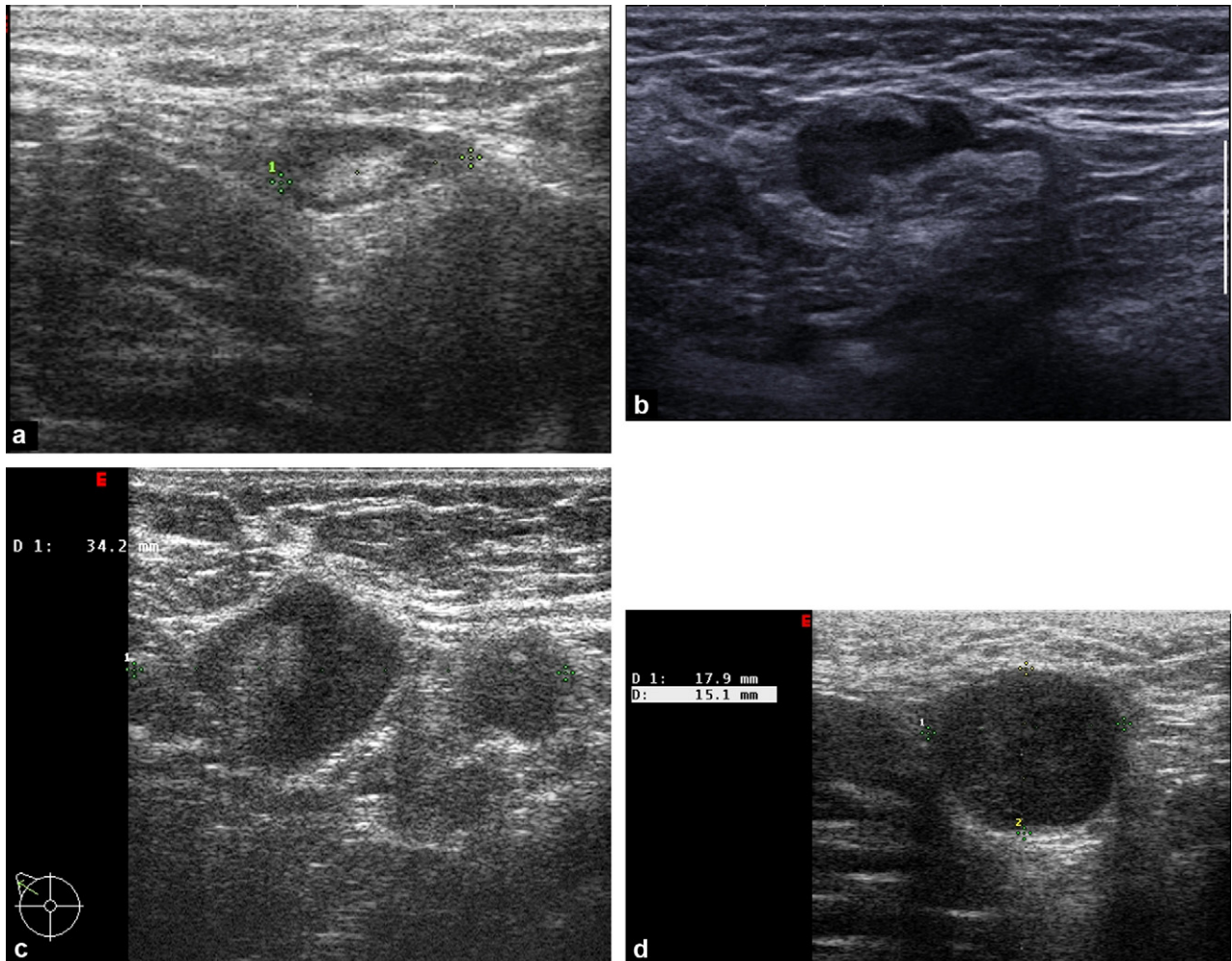
in the other areas mentioned in 50% of cases. Obviously this ultrasound detection is more sensitive than clinical examination, which is said to detect lymph node involvement only in 68% of cases [5]. Pretherapeutic detection of these instances of adenomegaly, in tandem with needle biopsies, can of course provide the clinician with essential information for the initial staging of the breast pathology and for envisaging appropriate treatment, particularly as regards the extent of post-treatment radiotherapy. Finally, detailed pretherapeutic ultrasound analysis will serve as a reference for later per and post-chemotherapy checks.

## MRI

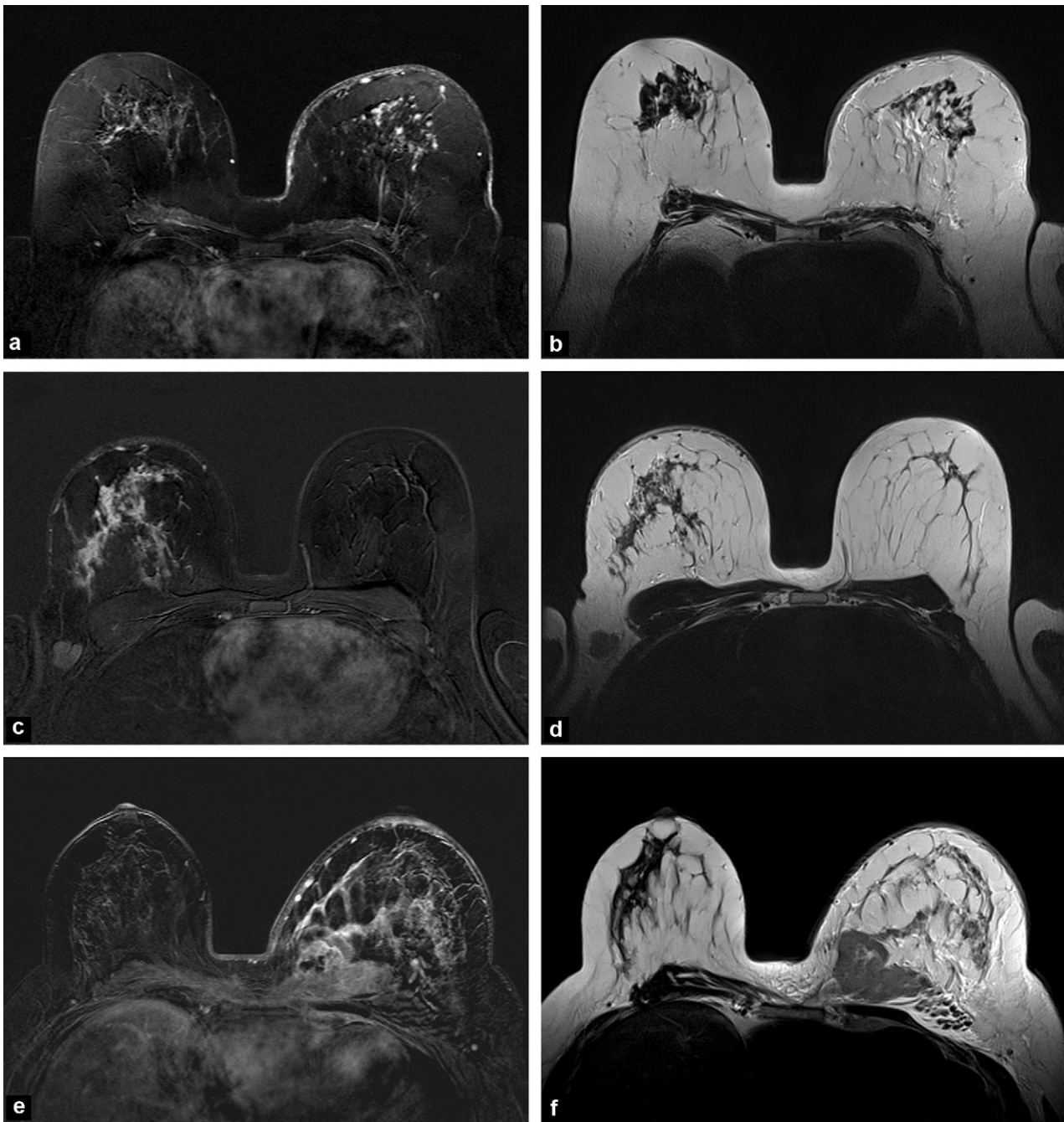
The following chapter, by Cédric de Bazelaire's team, specifically concerns the role of mammary MRI. The signs of inflammatory breast cancer, which are now well known [11,12], show up in perfect detail (Fig. 5). It should be remembered that even if MRI is recognised as being the most sensitive technique for detecting intramammary lesions and looking for multifocality, its role is widely disputed. The usefulness of in-depth detection of possible multifocality is indeed debatable, given the final treatment, which generally



**Figure 3.** Ultrasound appearance of the inflamed breast. a: Marked skin thickening with overall hyperechogenicity of the breast and a voluminous deep spiculated mass; b: Poorly defined attenuated area associated with skin thickening.



**Figure 4.** Axillary ultrasound. a: lymph node with benign appearance retaining a fine cortex and an echogenic hilum; b: suspect lymph node showing irregular eccentric thickening of the cortex while the fatty hilum is conserved; c: very suspect lymph node, of increased thickness, with very thick cortex and virtual disappearance of the fatty hilum; d: Round, totally hypoechoic lymph node with metastatic appearance.



**Figure 5.** MRI appearance of the inflamed breast (a, c, and e: dynamic T1 after injection of gadolinium and subtraction at 3 minutes. b, d and f: T2). a, b: Skin thickening in T2 hypersignal of the left breast, with punctiform enhancement. Diffuse intramammary oedema and non-mass enhancement of the breast with micronodular appearance; c, d: skin thickening of the right breast in T2 hypersignal associated with subcutaneous vessel hypertrophy and heterogeneous, reticular, diffuse non-mass enhancement of the breast. Intra-mammary oedema in T2 and right axillary adenomegaly; e, f: increase in left breast volume and in skin thickness associated with diffuse oedema of the breast. Diffuse non-mass enhancement and deep necrotic mass from the union of the medial quadrants invading the pectoral. Left parasternal lymph nodes probably involved.

consists of a total mastectomy [13]. In this situation, its use can only be logically justified for looking for bilaterality.

### Therapeutic monitoring

In the large majority of current reference documents, the standard treatment for inflammatory breast cancer is

neoadjuvant chemotherapy followed by total mastectomy with axillary lymph node dissection and irradiation [13]. In these conditions, the extent of the residual lesions seen by imaging is after all of little importance in the choice of final surgical treatment, so that assessment at the end of the chemotherapy is less important than in the case, in particular, of a plan for conservative management (apart from in an inflammatory context) [14].

Nevertheless, per- and post-chemotherapy monitoring is of course undertaken, if only to assess the response to the treatment, and possibly change the therapy if there is insufficient response or progression. In this context, a complete breast ultrasound examination is generally performed at the end of chemotherapy with an intermediate assessment, often using ultrasound, made halfway through the treatment. Clinical monitoring is naturally essential in the case of an inflammatory carcinoma: the slightest clinical doubt concerning the response during treatment should lead to earlier radiological evaluation.

As far as MRI is concerned, although its usefulness in monitoring during neoadjuvant chemotherapy has been widely confirmed, its indication should be considered case by case, since certain indications have been retained for imaging, for example in the context of prospective studies evaluating new therapeutic agents. On the other hand, some studies predict the possibility of early evaluation of the therapeutic response by MRI using innovative techniques (diffusion, perfusion, spectroscopy, etc.). Additional large-scale studies will nevertheless be needed before these techniques are routinely used.

## Differential diagnosis

There are a great number of differential diagnoses for inflammatory cancer: at the forefront is acute infectious mastitis, which is discussed in detail in the previous chapter. While in a certain number of cases the clinical picture and history are enough to differentiate these diseases from inflammatory breast cancer, this differential diagnosis often poses major problems. Kamal et al. [15] attempted to determine the infectious, non-infectious or carcinomatous nature of 197 cases of breast inflammation from mammograms and ultrasound scans. Certain ultrasound signs clearly indicate an infectious pathology (the presence of poorly circumscribed collections, or an abscess), while others rather support malignancy (extensive skin thickening and adenomegaly), which seems to agree with the ultrasound signs described above. The mammogram, on the other hand, seems to be less discriminating, the presence of retro-areolar duct ectasia indicating more a benign nature, whereas diffuse skin thickening and an increase in breast density seem to be more indicative of an inflammatory cancer. According to the study by Renz et al., the MRI morphological criteria as defined in the BI-RADS lexicon are quite insufficient for distinguishing between the two conditions. Certain dynamic criteria could provide diagnostic assistance, even if there is considerable overlap, particularly between the types of enhancement curves [16].

Post-traumatic, surgical and radiation treatment are often the cause of a real inflammatory picture, even if the context very often gives a pointer to the diagnosis. Nevertheless, considering the seriousness of inflammatory breast cancer, and while a short waiting period can be tolerated, doubt should often lead rapidly to a complete radiological assessment, looking for the signs described above. These radiological examinations must be interpreted with caution, since visualising, for example, mammogram images evoking cytosteatonecrosis obviously does not exclude adjacent evolving recurrence in an inflammatory form. In these

conditions, it should be widespread practice to take samples for histology.

An often-difficult differential diagnosis is that of locally advanced, often neglected, breast carcinoma manifesting secondarily through inflammation. The absence, in the past, of differentiation between these two very distinct types of breast pathology has probably led to many cases of confusion in older studies. The clinical history and examination generally enables a distinction to be made between these two types of lesion, which are quite different clinico-pathological entities [17]. Nevertheless, when the patient's answers to questions do not seem to be reliable, decisive morphological aspects can be used, such as the presence on the mammogram of voluminous masses and extensive calcifications. Many authors have also looked into the differential characteristics of these two conditions with MRI [18,19], which has identified very different imaging characteristics for these two diseases that have often been confused in the past.

### TAKE-HOME MESSAGES

#### Mammography

- The most frequent signs of inflammatory cancer are skin thickening, trabecular thickening and an overall increase in the density of the breast.
- Masses, distortions and microcalcifications are less common in carcinomatous mastitis than in locally advanced breast cancer.
- Mammography is the least sensitive technique for detecting intramammary masses in an inflammatory context.

#### Ultrasonography

- Inflammatory cancer is seen as thickening of the skin and an increase in echogenicity of the breast parenchyma.
- Ultrasound can detect breast masses and search for multifocality with greater sensitivity than mammography.
- The analysis of lymph node areas is essential, considering the frequency in particular of supra and sub-clavicular involvement.

#### MRI

- The usefulness of MRI is much debated both for pretherapeutic assessment and for monitoring during chemotherapy.
- The differential diagnosis with infectious mastitis may also be difficult.

#### Therapeutic monitoring

- Monitoring during chemotherapy is generally clinical with mammography and ultrasound examinations.

#### Differential diagnosis

- Infectious mastitis is the principle differential diagnosis for inflammatory breast cancer. Differentiating between these two conditions is essentially based on the clinical history and ultrasound. Mammography and MRI may also be useful.

- Post-therapeutic and particularly post-radiation lesions may be the cause of breast inflammation. Caution is nevertheless needed in this context.
- A clear distinction must be made between inflammatory breast cancer and locally advanced cancer, which are two quite distinct clinicopathological entities.

## Clinical case

Mrs I. comes to see you for a breast radiology consultation following the appearance of painful erythema of the right breast. She is a 42-year-old patient whose history includes left mastectomy for extensive DCIS at 35 years of age, and a recent T2N1 of 35 mm of the right sup. lat. quadrant (grade 3 IDC, RH-, Her2-) treated by neoadjuvant chemotherapy (4 FEC 100 +4 Taxotere) then conservative surgery and axillary lymph node dissection. The tissue removed contained 2 cm tumour remains, three largely invaded lymph nodes and two cicatricial lymph nodes (Sataloff TC-NC). Additional

irradiation of the breast and the lymph node areas was performed and finished three months ago. The erythema has appeared recently and is accompanied by an increase in breast volume.

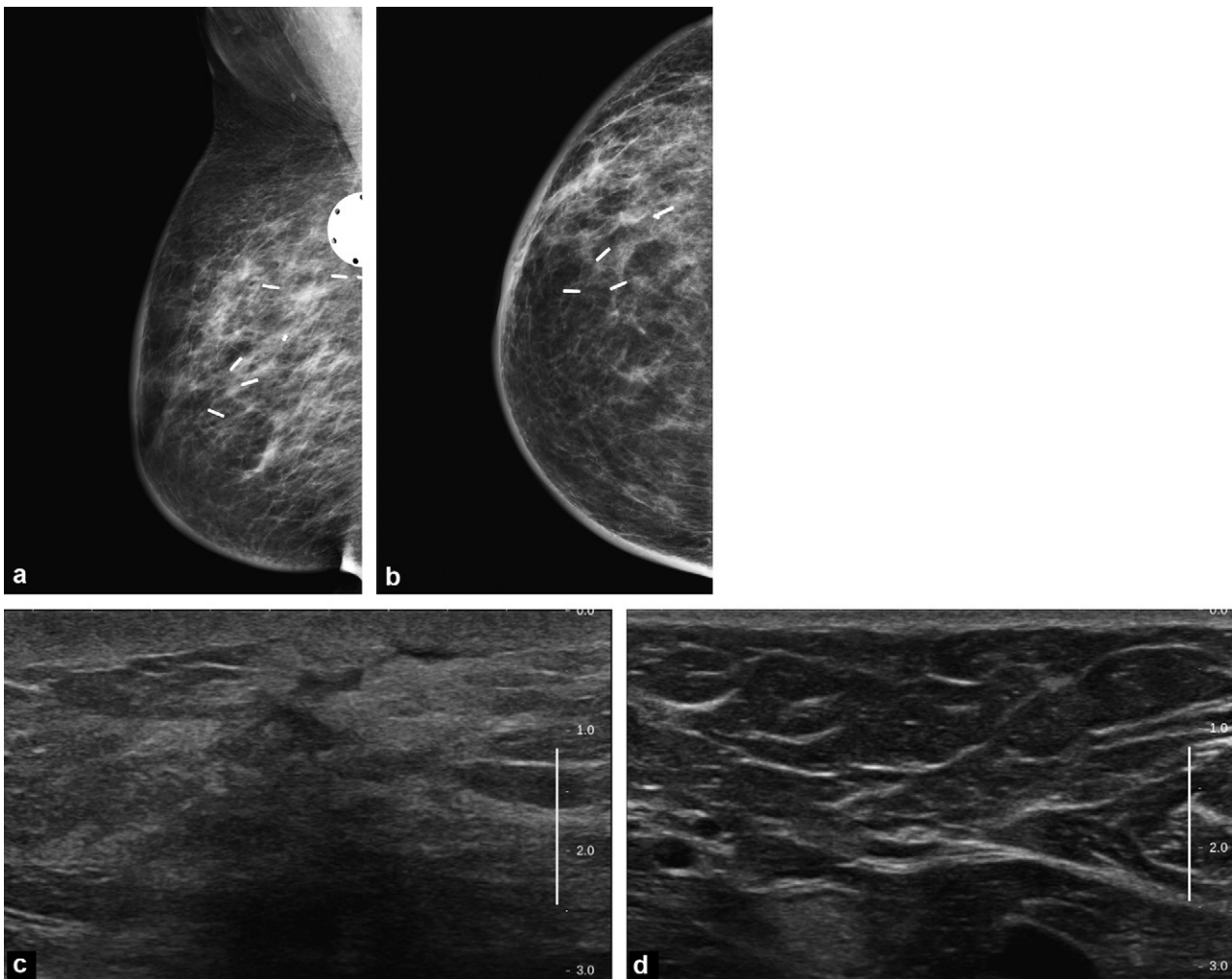
## Question 1

What would you do? (Several answers are possible):

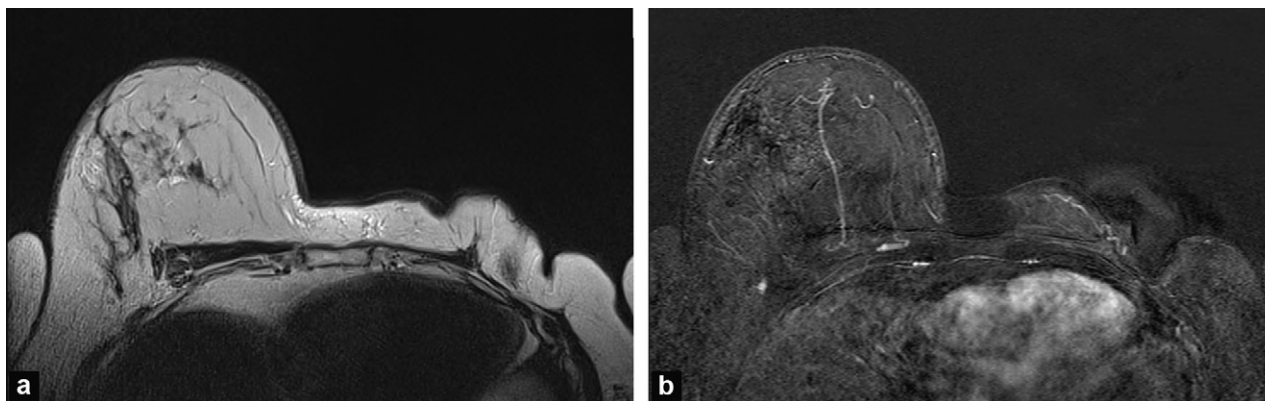
- Clinical examination;
- Mammogram;
- Ultrasound examination;
- MRI;
- Nothing;
- You would offer her an onco-genetic consultation if that has not already been done.

## Answer

a, b and c. Yes. The clinical and breast ultrasound examinations are the first examinations to perform in the event of clinical changes, particularly in a patient who has undergone treatment. Looking for an intramammary collection,



**Figure 6.** Right mammogram with MLO (a) and CC (b) incidence. Breast ultrasound of the surgical zone of the right sup. lat. quadrant (c) and ultrasound of the right axilla (d).



**Figure 7.** Bilateral breast MRI. Axial T2 TSE sequence (a). Dynamic T1 GE sequence with subtraction at 2 minutes (b).

for example, justifies these examinations and the ultrasound should also cover the lymph node areas.

d. No, not as a first course of action, all the more so because the irradiation was recent and could cause post-radiation phenomena upsetting reading of the MRI. In addition, the distinction between local recurrence and post-therapeutic inflammatory phenomena can be difficult.

e. No. The possibility of very early local recurrence, particularly given the aggressiveness of the initial condition and her very partial response to the chemotherapy, justifies performing these examinations immediately.

f. Yes, even if it is not the best of times to choose. Although this patient has already presented a bilateral cancer, her family history should be collected.

### Question 2

The clinical examination indeed reveals inflammatory signs (orange-peel skin, cutaneous erythema, increase in breast volume without a clearly palpable mass), without palpable adenopathy. You are shown the mammograms (Fig. 6a and b) and a breast (Fig. 6c) and axillary (Fig. 6d) ultrasound examination is performed. What do you think? (Several answers are possible):

- It is probably a post-therapeutic phenomenon;
- It is probably recurrence of the cancer in an inflammatory form;
- Biopsies are needed;
- You offer close monitoring;
- You perform MRI.

### Answer

a. Yes. The mammography and ultrasound characteristics (the absence in particular of a mass, and a fine surgical scar and benign looking axillary lymph nodes, respectively) support a post-therapeutic phenomenon, and very early recurrence is rare.

b. No. There are no specific decisive clinical or radiological aspects.

c. No. Given that the likelihood of recurrence is low, it is possible initially to defer multiple biopsies, which could exacerbate the inflammatory phenomena.

d. Yes, monitoring could be proposed in the first instance.

e. No, for the same reasons as in question 1.

### Question 3

After anti-inflammatory treatment and local care arranged jointly with the oncologist, the clinical situation after 1 month is stable. An MRI is performed (Fig. 7). What do you think? (Several answers are possible):

- The diagnosis of post-radiation inflammation is formally confirmed;
- The situation remains doubtful: it would be best to take biopsies;
- The MRI was useful;
- The MRI was not useful.

### Answer

a. No. Post-radiation phenomena are based on a diagnosis of exclusion, and the MRI does not formally exclude evolving recurrence even if the absence of an enhanced intramammary mass is reassuring. There is nevertheless enhanced skin thickening and intramammary oedema, which are not specific to any aetiology.

b. Yes, histological evidence is necessary.

c and d. Yes for both answers! MRI has not fundamentally changed the action to be taken and biopsies must be taken despite the absence in this examination of particularly suspect characteristics. However, it has shown the lack of intramammary uptake of contrast and consequently the skin should be sampled.

The skin biopsies are finally reassuring, supporting non-specific inflammation, without carcinomatous emboli. Clinical monitoring is continued and gradually records improvement in the inflammation. The condition was therefore a simple post-radiation phenomenon.

### Disclosure of interest

The author declares that he has no conflicts of interest concerning this article.

### References

- Li CI. Risk of mortality by histologic type of breast cancer in the United States. *Horm Cancer* 2010;1(3):156–65.



- [2] Anderson WF, Schairer C, Chen BE. Epidemiology of inflammatory breast cancer (IBC). *Breast Dis* 2006;22:9–23 [2005].
- [3] Yang WT. Advances in imaging of inflammatory breast cancer. *Cancer* 2010;116(11 Suppl.):2755–7.
- [4] Chow CK. Imaging in inflammatory breast carcinoma. *Breast Dis* 2006;22:45–54 [2005].
- [5] Günhan-Bilgen I, Ustün EE, Memiş A. Inflammatory breast carcinoma: mammographic, ultrasonographic, clinical, and pathologic findings in 142 cases. *Radiology* 2002;223(3):829–38.
- [6] Le-Petross CH, Bidaut L, Yang WT. Evolving role of imaging modalities in inflammatory breast cancer. *Semin Oncol* 2008;35(1):51–63.
- [7] Tardivon AA, Viala J, Corvellec Rudelli A, Guinebretiere JM, Vanel D. Mammographic patterns of inflammatory breast carcinoma: a retrospective study of 92 cases. *Eur J Radiol* 1997;24(2):124–30.
- [8] Dershaw DD, Moore MP, Liberman L, Deutch BM. Inflammatory breast carcinoma: mammographic findings. *Radiology* 1994;190(3):831–4.
- [9] Kushwaha AC, Whitman GJ, Stelling CB, Cristofanilli M, Buzdar AU. Primary inflammatory carcinoma of the breast: retrospective review of mammographic findings. *AJR Am J Roentgenol* 2000;174(2):535–8.
- [10] Yang WT, Le-Petross HT, Macapinlac H, Carkaci S, Gonzalez-Angulo AM, Dawood S, et al. Inflammatory breast cancer: PET/CT, MRI, mammography, and sonography findings. *Breast Cancer Res Treat* 2008;109(3):417–26.
- [11] Le-Petross HT, Cristofanilli M, Carkaci S, Krishnamurthy S, Jackson EF, Harrell RK, et al. MRI features of inflammatory breast cancer. *AJR Am J Roentgenol* 2011;197(4):W769–76.
- [12] Carbognin G, Calciolari C, Girardi V, Camera L, Pollini G, Pozzi Mucelli R. Inflammatory breast cancer: MR imaging findings. *Radiol Med* 2010;115(1):70–82.
- [13] Robertson FM, Bondy M, Yang W, Yamauchi H, Wiggins S, Kamrudin S, et al. Inflammatory breast cancer: the disease, the biology, the treatment. *CA Cancer J Clin* 2010;60(6):351–75.
- [14] Sardanelli F, Boetes C, Borisch B, Decker T, Federico M, Gilbert FJ, et al. Magnetic resonance imaging of the breast: recommendations from the EUSOMA working group. *Eur J Cancer* 2010;46(8):1296–316.
- [15] Kamal RM, Hamed ST, Salem DS. Classification of inflammatory breast disorders and step by step diagnosis. *Breast J* 2009;15(4):367–80.
- [16] Renz DM, Baltzer PA, Böttcher J, Thaher F, Gajda M, Camara O, et al. Magnetic resonance imaging of inflammatory breast carcinoma and acute mastitis. A comparative study. *Eur Radiol* 2008;18(11):2370–80.
- [17] Anderson WF, Chu KC, Chang S. Inflammatory breast carcinoma and noninflammatory locally advanced breast carcinoma: distinct clinicopathologic entities? *J Clin Oncol* 2003;21(12):2254–9.
- [18] Girardi V, Carbognin G, Camera L, Bonetti F, Manfrin E, Pollini G, et al. Inflammatory breast carcinoma and locally advanced breast carcinoma: characterisation with MR imaging. *Radiol Med* 2011;116(1):71–83.
- [19] Renz DM, Baltzer PA, Böttcher J, Thaher F, Gajda M, Camara O, et al. Inflammatory breast carcinoma in magnetic resonance imaging: a comparison with locally advanced breast cancer. *Acad Radiol* 2008;15(2):209–21.