



Placental pathology is associated with illness severity in preterm infants in the first twenty-four hours after birth[☆]

A.M. Roescher^{a,*}, M.M. Hitzert^a, A. Timmer^b, E.A. Verhagen^a, J.J.H.M. Erwich^c, A.F. Bos^a

^a Division of Neonatology, Beatrix Children's Hospital, University Medical Center Groningen, University of Groningen, Groningen, The Netherlands

^b Department of Pathology and Medical Biology, University Medical Center Groningen, University of Groningen, Groningen, The Netherlands

^c Department of Obstetrics and Gynaecology, University Medical Center Groningen, University of Groningen, Groningen, The Netherlands

ARTICLE INFO

Article history:

Received 22 September 2010

Received in revised form 29 December 2010

Accepted 24 January 2011

Keywords:

Placental pathology

Illness severity

SNAPPE

Preterm infants

ABSTRACT

Background: Placental pathology is associated with long-term neurological morbidity. Little is known about the association of placental pathology and illness severity directly after birth in preterm infants.

Objective: To determine the association between placental pathology and illness severity in preterm infants during the first 24 h after birth.

Study design: Placentas of 40 preterm infants, born after singleton pregnancies (gestational age 25.4–31.7 weeks, birth weight 560–2250 g) were assessed for histopathology. Illness severity was measured using the Score of Neonatal Acute Physiology Perinatal Extension (SNAPPE). A high SNAPPE reflects high illness severity.

Results: Examination of the 40 placentas revealed: pathology consistent with maternal vascular underperfusion (MVU) (n=24), ascending intrauterine infection (AIUI) (n=17), villitis of unknown aetiology (VUE) (n=6), foetal thrombotic vasculopathy (FTV) (n=6), elevated nucleated red blood cells (NRBCs) (n=6), and chronic deciduitis (n=10). SNAPPE ranged from 1 to 53 (median 10). Infants with elevated NRBCs had a higher SNAPPE than infants without elevated NRBCs (median 30 vs. 10, $p=0.014$). The same was found for the presence of FTV (median 30 vs. 10, $p=0.019$). No relation existed between SNAPPE and the other placental pathologies.

Conclusions: Elevated NRBCs and FTV were associated with higher illness severity during the first 24 h after birth in preterm infants. Ascending intrauterine infection was not associated with high illness severity.

© 2011 Elsevier Ireland Ltd. Open access under the [Elsevier OA license](http://creativecommons.org/licenses/by/3.0/).

1. Introduction

In industrialised countries, preterm birth is responsible for 75% of neonatal morbidity and contributes to long-term neurodevelopmental problems [1]. Placental pathology may act as a causative factor in preterm birth. The placenta plays a crucial role during pregnancy, with major implications for the child if its function is impaired. Previous studies in term infants suggested that several placental lesions are associated with long-term neurological morbidity [2,3]. These lesions include ascending intrauterine infection, chronic villitis of unknown aetiology, meconium associated vascular necrosis, foetal thrombotic vasculopathy, and the appearance of elevated nucleated

red blood cells [2,3]. Recently, placental pathology was also reported as being the main cause of foetal death [4]. The most common cause of foetal death in the preterm period is maternal hypoperfusion of the placenta in a pregnancy complicated by hypertensive disorders. In the term period, foetal death is mainly caused by developmental pathology of placenta parenchyma [4].

In the case of preterm infants little is known about the effect of placental pathology on neonatal morbidity. The question arises whether the same lesions that are associated with long-term neurological morbidity in term infants are also associated with early morbidity in preterm infants. If these lesions are associated with early morbidity, the mechanisms leading to neonatal morbidity may become clear. One way of assessing early morbidity is to determine illness severity soon after birth by scoring several clinical variables. A reliable instrument to measure illness severity in the first 24 h after birth is the Score of Neonatal Acute Physiology Perinatal Extension (SNAPPE) [5]. The scores obtained are associated with both mortality and morbidity.

Our objective was to determine whether placental pathology was associated with illness severity during the first 24 h after birth in preterm infants born at <32 weeks of gestational age. We

Abbreviations: AIUI, Ascending intrauterine infection; FTV, Foetal thrombotic vasculopathy; MVU, Maternal vascular underperfusion; NRBC, Nucleated red blood cells; SNAPPE, Score of Neonatal Acute Physiology Perinatal Extension; UMCG, University Medical Center Groningen; VUE, Villitis placentae of unknown aetiology.

[☆] All the authors declare that they have nothing to disclose.

* Corresponding author at: Division of Neonatology, Beatrix Children's Hospital, University Medical Center, University of Groningen, Hanzeplein 1, 9713 GZ Groningen, The Netherlands. Tel.: +31 503614 215; fax: +31 503614 235.

E-mail address: a.m.roescher@student.rug.nl (A.M. Roescher).

hypothesised that in the presence of placental lesions preterm infants will be more severely ill and physiologically unstable during the first 24 h after birth.

2. Materials and methods

2.1. Patient population

We carried out a cohort study of 44 preterm, singleton infants. All infants had been admitted to the NICU of the University Medical Center Groningen. The inclusion criterion was a gestational age of less than 32 weeks. Exclusion criteria were major chromosomal and congenital abnormalities. We also excluded infants whose placentas were not available for pathological examination ($n=4$). Our final study group consisted of 40 preterm singleton infants.

2.2. Placental pathology

The placentas were examined by a perinatal pathologist (AT) in accordance with the guidelines published by the Royal College of Obstetricians and Gynaecologists and the Royal College of Pathologists, and the College of American Pathologists [6,7]. We included and graded all placental lesions for which an association with neurological impairment had been suggested previously [2,3]. These lesions are placental pathology consistent with maternal vascular underperfusion (MVU) [8], ascending intrauterine infection (AIUI) [9], chronic villitis of unknown origin (VUE) [10], chronic deciduitis [11], perivillous fibrinoid [12], foetal thrombotic vasculopathy (FTV) [13], meconium associated vascular necrosis [14], chorioamniotic hemosiderosis [15], increased nucleated red blood cells (NRBCs) [2], chorangiomas [16], and umbilical cord abnormalities [17]. We also recorded placental weight, cord length, and coiling index.

2.3. Score of neonatal acute physiology perinatal extension

To assess the illness severity of the infants during the first 24 h after birth, we determined the Score of Neonatal Acute Physiology Perinatal Extension (SNAPPE) from the medical records and nursing files. SNAPPE consists of 31 clinical and physiological variables, such as blood pressure, pCO_2 , temperature, oxygen saturation, Apgar score, and the presence of apnoea. The most abnormal value of each item during the first 24 h after birth was used in the calculation. SNAPPE may range from 0 to 184, a higher SNAPPE reflects higher illness severity. SNAPPE is associated with both neonatal morbidity and mortality [5,18].

2.4. Statistical analysis

SPSS 16.0 software for Windows (SPSS Inc Chicago, IL) was used for the statistical analyses. To test the associations between placental pathology and SNAPPE, we used the Mann–Whitney U test for categorical placental pathologies and Spearman's rho correlation test for ordinal or continuous variables reflecting placental pathological measures. For further analysis, we used a multivariate regression model to test the independent associations of SNAPPE with the various individual placental pathologies. We used the logarithm of SNAPPE in this model to meet the conditions of multivariate regression. A p -value of $<.05$ was considered statistically significant.

3. Results

3.1. Patient characteristics

The patient characteristics are presented in Table 1. Placental characteristics such as placental weight and umbilical cord length were also included. None of the infants died within the first 24 h after

Table 1

Patient characteristics. Data are given as median (range) or numbers.

Study population	40
Gestational age, weeks	29.9 (25.4–31.7)
Birth weight, grammes	1243 (560–2250)
Male/female	20/20
Intracranial haemorrhage (Grade 1–2)	7
Intracranial haemorrhage (Grade 3–4)	2
Cause of preterm birth	
Preterm due to maternal or foetal reasons (e.g. foetal distress)	16
Spontaneous preterm birth	17
Preterm due to premature rupturing of the membranes (PPROM)	7
Caesarean section	22
Placental weight, grammes	260.5 (99–470)
Cord length, centimetre	28 (15–59)

birth, however 4 infants died between 6 and 19 days after birth. Three infants died of respiratory and circulatory insufficiency due to sepsis and 1 infant died of gastrointestinal perforation.

3.2. Placental pathology

The distribution of placental pathologies is presented in Fig. 1. Only 3 out of the 40 placentas showed no pathology. The largest group of 24 placentas consisted of pathologies consistent with MVU, followed by 17 placentas with signs of AIUI. The occurrence of placental pathologies, categorised by gestational age and birth weight, is presented in Table 2. We found no significant association between placental pathologies and gestational age. A lower birth weight was associated with a higher occurrence of NRBCs and FTV (Mann–Whitney U, $p<.05$).

Twenty-four placentas showed more than one category of placental histopathology. The most common combinations were placental pathology consistent with MVU plus elevated NRBCs ($n=5$) and MVU plus AIUI ($n=5$). We found no meconium associated vascular necrosis or complications of the umbilical cord in our group.

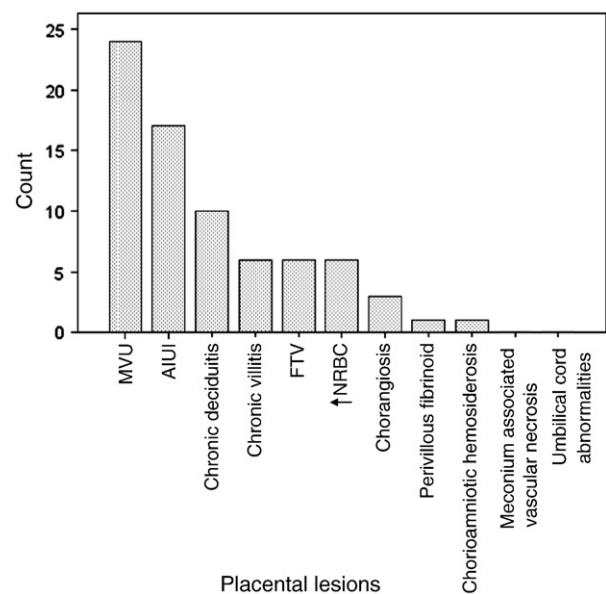


Fig. 1. The distribution of placental lesions in our study group. A single placenta can have more than one lesion. Abbreviations: MVU, maternal vascular underperfusion; AIUI, ascending intrauterine infection; FTV, foetal thrombotic vasculopathy; and NRBCs, nucleated red blood cells.

Table 2
Presence of placental pathology specified by gestational age and birth weight.

Placental lesions	<28 week	≥28 week	<1 kg	≥1 kg
	n=9	n=31	n=8	n=32
MVU (n=24)	4	20	7	17
AIUI (n=17)	6	11	2	15
Chronic deciduitis (n=10)	1	9	2	8
Chronic villitis (n=6)	1	5	2	4
FTV (n=6)	1	5	4	2
↑NRBCs (n=6)	2	4	5	1
Chorangiosis (n=3)	1	2	2	1
Perivillous fibrinoid (n=1)	-	1	1	-
Chorioamniotic hemosiderosis (n=1)	1	-	1	-

The distribution of placental lesions specified by gestational age (<28 weeks and ≥28 weeks) and by birth weight (<1 kg and ≥1 kg). The numbers exceed 100%, because a single placenta can have more than one lesions.

Abbreviations: MVU, maternal vascular underperfusion; AIUI, ascending intrauterine infection; FTV, foetal thrombotic vasculopathy; and NRBCs, nucleated red blood cells.

3.3. Placental pathology and SNAPPE

SNAPPE ranged from 1 to 53 (median 10). The number of placental lesions did not correlate with SNAPPE (Fig. 2). Regarding specific pathologies, SNAPPE was significantly higher in the presence of FTV, elevated NRBCs, and if maternal vascular underperfusion co-existed with elevated NRBCs. In the presence of these three pathological categories, the respective median SNAPPE was 20, 20, and 25 points higher (Mann–Whitney U, $p < .05$) (Fig. 3).

Furthermore, a higher SNAPPE correlated with the coiling index of the umbilical cord (median 0.29, range 0.06–0.57) with Spearman's $\rho = .359$ ($p = .029$).

Regarding placental pathology consistent with MVU in the absence of elevated NRBCs, no association with SNAPPE was found. Infants with this type of pathology ($n = 24$) had a median SNAPPE of 10, while those without ($n = 16$) had a median SNAPPE of 10.5. Placental signs of AIUI did not affect SNAPPE either, not even when we subdivided the infants whose placentas showed AIUI into a maternal and a foetal response. The same held true for chronic, predominantly low-graded villitis, chronic deciduitis, perivillous fibrinoid, chorioamniotic haemosiderosis, cord length, and placental weight.

Because the associations of the various individual placental pathologies with SNAPPE may be interdependent, we used multivariate linear regression, applying the transformed logarithm of SNAPPE. In the multivariate model we entered pathological placental entities, including

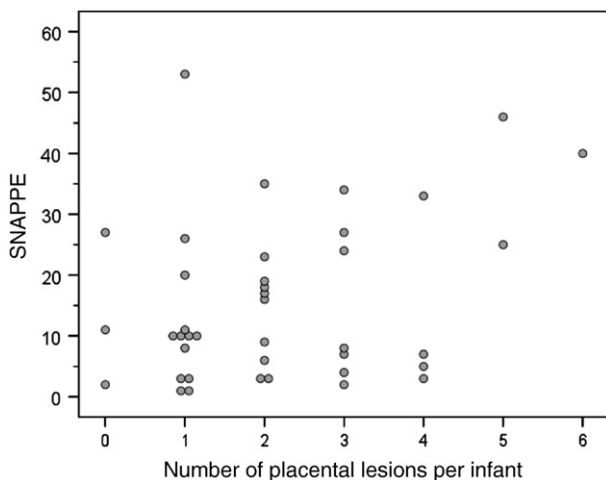


Fig. 2. The number of placental lesions in relation to SNAPPE. Three placentas showed no lesions. The maximum number of lesions in our group was six. There was no significant correlation between number of placental lesions and SNAPPE.

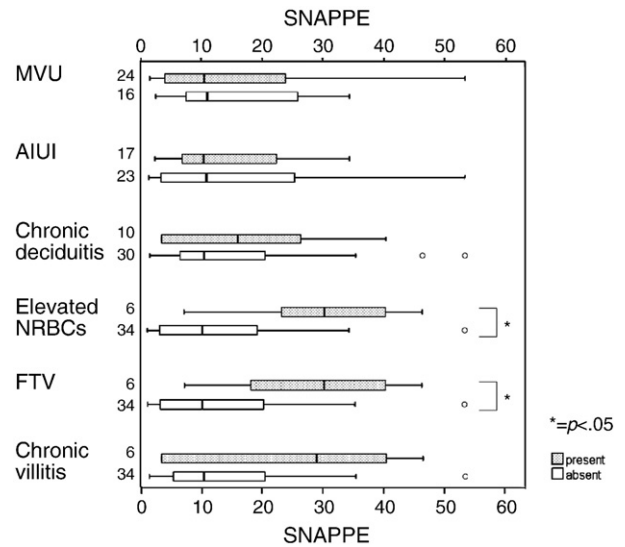


Fig. 3. Single placental pathological entities and distribution of SNAPPE. The data in the graphs are presented as box-and-whisker plots. Boxes represent the individual values between the 25th and 75th centiles (interquartile range, IQR); whiskers represent the range of the values, with the exception of outliers. Outliers are the circles, defined as values between 1.5 IQRs and 3 IQRs from the end of a box. The numbers on the Y-axis signify numbers of infants with the particular placental pathology (grey bars) and without the particular placental pathology (white bars). Abbreviations: FTV, foetal thrombotic vasculopathy; NRBCs, nucleated red blood cells; MVU, maternal vascular underperfusion; and AIUI, ascending intrauterine infection.

combinations, that occurred five times or more in our cohort. These were MVU, AIUI, chronic deciduitis, FTV, elevated NRBCs, VUE, MVU plus elevated NRBCs, and finally MVU plus AIUI. Together they explained 25.0% of the variance of illness severity. Following backward multivariate linear regression, only elevated NRBCs remained in the model explaining 14.9% of the variance of SNAPPE (Table 3).

4. Discussion

This study indicated that several placental lesions were associated with higher illness severity of preterm infants during the first 24 h after birth. These lesions included elevated nucleated red blood cells, foetal thrombotic vasculopathy, placental pathology consistent with maternal vascular underperfusion plus elevated nucleated red blood cells, and a high coiling index of the umbilical cord. Other lesions, such as ascending intrauterine infection, were not related to illness severity during the first 24 h after birth. Our hypothesis was therefore confirmed for some, but not all, lesions.

The strongest association existed with elevated NRBCs in the placenta. Elevated NRBCs are a marker for foetal hypoxia. Elevated NRBCs are different in kind from the other placental lesions. They are all potential causes of foetal physiological disruption, while elevated NRBCs are the result of or indicators for this disruption [2]. Placental lesions, especially chronic and sub acute lesions, may even be antecedents of elevated NRBCs [19]. Redline found that elevated

Table 3
Backward, multivariate linear regression: SNAPPE^a.

	B	95% CI	t	p
Constant	2.130	1.786–2.474	12.540	<0.001
Elevated NRBCs	1.098	0.210–1.987	2.504	0.017

Multivariate analysis using backward linear regression of placental pathology for SNAPPE.

$N = 40$, $r^2 = 0.149$. Abbreviations: NRBCs, nucleated red blood cells; CI, confidence interval; and SNAPPE, score of neonatal acute physiology perinatal extension.

^a Transformation SNAPPE into: $\log(\text{SNAPPE})$.

NRBCs in term infants were significantly more common in the placentas of infants who later developed cerebral palsy [19]. This signifies that foetal distress, whether or not recognised, may lead to a high illness severity of the infant immediately following birth. The placental lesions potentially leading to foetal hypoxia may be several. Placental pathology consistent with MVU could be responsible, since elevated NRBCs frequently co-existed with MVU. This combination could be considered a more severe form of MVU, because of the presence of foetal hypoxia. Following multivariate regression, our data suggested that particularly elevated NRBCs, and not MVU, contribute to higher illness severity. Previous findings are in conflict on this point. A recent study reported that placental pathology consistent with maternal vascular underperfusion was often present, and possibly causative, in intrauterine foetal deaths, especially between 24 and 32 weeks of gestation [4]. Another study, in term infants, reported that maternal vascular underperfusion is *not* associated with neurological impairment [2]. Our findings in live-born preterm infants were consistent with the latter study.

FTV was also associated with higher illness severity. FTV is characterised by devascularised distal villi and is often accompanied by identifiable organising thrombi in upstream feeding vessels in the chorionic plate or large stem villi [20]. In term infants FTV is highly associated with neurologic impairment and cerebral palsy [3]. Another recent study reported that FTV was also associated with a higher incidence of obstetric and perinatal complications and an increase in foetal cardiac abnormalities [21]. This is in line with our findings in preterm infants that illness severity is higher during the first 24 h after birth in the presence of FTV. In the present study, however, the association with SNAPPE was not as strong as the elevated NRBCs. After performing multivariate regression, FTV was no longer an independent factor related to illness severity.

The present study indicated that the coiling index of the umbilical cord was also associated with illness severity. It has been suggested that both a low and a high coiling index are related with adverse perinatal outcome [22,23]. A normal coiling index is between 0.1 and 0.3 [22]. The median in our group was 0.29. This means that almost half of the umbilical cords of our infants had a high coiling index. In our study the higher coiling index was indeed associated with higher illness severity. Previously, a high coiling index was associated with asphyxia and intrauterine growth restriction [23]. Both items are part of the SNAPPE score. Furthermore, it has been demonstrated that a high coiling index is associated with foetal thrombosis [24]. This may lead to a higher illness severity, which we found in our study. However, in our study the foetal thrombotic vasculopathy was not associated with the coiling index.

To our surprise, placental signs of AIUI were not associated with higher illness severity during the first 24 h after birth. A previous study found that AIUIs are associated with neurological impairment in later life [2], possibly due to elevated cytokines and cardiovascular instability. Exposure of the foetal lung to chorioamnionitis may, however, induce lung maturation leading to a lower illness severity immediately after birth [25]. We think this might be the reason why we could not find an association of ascending intrauterine infection with illness severity.

We did not evaluate illness severity with some placental lesions because they rarely occurred in our study group; these included high grade foetal chorionic vasculitis, diffuse villous oedema and recent non-occlusive chorionic vessel thrombi in association with chorioamnionitis. Previously, these lesions have been associated with adverse neurological outcomes [26].

The present study demonstrated that placental pathology frequently accompanies birth before 32 weeks of gestation. Only three placentas did not show any placental pathology, while the others showed a wide range of various pathologies, alone or in combination. This may reflect that conditions associated with preterm birth are frequently caused by a diversity of pathological placental lesions. This

does not necessarily imply that these pathological lesions all lead to higher illness severity. The number of placental lesions was not associated with illness severity.

We recognise several limitations of our study. Firstly, we only included singletons so as to be certain the right placenta was linked to the right infant. It might be that placental pathology in twins is different, e.g. in the case of twin-to-twin transfusion. Secondly, our study had a low sample size. Thirdly, we did not check complete neonatal blood counts for presence of NRBCs. Previously it was reported that the diagnosis of elevated NRBCs by placental examination alone is significantly associated with elevated NRBCs in complete neonatal blood count [19]. Finally, we limited our outcome to neonatal illness severity during the first 24 h following preterm birth. It might well be that an adverse clinical course due to placental pathology only becomes apparent later on.

Our findings may have implications for clinical practise. Placental pathology is very common following preterm birth. An understanding of those pathological lesions that are most frequently associated with illness severity may reveal the relevant pathophysiological mechanisms that lead to neonatal morbidity. Our findings suggested that prenatal hypoxia and activation of foetal coagulation might act as mediators in causing higher illness severity in preterm infants. An increase of haematocrit, because of the hypoxia, may consequently also give rise to a higher chance of thrombosis. Strategies should be aimed at detecting these conditions before birth and finding preventive measures to improve the outcomes of these infants.

In conclusion, this study indicated that placental pathologies including elevated nucleated red blood cells and foetal thrombotic vasculopathy were associated with higher illness severity during the first 24 h after birth in preterm infants. Ascending intrauterine infection was not associated with a high illness severity.

Acknowledgements

This study was part of the research program of the postgraduate school for Behavioral and Cognitive Neurosciences, (BCN), University of Groningen. Annemiek Roescher, Marrit Hitzert and Elise Verhagen were financially supported by a Junior Scientific Master Class of the University of Groningen. We greatly acknowledge the help of Drs. Hans Burgerhof for his statistical advice and of Dr. Titia Brantsma-van Wulfften Palthe in Utrecht for correcting the English manuscript.

References

- [1] Romeo DMM, Guzzetta A, Scoto M, Cioni M, Patusid P, Mazonne D, et al. Early neurologic assessment in preterm-infants: integration of traditional neurologic examination and observation of general movements. *Eur J Paediatr Neurol* 2008;12:183–9.
- [2] Redline RW, O'Riordan MA. Placental lesions associated with cerebral palsy and neurologic impairment following term birth. *Arch Pathol Lab Med* 2000;124:1785–91.
- [3] Redline RW. Severe fetal placental vascular lesions in term infants with neurologic impairment. *J Obstetr Gynecol* 2005;192:452–7.
- [4] Korteweg FJ, Erwich JJHM, Holm JP, Ravisé JM, van der Meer J, Veeger NJGM, et al. Diverse placental pathologies as the main causes of fetal death. *Obstetr Gynecol* 2009;114:809–17.
- [5] Richardson DK, Phibbs CS, Gray JE, McCormick MC, Workman-Daniels K, Goldmann DA. Birth weight and illness severity: independent predictors of neonatal mortality. *Pediatrics* 1993;91:969–75.
- [6] Royal College of Obstetricians and Gynaecologists. Fetal and perinatal pathology. Report of a joint working party. London, UK: RCOG-press; 2001.
- [7] Langston C, Kaplan C, Macpherson T, Mancini E, Peevy K, Clark B, et al. Practice guideline for examination of the placenta: developed by the Placental Pathology Practice Guideline Development Task Force of the College of American Pathologists. *Arch Pathol Lab Med* 1997;121:449–76.
- [8] Redline RW, Boyd T, Campbell V, Hyde S, Kaplan C, Khong TY, et al. The Society for Pediatric Pathology, Perinatal Section, Maternal Vascular Underperfusion Nosology Committee. Maternal vascular underperfusion: nosology and reproducibility of placental reaction patterns. *Pediatr Dev Pathol* 2004;7:237–49.
- [9] Redline RW, Faye-Petersen O, Heller D, Qureshi F, Savell V, Vogler C. The Society for Pediatric Pathology, Perinatal Section, Amniotic Fluid Infection Nosology Committee. Amniotic infection syndrome: nosology and reproducibility of placental reaction patterns. *Pediatr Dev Pathol* 2003;6:435–48.

- [10] Redline RW. Villitis of unknown etiology: noninfectious chronic villitis in the placenta. *Hum Pathol* 2007;38:1439–46.
- [11] Yee Khong T, Bendon RW, Qureshi F, Redline RW, Gould S, Stallmach T, Lipsett J, Staples A. Chronic deciduitis in the placental basal plate: definition and interobserver reliability. *Hum Pathol* 2000;31:292–5.
- [12] Katzman PJ, Genest DR. Maternal floor infarction and massive perivillous fibrin deposition: histological definitions, association with intrauterine fetal growth restriction, and risk of recurrence. *Pediatr Dev Pathol* 2002;159–64.
- [13] Redline RW, Ariel I, Baergen RN, Desa DJ, Kraus FT, Roberts DJ, Sander M. The Society for Pediatric Pathology, Perinatal Section, Fetal Vascular Obstruction Nosology Committee. Fetal vascular obstructive lesions: nosology and reproducibility of placental reaction patterns. *Pediatr Dev Pathol* 2004;7:443–52.
- [14] Altshuler G, Arizawa M, Molnar-Nadasdy G. Meconium-induced umbilical cord vascular necrosis and ulceration: a potential link between the placenta and poor pregnancy outcome. *Obstet Gynecol* 1992;79:760–6.
- [15] Ohyama M, Itani Y, Yamanaka M, Goto A, Kato K, Ijiri R, et al. Maternal, neonatal, and placental features associated with diffuse chorioamniotic hemosiderosis, with special reference to neonatal morbidity and mortality. *Pediatrics* 2004;113:800–5.
- [16] Ogino S, Redline RW. Villous capillary lesions of the placenta: distinctions between chorangioma, chorangiomatosis, and chorangiosis. *Hum Pathol* 2000;8:945–54.
- [17] Baergen RN. Cord abnormalities, structural lesions, and cord "accidents". *Semin Diagn Pathol* 2007;24:23–32.
- [18] Richardson DK, Gray JE, McCormick MC, Workman K, Goldmann DA. Score for neonatal acute physiology: a physiologic severity index for neonatal intensive care. *Pediatrics* 1993;91:617–23.
- [19] Redline RW. Elevated circulating fetal nucleated red blood cells and placental pathology in term infants who develop cerebral palsy. *Hum Pathol* 2008;39:1378–84.
- [20] Redline RW, Pappin A. Fetal thrombotic vasculopathy: the clinical significance of extensive avascular villi. *Hum Pathol* 1995;26:80–5.
- [21] Saleemuddin A, Tantbirojn P, Sirois K, Crum CP, Boyd TK, Tworoger S, Parast M. Obstetric and perinatal complications in placentas with fetal thrombotic vasculopathy. *Pediatr Dev Pathol*. 2010 May [Epub ahead of print]
- [22] Kashanian M, Akbarian A, Kouhpayehzadeh J. The umbilical coiling index and adverse perinatal outcome. *Int J Gynecol Obstetr* 2006;95:8–13.
- [23] de Laat MWM, Franx A, Bots ML, Visser GHA, Nikkels PGJ. Umbilical coiling index in normal and complicated pregnancies. *Obstet Gynecol* 2006;107(5):1049–55.
- [24] de Laat MWM, van Alderen ED, Franx A, Visser GHA, Bots ML, Nikkels PGJ. The umbilical coiling index in complicated pregnancy. *Eur J Obstet Gynecol Reprod Biol* 2007;103(1):66–72.
- [25] Kramer BW, Kallapur S, Newnham J, Jobe AH. Prenatal inflammation and lung development. *Semin Fetal Neonatal Med* 2009;14:2–7.
- [26] Redline RW, Minich N, Taylor HG, Hack M. Placental lesions as predictors of cerebral palsy and abnormal neurocognitive function at school age in extremely low birth weight infants (<1 kg). *Pediatr Dev Pathol* 2007;10(4):282–92.