

ORIGINAL ARTICLE

# Surgical ampullectomy: an underestimated operation in the era of endoscopy

Lutz Schneider, Pietro Contin, Stefan Fritz, Oliver Strobel, Markus W. Büchler & Thilo Hackert

Department for General, Visceral and Transplantation Surgery, University of Heidelberg, Germany

## Abstract

**Introduction:** Benign neoplastic, inflammatory or functional pathologies of the ampulla of Vater are mainly treated by primary endoscopic interventions. Consequently, transduodenal surgical ampullectomy (TSA) has been abandoned in many centres, although it represents an important tool not only after unsuccessful endoscopic treatment. The aim of the study was to analyse TSA for benign lesions of the ampulla of Vater.

**Patients and methods:** All patients who underwent TSA between 2001 and 2014 were included. Patients were analysed in terms of indications, postoperative morbidity and mortality as well as long-term success.

**Results:** Eighty-three patients underwent TSA. Indications included adenomas in 44 and inflammatory stenosis in 39 patients. 96% of the patients had undergone endoscopic therapeutic approaches prior to TSA (median no. of interventions  $n = 3$ ). Postoperative morbidity occurred in 20 patients (24%). There was one procedure-associated death (mortality 1.2%). The mean follow-up was 54 months. Long-term overall success rate for TSA was 83.6%. After TSA for ampullary adenoma, the recurrence rate was 4.5%.

**Conclusion:** TSA is an underestimated surgical procedure, which can be performed safely with high long-term efficacy. It can be implemented in clinical algorithms for patients with benign pathologies of the ampulla of Vater, particularly after unsuccessful endoscopic treatment.

Received 28 April 2015; accepted 10 July 2015

## Correspondence

Markus Büchler, Department of General, Visceral and Transplantation Surgery, University of Heidelberg, Im Neuenheimer Feld 110, 69120 Heidelberg, Germany. Tel.: +49 6221 566110. Fax: +49 6221 56 5450. E-mail: [Markus.Buechler@med.uni-heidelberg.de](mailto:Markus.Buechler@med.uni-heidelberg.de)

## Introduction

Transduodenal surgical ampullectomy (TSA) is a limited surgical approach for pathologies of the duodenal major and minor papilla. The method was first described by Halsted in 1899.<sup>1</sup> In many centres, this surgical treatment approach is not included in the clinical routine and has almost been forgotten, because endoscopic intervention has replaced surgical treatment. Potential indications for TSA are ampullary adenomas, inflammatory or fibrotic stenosis, dysfunction of the major or minor papilla resulting in upper abdominal pain, recurrent acute pancreatitis and cholestasis.

The study protocol and all documents used were approved by the local ethical review board of the University of Heidelberg (S-604/2013).

Endoscopic ampullectomy is globally recognised as a first-choice procedure for benign ampullary pathologies.<sup>2</sup> If endoscopic resection is not successful or recurrence of the ampullary pathology occurs, a surgical approach has to be considered. The potential advantages of endoscopic ampullectomy are low morbidity and mortality rates compared with pancreatoduodenectomy, which is considered as a surgical treatment option by many clinicians after endoscopic therapy has failed.<sup>3</sup> However, there are no trials comparing TSA as a limited surgical approach with endoscopic ampullectomy in terms of outcome, recurrence rates, and the need for reinterventions, which are required in a considerable percentage of patients.<sup>2,3</sup> In the current literature, only a few studies on TSA are available, most of them with small numbers of patients, and they focus on the early postoperative outcome.<sup>4–8</sup> Consequently, there are no recommendations with

regard to the duration of endoscopic treatment of ampullary pathologies or the number of interventions that should not be exceeded before surgery is considered.

The aim of the present study was to analyse TSA as a surgical approach for benign ampullary lesions in a large single-centre series with a focus on indications, postoperative morbidity and mortality, as well as long-term outcome.

## Patients and methods

All patients who underwent TSA for at the Department of Surgery at the University Hospital of Heidelberg, Germany between October 2001 and August 2014 were identified from a prospectively maintained database. The study protocol was designed in compliance with the guideline established by the International Conference on Harmonisation (ICH) on the topic of good clinical practice (GCP), with primary focus on efficacy, safety and ethical guidelines. Accordingly, the study protocol and all documents used were approved by the local ethical review board of the University of Heidelberg (S-604/2013).

## Surgical technique

After laparotomy and exploration of the abdominal cavity and the liver, the duodenum and pancreatic head were mobilised from the retroperitoneum by a Kocher manoeuvre. After palpation of the pancreatic head to exclude an underlying pancreatic head tumour and a longitudinal duodenotomy, the ampulla of Vater was identified. Local excision of the ampulla was performed by sharp dissection and electro-cautery with careful identification of the pancreatic and bile ducts (Fig. 1).

Both ducts were marked with stay sutures before completion of the excision. An intraoperative frozen section was performed to exclude a malignant lesion and to ensure complete excision. To prepare reconstruction, a common ostium of the pancreatic and bile ducts was created by single 5-0 stitches. Afterwards, duct reinsertion by circular single sutures (duct-to-mucosa) and two-layer closure of the duodenal wall completed reconstruction. If the gallbladder was present at the time of operation it was removed to avoid potential cholangitis-associated complications. In the case of resection of the minor papilla, reinsertion of the Santorini duct was performed similarly.

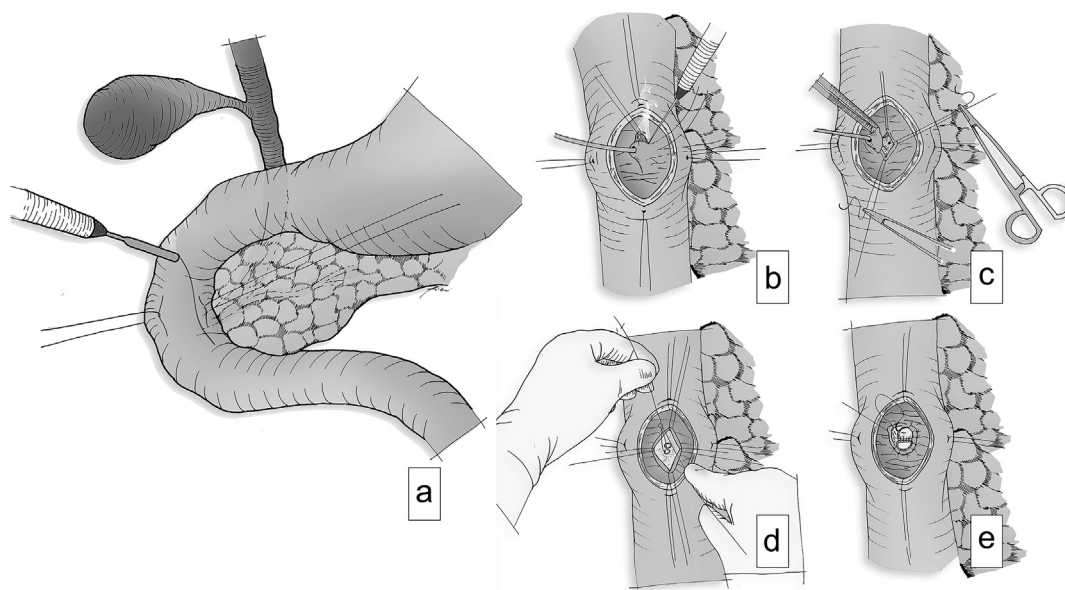
Patients' demographic characteristics, pre- or postoperative endoscopic interventions, operative procedures, postoperative morbidity and mortality, hospitalisation and follow-up time were analysed. Morbidity evaluation included postoperative pancreatic fistula (POPF), delayed gastric emptying (DGE) and postoperative haemorrhage (PPH) according to the definitions of the International Study Group for Pancreatic Surgery (ISGPS).<sup>9–11</sup>

Patients were followed up in the outpatient clinic and by telephone visits. After formal informed consent, all patients were interviewed for clinical condition, symptoms and recurrent disease as well as further endoscopic or surgical interventions.

## Results

### Patients

83 patients underwent TSA during the study period. Fifty-one were female and 32 were male with a median age of 63 years (IQR 49–69 years). Leading clinical presentation was recurrent



**Figure 1 Surgical procedure.** a) Linear duodenotomy after stay sutures in the duodenal wall. b) Identification of the ampulla of Vater, placing of stay sutures and dissection of the ampulla. c) Placing multiple mucosal stay sutures during the dissection of the ampulla. d) Suturing a common ostium between the bile and pancreatic ducts. e) Reinsertion of the common duct into the duodenal mucosa

pancreatitis in 47 patients (56.6%), unspecific upper abdominal pain in 28 patients (33.7%), and jaundice in 8 patients (9.6%) (Table 1).

### Preoperative interventions, indications and surgical procedures

Preoperatively, 73 patients had endoscopic therapeutic interventions (median  $n = 3$ , IQR 1–8). Three patients did not undergo endoscopic therapy and for seven, no data on preoperative interventions were available (Table 1). Indications for surgery were endoscopically non-resectable ampullary neoplasia ( $n = 44$ ; 53%) and inflammatory stenosis ( $n = 39$ ; 47%) (Table 1). Ampullectomy of the papilla of Vater was performed in 72 patients (87%) whereas resection of the minor papilla was carried out in 11 (13%) (Table 2).

### Histopathological findings

Postoperative histopathology revealed a benign ampullary adenoma in 42 patients (50.6%). Of those, 37 (88%) had low-grade and 5 (12%) high-grade dysplasia. Chronic inflammatory papillitis was present in 38 patients (45.8%). Three patients showed adenocarcinoma in the final histology (3.6%) (Table 2). In two of these patients, TSA was intended despite the suspicion

of malignancy because of severe co-morbidities, making pancreatoduodenectomy unfeasible. In the third patient, an in situ carcinoma was found in the definite histology report after primary intraoperative unsuspecting frozen section. Because of the in situ stage, after discussion of the finding with the patient, close follow-up examinations were performed instead of an oncological resection, without evidence of tumour recurrence to date (follow-up 102 months).

### Perioperative outcome

One patient died on postoperative day 230. In this patient, after initial TSA an emergency pancreatoduodenectomy for necrosis of the pancreatic head was performed. He died in the further follow up from multi-organ failure, resulting in an overall mortality rate of 1.2% ( $n = 1$ ).

Postoperative complications occurred in 20 patients revealing a morbidity rate of 24% (Table 2). There was a need for reoperation in five patients (6%). Two patients required emergency total pancreatectomy, one patient because of PPH grade C, the other because of duodenal leakage, both caused by fulminant necrotising pancreatitis. In one patient, an operative revision at postoperative day nine was necessary because of colonic perforation after percutaneous abscess drainage. Another patient underwent a biliodigestive anastomosis on postoperative day six for necrosis of the bile duct. Postoperative complications graded in accordance to the classification of Dindo *et al.* (Table 2).<sup>12</sup>

### Follow-up

The median follow-up was 54 months (IQR 21–101). Complete follow-up was available in 73 patients (88%). 61 patients had no recurrent adenoma/pancreatitis revealing a success rate of 83.6% for TSA. The success rates of patients with symptomatic pancreas divisum were lower (67%) than in patients with TSA of the ampulla of Vater (Table 3). In the adenoma group, one local recurrence was observed 49 months after initial TSA. The patient is under endoscopic surveillance. During the follow up, three pancreatoduodenectomies were performed (4.1%). One pancreatoduodenectomy was performed for multiple duodenal adenomas in an FAP patient four years after initial TSA but no local recurrence in the area of the initial ampullectomy. Two of them for recurrent symptoms after TSA of the minor papilla, five months and four years after the initial TSA, respectively. Both patients are well at the follow-up. Three additional patients are currently not satisfied with the long-term result after TSA.

Consequently, including the five redo operations in the primary hospital stay, the overall success rate was 83.6% for TSA in the present cohort (Table 3).

### Discussion

In the present study, we report a single-centre experience of transduodenal surgical ampullectomy (TSA). The procedure was applied to patients with ampullary stenosis or neoplasia,

**Table 1** Baseline data of patients. All: all included patients; PD: symptomatic pancreas divisum; inflamm.: patients with inflammatory or structural alteration of the sphincter Oddi; adenoma: patients with ampullary adenoma. Clinical presentation was recurrent pancreatitis, unspecific upper abdominal pain, and jaundice. Pre-operative diagnoses leading to resection were ampullary adenoma and inflammatory stenosis of the ampulla. ERCP means median preoperative endoscopic therapeutic interventions. IQR: interquartile range

Patients	All	PD	Inflamm.	Adenoma
n (%)	83	10 (12%)	29 (34.9%)	44 (53%)
Age median (IQR)	63 (49–69)	47 (41–55)	61 (41–69)	67 (57–70)
Sex				
F	51	7	16	28
M	32	3	13	16
Clinical presentation				
Pancreatitis	47	10	24	13
Unspecific pain	28		2	26
Jaundice	8		3	5
Indications				
Adenoma	44		4	40
Inflammatory stenosis	39	10	25	4
ERCP (median; IQR)				
Prior to surgery	3 (1–8)	8 (8–8)	3.5 (1.25–7.75)	2 (1–2.25)

**Table 2 Operative results.** All: all included patients; PD: symptomatic pancreas divisum; inflamm.: patients with inflammatory or structural alteration of the sphincter oddi; adenoma: patients with ampullary adenoma; DGE: delayed gastric emptying; POPF: postoperative pancreatic fistula; PPH: postoperative pancreatic haemorrhage in accordance with ISGPF and ISGPS guidelines.<sup>9–11</sup> Operative revision means re-done operations at the primary hospital stay for surgical complications. Clavien-Dindo Classification means severity of post-operative complications.<sup>12</sup> IQR: interquartile range

Patients	All	PD	Inflamm.	Adenoma
<b>Ampullary resection</b>				
Major papilla	72	0	29	43
Minor papilla	11	10	0	1
<b>Histology</b>				
Adenoma	42	1		41
Inflammatory stenosis	38	9	29	
Carcinoma	3			3
<b>Hospitalization median (IQR)</b>	10 (9–14)	12 (10–16)	9 (8–13)	10 (9–14)
<b>Morbidity &amp; mortality (n = 25)</b>				
DGE Grade A	1		1	
DGE Grade C	1	1		
POPF Grade B	2		2	
POPF Grade C	1			1
PPH Grade C	1			1
CT-Drain	7		4	3
Abscess	2			2
Wound infection	3			3
Duodenal leakage	1			1
Necrotizing pancreatitis	1			1
Cholangitis	2			2
Pneumonia	2		1	1
Pneumothorax	1			1
<b>Operative revision</b>	5 (6%)			
Pancreatic head resection	1			1
Total pancreatectomy	2			2
Biliodigestive anastomosis	1			1
Colonic perf. after CT-Drain	1		1	
<b>Mortality</b>				
30 days	0			
Overall	1 (1.2%)			1 (2.2%)
<b>Clavien–Dindo classification</b>				
I	1		1	
II	13	1	3	9
IIIa	8		4	4
IIIb				
IVa				
IVb	3			3
V	1		1	

respectively. To our knowledge, this study represents the largest cohort reported in the literature so far. The results demonstrate that TSA is a feasible method with low morbidity and mortality rates as well as high long-term efficacy, and should be incorporated in clinical routine algorithms for suitable patients.

Pathologies of the minor and major pancreatic sphincter can be functional, inflammatory and neoplastic. Clinical symptoms are often unspecific, varying between unspecific abdominal discomfort and acute pancreatitis or obstructive jaundice. The clinical symptoms do not allow a general conclusion about the

**Table 3 Long-term success with regard to primary diagnosis.**

All: all included patients; PD: symptomatic pancreas divisum; inflamm.: patients with inflammatory or structural alteration of the sphincter oddi or dysfunction; adenoma: patients with ampullary adenoma. Response rate means patients who could be contacted for long-term follow-up interview. Success rate means symptom/disease relief after transduodenal surgical ampullectomy

Patients	All	PD	Inflamm.	Adenoma
Response rate (%)	73 (88%)	9 (90%)	27 (93%)	37 (84%)
Success rate	61 (83.6%)	6 (67%)	24 (88.9%)	31 (83.7%)
Non success (%)	12 (16.4%)	3 (33%)	3 (11.1%)	6 (16.3%)

underlying pathology. Diagnosis is mostly made by endoscopy including biopsy, endoscopic ultrasound and endoscopic retrograde cholangio-pancreatography. Cross-sectional imaging by MRI including MRCP can supplement the work-up. In the case of proven malignancy, oncological pancreatic head resection including systematic lymphadenectomy is the treatment of choice.<sup>13</sup>

In contrast, for all benign pathologies, the surgical option of TSA can be evaluated although a primary endoscopic treatment is the most commonly applied approach today because of increasing experience in interventional endoscopy.<sup>2</sup> This is suitable for all benign pathologies including pancreatic sphincter dysfunction, symptomatic pancreas divisum without signs of chronic pancreatitis and small benign neoplastic lesions.<sup>14,15</sup> However, endoscopic approaches are limited in case of recurrence of inflammatory disease with sclerosis of the pancreatic sphincter or when a neoplastic lesion exceeds the size that allows safe endoscopic removal.<sup>15</sup> In these situations, TSA is a feasible approach avoiding pancreatic head resection.

There are only a few reports about TSA with small numbers of patients in the literature to date. The present study examined the short- and long-term surgical outcome of TSA in 83 patients including a subcohort with TSA for inflammatory pathology of the minor papilla in symptomatic pancreas divisum. Of those patients, all had undergone endoscopic therapy including papillotomy and stent insertion. This underlines that the endoscopic approach is generally considered as the first-line treatment but is also burdened by a certain rate of therapeutic failure.<sup>14,15</sup>

In a retrospective analysis, Ceppa and colleagues compared endoscopic versus surgical resection of the ampulla of Vater with regard to therapeutic success, morbidity and mortality. They concluded that endoscopic treatment was a safer option with morbidity rates of 18% vs. 42% after surgical ampullectomy.<sup>6</sup> In a retrospective analysis, Dixon *et al.* report about a morbidity rate of 37% after surgical ampullectomy.<sup>8</sup> Other non-comparative publications reported morbidity rates between 8 and 27% after endoscopic ampullectomy.<sup>3,6,16–20</sup> In the present study, postoperative morbidity was 24% which is comparable with the reported endoscopic morbidity rates. 56% of the postoperative

complications in the present study were Clavien–Dindo grade I or II.<sup>12</sup> The majority of the grade III and IV postoperative complications could be treated interventionally. Indications for reoperation in five patients were colon perforation, bile duct necrosis, PPH grade C, duodenal perforation or fulminant acute pancreatitis. All of these complications are observed after endoscopic therapy as well and may similarly lead to endoscopic or even surgical interventions.<sup>21</sup> We observed a procedure-related mortality of 1.2%, which is in line with other surgical series that reported rates between 0 and 3% for TSA.<sup>6,22</sup> Mortality after endoscopic ampullectomy ranges between 0 and 2%.<sup>23</sup> Since the gross ranges of reported morbidity in the literature are equally comparable between endoscopy and surgery, no conclusion can be drawn with regard to the superiority of either procedure. But it has to be mentioned, that the severity of either complication is only restrictive comparable without a comparative randomized trial.

Regarding the primary therapeutic success rate, TSA showed excellent results with 83.6% long-term success and a very low recurrence rate of 4.5% in patients undergoing this operation for adenomas in the present study. Other series including more than 40 patients report recurrence rates after surgical ampullectomy of 0%–9% and endoscopic ampullectomy of 17%–20%, respectively<sup>6,24–27</sup> which suggests that TSA is the more effective procedure. Furthermore, if endoscopic resection of an ampullary adenoma requires more than one session, the recurrence risk increases up-to 13-fold.<sup>7</sup>

In the subgroup of patients with pancreas divisum, a primary success rate of 67% was achieved by TSA which is comparable to reported endoscopic success rates.<sup>28–36</sup> The selection of patients seems to play an important role in this setting.<sup>28,29,32,34</sup> Especially when the stenosis of the minor papilla has already led to chronic pancreatitis, an ampulla-directed approach may fail due to the consecutive severe tissue alterations in the pancreatic head. In contrast to endoscopy, this situation can be realised during surgery and the concept of ampullectomy can be changed to a suitable surgical drainage or resection procedure when necessary.<sup>15</sup> Notably, all patients in the present study who suffered from symptomatic pancreas divisum had recurrent symptoms after a median number of eight endoscopic approaches before being referred to surgery. The majority of these patients were free of symptoms after TSA and did not undergo any further intervention. This underlines that TSA is an effective procedure after unsuccessful endoscopic therapeutic attempts.

With regard to functional pathologies of the ampulla, a recent systematic review by Hall and colleagues demonstrates symptom relief for morphologic sphincter Oddi dysfunction (Milwaukee Type I) after endoscopic therapy varying from 83% to 100%.<sup>14</sup> We achieved a complete symptom relief in 89% of our patients with dysfunction of the sphincter Oddi without concomitant pancreas divisum suggesting an equal efficacy of TSA. These patients had undergone a median of 3.5 endoscopic therapies prior to TSA. Consequently, surgical TSA should be attempted

early, when symptom recurrence after primary endoscopic therapy appears.

The descriptive design of the present study is a limitation as it only allows comparison of the current results with the existing literature. A randomised trial comparing endoscopic versus surgical approaches and stratifying patients for inflammatory and neoplastic ampullary lesions could provide more valid data. However, the design and performance of an RCT seems to be unlikely due to the small numbers of patients undergoing these procedures. Therefore, we believe that the present study can contribute substantially to the available evidence despite its limitations.

In conclusion, TSA is a feasible and effective surgical procedure in the treatment of benign ampullary pathologies. Although, endoscopic treatment represents an important tool – especially in the initial therapy of these findings – it is mandatory to evaluate surgical resection if there is primary therapy failure or recurrent disease. Clinical pathways should incorporate TSA as a standard treatment option for suitable patients as it can be carried out safely and with good long-term outcome.

#### Conflicts of interest

None to declare.

#### References

- Halsted, W. S. (1899). Contributions to the surgery of the bile passages, especially of the common bile duct. *Boston Med Surg J*, *141*, 645–654.
- De Palma, G. D. (2014 Feb 14). Endoscopic papillectomy: indications, techniques, and results. *World J Gastroenterol*, *20*, 1537–1543. PubMed PMID: 24587629. Pubmed Central PMCID: 3925862.
- Patel, R., Varadarajulu, S., & Wilcox, C. M. (2012 Jan). Endoscopic ampullectomy: techniques and outcomes. *J Clin Gastroenterology*, *46*, 8–15. PubMed PMID: 22064552.
- Mathur, A., Paul, H., Ross, S., Lubrice, K., Hernandez, J., Vice, M., et al. (2014 Feb). Transduodenal ampullectomy for ampullary adenomas: a safe and effective procedure with long-term salutary outcomes. *Am Surg*, *80*, 185–190. PubMed PMID: 24480221.
- Kim, J., Choi, S. H., Choi, D. W., Heo, J. S., & Jang, K. T. (2011 Oct). Role of transduodenal ampullectomy for tumors of the ampulla of Vater. *J Korean Surg Soc*, *81*, 250–256. PubMed PMID: 22111080. Pubmed Central PMCID: 3219850.
- Ceppa, E. P., Burbidge, R. A., Rialon, K. L., Omotosho, P. A., Emick, D., Jowell, P. S., et al. (2013 Feb). Endoscopic versus surgical ampullectomy: an algorithm to treat disease of the ampulla of Vater. *Ann Surg*, *257*, 315–322. PubMed PMID: 23059497.
- Onkendi, E. O., Naik, N. D., Rosedahl, J. K., Harmsen, S. W., Gostout, C. J., Baron, T. H., Sr., et al. (2014 Sep). Adenomas of the ampulla of Vater: a comparison of outcomes of operative and endoscopic resections. *J Gastrointest Surg*, *18*, 1588–1596. PubMed PMID: 24916584.
- Dixon, E., Vollmer, C. M., Jr., Sahajpal, A., Cattral, M. S., Grant, D. R., Taylor, B. R., et al. (2005 May). Transduodenal resection of peri-ampullary lesions. *World J Surg*, *29*, 649–652. PubMed PMID: 15827855.
- Wente, M. N., Veit, J. A., Bassi, C., Dervenis, C., Fingerhut, A., Gouma, D. J., et al. (2007 Jul). Postpancreatectomy hemorrhage (PPH): an international study group of pancreatic surgery (ISGPS) definition. *Surgery*, *142*, 20–25. PubMed PMID: 17629996.
- Bassi, C., Dervenis, C., Butturini, G., Fingerhut, A., Yeo, C., Izbicki, J., et al. (2005 Jul). Postoperative pancreatic fistula: an international study group (ISGPF) definition. *Surgery*, *138*, 8–13. PubMed PMID: 16003309.
- Wente, M. N., Bassi, C., Dervenis, C., Fingerhut, A., Gouma, D. J., Izbicki, J. R., et al. (2007 Nov). Delayed gastric emptying (DGE) after pancreatic surgery: a suggested definition by the International Study Group of Pancreatic Surgery (ISGPS). *Surgery*, *142*, 761–768. PubMed PMID: 17981197.
- Dindo, D., Demartines, N., & Clavien, P. A. (2004 Aug). Classification of surgical complications: a new proposal with evaluation in a cohort of 6336 patients and results of a survey. *Ann Surg*, *240*, 205–213. PubMed PMID: 15273542. Pubmed Central PMCID: 1360123.
- Berberat, P. O., Kunzli, B. M., Gulbinas, A., Ramanauskas, T., Kleeff, J., Muller, M. W., et al. (2009 Feb). An audit of outcomes of a series of periampullary carcinomas. *Eur J Surg Oncol*, *35*, 187–191. PubMed PMID: 18343082.
- Hall, T. C., Dennison, A. R., & Garcea, G. (2012 Aug). The diagnosis and management of Sphincter of Oddi dysfunction: a systematic review. *Langenbecks Arch Surg*, *397*, 889–898. PubMed PMID: 22688754.
- Schneider, L., Muller, E., Hinz, U., Grenacher, L., Buchler, M. W., & Werner, J. (2011 Jun). Pancreas divisum: a differentiated surgical approach in symptomatic patients. *World J Surg*, *35*, 1360–1366. PubMed PMID: 21472371.
- Binmoeller, K. F., Boaventura, S., Ramsperger, K., & Soehendra, N. (1993 Mar-Apr). Endoscopic snare excision of benign adenomas of the papilla of Vater. *Gastrointest Endosc*, *39*, 127–131. PubMed PMID: 8495831.
- Ponchon, T., Berger, F., Chavaillon, A., Bory, R., & Lambert, R. (1989 Jul 1). Contribution of endoscopy to diagnosis and treatment of tumors of the ampulla of Vater. *Cancer*, *64*, 161–167. PubMed PMID: 2471581.
- Zadorova, Z., Dvofak, M., & Hajer, J. (2001 Apr). Endoscopic therapy of benign tumors of the papilla of Vater. *Endoscopy*, *33*, 345–347. PubMed PMID: 11315897.
- Norton, I. D., Gostout, C. J., Baron, T. H., Geller, A., Petersen, B. T., & Wiersema, M. J. (2002 Aug). Safety and outcome of endoscopic snare excision of the major duodenal papilla. *Gastrointest Endosc*, *56*, 239–243. PubMed PMID: 12145603.
- Desllets, D. J., Dy, R. M., Ku, P. M., Hanson, B. L., Elton, E., Mattia, A., et al. (2001 Aug). Endoscopic management of tumors of the major duodenal papilla: refined techniques to improve outcome and avoid complications. *Gastrointest Endosc*, *54*, 202–208. PubMed PMID: 11474391.
- Irani, S., Arai, A., Ayub, K., Biehl, T., Brandabur, J. J., Dorer, R., et al. (2009 Nov). Papillectomy for ampullary neoplasm: results of a single referral center over a 10-year period. *Gastrointest Endosc*, *70*, 923–932. PubMed PMID: 19608181.
- Grobmyer, S. R., Stasik, C. N., Draganov, P., Hemming, A. W., Dixon, L. R., Vogel, S. B., et al. (2008 Mar). Contemporary results with ampullectomy for 29 “benign” neoplasms of the ampulla. *J Am Coll Surg*, *206*, 466–471. PubMed PMID: 18308217.
- Moon, J. H., Choi, H. J., & Lee, Y. N. (2014 Nov). Current status of endoscopic papillectomy for ampullary tumors. *Gut Liver*, *8*, 598–604. PubMed PMID: 25368746. Pubmed Central PMCID: 4215444.
- Beger, H. G., Treitschke, F., Gansauge, F., Harada, N., Hiki, N., & Mattfeldt, T. (1999 May). Tumor of the ampulla of Vater: experience with

- local or radical resection in 171 consecutively treated patients. *Arch Surg*, 134, 526–532. PubMed PMID: 10323425.
- 25.** Catalano, M. F., Linder, J. D., Chak, A., Sivak, M. V., Jr., Rajiman, I., Geenen, J. E., et al. (2004 Feb). Endoscopic management of adenoma of the major duodenal papilla. *Gastrointest Endosc*, 59, 225–232. PubMed PMID: 14745396.
- 26.** Bohnacker, S., Seitz, U., Nguyen, D., Thonke, F., Seewald, S., deWeerth, A., et al. (2005 Oct). Endoscopic resection of benign tumors of the duodenal papilla without and with intraductal growth. *Gastrointest Endosc*, 62, 551–560. PubMed PMID: 16185970.
- 27.** Jeanniard-Malet, O., Caillol, F., Pesenti, C., Bories, E., Monges, G., & Giovannini, M. (2011 Jul). Short-term results of 42 endoscopic ampullectomies: a single-center experience. *Scand J Gastroenterology*, 46, 1014–1019. PubMed PMID: 21492053.
- 28.** Borak, G. D., Romagnuolo, J., Alsolaiman, M., Holt, E. W., & Cotton, P. B. (2009 Nov). Long-term clinical outcomes after endoscopic minor papilla therapy in symptomatic patients with pancreas divisum. *Pancreas*, 38, 903–906. PubMed PMID: 19672208. Epub 2009/08/13. eng.
- 29.** Ertan, A. (2000 Jul). Long-term results after endoscopic pancreatic stent placement without pancreatic papillotomy in acute recurrent pancreatitis due to pancreas divisum. *Gastrointest Endosc*, 52, 9–14. PubMed PMID: 10882955. Epub 2000/07/07. eng.
- 30.** Fogel, E. L., Toth, T. G., Lehman, G. A., DiMagno, M. J., & DiMagno, E. P. (2007 Jan). Does endoscopic therapy favorably affect the outcome of patients who have recurrent acute pancreatitis and pancreas divisum? *Pancreas*, 34, 21–45. PubMed PMID: 17198181. Epub 2007/01/02. eng.
- 31.** Kamisawa, T. (2004 Jul). Clinical significance of the minor duodenal papilla and accessory pancreatic duct. *J Gastroenterol*, 39, 605–615. PubMed PMID: 15293129. Epub 2004/08/05. eng.
- 32.** Lans, J. I., Geenen, J. E., Johanson, J. F., & Hogan, W. J. (1992 Jul-Aug). Endoscopic therapy in patients with pancreas divisum and acute pancreatitis: a prospective, randomized, controlled clinical trial. *Gastrointest Endosc*, 38, 430–434. PubMed PMID: 1511816. Epub 1992/07/01. eng.
- 33.** Lehman, G. A., & Sherman, S. (1995 Jan). Pancreas divisum. Diagnosis, clinical significance, and management alternatives. *Gastrointest Endosc Clin N Am*, 5, 145–170. PubMed PMID: 7728342. Epub 1995/01/01. eng.
- 34.** Vitale, G. C., Vitale, M., Vitale, D. S., Binford, J. C., & Hill, B. (2007 Dec). Long-term follow-up of endoscopic stenting in patients with chronic pancreatitis secondary to pancreas divisum. *Surg Endosc*, 21, 2199–2202. PubMed PMID: 17514389. Epub 2007/05/22. eng.
- 35.** Warshaw, A. L. (1988). Pancreas divisum: a case for surgical treatment. *Adv Surg*, 21, 93–109. PubMed PMID: 3484379. Epub 1988/01/01. eng.
- 36.** Warshaw, A. L., Simeone, J. F., Schapiro, R. H., & Flavin-Warshaw, B. (1990 Jan). Evaluation and treatment of the dominant dorsal duct syndrome (pancreas divisum redefined). *Am J Surg*, 159, 59–64. discussion -6. PubMed PMID: 2403764. Epub 1990/01/01. eng.