JACC Vol 7, No 4
April 1986 800–6

Instantaneous Pressure Gradient: A Simultaneous Doppler and Dual Catheter Correlative Study

PHILIP J. CURRIE, MBBS, FRACP, DONALD J. HAGLER, MD, FACC,
JAMES B. SEWARD, MD, FACC, GUY S. REEDER, MD, FACC, DEREK A. FYFE, MD, PHD,
ALFRED A. BOVE, MD, PHD, FACC, A. JAMIL TAJIK, MD, FACC

Rochester, Minnesota

To more precisely measure the beat to beat and instantaneous pressure gradients across outflow stenotic lesions, simultaneous Doppler and dual catheter pressure gradient measurements were performed in 95 patients (mean age 42 years, range 1.5 to 85). There were 38 right ventricular and 62 left ventricular outflow obstructive lesions. Forty-nine patients also had a nonsimultaneous Doppler study performed within 7 days before catheterization. The simultaneous pressure waveforms and Doppler spectral velocity profiles were digitized at 10 ms intervals deriving maximal, mean and instantaneous gradients (mm Hg).

For simultaneous maximal Doppler and catheter gradient measurements, the correlation coefficient (r) was 0.95 (SEE = 10 mm Hg), for Doppler and catheter mean gradients it was 0.94 (SEE = 8 mm Hg) and for maximal Doppler and peak to peak catheter gradients it was 0.92 (SEE = 13 mm Hg). The correlation of maximal and mean Doppler gradients with the respective catheter gradients was similarly high when the right and left ventricular outflow lesions were analyzed separately. However, the maximal Doppler gradient was significantly higher than the peak to peak catheter gradient. This was more evident with left ventricular outflow stenotic lesions. The correlation of the outpatient maximal Doppler and catheter gradients (r = 0.80, SEE = 17 mm Hg) was significantly lower than the simultaneous correlation (r = 0.96, SEE = 10 mm Hg) in the 49 patients with two Doppler studies.

Continuous wave Doppler echocardiography accurately measures the instantaneous pressure gradient across both left and right ventricular outflow obstructive lesions. The maximal Doppler gradient should not be equated with the peak to peak catheter gradient. As Doppler echocardiography measures instantaneous pressure gradients, it should not be directly compared with nonsimultaneous events.

(J Am Coll Cardiol 1986;7:800–6)

The development of continuous wave Doppler echocardiography has enabled pressure gradients to be estimated noninvasively (1–11). The purpose of this study was to assess the accuracy and validity of continuous wave Doppler estimation of pressure gradients across a wide variety of right and left ventricular outflow stenotic lesions, with simultaneous Doppler and dual catheter pressure measurements. The clinical utility of the noninvasive Doppler examination, instantaneous pressure relations and unique features of right and left ventricular outflow lesions were studied in detail. A dual catheter technique was used to more precisely measure beat to beat and instantaneous pressure gradients.

Methods

Study patients. The study patients included 95 consecutive patients with right or left ventricular outflow obstructive lesions who had simultaneous Doppler and dual catheter pressure measurements during clinically indicated cardiac catheterization. There were 50 male and 45 female patients with a mean age of 42 years (range 1.5 to 85). There were 100 stenotic cardiac lesions studied, of which 38 were right ventricular outflow obstruction (17 pulmonary artery band, 12 pulmonary valvular, 5 infundibular, 3 conduit obstruction and 1 supravalvular pulmonary stenosis) and 62 were left ventricular outflow obstruction (52 valvular aortic stenosis, 4 discrete subvalvular stenosis, 4 bulboventricular foramen obstruction and 2 hypertrophic obstructive cardiomyopathy).

From the Division of Cardiovascular Diseases and Internal Medicine and the Section of Pediatric Cardiology, Mayo Clinic, Rochester, Minnesota. Dr. Currie was supported by an Overseas Clinical Fellowship of the National Heart Foundation of Australia, Canberra, Australia.

Manuscript received September 17, 1985; revised manuscript received November 19, 1985, accepted November 22, 1985.

Address for reprints: Philip J. Currie, MD, Department of Cardiology, Cleveland Clinic Foundation, 9500 Euclid Avenue, Cleveland, Ohio 44106.

0735-1097/86/$3.50

Continuous wave Doppler technique. The continuous wave Doppler examination was performed with an IREX 3B system (IREX Systems) using a 2.0 MHz nonimaging transducer (Pedof, Vingmed A/S). A 2.5 MHz two-dimensional imaging/Doppler transducer was occasionally used for orientation only. Recordings were routinely performed from multiple transducer positions including suprasternal, parasternal (right and left), apical and subcostal positions. Doppler examination was considered optimal only after systematic examination from multiple transducer positions defined the signal of highest audible frequency, maximal velocity and most clearly defined spectral envelope. Optimal signals were assumed to be in a near parallel orientation to the direction of maximal blood flow across the stenosis. No angle correction was employed. The Doppler gradient across the stenosis was calculated using the modified Bernoulli equation (12): GRAD = $4v^2$, where GRAD = instantaneous pressure gradient in millimeters of mercury and v^2 = square of the instantaneous velocity in meters per second.

In addition to the simultaneous Doppler and catheter examinations, 49 patients also had a nonsimultaneous Doppler study within 7 days (average 3 days) before catheterization. This was performed as part of a comprehensive outpatient two-dimensional echocardiographic examination.

Cardiac catheterization. Before catheterization, premedication was given according to the age and clinical condition of the patient (13). Fluid-filled catheters (5F to 8F) connected to strain gauge pressure transducers (Gould P23Id) were used for pressure measurement. The frequency response of the catheter recording systems was linear to 15 Hz. In all patients, the catheter pressure gradient across the stenotic lesion was measured using a dual catheter technique. For measurements in right ventricular outflow obstructive lesions, one catheter was placed in the ventricle and the other was placed across the stenosis in the pulmonary artery. For measurements in left ventricular outflow obstructive lesions, 32 patients had transseptal catheterization and in the remaining 30 patients, one catheter was retrogradely positioned across the aortic valve and the other was placed in the ascending aorta. The catheters were matched for size and length when possible. Pressures were recorded onto the calibrated IREX 7 inch (17.8 cm) strip chart recorder, using a direct current coupler, simultaneously with the Doppler spectral signals and the electrocardiogram (Fig. 1A and 2A) (10,11,13).

Pressure gradient analysis. Simultaneous Doppler spectral envelope and dual catheter pressure waveforms were digitized at 10 ms intervals with instantaneous Doppler and catheter pressure gradients calculated at each interval (Fig. 1), using a specially designed computer program, a digitizer tablet and a PDP-11/34 computer (DEC). Mean Doppler gradients were derived by application of the modified Bernoulli equation at 10 ms intervals to calculate the instantaneous Doppler gradients during systole. The maximal

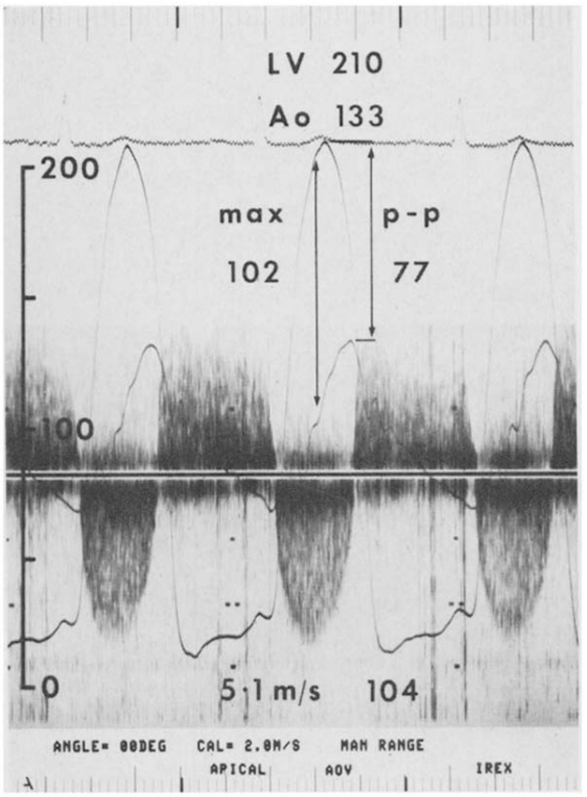

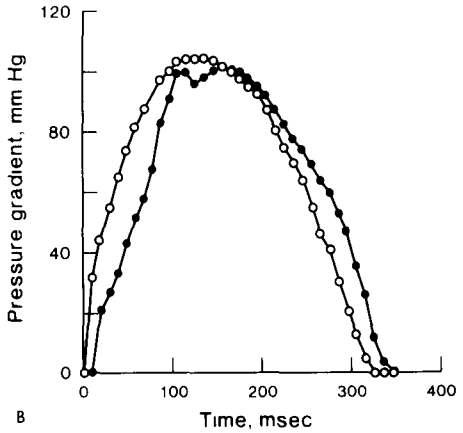

Figure 1. A, Simultaneous Doppler and dual catheter pressure recordings in a patient with severe valvular aortic stenosis. The maximal catheter gradient (max) of 102 mm Hg corresponded closely to the maximal instantaneous Doppler gradient of 104 mm Hg. The peak to peak catheter pressure gradient (p-p) was 77 mm Hg. Note that the peak left ventricular (LV) pressure and the peak aortic (Ao) pressures are nonsynchronous; therefore, the peak to peak catheter pressure gradient does not represent an instantaneous pressure gradient. **B**, Same patient. Instantaneous Doppler and catheter pressure gradients from the digitized Doppler spectral velocity envelope and simultaneous left ventricular and ascending aortic pressure waveforms of the second beat from **A**. The instantaneous catheter gradient (**closed circles**) is comparable with the Doppler-derived gradient (**open circles**). Note the slight phase delay related to the fluid-filled catheter system. The mean catheter gradient (area under the curve divided by gradient time) was 69 mm Hg and the mean Doppler-derived gradient was 74 mm Hg.

JACC Vol 7, No 4
April 1986 800–6

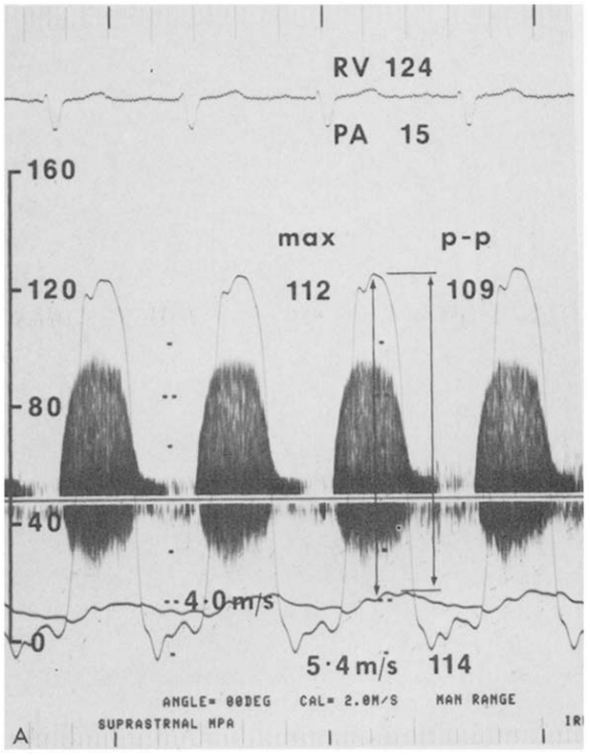

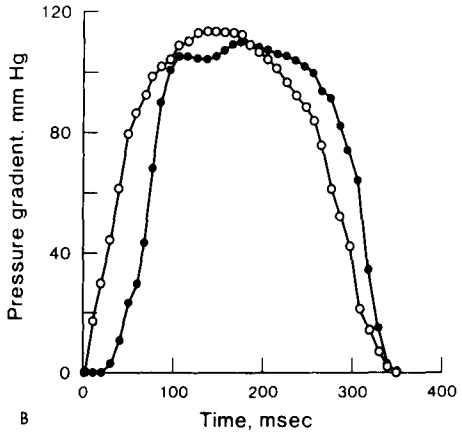

Figure 2. A, Simultaneous Doppler-catheter pressure recording in a patient with a pulmonary artery (PA) band. The maximal catheter gradient (max) of 114 mm Hg was comparable with the maximal instantaneous Doppler gradient of 112 mm Hg. The peak to peak catheter pressure gradient (p-p) was 109 mm Hg. Note the similar values of peak to peak and maximal Doppler gradients, a finding more typical of right ventricular (RV) outflow stenoses. **B**, Same patient. Instantaneous Doppler and catheter pressure gradients from the digitized Doppler spectral velocity envelope and simultaneous right ventricular and pulmonary artery pressure waveforms of the third beat from **A**. Note the phase delay of the fluid-filled catheter system. The mean catheter gradient (area under the **closed circle curve** divided by gradient time) of 80 mm Hg and mean Doppler-derived gradient (**open circle curve**) of 77 mm Hg were similar.

catheter gradient was defined as the maximal instantaneous pressure gradient across the stenosis. The maximal Doppler gradient was derived from the maximal Doppler spectral velocity. The peak to peak systolic catheter gradient was defined as the difference between the peak ventricular and peak arterial pressures; these peak pressures are nonsynchronous (Fig. 1A).

A fluid-filled catheter system was used for catheter pressure measurements in our study. The phase delay of the catheter gradient compared with the Doppler-derived gradient (Fig. 1B and 2B) was related to the mechanical delay of the fluid-filled catheter system. In a study of experimental aortic stenosis in a canine model in this laboratory (14), high fidelity pressure-tipped transducers were used and demonstrated a negligible phase shift.

Statistical analysis. Data are expressed as mean ± SD. The correlation of Doppler gradients with pressure gradients was assessed by linear regression analysis using a least squares method. Comparison of simultaneous Doppler measurements with nonsimultaneous Doppler measurements was made using a paired Student *t* test. Comparisons between the right ventricular outflow and left ventricular outflow stenotic lesions, of Doppler and catheter pressure gradients and the differences between the Doppler and catheter gradients were made with a nonpaired Student *t* test.

Results

Correlation of simultaneous Doppler-catheter pressure gradients. The maximal instantaneous Doppler-derived gradient ranged from 14 to 156 mm Hg (mean 72 ± 33) and the simultaneous maximal catheter pressure gradients ranged from 16 to 168 mm Hg (mean 76 ± 34). They correlated closely ($r = 0.95$ and SEE = 10 mm Hg) (Fig. 3A). The mean Doppler gradient ranged from 7 to 106 mm Hg (mean 46 ± 23) and the mean catheter pressure gradient ranged from 8 to 108 mm Hg (mean 48 ± 23). These values also correlated very closely ($r = 0.94$, SEE = 8) (Fig. 3B).

The peak to peak catheter gradient ranged from 0 to 154 mm Hg (mean 58 ± 34), which was significantly lower than either the maximal catheter gradient or the maximal Doppler gradient ($p < 0.001$). The correlation coefficient of the maximal Doppler-determined gradient and the peak to peak catheter gradient was 0.92 (SEE = 13 mm Hg).

Comparison of right and left ventricular outflow stenotic lesions. The mean values for maximal, mean Doppler and catheter pressure gradients for the 38 right and 62 left ventricular outflow obstructive lesions are shown in Table 1. There was similar close correlation between the maximal Doppler and catheter pressure gradients with the right ($r = 0.96$, SEE = 9 mm Hg) and left ventricular outflow stenotic lesions ($r = 0.95$, SEE = 11 mm Hg). The maximal Doppler gradient reliably estimated the maximal catheter gradients; the mean difference between the maximal gradients was 4 ± 9 mm Hg for right and 5 ± 11 mm Hg for left ventricular outflow stenotic lesions. The findings were sim-

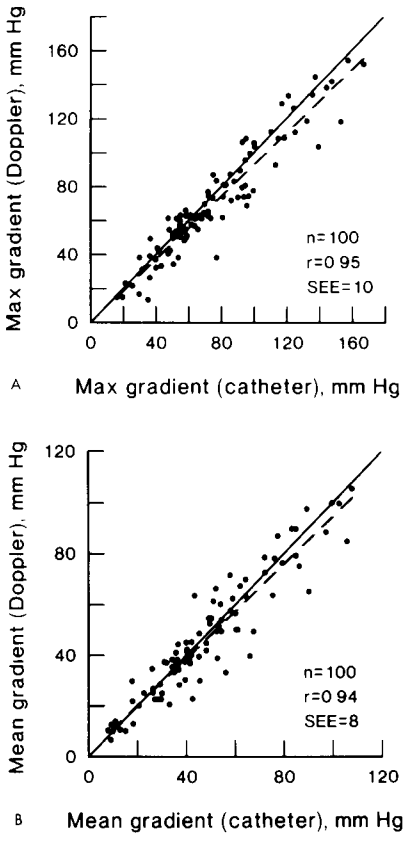

Figure 3. **A**, Correlation of simultaneous maximal (Max) Doppler and catheter pressure gradients in the 100 stenotic lesions. The regression equation is: Doppler gradient = 0.5 + 0.93 × catheter gradient. **B**, Correlation of simultaneous mean Doppler and catheter pressure gradients in the 100 lesions. The regression equation is: Doppler gradient = 1.8 + 0.93 × catheter gradient. The **dotted lines** represent the regression lines and the **solid lines** represent the lines of identity.

ilar when mean Doppler and catheter gradients were compared. The correlation coefficient of mean gradients in right ventricular outflow lesions was 0.93 (SEE = 8 mm Hg) and for left ventricular outflow lesions was 0.95 (SEE = 8 mm Hg). The average difference between the mean gradients was −1 ± 8 mm Hg for the right and 3 ± 8 mm Hg for the left ventricular outflow stenoses.

There was a small difference in correlation of peak to peak catheter gradient and maximal Doppler gradient for right ventricular outflow obstructive lesions (r = 0.95, SEE = 10) and for left ventricular outflow lesions (r = 0.92, SEE = 13) (Fig. 4B). However, there was a significant difference between the right and left ventricular outflow stenotic lesions for the mean difference between the peak to peak and maximal Doppler gradients. This difference was greater with left (mean −19 ± 13 mm Hg) than with right ventricular outflow tract obstructive lesions (mean −5 ± 10 mm Hg) ($p < 0.001$).

Table 1. Comparisons of Right Ventricular (RVOT) and Left Ventricular (LVOT) Outflow Tract Obstructive Lesions

	RVOT (n = 38) (mm Hg)	LVOT (n = 62) (mm Hg)	p Value
Maximal Doppler gradient	76 ± 32	69 ± 34	NS
Maximal catheter gradient	80 ± 32	74 ± 35	NS
Peak to peak (catheter) gradient	71 ± 33	51 ± 33	<0.01
Mean Doppler gradient	50 ± 21	45 ± 24	NS
Mean catheter gradient	49 ± 20	47 ± 25	NS
Maximal catheter − maximal Doppler gradient	4 ± 9	5 ± 11	NS
Mean catheter − mean Doppler gradient	−1 ± 8	3 ± 8	NS
Peak to peak − maximal Doppler gradient	−5 ± 10	−19 ± 13	<0.001
Peak to peak − maximal catheter gradient	−9 ± 6	−23 ± 11	<0.001

NS = not significant.

Nonsimultaneous (outpatient) versus simultaneous Doppler and catheter measurement. In the 49 patients with two Doppler studies, the outpatient Doppler velocities ranged from 2.0 to 5.9 m/s (mean 3.8 ± 0.9) and the Doppler velocities at cardiac catheterization ranged from 2.0 to 6.3 m/s (mean 4.2 ± 1.0). The outpatient Doppler gradients ranged from 16 to 140 mm Hg (mean 62 ± 29), the Doppler gradients at catheterization ranged from 16 to 156 mm Hg (mean 74 ± 35) and the maximal catheter gradient ranged from 20 to 168 mm Hg (mean 78 ± 35). The correlation coefficient of the outpatient maximal Doppler gradient and the maximal catheter gradient was 0.80 (SEE = 17 mm Hg). This was significantly lower than the simultaneous maximal Doppler and catheter gradient correlation in these 49 lesions (r = 0.96, SEE = 10 mm Hg) (Fig. 5).

Discussion

There have been few comprehensive clinical studies correlating Doppler-derived pressure gradients with simultaneous catheter gradients. Most have only compared nonsimultaneous maximal Doppler gradients with maximal or nonsynchronous peak to peak catheter gradients. Dual catheter measurement of pressure difference has infrequently been employed for measurement of comparative gradients, generally in small groups of patients and almost exclusively in relation to aortic stenosis. Most commonly, a pullback technique or use of simultaneous left ventricular and peripheral arterial pressures has been used for comparison (1–9). Both techniques are less than ideal. With catheter pullback, alignment of the proximal and distal pressure waveforms may be inaccurate because of variation of cardiac cycle length, especially in patients with arrhythmias and

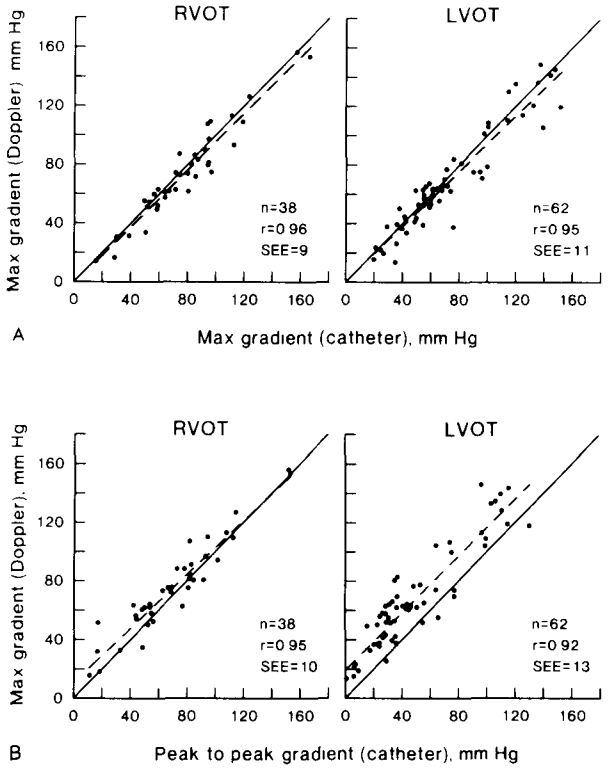

Figure 4. **A**, Correlation of simultaneous maximal (Max) Doppler and peak to peak catheter pressure gradients in the 38 right ventricular outflow (RVOT) stenotic lesions and 62 left ventricular outflow (LVOT) obstructive lesions. The regression equation is: Doppler gradient = 11 + 0.92 × peak to peak catheter gradient. **B**, Correlation of simultaneous mean Doppler and catheter pressure gradients in the same patients. The regression equation is: Doppler gradient = 21 + 0.94 × catheter gradient. The **dotted lines** represent the regression lines and the **solid lines** represent the lines of identity.

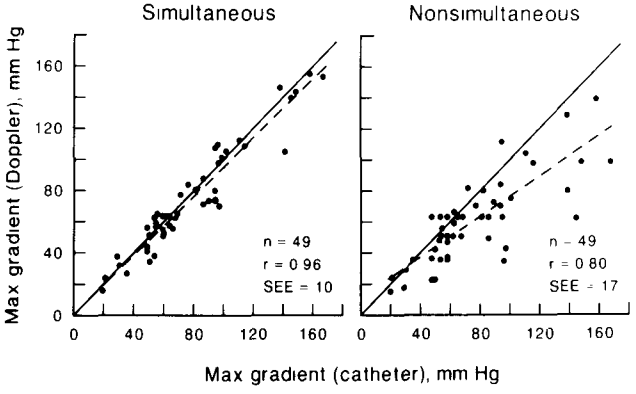

Figure 5. Nonsimultaneous versus simultaneous Doppler-catheter correlation. Correlation of simultaneous (**left**) and nonsimultaneous (**right**) maximal Doppler and catheter pressure gradients. The respective regression equations are: Doppler gradient = 0.98 × catheter gradient − 1.4 and 5.2 + 0.78 × catheter gradient. The **dotted lines** represent the regression lines and the **solid lines** represent the lines of identity.

respiratory variations in pressures. The use of ventricular to peripheral arterial pressure gradient is also suboptimal because of distortion of the arterial pressure waveform (that is, upstroke delay, peripheral systolic pressure amplification and ejection time prolongation) (15).

Peak ventricular and arterial pressures are nonsynchronous events and the pressure difference betwen them does not represent an instantaneous pressure gradient relation. Therefore, comparison of maximal instantaneous Doppler gradient with a nonsynchronous peak to peak gradient will lead to "overestimation" of the catheter gradient. However, a less than meticulous Doppler examination, resulting in suboptimal alignment of the ultrasound beam to the maximal velocity of flow, will underestimate the instantaneous pressure gradient. Because of these potential sources of error and the resultant variations in reported correlation, we undertook a study of a large group of patients with right or left ventricular outflow obstructive lesions. To show a beat to beat and instantaneous relation, we used a dual catheter technique and a direct current coupler, which permitted superimposition of calibrated catheter pressures and simultaneously recorded Doppler signals. We then analyzed the waveforms by computer at 10 ms intervals. Using this controlled clinical model in human subjects, we hoped to more accurately study the relation between noninvasive Doppler and catheter gradients.

Doppler maximal instantaneous pressure gradient versus peak to peak catheter gradient. This study showed that Doppler velocities represent an instantaneous pressure relation and as such are not comparable with peak to peak catheter gradients. The instantaneous gradient is normally greatest in early systole, well before the nonsynchronous peak to peak gradient. In fact, at peak aortic pressure, the instantaneous gradient has often returned to nearly zero (Fig. 1). Because aortic systolic pressure and pulse pressure are greater in amplitude than are pressures in the pulmonary artery, the difference between the maximal instantaneous and peak to peak pressure gradients is less evident with right than with left ventricular outflow tract obstructive lesions. Therefore, at almost any level of pressure gradient there will be a closer relation between the maximal instantaneous Doppler gradient and peak to peak catheter gradient for right ventricular outflow obstructions. Also, the higher the gradient, the less pulsatile the upstream arterial pressure waveform and the closer the relation between maximal instantaneous and peak to peak gradients.

A transvalvular gradient may be increased by a catheter across the stenotic valve. For left-sided lesions, this phenomenon would be difficult to document in a clinical setting, requiring both a transseptal approach and an additional arterial catheter. The design of the present study did not address this question. However, occasionally a change in blood flow characteristics was detected by Doppler study at the time of catheter withdrawal. Any hemodynamic effect caused by a catheter did not alter our comparison, because these

studies were performed simultaneously under steady state conditions.

Simultaneous versus nonsimultaneous catheter and Doppler studies. We found, in the same patients, a significant difference between a gradient determined simultaneously at catheterization and that obtained nonsimultaneously on an outpatient basis. These differences have many causes, but are probably largely attributable to a change in the hemodynamic state between the outpatient and the catheterization environment. In addition, the examination in the catheterization laboratory was performed with some knowledge of the underlying catheter gradient. Thus, a more meticulous examination was performed, which may have improved the correlation. It is to be expected that comparison of Doppler gradient with nonsimultaneous events may result in a lower correlation. However, this study does show that a meticulous examination using multiple transducer sites can give an excellent hemodynamic estimate of right and left ventricular outflow gradients. The gradient recorded in an outpatient environment may be obtained under a different hemodynamic state and therefore may not absolutely correspond to the nonsimultaneously measured catheter gradient. Other factors that should be considered include Doppler learning curve, suboptimal Doppler or catheter techniques or inappropriate hemodynamic comparisons. With the capability of accurate noninvasive measurement of pressure gradient, a change in clinical practice will surely occur. However, it is yet to be established how to best relate this new technique to conventional catheterization data obtained under a different hemodynamic state.

Potential errors. Doppler examination in our study was performed with the nonimaging Pedof transducer and without correction for presumed angle between the ultrasound beam and the maximal systolic jet. We have shown an accurate correlation between Doppler-derived and catheter-measured gradients. This is in contrast to reports in which angle correction has been advocated on the basis of estimation of the direction of blood flow using either two-dimensional echocardiography alone (15) or color flow Doppler imaging of the systolic jet (16,17). In our opinion, two-dimensional echocardiographic prediction of jet direction is fraught with potential error and should not be used for angle correction. Color flow Doppler imaging of jet lesions is exciting; however, there have been no comparisons between a comprehensive nonimaging continuous wave Doppler examination and color flow Doppler angle correction.

Conclusions. We have shown that continuous wave Doppler echocardiography can reliably estimate instantaneous and mean pressure gradients across both right and left ventricular outflow obstructive lesions. This study emphasizes that the Doppler examination measures instantaneous pressure gradient and the data cannot be directly compared with those of nonsimultaneous events, such as peak to peak gradient. Comparable events are, however, maximal instantaneous and mean catheter pressure gradients. Temporal change in patient state can alter the observed pressure gradient. Outpatient and catheterization results can be expected to vary depending on the state of the patient. Most importantly, proper understanding of the instantaneous relation between the Doppler velocity (gradient) and measured catheter gradient is critical for the optimal application of this exciting noninvasive technique.

We thank Elizabeth Dunnett for assistance with manuscript preparation and we also thank the staff of the catheterization and echocardiographic laboratories for assistance.

References

1. Hatle L, Angelsen BA, Tromsdal A. Noninvasive assessment of aortic stenosis by Doppler ultrasound. Br Heart J 1980;43:183–92.
2. Hatle L. Noninvasive assessment and differentiation of left ventricular outflow obstruction with Doppler ultrasound. Circulation 1981;64:381–7.
3. Lima CO, Sahn DJ, Valdes-Cruz LM, et al. Noninvasive prediction of transvalvular pressure gradient in patients with pulmonary stenosis by quantitative two-dimensional echocardiographic Doppler studies. Circulation 1983;67:866–71.
4. Kosturakis D, Allen HD, Goldberg SJ, Sahn DJ, Valdes-Cruz LM. Noninvasive quantification of stenotic semilunar valve areas by Doppler echocardiography. J Am Coll Cardiol 1984;3:1256–62.
5. Stamm RB, Martin RP. Quantification of pressure gradients across stenotic valves by Doppler ultrasound. J Am Coll Cardiol 1983;2:707–18.
6. Simpson IA, Houston AB, Sheldon CD, Hutton I, Lawrie TDV. Clinical value of Doppler echocardiography in the assessment of adults with aortic stenosis. Br Heart J 1985;53:636–9
7. Johnson GL, Kwan OL, Handshoe S, Noonan JA, DeMaria AN. Accuracy of combined two-dimensional echocardiography and continuous-wave Doppler recordings in the estimation of pressure gradient in right ventricular outlet obstruction J Am Coll Cardiol 1984;3:1013–8.
8. Berger M, Berdoff RL, Gallerstein PE, Goldberg E. Evaluation of aortic stenosis by continuous-wave Doppler ultrasound. J Am Coll Cardiol 1984;3:150–6.
9. Reeder GS, Currie PJ, Fyfe DA, Hagler DJ, Seward JB, Tajik AJ. Extracardiac conduit obstruction: initial experience in use of Doppler echocardiography for noninvasive estimation of pressure gradient. J Am Coll Cardiol 1984;4:1006–11.
10. Fyfe DA, Currie PJ, Seward JB, et al. Continuous-wave Doppler determination of the pressure gradient across pulmonary artery bands: hemodynamic correlation in 20 patients. Mayo Clin Proc 1984;59:744–50
11. Currie PJ, Seward JB, Reeder GS, et al. Continuous-wave Doppler echocardiographic assessment of calcific aortic stenosis: a simultaneous Doppler-catheterization study in 100 adult patients. Circulation 1985;71:1162–9
12. Hatle L, Angelsen B. Doppler Ultrasound in Cardiology: Physical Principles and Clinical Applications. Philadelphia: Lea & Febiger, 1982:62.
13. Currie PJ, Seward JB, Chan KL, et al Continuous wave Doppler determination of right ventricular pressure: a simultaneous Doppler-catheterization study in 127 patients. J Am Coll Cardiol 1985;6:750–6.
14. Callahan M, Tajik AJ, Su-Fan Q, Bove AA. Continuous wave correlation of pressure gradients in experimental aortic stenosis. Am J Cardiol 1985;56:989–93.

15. Kroeker EJ, Wood EH. Comparison of simultaneously recorded central and peripheral arterial pressure pulses during rest, exercise and tilted position in man. Circ Res 1955;3:623–32.

16. Valdes-Cruz LM, Sahn DJ, Scagnelli S, Lima CO. Accuracy of continuous wave 2D echo Doppler studies for prediction of gradients across pulmonary artery bands: clinical studies (abstr). J Am Coll Cardiol 1984;3:603

17. Sahn DJ, Valdes-Cruz LM, Swensson RE, Scagnelli S, Dalton N. Potential for angular errors in Doppler gradient estimates: a study of spatial orientation of jet lesions using real-time color flow Doppler imaging (abstr). Circulation 1984;70(suppl II):II-115.

18. Valdes-Cruz LM, Yoganathan AP, Sahn DJ, Sherman F, Swensson R. Accuracy of color encoded Doppler flow mapping techniques for defining stenotic jets: studies in an in vitro model and in the clinical setting (abstr). Second World Congress of Pediatric Cardiology. New York: Springer-Verlag, 1985:28.