

lar ejection fraction (EF) < 50% (n=18, low EF); and EF ≥ 50% (n=353, controls).

Results: There were no significant differences between the groups in regards to conventional cardiovascular risk factors. The change in CBF (mean±SE) in response to ACH was significantly diminished in the low EF patients when compared to the controls (2.3±20.9 % versus 63.5±6.1%, p=0.04). By multivariate analysis, low EF status was independently associated with depressed coronary microvascular dilation with ACH (p=0.002). There was no difference in the change in ED in response to ACH (-20.6±6.3% versus -12.8±1.4%, p=0.3). CFR was also decreased in low EF patients (2.5±0.2 versus 2.9±0.04, p=0.01), however, low EF status was not an independent predictor of CFR by multivariate analysis (p=0.2)

Conclusion: The study demonstrates that coronary microvascular endothelial dysfunction is present in asymptomatic left ventricular dysfunction. Thus, coronary endothelial dysfunction may be an early event in the pathophysiology of heart failure.

POSTER SESSION

1087 Cardiomyopathy, Imaging, and Constrictive Pericarditis

Monday, March 18, 2002, 9:00 a.m.-11:00 a.m.

Georgia World Congress Center, Hall G

Presentation Hour: 9:00 a.m.-10:00 a.m.

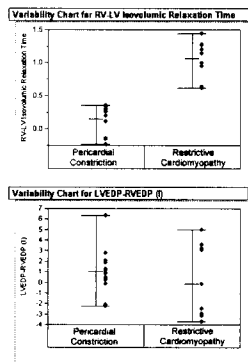
1087-146 Constrictive Pericarditis in the Modern Era: Novel Criteria for Diagnosis in the Cardiac Catheterization Laboratory

Deepak R. Talreja, Rick A. Nishimura, Jae Oh, Christopher Appleton, Stuart T. Higano, David Holmes, *Mayo Clinic, Rochester, Minnesota, Mayo Clinic, Scottsdale, Arizona.*

Background: Constrictive pericarditis (CP) and restrictive cardiomyopathy (RCM) are difficult to distinguish. Doppler findings and the finding of elevation and equalization of diastolic pressures at catheterization are nonspecific. We have shown that enhanced ventricular interaction with respiration is unique to patients with CP, but reliable criteria for this have not been established. We, therefore, examined intracardiac pressure waveforms from eight patients with CP and five patients with RCM. We selected waveforms from cardiac cycles with maximum and minimum right ventricular (RV) filling corresponding to peak inspiration and expiration. Calibrated measurements were used to compare the ratio of RV and left ventricular (LV) systolic durations.

Results: All patients had elevation and equalization of diastolic pressures in all cardiac chambers. However, when the ratio of inspiratory to expiratory RV systolic duration was compared with the ratio of inspiratory to expiratory LV systolic duration, patients with CP had a mean of 1.41 (range 1.2 to 2.0) versus RCM patients with a mean of 0.97 (range 0.9 to 1.1). When comparing the time difference during isovolumic relaxation between the RV and LV, the difference is even more pronounced (chart).

Conclusion: The ratio of RV to LV systolic duration during inspiration and expiration may distinguish CP from RCM. This is consistent with the concept of filling and ejection of the RV and LV show greater interdependence in patients with CP than those with RCM.



1087-147 Natural History of Familial Dilated Cardiomyopathy: The Heart Muscle Disease Registry of Trieste

Andrea Di Lenarda, Elisa Carniel, Gastone Sabbadini, Mauro Driussi, Serena Rakar, Cinzia Di Chiara, Cristiana Zanchi, Gianfranco Sinagra, Luisa Mestroni, *Department of Cardiology, Trieste, Italy, University of Colorado Cardiovascular Institute, Denver, Colorado.*

The aim of the study was to analyse the natural history of familial dilated cardiomyopathy (FDC), as compared to that of sporadic forms of the disease. From January 1978 to December 1997, 441 patients with dilated cardiomyopathy (DC) were consecutively enrolled in the Heart Muscle Disease Registry of Trieste and prospectively followed up for a mean of 81 ± 50 months. On the basis of an extensive familial pedigree evaluation, complete clinical-instrumental examination and, when available, molecular genetic studies, 82 (19%) patients (deriving from 55 families) were diagnosed to have FDC. At enrolment, patients with FDC were younger (39±14 vs 47±14 years, p<0.0001) and exhibited less frequently the presence or history of heart failure (HF) symptoms (44% vs 67%, p<0.0001) and the existence of left bundle branch block (18% vs 35%, p=0.002) in comparison to those with sporadic DC; conversely, no significant difference between the 2 cohorts was detectable in LV ejection fraction (32±10 vs 31±11%, p=NS) and end-dias-

toxic diameter index (37±6 vs 38±7 mm/m², p=NS), as well as in the use of ACE-inhibitors (79 vs 74%, p=NS) and beta-blockers (67 vs 64%, p=NS). Two, 4 and 8-year transplant-free survival was 91, 88 and 79% in patients with FDC and 89, 78 and 64% in patients with sporadic DC (p=0.011); 2, 4 and 8-year hospitalisation-free survival was respectively 68, 65 and 50% and 69, 54 and 37% (p=0.041). However, after stratification for the presence or history of HF symptoms, the outcome of the 2 cohorts was not significantly different. Patients with FDC show a better long-term outcome in comparison to patients with sporadic DC. However, this is likely to be an effect of an earlier identification and treatment of FDC patients, since the natural history of familial and sporadic forms of DC does not differ after stratification of the patients for the severity of the disease. Large clinical studies are warranted to better evaluate whether any difference exists in outcome among different forms of FDC as well as to ascertain the potential benefits of an early effective treatment in asymptomatic relatives of FDC patients.

1087-148 Myocardial Fibrosis Imaging in Hypertrophic Cardiomyopathy Using Gadolinium Enhanced Magnetic Resonance Imaging: Correlation With Risk of Arrhythmia and Progressive Disease

James C. Moon, William McKenna, Gillian C. Smith, Jane McCrohon, Perry M. Elliott, Dudley J. Pennell, *Royal Brompton Hospital, London, United Kingdom, St Georges Hospital, London, United Kingdom.*

Background: Some patients with Hypertrophic Cardiomyopathy (HCM) are at risk of sudden death due to ventricular arrhythmias and to heart failure. Myocardial fibrosis is thought to play a key role in these processes. We hypothesized that myocardial fibrosis could be demonstrated by gadolinium enhanced MRI in HCM and that its presence would associate with risk of arrhythmia and evidence of progressive disease.

Methods: A blinded, case matched prospective study with predefined statistical analysis. 33 patients with HCM were studied. Risk of sudden death was graded 0-4 on: a family history of ≥ 2 sudden death (<40 years), unexplained syncope, non-sustained VT (holter) and an abnormal exercise blood pressure response. Progressive LV dilatation was defined on serial echo as a decrease in maximal LV wall thickness and an increase in LV end systolic dimension of ≥ 5 mm over at least 5 years. Imaging was performed on a 1.5T Sonata scanner. TrueFISP cine imaging and contrast enhance (CE) modified inversion recovery gadolinium imaging was performed. LV volumes, function and mass and total myocardial CE assessed by planimetry.

Results: 22 (67%) of patients had CE. The mean percentage CE was 8.42% of the myocardium (range 0-30%; SD 9.7%). 3 patterns of CE were seen: sub-endocardial, fluffy septal and confluent blocks. Patients with LV dilatation had more CE than patients without dilatation. (27% vs 5%, p=0.005). Patients with ≥3 clinical risk factors had more CE than those with 0 or 1 risk factors (24% vs 5.8%, p=0.0005). No patient with 3 risk factors or a history of dilatation had less than 20% CE but 3 patients with 0 or 1 risk factors and no dilatation had >10% CE.

Conclusion: CE is found in HCM. Different pattern were observed, which may represent subendocardial fibrosis, severe myocardial disarray or fibrosis from small vessel myocardial ischaemia. CE was associated with LV dilatation and the risk of arrhythmia. These data suggest a role for gadolinium enhanced MRI in risk assessment of disease progression and sudden death.

1087-149 Transmural Principal Strains in Tachycardia-Induced Cardiomyopathy

Frederick A. Tibayan, David T. Lai, Tomasz A. Timek, Paul Dagum, David Liang, George T. Daughters, Neil B. Ingels, D. Craig Miller, *Stanford University, Stanford, California, Palo Alto Medical Foundation, Palo Alto, California.*

Background: Principal strains in normal hearts are greater in LV endocardium than epicardium but similarly oriented. Tachycardia-induced cardiomyopathy (TIC) causes hypoperfusion and metabolic changes at the endocardium, but the effects of TIC on transmural principal strains have not been fully characterized. **Methods:** Radiopaque markers were implanted in eight sheep, with a subendocardial triangle underlying a sub-epicardial triangle in the anterior LV wall. One week postoperatively, biplane fluoroscopy was used to determine 3D marker dynamics (Control). Rapid ventricular pacing (180-250 bpm) was instituted until signs of heart failure developed (15±6 days, TIC). With the pacer off, fluoroscopy was repeated. The magnitude and direction (circumferential = 0°) of 2D principal strains were computed from triangle deformations from end-diastole to end-systole. **Results:** (Table) TIC decreased both epicardial and endocardial principal strains, increased the endo/epi strain imbalance, and changed the direction of the epicardial principal strain towards the circumferential. **Conclusions:** These changes with TIC are consistent with a detrimental shift in the transmural distribution of myocardial strain towards the endocardium and likely reflect alterations in functional tethering between fiber layers associated with structural remodeling.

	Control	TIC	p
Endo Principal Strain	-0.117±0.047	-0.073±0.037	.023
Epi Principal Strain	-0.095±0.055	-0.040±0.032	.006
Endo/Epi Principal Strain	1.36±0.55	2.49±1.13	.011
Endo Angle (deg)	-25±28	-35±23	NS
Epi Angle (deg)	-50±20	-19±23	.004