JACC Vol. 30, No. 2
August 1997:370–6

Iodine-123 Metaiodobenzylguanidine Cardiac Imaging to Identify and Localize Vasospastic Angina Without Significant Coronary Artery Narrowing

KAZUYUKI SAKATA, MD, PHD, MANABU SHIROTANI, MD, PHD, HIROSHI YOSHIDA, MD, CHINORI KURATA, MD, PHD*

Shizuoka and Hamamatsu, Japan

Objectives. **We assessed the ability of iodine-123 metaiodobenzylguanidine (MIBG) imaging to identify and localize coronary spasm and determined the most useful method of MIBG analysis in vasospastic angina without significant coronary narrowing.**

Background. **Various noninvasive methods have been used to detect vasospastic angina, but they are not very sensitive in patients with sporadic attacks. MIBG imaging has recently been proposed as a useful tool for detecting vasospastic angina.**

Methods. **Normal limits of both visual and quantitative analysis of two-dimensional polar maps (bull's-eyes) for MIBG imaging were at first established in 59 normal subjects. For optimal criteria of visual analysis, we established regional differences in abnormal MIBG defect scores. An abnormal region of the bull's-eye was defined as an area >2 SD below normal. An abnormal regional washout rate was defined as <0%. Using these criteria, we prospectively evaluated 104 patients with suspected vasospastic angina. Visual, bull's-eye and regional washout rate analyses were compared for overall detection of the disease and for individual vessel involvement.**

Results. **Overall sensitivity by these methods was 30%, 42% and 76%, respectively. Washout rate analysis showed a significantly higher sensitivity than the other two methods. Specificity was 78%, 72% and 87%, respectively. The sensitivity of detecting spasm-induced coronary artery with washout rate analysis was 82% for the left anterior descending (LAD), 76% for the right (RCA) and 69% for the circumflex (Cx) coronary arteries. The sensitivity of visual analysis was 29%, 15% and 35%, respectively; that for bull's-eye analysis was 34%, 54% and 41%, respectively. Washout rate analysis showed a significantly higher sensitivity for LAD spasm than for the other two methods and a higher sensitivity for RCA and Cx spasms than for visual analysis.**

Conclusions. **Regional washout rate analysis of MIBG imaging is a highly accurate technique for determining the presence and location of coronary artery spasm.**

(J Am Coll Cardiol 1997;30:370–6)

Various noninvasive diagnostic techniques for vasospastic angina have been recommended (1–9). However, many physicians consider these noninvasive modalities frustrating, especially in patients with infrequent episodes of chest pain. Recently, several studies (10–12) have proposed that iodine-123 metaiodobenzylguanidine (MIBG) imaging could be a useful tool for detecting vasospastic angina. Because various physiologic factors are known to influence MIBG images (13–16), considerable experience and attention are required for visual interpretation of MIBG imaging. Therefore, as in thallium-201 imaging (17), quantification of the uptake and washout of MIBG and the use of normal limits for comparison might overcome these limitations.

The present study assessed the ability of MIBG imaging to identify and localize coronary artery spasm and to determine the most useful method of MIBG imaging analysis in vasospastic angina without significant coronary narrowing.

Methods

Patients. In preliminary studies, we examined 59 patients >40 years old (range 40 to 69; 30 men, mean [± SD] age 57 ± 112 years; 29 women, mean age 58 ± 9 years) who were referred for cardiac catheterization because of chest pain, which revealed normal coronary artery without spasm and normal cardiac function. After cardiac catheterization, they underwent MIBG imaging. These subjects had no diabetes mellitus or any other disease affecting the autonomic nervous system. In this group, we established optimal criteria for visual analysis and generated normal two-dimensional polar maps (bull's-eyes) for men and women. After these data were obtained, the prospective study was performed.

Between September 1995 and June 1996, we prospectively selected 116 patients >40 years old with chest pains at rest that were limited to a few attacks per week within the 3 months

From the Department of Cardiology, Shizuoka General Hospital, Shizuoka and *Third Department of Internal Medicine, Hamamatsu University School of Medicine, Hamamatsu, Japan.

Manuscript received August 8, 1996; revised manuscript received March 31, 1997, accepted April 17, 1997.

Address for correspondence: Dr. Kazuyuki Sakata, Department of Cardiology, Shizuoka General Hospital, 4-27-1 Kita-andou, Shizuoka, Japan.

Published by Elsevier Science Inc.

0735-1097/97/$17.00
PII S0735-1097(97)00159-9

Abbreviations and Acronyms

Cx = circumflex coronary artery
LAD = left anterior descending coronary artery
MIBG = iodine-123 metaiodobenzylguanidine
RCA = right coronary artery

before MIBG imaging. No patient showed any reliable evidence of vasospastic angina, except for chest pain at rest before cardiac catheterization. All subjects underwent cardiac catheterization within 2 weeks of MIBG imaging. At least one coronary artery spasm was present in 50 of these patients, and 54 had insignificant coronary artery narrowing without spasm. We excluded 12 patients with coronary artery stenosis >50% in at least one vessel (10 patients) or left ventricular wall motion abnormality (2 patients with coronary artery spasm). No patient included in the study had a previous myocardial infarction, diabetes mellitus or any other disease affecting the autonomic nervous system. Of the 50 patients with coronary artery spasm, 34 showed single-vessel spasm (22 patients with left anterior descending coronary artery [LAD] spasm, 11 with the right coronary artery [RCA] spasm, 1 with circumflex coronary artery [Cx] spasm). Two-vessel coronary artery spasm was observed in 14 patients (4 with both LAD and RCA spasm, 10 with both LAD and Cx spasm). Three-vessel coronary artery spasm was observed in two patients. No patient took any antianginal drugs other than sublingual nitroglycerin before cardiac catheterization. Informed consent was obtained from each patient. This study protocol was approved by the hospital's ethics committee.

Coronary angiography. Within 2 weeks after MIBG imaging, coronary angiography with the acetylcholine provocation test was performed by the standard Judkins technique in all patients, as described previously (11,12). In brief, acetylcholine was injected in incremental doses of 20 and 100 μg directly into the RCA and, subsequently, the left coronary artery through the Judkins catheter after control coronary arteriograms were obtained. The results of coronary angiography after injection of nitroglycerin were classified according to the reporting system of the American Heart Association. Coronary artery spasm induced by acetylcholine was considered present if total or subtotal occlusion (a reduction in lumen diameter ≥99%) of the involved artery occurred in association with chest pain and ischemic ST segment changes (>0.1-mV ST segment elevation or depression from control levels).

MIBG scintigraphy. A dose of 111 MBq of commercially available MIBG (Daiichi Radioisotopes Labs., Ltd., Tokyo, Japan) was administered intravenously. Cardiac images were acquired 15 min (initial image) and 3 h (delayed image) after the injection of MIBG, using a three-headed gamma camera (Toshiba GCA 9300A/HG, Tokyo, Japan), with 120° rotation/head, 3° increments, 30 s/step and a 128 × 128 matrix. The data were reconstructed by filtered backprojection (Shepp-Logan) on a Toshiba GMS 5500A system. Neither scatter correction nor attenuation correction was performed. Oblique tomographic slices on the short, vertical long and horizontal long axes were computed and displayed.

Analysis of MIBG imaging. For visual analysis, tomograms were divided into 26 segments, as shown in Figure 1a. The short-axis slices were separated into eight segments at the apical, mid and basal ventricular levels. Vertical long-axis slices were used to evaluate the apical portion, which was divided into two segments. Each segment on the delayed images was visually analyzed using a 0 to 4 scale (0 = normal; 1 = equivocally reduced uptake; 2 = mildly reduced uptake; 3 = moderately reduced uptake; 4 = severely reduced uptake) by two experienced observers. The left ventricular myocardium was divided into the same three vascular territories as the bull's-eye. Differences of opinion were resolved by consensus. Quantitative analysis of MIBG uptake and washout rate in the left ventricle was performed as described previously (11,12). In short, the extent polar map depicting the extent of MIBG abnormality was obtained by comparing normalized maximal count values for each point on the generated bull's-eye with corresponding lower normal limits at 2 SD below the mean value derived from age- and gender-matched normal subjects who were examined in the preliminary portion of this study (Fig. 2 and 3). In our experience, the extent of MIBG abnormalities had to contain at least 2% of the pixels in the bull's-eye to be significant in women; 3% was required in men. Regional quantitative analysis of the washout rate of MIBG was also performed (Fig. 2 and 3). An abnormal regional washout rate in any region was defined as >0%. On a bull's-eye representation, the territory in each of the three major coronary arteries was defined as previously described (11,12).

Statistical analysis. Statistical assessment of the data used an individual patient as the unit of analysis. *Sensitivity* was defined as the number of true positive tests × 100 divided by the sum of the true positive and false negative tests. *Specificity* was defined as the number of true negative tests × 100 divided by the sum of the true-negative and false-positive tests. *Predictive accuracy* was defined as the number of true positive and true negative tests × 100 divided by the total number of tests. Chi-square analysis or a Fisher exact test was used to determine the significance of differences in the observed occurrence rates. Comparisons among the three groups (normal patients and patients with and without vasospastic angina) were performed by analysis of variance followed by the Bonferroni multiple comparison test. A p value <0.05 was considered significant.

Results

Normal MIBG distribution and optimal criteria of visual analysis. The mean MIBG defect scores in each segment for men and women are shown in Figure 1b. Both men and women had lower MIBG uptake in the basoseptal, inferoseptal, septoinferior, lateroinferior and inferolateral segments of all short-axis slices and the apicoinferior segments of the vertical

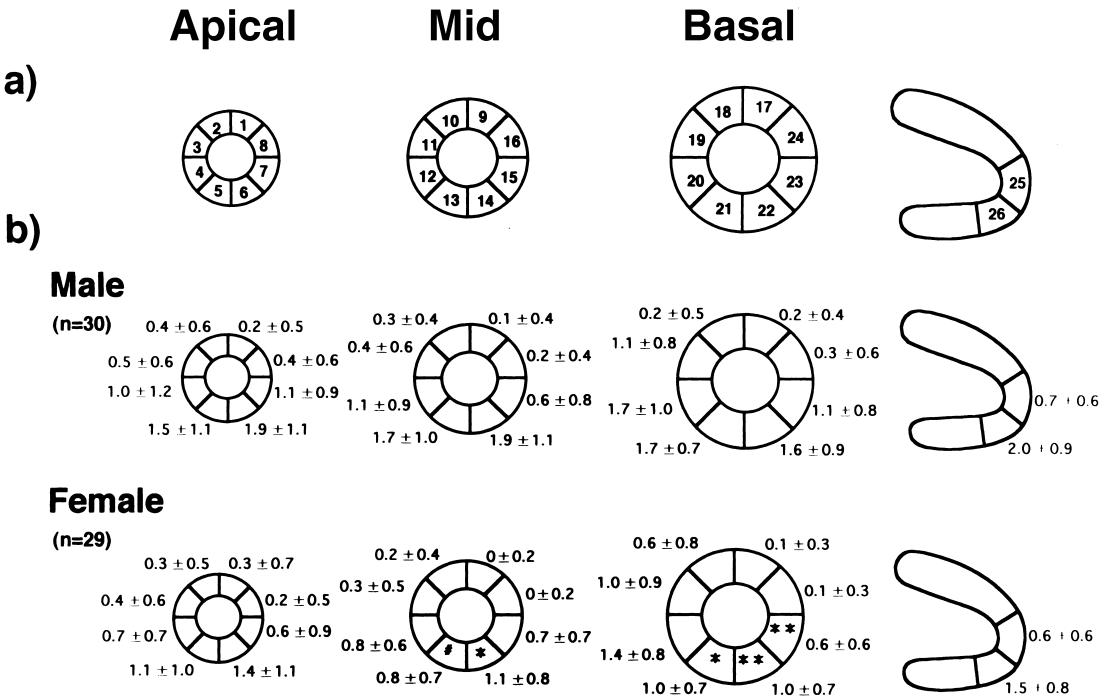

Figure 1. **a**, Separation of MIBG delayed images into 26 segments: 1, 9, 17 = anterolateral; 2, 10, 18 = anteroseptal; 3, 11, 19 = superoseptal; 4, 12, 20 = inferoseptal; 5, 13, 21 = septoinferior; 6, 14, 22 = lateroinferior; 7, 15, 23 = inferolateral; 8, 16, 24 = superolateral; 25 = anteroapical; 26 = inferoapical. For comparison with a bull's-eye, the segments were classified into the territories of the three major coronary arteries. The territory of the LAD = 1, 2, 3, 4, 9, 10, 11, 12, 17, 18, 19, 20, 25. The territory of the RCA = 5, 6, 13, 14, 21, 22, 26. The territory of the Cx = 7, 8, 15, 16, 23, 24. **b**, Results of visual analysis of MIBG images for men and women, expressed as mean value ± SD. *$p < 0.005$. **$p < 0.01$. #$p < 0.001$.

long-axis slice than that in the other segments. The two inferior segments at the mid and basal short-axis slices and the inferolateral segment at the basal short-axis slice showed a significantly higher MIBG defect score in men than in women. According to these findings, an abnormal defect score in each region was determined as more than the mean value ± 2 SD of the defect score in each segment.

Table 1 shows the actual values obtained from various analyses. In the washout rate analysis, patients with vasospastic angina had a significantly reduced regional washout rate in every region compared with normal patients and those without vasospastic angina.

Comparison of various analyses of MIBG imaging for identification of vasospastic angina. The overall sensitivity, specificity and predictive accuracy for detecting vasospastic angina on visual, quantitative and regional washout rate analyses are shown in Figure 4. Of the 50 patients with vasospastic angina, regional washout rate analysis identified 76% (n = 38), which was significantly higher than visual (30% [n = 15]) and quantitative (42% [n = 21]) analyses ($p < 0.01$ for both). Of the 54 patients without coronary spasm, 47 (87%) showed negative findings on regional washout rate analysis, which was significantly higher than 42 (78%) on visual analysis, and 39 (72%) showed negative findings on quantitative analysis. The overall accuracy of regional washout rate analysis (82%) was significantly higher than those of visual (55%) and quantitative analyses (58%) ($p < 0.01$ for both).

Comparison of various analyses of MIBG imaging for localization of spasm-induced coronary artery. The ability to detect individual spasm-induced coronary artery is compared in Figure 5. Of 38 patients with LAD spasm, regional washout rate analysis (82% [n = 31]) showed a significantly high sensitivity compared with that of visual (29% [n = 11]) and quantitative (34% [n = 13]) analysis ($p < 0.01$ for both). Likewise, regional washout rate analysis for patients with RCA (76% [n = 13]) or Cx (69% [n = 9]) spasm showed a significantly higher sensitivity than visual analysis (35% [n = 6] for RCA spasm, $p < 0.05$; 15% [n = 2] for Cx spasm, $p < 0.02$). In addition, regional washout rate analysis (90%) showed a significantly higher specificity for RCA spasm than visual analysis (76%) ($p < 0.05$). Regional washout rate analysis (84%) showed a significantly higher predictive accuracy for LAD spasm than visual (61%) and quantitative (67%) analysis ($p < 0.01$ for both) and a significantly higher predictive accuracy for RCA spasm than visual analysis ($p < 0.01$). In 16 patients with multivessel coronary artery spasm, both regional washout rate and quantitative analysis correctly identified all spasm-induced arteries in 7 (44%) patients, and visual analysis identified all spasm-induced arteries in 2 (12%).



Figure 2. Images from a 52-year old man without coronary vasospasm. **Upper panel**, MIBG delayed images in the basal, mid- and apical short axis and mid-vertical long axis. **Lower panel**, **A** shows extent score (ES) and severity score (SS) for each region (L = lateral; A = anterior; S = septal; I = inferior) positioned in, and compared with, a normal bull's-eye. There were no abnormal scores in this case. **B**, Bull's-eye representing the three-dimensional myocardial MIBG count distribution on a scale ranging from white (high counts) to black (low counts). **C and E**, Mean percent MIBG uptake and mean MIBG washout rate (WR), respectively, in each area generated by dividing myocardial profile maps into 48 sectors. **D**, Bull's-eye representing the three-dimensional myocardial MIBG washout rate distribution on a scale ranging from white (high washout rate) to black (low washout rate). At the **lower right corner**, average values of percent MIBG uptake and washout rate for each territory are summarized. All analyses correctly identified this patient as having no spasm. MAX = maximum; MIN = minimum.

Discussion

This prospective study showed that the regional washout rate analysis of MIBG imaging had a high diagnostic value for detection of vasospastic angina and spasm-induced coronary arteries.

Comparison of various analyses of MIBG. It is well known that many physiologic factors, such as gender (13), age (13) and high MIBG uptake of the liver and spleen (14), and regional differences in sympathetic nerve innervation in the left ventricle (13–16) affect MIBG uptake. In addition, a reduced MIBG uptake at the cardiac apex (16), septum (14,15) and inferior wall (14) have been reported. The present study demonstrated that reduced MIBG uptake in normal subjects >40 years old was observed in the inferior and inferoseptal walls and frequently in the apical inferior wall and was more prominent in men than women. On the basis of these findings, we especially established criteria for visual analysis of MIBG image. However, visual analysis showed a low sensitivity for vasospastic angina without significant coronary narrowing. Recently, several investigators (11,12,14,18) have assessed MIBG imaging using the same quantitative analysis (bull's-eye) as that used for thallium-201 imaging. Superiority of quantitative analysis over visual analysis has generally been shown with thallium-201 imaging. In the present study, however, even with this quantitative analysis, diagnostic values were only slightly improved. Considering the limited extent of the reduction in MIBG uptake on quantitative analysis as shown in Table 1 and the low sensitivity of visual analysis, ischemic attacks due to coronary spasm do not usually cause apparent sympathetic nerve denervation in patients with vasospastic angina. In contrast to the two analyses, regional washout rate analysis of MIBG showed a high diagnostic value.

We believe that MIBG washout rather than MIBG uptake is a useful marker of sympathetic activity if severe denervation is not present because, as demonstrated in myocardial infarction (19,20), denervation increases the MIBG washout rate. In such a case, regional MIBG uptake as well as regional MIBG washout appears to be important in assessing sympathetic activity. It has been demonstrated (21) that patients with congestive heart failure had high MIBG washout, which could represent increased sympathetic activity. Therefore, it is reasonable to assume that a decreased MIBG washout rate represents decreased sympathetic activity. In the present study, apparently abnormal values of regional washout rate related to coronary spasm were defined as <0%, which was >2 SD below normal regional washout rates (as shown in Table 1). Given the pharmacology of MIBG (15), this extremely low washout rate (negative values) may result from a longer half-life of MIBG in the heart of patients with vasospastic angina, which would be in agreement with measurements of 3H-norepinephrine in rat hearts (22). Thus, we could not precisely measure the washout rate approaching zero, which causes negative washout rate

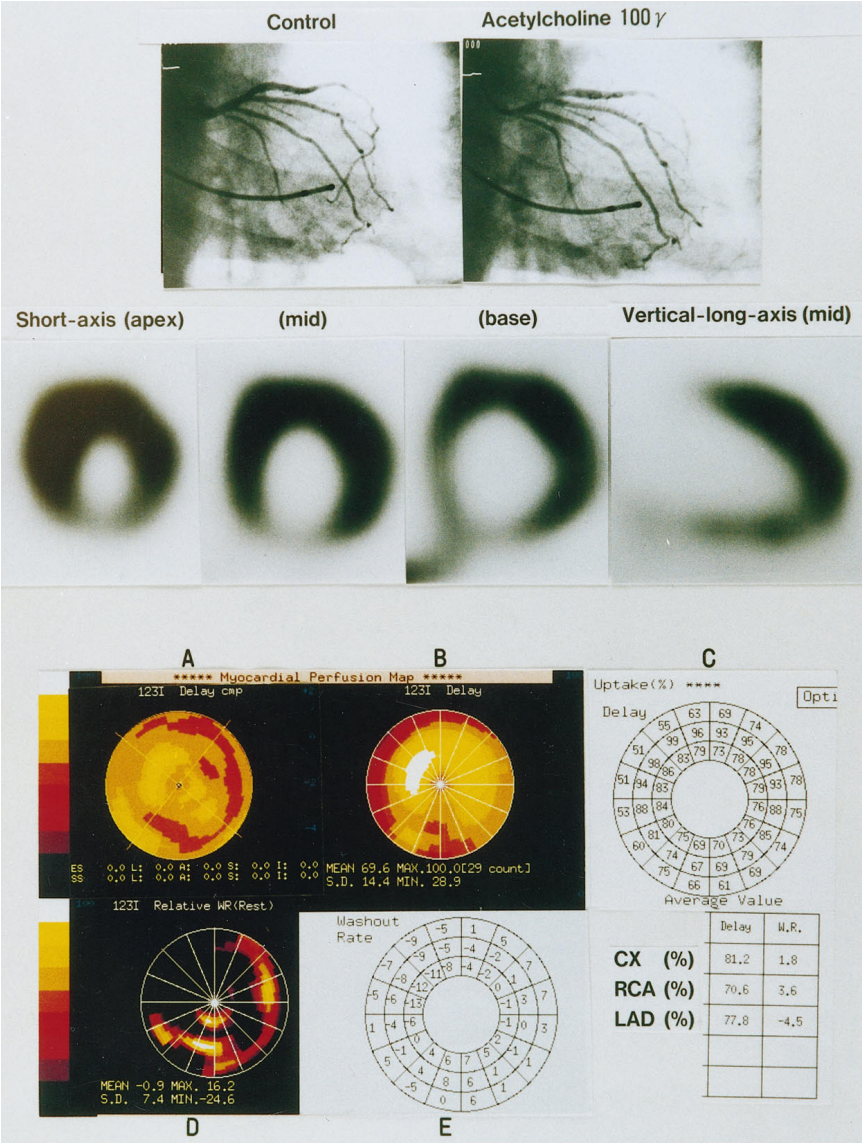

Figure 3. Images from a 60-year old man with LAD spasm. **Upper panel**, Coronary angiography showed >99% stenosis of the proximal LAD after intracoronary injection of 100 μg of acetylcholine. **Middle panel**, Normal MIBG delayed images. **Lower panel**, Bull's-eye showed no abnormal scores (**A**), and washout rate in the LAD territory was −4.5%. Only washout rate analysis correctly identified this patient as having LAD spasm. See Figure 2 for explanation of MIBG images. Abbreviations as in Figure 2.

values. However, we assumed that this extremely slow washout rate might result from strong suppression of norepinephrine release by the enhanced parasympathetic nervous system because it has been proposed (23,24) that the parasympathetic nervous system contributes to the pathogenesis of coronary vasospasm. This hypothesis is partially supported by the finding that the negative washout rate returns to normal on atropine–stress MIBG scintigraphy (11,12). However, because 13% of patients without coronary vasospasm had a regional washout rate <0%, a markedly enhanced parasympathetic nervous system may be an important condition, but other factors such as endothelial dysfunction are indispensable in inducing coronary spasm. Thus, it is considered that washout rate analysis is based on the pathophysiology of coronary spasm, whereas the

Table 1. Results of Visual, Quantitative and Regional Washout Rate

	Visual (mean defect score)			Quantitative (extent score, %)			Washout Rate (regional washout rate, %)		
Group	LAD	Cx	RCA	LAD	Cx	RCA	LAD	Cx	RCA
Normal pts (n = 59)	7.8 ± 5.1	3.1 ± 2.7	10.1 ± 5.3	—	—	—	9.9 ± 4.5	11.8 ± 5.5	12.0 ± 5.3
Pts without VSA (n = 54)	8.2 ± 4.9	4.1 ± 3.8	12.0 ± 6.8	1.2 ± 2.1	1.0 ± 2.2	1.0 ± 2.2	6.8 ± 5.2	8.3 ± 5.9	10.7 ± 6.8
Pts with VSA (n = 50)	6.7 ± 6.8	3.6 ± 3.1	9.6 ± 7.4	0.9 ± 1.9	0.7 ± 1.7	1.3 ± 2.0	−0.4 ± 8.3*	2.2 ± 7.9*	4.0 ± 7.8*

*$p < 0.0001$ versus patients (pts) without vasospastic angina (VSA) and normal patients. Data presented are mean value ± SD. Cx = circumflex coronary artery territory; LAD = left anterior descending coronary artery territory; RCA = right coronary artery territory.

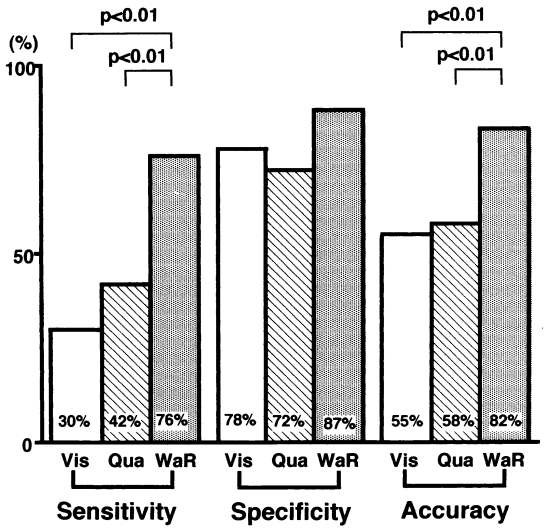

Figure 4. Comparison of sensitivity, specificity and overall accuracy of visual (Vis), quantitative (Qua) and regional washout rate (WaR) analyses for detection of vasospastic angina on MIBG imaging.

other two analyses are based on ischemia resulting from coronary spasm.

Comparison with previous studies. As noninvasive methods, the cold pressor test (2,5), hyperventilation test (1,2,4–6) and exercise (3,7) have been used to detect coronary artery spasm in vasospastic angina. These tests are well known to show a high sensitivity in patients with high disease activity (1) but low sensitivity in patients with sporadic attacks. Furthermore, thallium-201 emission computed tomography combined with one of these tests was reported (7–9) to increase sensitivity and provide an advantage in locating the spasm-induced coronary artery. Although the present study evaluated patients with vasospastic angina with sporadic attacks, the sensitivity of regional washout rate analysis of MIBG imaging was 76%, which is higher than that in previous reports (1,2,6–8). In addition, regional washout rate analysis could also detect the location of the spasm-induced coronary artery with high diagnostic values. Recently, Takano et al. (10) demonstrated the usefulness of MIBG imaging combined with thallium-201 imaging in detecting patients with vasospastic angina with high sensitivity (92%) and specificity (88%).

Clinical implications. It is still unknown what frequency and duration of ischemic attack are needed to affect the cardiac sympathetic nerves resulting in reduced MIBG uptake, although histologic studies have demonstrated (25,26) that depletion of norepinephrine from cardiac nerve endings can occur after 30 min of ischemia. Many investigators have demonstrated that severe or frequent ischemic attacks, such as those in unstable angina (27) and myocardial infarction (19,20), caused a reduction in MIBG uptake. Therefore, severe myocardial ischemia due to coronary artery spasm most likely results in sympathetic denervation in vasospastic angina. Indeed, we had two patients with vasospastic angina with extensive or severe reduction of MIBG uptake over the territory of the spasm-induced coronary artery who were excluded from this study. However, these patients included a small number of patients with vasospastic angina without significant coronary

Figure 5. Sensitivity (**A**), specificity (**B**) and predictive accuracy (**C**) for detection of individual spasm-induced coronary arteries by MIBG imaging. Abbreviations as in Figure 4.

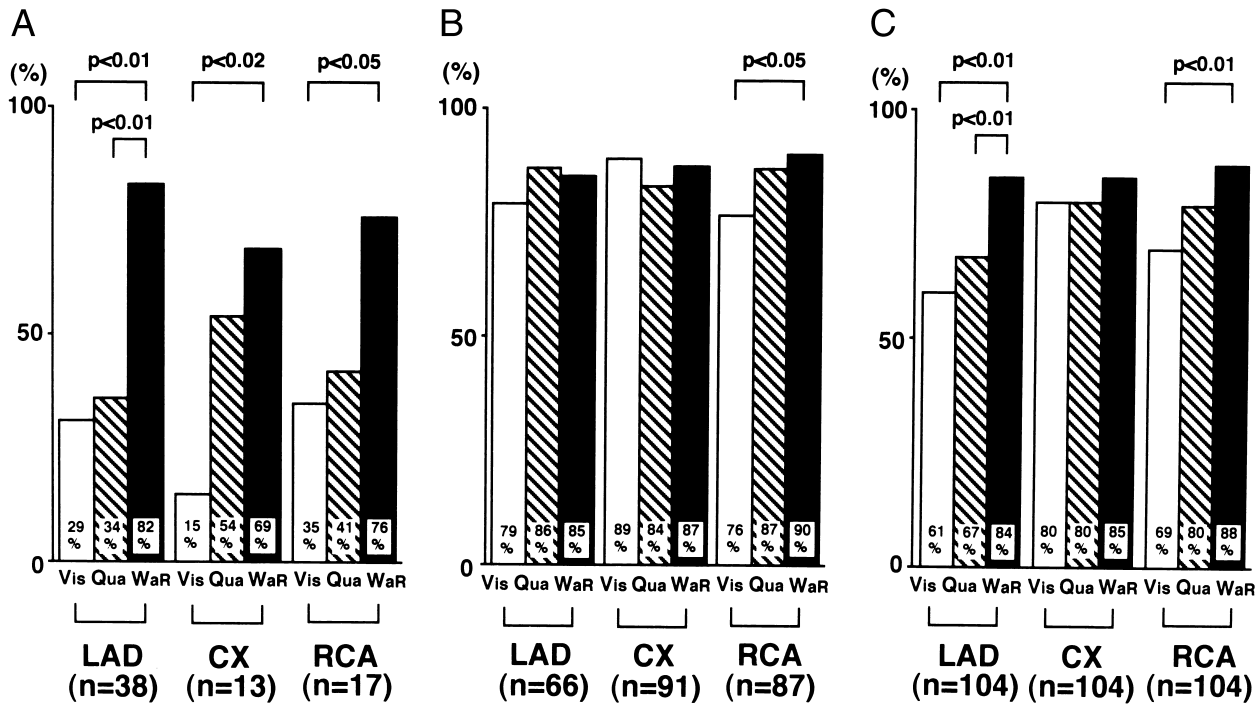

artery narrowing, whose abnormality on MIBG imaging could suggest the presence of heart disease, even if vasospastic angina is not considered. Furthermore, patients with vasospastic angina, if they have frequent ischemic attacks, could be easily detected by other noninvasive methods.

Conclusions. Regional washout rate analysis of MIBG imaging is a useful noninvasive method of detecting patients with vasospastic angina with sporadic attacks and identifying spasm-induced coronary arteries.

References

1. Previtali M, Ardissino D, Barberis P, Panciroli C, Chimienti M, Salerno JA. Hyperventilation and ergonovine tests in Prinzmetal's variant angina pectoris in men. Am J Cardiol 1989;63:17–20.
2. Water DD, Szlachcic J, Bonan R, Miller DD, Dauwe F, Theroux P. Comparative sensitivity of exercise, cold pressor and ergonovine testing in provoking attacks of variant angina in patients with active disease. Circulation 1983;67:310–5.
3. Water DD, Szlachcic J, Bourassa MG, School JM, Theroux P. Exercise testing in patients with variant angina: results, correlation with clinical and angiographic features and prognostic significance. Circulation 1982;65:265–74.
4. Mortensen SA, Vilhelmsen R, Sandoe E. Non-pharmacological provocation of coronary vasospasm: experience with prolonged hyperventilation in the coronary care unit. Eur Heart J 1983;4:391–7.
5. Rasmussen K, Bagger JP, Bottzauw J, Henningsen P. Prevalence of vasospastic ischemia induced by the cold pressor test or hyperventilation in patients with severe angina. Eur Heart J 1984;5:354–61.
6. Kaski JC, Crea F, Meran D, et al. Local coronary supersensitivity to diverse vasoconstrictive stimuli in patients with variant angina. Circulation 1986;74:1255–65.
7. Sakata K, Yoshida H, Sugino H, et al. Assessment of quantitative exercise thallium-201 emission computed tomography in patients with vasospastic angina: value of washout rate analysis. Jpn Circ J 1994;58:379–88.
8. Koyanagi S, Sakai K, Irie T, Takeshita A, Nakamura M, Nakagaki O. Exercise-induced silent myocardial ischemia in patients with vasospastic angina. Am Heart J 1990;119:551–6.
9. Imamura T, Nagatomo Y, Nakagawa S, Koiwaya Y, Hoshi H, Watanabe K. Hyperventilation thallium-201 myocardial imaging for the diagnosis of vasospastic angina. Clin Nucl Med 1987;12:729–34.
10. Takano H, Nakamura T, Satou T, et al. Regional myocardial sympathetic dysinnervation in patients with coronary vasospasm. Am J Cardiol 1995;75:324–9.
11. Sakata K, Yoshida H, Hoshino T, Kurata C. Sympathetic nerve activity in the spasm-induced coronary artery region is associated with disease activity of vasospastic angina. J Am Coll Cardiol 1996;28:460–4.
12. Sakata K, Miura F, Sugino H, et al. Assessment of regional sympathetic nerve activity in vasospastic angina: analysis of 123-I metaiodobenzylguanidine (123-I-MIBG) scintigraphy. Am Heart J 1997;133:484–9.
13. Tsuchimochi S, Tamaki N, Tadamura E, et al. Age and gender difference in normal myocardial adrenergic neuronal function evaluated by iodine-123-MIBG imaging. J Nucl Med 1995;36:969–74.
14. Gill JS, Hunter JG, Gane J, Ward DE, Camm AJ. Asymmetry of cardiac (^{123}I) metaiodobenzylguanidine scans in patients with ventricular tachycardia and a clinically normal heart. Br Heart J 1993;69:6–13.
15. Kline RC, Swanson DP, Wieland DM, et al. Myocardial imaging in man with I-123 meta-iodobenzylguanidine. J Nucl Med 1981;22:129–32.
16. Sisson JC, Shapiro B, Meyers LJ, et al. Metaiodobenzylguanidine to map scintigraphically the adrenergic nervous system in man. J Nucl Med 1987;28:1625–36.
17. DePasquale EE, Nody AC, DePuey EG, et al. Quantitative rotational thallium-201 tomography for identifying and localizing coronary artery disease. Circulation 1988;77:316–27.
18. Wichter T, Hindricks G, Lerch H, et al. Regional myocardial sympathetic dysinnervation in arrhythmogenic right ventricular cardiomyopathy: an analysis using 123-I-meta-iodobenzylguanidine scintigraphy. Circulation 1994;89:667–83.
19. Stanton MS, Tuli MM, Radtke NL, et al. Regional sympathetic denervation after myocardial infarction in humans detected noninvasively using I-123-meta-iodobenzylguanidine. J Am Coll Cardiol 1989;14:1519–26.
20. Dae MW, Herre JM, OConnell W, Botvinick EH, Newman D, Munoz L. Scintigraphic assessment of sympathetic innervation after transmural versus nontransmural myocardial infarction. J Am Coll Cardiol 1991;17:1416–26.
21. Imamura Y. Ando H, Itsuoka W, et al. Iodine-123 metaiodobenzylguanidine images reflect intense myocardial adrenergic activity in congestive heart failure independent of underlying cause. J Am Coll Cardiol 1995;26:1594–9.
22. Ganguly PK, Beamish RE, Dhalla KS, Innes LA, Dhalla NS. Norepinephrine storage, distribution, and release in diabetic cardiomyopathy. Am J Physiol 1987;252:E734–9.
23. Yasue H, Horio Y, Nakamura N, et al. Induction of coronary artery spasm by acetylcholine in patients with variant angina: possible role of the parasympathetic nervous system in the pathogenesis of coronary artery spasm. Circulation 1986;74:955–63.
24. Yoshio H, Shimizu M, Sugihara N, et al. Assessment of autonomic nervous activity by heart rate spectral analysis in patients with variant angina. Am Heart J 1993;125:324–9.
25. Holmgren S, Abrahamsson T, Almgren O, Eriksson B-M. Effect of ischaemia on the adrenergic neurons of the rat heart: a fluorescence histochemical and biochemical study. Cardiovasc Res 1981;15:680–9.
26. Passens R, Borchard F. Morphology of cardiac nerves in experimental infarction of rat hearts. Virchows Arch A Pathol Anat Histopathol 1980;386:265–78.
27. Tsutsui H, Ando S, Fukai T, et al. Detection of angina-provoking coronary stenosis by resting iodine 123 metaiodobenzylguanidine scintigraphy in patients with unstable angina pectoris. Am Heart J 1995;129:708–15.