

Head and neck oncology – 2010, part I

Nowotwory głowy i szyi – 2010, część I

Eugene N. Myers, MD, FACS, FRCS Edin (Hon)

SUMMARY

This article reviewed the current state of the art in head and neck oncology. These include very important and stimulating new areas of interest including the marked acceptance of chemoradiation in favor of surgery in patients with cancer of the head and neck. The concept of HPV as a cause of cancer of the oropharynx is relatively new and very important in the epidemiology of these tumors. New modalities such as PET CT scanning and robotic surgery are discussed and appear to be very important in management of cancer of the head and neck. Endoscopic endonasal skull base surgery is another new high technology contribution to the field of head and neck surgery as is the use of endoscopic assisted thyroid surgery. These and other new concepts are discussed in this manuscript.

Key words: PET CT scanning, robotic surgery, endoscopic endonasal skull base surgery, endoscopic assisted thyroidectomy, nonsurgical treatment of cancer of the head and neck, microvascular free tissue transfer, selective neck dissection, sentinel node biopsy

©by Polskie Towarzystwo Otolaryngologów – Chirurgów Głowy i Szyi

To jest Open Access artykuł pod CC BY-NC-ND licencją

Otrzymano/Received:

02.04.2010

Zaakceptowano do druku/Accepted:

14.04.2010

UPP Department of Otolaryngology,
University of Pittsburgh Medical Center,
Eye and Ear Institute, Pittsburgh, PA

Wkład pracy autorów/Authors contribution:
xxxxxx

Konflikt interesu/Conflicts of interest:

Autorzy pracy nie zgłaszają konfliktu interesów.

Adres do korespondencji/

Address for correspondence:

imię i nazwisko: Eugene N. Myers, MD, FACS,

FRCS Edin (Hon)

adres pocztowy:

Distinguished Professor and Emeritus Chair

UPP Department of Otolaryngology

University of Pittsburgh Medical Center

Eye and Ear Institute; Suite 519

200 Lothrop Street

Pittsburgh, PA 15213

tel. 412-647-2111

fax 412-647-2080

e-mail myersen@upmc.edu

Otolaryngol Pol 2010;
64 (3): 136-146

Introduction

Squamous cell carcinoma is the most common cancer arising in the head and neck and affects more than 500,000 patients each year world wide. It has been thought that these cancers arise in the mucosa after exposure to carcinogens such as tobacco and alcohol. Recently, however, the human papilloma virus (HPV) has been strongly implicated as a causative agent particularly in cancer of the oropharynx. The complex regional anatomy and vital physiological role of the structures involved dictate that the goals of treatment are not only to attempt to cure the cancer, but also to preserve function. A multidisciplinary approach is important in treating these patients given the complexity of treatment and acute and long term complications that result from chemotherapy, radiation therapy and surgery. Appropriate clinical and radiographic staging is crucial for accurate treatment planning and delivery [1].

The pendulum has swung away from primary surgery to chemoradiation with surgery left for the salvage of therapeutic failures. The development of PET CT scanning has proven invaluable, both for initial precise staging of the cancer and follow up after chemoradiation. Molecular targeting agents, particularly epidermal growth factor inhibitors, have been successfully integrated into potentially curative treatment of locally advanced squamous cell carcinoma of the head and neck [2].

Recently, major improvements in technology including microvascular reconstruction, technical advances in radiation therapy delivery, such as IMRT and cyber knife, transoral laser therapy for cancer of the base of the tongue and larynx, and robotic surgery for cancer of the oropharynx and larynx have lead to improvement in patient care.

HPV has been shown to cause virtually all cancers of the female cervix. Molecular evidence also suggests a role for HPV particularly HPV 16 in the pathogenesis of a subgroup of squamous cell carcinomas in the head and neck. HPV DNA was detected in 72% of 100 oropharynx tumor specimens and 64% of the patients in the study were sero-positive for HPV 16 E6, HPV16 E7 or both [3]. Furthermore, exposure to HPV increased the association with cancer of the oropharyngeal regardless of the use of tobacco or alcohol and without evidence of synergy between exposure to HPV and the use of tobacco and alcohol. These data suggest that two distinct pathways may be involved in the development of cancer of the oropharynx. One may be driven by tobacco and alcohol and the other by HPV induced genetic instability.

Among young patients, widespread use of oral sexual practices and a trend towards multiple sexual partners may be contributing to an increased incidence of HPV related head and neck cancer particularly

those in the tonsil and base of the tongue. In fact, in Stockholm a recent report disclosed that between 1970 and 2002 there was a threefold parallel increase in the incidence of squamous cell carcinoma of the oropharynx and the proportion of HPV positive squamous cell carcinoma. The authors stated that "the incidence of HPV positive tonsil cancer is still increasing in the county of Stockholm suggesting an epidemic of virus induced cancer with soon almost all tonsil cancer being HPV positive, as in cervical cancer [4]. Since HPV vaccination is an important strategy to prevent cervical cancer, so it would seem logical that HPV vaccination trials may be tested as a potential means of preventing HPV induced cancer of the head and neck.

Advances in treatment strategies have affected all the approaches used in head and neck cancer: radiation therapy, chemotherapy, and targeted agents: radiation therapy is now the mainstay of curative therapy for oropharyngeal cancer and advanced hypopharyngeal and laryngeal cancer. Recent advances have focused primarily on variations in fractionation schedule and intensity modulated radiation therapy (IMRT) a form of high precision conformal radiotherapy that delivers radiation more precisely to the tumor while relatively sparing the surrounding normal tissue in particular the salivary glands to try to prevent xerostomia. In our Department and others, the cyberknife has come into common practice for use in patients with recurrent cancer in the head and neck.

Chemotherapy is an integral part of treating locally advanced head and neck cancer. It may be administered either before radiotherapy as induction (neoadjuvant) therapy or concurrently with radiotherapy. Postoperative adjunctive chemoradiation continues to play an important role in treating locally advanced, but operable, cancer of the head and neck [5, 6].

Targeting agents such as Cetuximab appear to have promise both in combination with chemo/radiotherapy as primary treatment, or as single agents in patients with recurrent or metastatic cancer [7, 8].

Nonsurgical treatment

Concurrent chemotherapy has a long record of improving local and regional control in squamous cell carcinoma of the head and neck, however, its effect on distant metastases is controversial. Conversely induction chemotherapy appears to reduce distant metastases. Induction chemotherapy may be ideally used in patients with good performance status and advanced primary and nodal presentations, such as T3, T4, and N2A or N3. It is also reasonable to offer induction chemotherapy to symptomatic patients in need of immediate therapy.

Many retrospective analyses have shown poor outcome for patients with squamous cell carcinoma of the

head and neck which express high levels of EGFR. Targeting this receptor with a monoclonal antibody has been successfully exploited for therapeutic purposes, an example of which previously mentioned is cetuximab. Cetuximab is a monoclonal antibody approved by the FDA for treating cancer of the head and neck. Its use as a single agent in patients with platinum resistant cancer has been approved for use in combination with radiation in previously untreated patients. Bonner et al [7], in a recent Phase III trial, demonstrated that cetuximab in combination with radiotherapy improved local regional control and progression free and overall survival in locally advanced cancer. Treatment with a combination regimen decreased the risk of local regional progression by 32% and the risk of death by 26%. However, the rates of distant metastasis in one and two years were similar in the two study groups. Cetuximab has also been tested as a single agent in 103 patients with recurrent or metastatic head and neck cancer resistant to platinum based therapy. The response rate was 13% and the rate of cancer control was 46% [8].

Angiogenesis is also fundamental to cancer growth and metastasis and is regulated by many endogenous pro-angiogenic and anti-angiogenic factors, the most important being the vascular endothelial growth factor (VEGF) and its receptors [9]. VEGF can be upregulated and has prognostic significance in squamous cell carcinoma of the head and neck. Anti-angiogenesis therapeutic strategies have been extensively studied in other solid tumors and are currently being evaluated in the treatment of squamous cell carcinoma of the head and neck.

Definitive chemoradiation for cancer of the oropharynx, larynx, and hypopharynx has replaced surgery in many cases. A meta-analysis involving patients with head and neck cancer showed an absolute benefit of 8% associated with concurrent chemoradiation compared to radiation therapy alone [10]. Unfortunately the side effects of many of the chemotherapy approaches include neuropathy, hearing loss, marked nausea and vomiting, renal dysfunction and long term sequela such as dysphagia.

Postoperative concurrent chemoradiation has been tested in two Phase III studies conducted by the Radiation Therapy Oncology Group (RTOG) [5] and the European Organization for Research and Treatment of Cancer (EORTC) [6]. Both trials aimed to determine whether the addition of cisplatin to radiotherapy improved the outcome as compared with radiotherapy alone. In both studies, patients with high risk pathological features after surgery were randomly assigned to receive either radiotherapy alone or radiotherapy plus cisplatin. High risk features were defined as the presence of positive margins, extracapsular spread, lymphovascular invasion, perineural invasion, and

multiple positive lymph nodes. In the RTOG study concurrent chemotherapy significantly reduced the risk of local regional recurrence compared with radiation therapy alone, but, unfortunately no benefit in survival was noted. In the EORTC study, both progression free survival and overall survival rates were significantly better in patients receiving concurrent chemoradiation. Both trials demonstrated that adding cisplatin had no significant effect on the incidence of distant metastasis. Although postoperative concurrent chemotherapy was more effective than radiotherapy alone, it was also more toxic.

Long term sequel of these nonsurgical treatments include: dysphagia, osteo-radionecrosis, dental caries, trismus, thyroid dysfunction, sensorineural hearing loss, myelitis and pharyngeal or esophageal stenosis. Radiation induced xerostomia is a universal problem for long-term survivors. Unfortunately there is no radioprotectant with proven efficacy available in decreasing the severity of mucositis during chemoradiation therapy for squamous cell carcinoma.

Larynx

Several interesting trends have arisen in the treatment of laryngeal cancer since the landmark study conducted by the Veterans Affairs Laryngeal Cancer Study Group in 1991. That study concluded that induction chemotherapy followed by radiation therapy for complete responders gave the same results as total laryngectomy followed by radiation therapy, but the chemoradiation survivors retained their larynx. This has evolved into treatment with concurrent chemoradiation (CR) based on the results of the Radiation Therapy Oncology Group (RTOG) trial 91-11 which showed improved local control rates. These clinical trials have impacted practice patterns as reflected in the National Cancer Database by an increase in the use of chemoradiation in both community hospitals and academic centers [11].

Paradoxically during this same time period, survival amongst patients with laryngeal cancer had decreased according to the National Cancer Data Base (NCDB) [12]. The decreased survival parallels the observed trend of increasing use of nonoperative treatment in patients with laryngeal cancer. In contrast to results of the VA study an analysis of NCDB records of patients with laryngeal cancer found an increased risk of death for stage IV patients treated with chemoradiation [13] suggesting that there may be differences in patient populations and the application of treatment between the clinical trial setting and the larger community was analyzed.

A total of 451 patients at the Medical College of Georgia who underwent primary surgical therapy including cordectomy and partial horizontal laryngectomy and total or extended total laryngectomy were included in this study with a mean follow up time

of 35 months [14]. The authors demonstrated that nonoperative treatments were associated with poorer survival for patients with Stage IV cancer of the larynx and particularly a subset of patients with T4 cancer. T4 lesions are defined as tumors that invade through the thyroid cartilage or invade soft tissues beyond the larynx. Nodal status was associated with an increased risk of disease specific mortality in Stage IV disease. Only treatment was significant in the analysis of T4 patients suggesting that T4 status may be the single most important predictor of survival differences between surgical and nonoperative treatment for patients with Stage IV laryngeal cancer. These data suggest that the observed national decrease in survival for laryngeal cancer may be due to the shift toward nonoperative treatment in the subset of patients with advanced laryngeal cancer.

Early laryngeal cancer can be effectively treated either by larynx preserving surgery or with external beam radiation therapy or chemoradiation. Results in terms of tumor control and preservation of function for both modalities are satisfactory with reported rates of recurrence or persistence of tumor varying from 10 to 35% [15]. However, if there is local recurrence after radiation therapy then surgery is mandatory and total laryngectomy remains the most frequently used technique for achieving local control. However, in selected cases, partial surgery with an attempt to preserve laryngeal function can be considered.

Recent reports in the literature indicate that supracricoid partial laryngectomy (SPL) is a valid alternative to total laryngectomy in selected cases of radiation failure. It can be a safe option oncologically and at the same time a valuable solution for retention of the all important functions of speaking and swallowing. The authors [15] describe a series of 31 patients who had failed treatment with radiation who were treated with SPL over a 20 year period. Historically, a total laryngectomy for salvage in cases of early laryngeal cancer failing radiation therapy achieves local control in 78 to 85% of T1 (preoperative staging) and 65% of T2 (preradiotherapy staging). Oncologic results with salvage SPL of 75% indicated that this operation is a serious alternative to total laryngectomy in carefully selected cases of radiation failure.

Endoscopic horizontal partial laryngectomy, using a CO₂ laser, is another conservation technique which has been found useful in the treatment of early cancer. Bussu et al [16] studied a series of 144 patients who underwent laser supraglottic partial laryngectomy as primary treatment for supraglottic squamous cell carcinoma. The authors state that a horizontal supraglottic laryngectomy is the mainstay of surgical management of the primary tumor for T1, T2 and selected T3 cancers of the supraglottic area producing good local control while allowing the patient to retain their voice. Unless

nodes are positive, Stage I and Stage II lesions could be treated by surgery as a single modality with a low rate of complications and good functionality saving radiation therapy for possible recurrence or a second primary tumor which occurs not infrequently. They cite the importance of neck dissection in the overall management of these patients. The authors did not find a significant difference between the oncologic endpoints of the external and the endoscopic approach. Following treatment of the primary, a selective neck dissection levels II, III and IV was carried out. The authors had a few recurrences in both the endoscopic group and the external horizontal laryngectomy group. They were able to perform a total laryngectomy successfully for salvage.

Chen et al [17] studied the impact of the treating facilities volume of cases on survival for early stage laryngeal cancer to evaluate the relationship between total treatment volume of patients and survival in the first five years after treatment. Their analysis demonstrated that for patients with early stage laryngeal cancer several factors are associated with survival including: type of treatment, volume of cases in the treating facility, and the patients' insurance status. The report disclosed that patients with early stage laryngeal cancer treated initially with surgery had substantially better survival than those treated with radiation.

This is the first study to report poor survival for patients treated with radiation as compared with surgery and raises questions about the evidence base for including radiation and surgery as equally effective in treating early stage laryngeal cancer. The conclusion is based on 11,446 cases of early stage laryngeal cancer. The authors suggest that radiation treatment (vs. surgery) and treatment at low volume (vs. high volume) facilities are both associated with poor survival. They do not know whether the apparent lower survival in low volume facilities reflects understaging the primary laryngeal cancer, patient selection factors, or poor quality of care. Patients who are uninsured or had Medicare, Medicaid or other types of government insurance had lower survival rates compared with those patients who had private insurance. It is most likely attributable to difficulties in access to primary specialty care amongst patients with no or inadequate insurance.

Chen et al [18] found that black patients with laryngeal cancer had a decreased likelihood of survival compared with whites even after controlling for clinical factors, insurance types and area socioeconomic characteristics. A recent Canadian study also reported differences in cost specific survival for patients with laryngeal cancer based on socioeconomic status [19].

Oropharynx

The epidemiology, diagnosis, and treatment of oropharyngeal cancers are in a state of transition. Although

there are new imaging and screening methodologies making earlier diagnosis more accurate as well as new treatment modalities the clinical challenges for both patient and surgeon/physician remain essentially unchanged. Although there has been improved local regional control, this may not translate into improved overall survival.

The vast majority of primary tumors of the oropharynx are squamous cell carcinoma and the recent literature suggests that many of these are associated with human papilloma virus (HPV), a situation which may be more amenable to curative treatment [20]. Approximately 5,000 new cases of cancer of the oropharynx diagnosed in the United States annually have in the past been closely correlated with tobacco and alcohol abuse. In Western Europe and the United States recent studies suggest that there is an increased incidence of these cancers in people less than 45 years of age. Studies have shown an increased relative risk for cancer of the oropharynx in patients with HPV seropositivity and HPV infection or both. This increased risk seems to be higher in younger populations and different patterns of sexual behaviors may partially account for this trend. Most HPV associated cancers originate in the tonsil for reasons not currently understood. Although HPV 16 and 18 are associated with cancer of the female genital tract, the vast majority of HPV associated head and neck cancers are associated with HPV 16 only. The role of HPV vaccination in the prevention of cervical cancer suggests itself in cancer of the head and neck.

The use of PET CT scanning appears to enhance the detection of primary cancers and cervical metastasis in the oropharynx. This is important since many of these cancers present initially with a mass in the neck with no obvious primary site. PET CT is very helpful in identifying the primary cancer in the oropharynx in such cases so that these will no longer be considered metastatic to the neck from an "unknown primary cancer".

The paradigm has shifted in managing these patients and Cohan et al [20] recommend that all medically able patients with a biopsy proven cancer of the base of the tongue receive chemoradiation to their primary disease and the neck with neck dissection reserved for those patients that have initial N2 disease or greater.

In our Department following chemoradiation: 1. if the physical examination is normal, the patients are followed with PET CT scans rather than planned post treatment neck dissections. 2. Patients with cancer of the posterior pharyngeal wall are offered chemoradiation as a primary treatment modality reserving surgery for salvage therapy. 3. Early cancer of the soft palate is excised surgically. Patients with higher stage tumors will be offered adjuvant radiation therapy encompassing

the primary site and the retropharyngeal lymph nodes. 4. The treatment of tonsil cancer remains a clinical treatment dilemma since there are no prospective randomized studies or site specific retrospective analyses that clearly indicate which is the superior approach to this locally and regionally aggressive disease. Cohan's patients are offered first-line therapy choices of chemoradiation with surgery for salvage or primary surgical resection with adjuvant chemoradiation.

Grant et al [21] reviewed a series of 206 patient with cancer of the oropharynx who underwent transoral laser microsurgery (TLM). They found that TLM alone with neck dissection is an effective approach for highly selected T1 to T3 N0 or N1 cancer of the oropharynx. In this series the TLM control of the disease at the primary site was 66/69 patients. Those patients with local recurrence were successfully salvaged with further TLM. The overall local control rate was 94%. This is comparable with local control rates for conventional surgery with or without adjuvant radiation therapy and for primary radiation therapy with or without neck dissection [22]. The primary neck dissection was found to be an effective approach for the N0 and N1 and select N2 neck. Thirty-five of their 44 patients in the series had neck dissections. The authors state that TLM has considerable advantage over radiation therapy or concurrent CRT including chemoradiation therapy, including lower morbidity, short duration of treatment, and patient acceptance. This technique re-establishes the principle of primary surgery as it was in the open surgery era for acceptable local and regional disease control and to more accurately identify the requirement for adjuvant therapy.

Henstrom et al [23] reported a series of 141 patients who underwent surgical resection for primary cancer of the base of the tongue. They reviewed the outcome of 20 of these patients who underwent transoral resection with the use of the microscope and laser together with neck dissection with and without adjuvant therapy. Good results were based upon carefully assessing the site of neck metastasis, sampling the retropharyngeal nodes, dissecting both sides of the neck when there is palpable or radiographic suspected metastasis on the contralateral side and prescribing adjuvant therapy for a specific group of high risk patients. Maintaining function is one of the outcome measures in these patients. The authors attribute their high functionality rates to performing selective or modified neck dissection, thus preserving the spinal accessory and sensory nerves. The authors feel that the surgical techniques will continue to be improved and they believe that transoral resection will continue to be a superior option for patients with squamous cell carcinoma of the base of the tongue and it should be considered a real alternative to chemoradiation therapy for early primary cancer.

Cano et al [24] reported a series of 88 patients with carcinoma of the base of the tongue treated with concurrent chemoradiation (50Gy) followed by brachytherapy. They found that this is a safe and effective method of treating squamous cell carcinoma of the base of the tongue. This protocol focused on organ preservation given the role of the base of the tongue in speech and swallowing function. This was a paradigm shift in the management of patients with cancer of the oropharynx since prior to this study we used surgical resection with postoperative adjunctive radiation therapy. Brachytherapy given both to the base of the tongue and to the neck for those patients who were node positive proved to be an effective method of directly boosting dose intensity to a particular target. The neck was treated with brachytherapy (25Gy) if it was cN+ at initial presentation. We found this approach to be extremely effective in controlling metastasis to the cervical lymph nodes and a neck dissection was performed only if there was residual disease following brachytherapy or if regional metastasis recurred. Following chemoradiation and brachytherapy, only 6 patients (6.8%) had a persistent or recurrent mass in the neck that was palpable or discovered on PET CT scanning. Neck dissection was performed in those patients and four specimens were found positive for tumor. Five of the six patients remain disease free.

We have adopted the use of PET CT scan to monitor for local regional control following definitive chemoradiation therapy. Our Department as well as others in the literature, have reported that a neck dissection can be deferred when clinical examination and PET scan findings are negative. The use of combined chemoradiation with brachytherapy has lead to a high rate of local regional control with a low rate of short term or long term complications. The control rate was nearly 80%, and our 5 to 7% rate of complications seems acceptable but demonstrates the technical expertise necessary in the placement of brachytherapy catheters. The substitution of brachytherapy catheters for external beam radiation appears to decrease the severity of xerostomia, trismus and osteoradionecrosis providing improvement in the quality of life for these patients.

Cancer of the nasopharynx (NPC)

Chevalier Jackson in 1901 published an article entitled "Primary Carcinoma of the Nasopharynx: Table of Cases" [25]. This created an awareness of this cancer in the United States for the first time. This tumor has a geographic prevalence in the Southeastern China province of Guangdong therefore being known as the "Chinese tumor", but is also prevalent throughout Southeast Asia. The management of NPC was palliative in the early years before the introduction of radiation therapy. Curative treatment with long term survival

became possible only after the introduction of the linear accelerator in 1953. However, now with new types of imaging studies with more precise diagnosis, remarkable improvements in radiation therapy techniques and chemotherapy, the management of this disease has improved dramatically.

A randomized study with concurrent chemoradiation and adjunctive chemotherapy was carried out at the Dana Farber Cancer Center in Boston. This study indicated significant improvement in a three year progression free survival from 24% vs. 69% and an overall survival of 47% vs. 78% compared with radiation alone. This study employed three courses of concurrent cisplatin with radiotherapy followed by three courses of adjuvant chemotherapy using cisplatin and 5-FU. This trial has been considered a break-through in the use of chemotherapy for NPC [26].

Treatment of recurrent cancer in the nasopharynx is difficult but good results may be obtained using a variety of both standard and new techniques. Brachytherapy, which has been the standard treatment, delivers a high dose of radiation directly to the recurrent cancer which has the advantage of providing radiation at a continuous low-dose rate which may confer additional radiobiological effectiveness compared to fractionated external beam radiation. Yeo et al [27] studied a cohort of patients treated primarily with radiotherapy using supplemental intercalary brachytherapy to boost the total dose to the nasopharynx and enhance local control. Their center used a protocol from 1996 to 2000 that routinely used ICB (Interstitial Intercalary Brachytherapy) to achieve the ICB boost for all T1/T2 tumors treated with curative intent. The authors state that ICB is an effective and well tolerated procedure and is more economical than IMRT.

Kim et al [28] suggest that intensely modulated radiation therapy (IMRT) with simultaneous integrated boost (SIB) technique following neoadjuvant chemotherapy for locally advanced nasopharyngeal carcinoma was feasible and effective for achieving local regional control in advanced cancers. The incorporation of neoadjuvant chemotherapy enables reduction in gross tumor volume. Using this approach it may be possible to reduce the dose to the normal structures and reduce radiation therapy related toxicity such as xerostomia without compromising treatment outcome.

The use of surgical techniques to remove recurrent cancer of the nasopharynx have been well described and include splitting the soft palate followed by surgical resection. The problem with this technique was lack of good exposure. Dr. William Wei of Hong Kong [29] introduced the technique of open nasopharyngectomy using an osteotomy of the maxilla, allowing the maxilla to be displaced laterally while attached to a cheek flap which provided excellent exposure and after the resection of the recurrent tumor, the osteotomies were plated

and the flap was sewn back in place. This resulted in a good five-year survival and excellent cosmetic results. Between February of '89 and September '99, the maxillary swing nasopharyngectomy was employed by Dr. Wei as a surgical salvage procedure for 71 patients with recurrent or persistent primary NPC. In fifty-four patients resection resulted in a five-year actuarial local tumor control of 62% and a five-year actuarial survival of 49%. There is a great interest in treating recurrent local disease because otherwise, it always leads to the death of the patient.

Ko and his colleagues [30] use the endoscopic KTP laser pharyngectomy which they state is a safe and simple procedure in treating T1 NPC. The technique included using a zero or 30° angle endoscope with the laser to get a clear resection margin down to and sometimes into the prevertebral muscles depending on the extent of tumor infiltration. There were few postoperative problems in this series of patients. Five patients underwent endoscopic nasopharyngectomy. The two-year local disease free rate for T1 tumor was 100% and the two-year overall survival rate was 41.7%. The authors concluded that the endoscopic pharyngectomy with KTP laser is a simple, safe, and successful procedure for treatment of recurrent T1 NPC.

Tan et al [31] reported that Photo Dynamic Therapy (PDT) has the potential to be a very effective local treatment modality for NPC without the severe side effects seen with radiation therapy. Clinical trials with either HpD or Photofrin has shown that PDT is effective in destroying NPC with good local control and a complete response in the majority of small recurrent or persistent cancers (T1-2). Long term palliation in advanced stage (T3, T4) recurrence was also noted. Although these results were encouraging, PDT for NPC has not been considered as a breakthrough. It is felt that three issues are responsible for this fact:

1. Reliable and reproducible light exposure has not been achieved since it is almost impossible to illuminate the whole tumor area with a lens fiber guided with an endoscope.
2. The wave length of light used in these studies to activate HPD or Photofrin which are photosensitizers limits the depth of necrosis.
3. The prolonged skin photosensitivity seen with these sensitizers which may last for 1-2 months restricts the patients in their daily life.

FOSCAN, the second generation of photosensitizer approved in Europe for treatment of advanced cancer of the head and neck has the potential to be an efficient drug to treat NPC. Since the complex shape of the nasopharynx makes it impossible to produce a homogenous field of illumination, a new nasopharyngeal light applicator has been designed by the investigators. The applicator is introduced into the nasopharynx transorally attached to two guidance tubes inserted through the

nose and secured with a small silicone flange at the level of the nostrils. In a feasibility study conducted in Indonesia, the preliminary data for FOSCAN PDT in the nasopharynx are very promising. Eighteen (18) patients with recurrent or persistent NPC were treated in the study and only two recurrences were noted. One great advantage of the FOSCAN-PDT in NPC is the simplicity of the procedure and that it can be performed under local anesthesia. Another advantage is that it can be used for treatment of previously irradiated areas without the risk of excessive toxicity in normal tissue. Although PDT is a local treatment, this modality could be considered as part of the primary treatment for NPC. The authors feel that as a result of this study in Indonesia that the use of a single agent such as PDT in NPC with a N0 neck is a realistic alternative to radiation therapy. This could reduce the treatment time of six weeks of daily fractionated radiation therapy for a few days of PDT treatment.

Sentinel node biopsy

Sentinel node lymph node biopsy (SLNB) is a minimally to moderately invasive technique which allows the surgeon to identify, excise and meticulously examine the primary draining lymph nodes in a clinically N0 neck [32]. The use of SLNB in melanoma of the extremities and breast cancer is well established, however, it is still considered investigational for squamous cell carcinoma of the mucosal surface of the head and neck or for cutaneous squamous cell carcinoma or melanoma of the head and neck. Multiple centers in Europe have adopted SLNB as a standard additional approach to the neck for early clinically accessible mucosal squamous cell carcinoma. It provides accurate information and identifies those patients who may benefit from additional treatment to the cervical lymphatics.

Civantos et al [32] reported on the clinical utility of SLNB of the head and neck in their own experience. An institutional validation study was recently completed which included 25 institutions and 34 certified surgeons under the general supervision of the American College of Surgeons Oncology Group. A total of 137 evaluable patients were studied. As a result of this analysis, the authors concluded that multiple issues remain to be resolved before SLNB can be advocated as a reasonable alternative to selective neck dissection for the majority of early oral cancers.

There is still significant true morbidity associated in selective neck dissection so that the use of SLNB, if validated, would be an intermediate option between observation alone and selective neck dissection. One problem is the inability to achieve immediate diagnosis of positive sentinel nodes because frozen section technique, even with multiple sections, is not sufficiently accurate [33]. Rapid reverse transcriptase polymerase

chain reaction assessment of lymph nodes may provide immediate information regarding the status of the sentinel node [34]. This seems to be a promising technique to provide immediate diagnosis with much greater accuracy as compared with frozen section. The authors conclude that SLNB can be used safely and with technical success for accessible squamous cell carcinomas of the head and neck. It offers the potential for more anatomically accurate surgery based on each patient's unique lymphatic drainage system. However, without completion of the selective neck dissection, there may be up to 5% chance of missing cancer in this group of potentially curable patients.

Neck dissection

Neck dissection is one of the most commonly performed operations in head and neck surgery. Better understanding of the structure and pattern of lymphatic flow in the neck has transformed this operation into a more selective and less morbid treatment. Givi and Andersen [35] in an excellent article entitled "Rational for Modifying Neck Dissection" begin by stating that neck dissection is one of the "most time honored operations in the field of head and neck surgery." The evolution of this operation follows the evolution of cancer treatment from the first published articles in the middle of the 19th Century [36]. The radical neck dissection included removal of most of the structures of the neck, including the spinal accessory nerve, and although the radical neck dissection was an effective oncologic procedure, it carried with it substantial morbidity which led later surgeons to search for operations that were the oncologic equivalent, but less morbid. Suarez [37] was a pioneer in functional neck dissection which preserved the nonlymphatic structures of the neck normally removed during a radical neck dissection.

Radical neck dissection is defined as the removal of all ipsilateral cervical lymph node groups extending from the inferior border of the mandible to the clavicle and from the midline to the anterior border of the trapezius muscle and included the spinal accessory nerve, internal jugular vein and sternocleidomastoid muscle. Modified radical neck dissection refers to the excision of all lymph nodes routinely removed by radical neck dissection with preservation of one or more nonlymphatic structures, such as: the spinal accessory nerve, internal jugular vein, and sternocleidomastoid muscle. Selective neck dissection refers to a cervical lymphadenectomy in which one or more of the lymph node groups are removed with the other structures in the neck are preserved. The lymph node groups that are removed are based on the pattern of metastasis which is predictable relative to the primary site of the disease.

Neck dissection is performed in several distinct settings:

- At the time of surgical treatment of a primary tumor without any evidence of neck metastasis (No).
- As a therapeutic modality for positive cervical lymph nodes with or without adjuvant chemotherapy (N+).
- Planned neck dissection after primary chemoradiation.
- As an adjunct or salvage therapy after recurrence or failure of primary chemoradiation.

In performing selective neck dissection (SND) in the NO neck one must consider which patient will benefit in terms of regional control and whether there is a survival benefit associated with the procedure. There are three randomized studies on this subject and only one which showed improved survival. Andersen [38] states that it might be "assumed that if the neck is closely observed instead of operated that any metastatic disease that occurs will be detected in an early stage. However, this study proved this assumption incorrect and reported a series of 47 patients who failed in the neck during the observation period. In these patients, 60% were pathologically N2 or greater and extracapsular spread was present in 50% when the failure was detected. This paper is widely cited as an argument for elective neck dissection.

The most recent step was to extend the concept of SND to the clinically node positive neck. This remains somewhat controversial, but many series, particularly Byers [39] whose series consisted of 967 patients, show that SND in early stage metastatic cancer will provide results comparable to modified neck dissection if followed by adjuvant radiation therapy.

Andersen et al [40] published results of a multi-institutional study which showed that in a carefully selected group of patients it is possible to achieve good results with SND in the N2 neck. Their regional control rate was 94.3% in their cohort of 106 previously untreated patients. Andersen concludes that there is an expanded role for SND in the treatment of the node positive neck.

One of the most highly debated topics in recent years has been the role of neck dissection following definitive chemoradiation. There are two situations in which neck dissection is being used. The first is the planned neck dissection for patients with N2-N3 following chemoradiation without any evidence of persistent or recurrent cervical metastasis. The second situation is in the presence of cervical metastasis, residual or recurrent following definitive chemoradiation. Decision making in this situation has been helped tremendously by the use of PET CT scanning. This modality has shown a high sensitivity and high negative predictive value. Currently it seems that it is most helpful to patients who are PET negative. In this setting patients' who have evidence of cancer of the neck on physical examination and are PET negative,

are now followed with serial physical examination and PET CT scanning and it has been concluded that in the face of complete response and negative PET scan no neck dissection need be done [40]. If there is evidence of metastasis after chemoradiation either on physical examination or PET scanning then neck dissection may be indicated.

A report from Veldre et al [41] of the GETTEC group raises a question about the need for neck dissection following definitive chemoradiation. The study had a total of 103 patients with unresectable cancer of the head and neck, cervical metastasis and no distant metastasis who were treated between 1996 and 2002. After a CT scan with/without cervical ultrasound or PET CT demonstrated complete disappearance of neck nodes three months after completion of chemoradiation, no neck dissections were necessary. Based on their five year observations the authors concluded that careful followup of patients is becoming the most common attitude in France thereby replacing the planned neck dissection.

Lango et al [42] examined the medical records of 65 patients who had received chemoradiation with a median follow up of 33 months. The recurrence free survival of patients with a single positive node within a clinically involved nodal level approached that of patients with a complete pathological response. It had been their practice to perform a comprehensive neck dissection at levels 1 through 4 regardless of clinical response to nonsurgical treatment. In this study no patient classified as N1-2a who underwent a comprehensive neck dissection was found to have residual cancer and no patient failed in the neck. Other investigators have suggested that a limited or SND may be used to treat patients with N1-2A disease.

van der Putten et al [43], of the Netherlands Cancer Center and the University Medical Center, studied a series of 207 patients who were treated with intra-arterial chemoradiation. The schedule consisting of 4 consecutive weekly selective intra-arterial infusions of cisplatin was followed by intravenous sodium thiosulfate and simultaneous radiation therapy according to the RADPlat protocol. Following this treatment, all patients with persistent or recurrent lymph node metastasis and who were considered operable underwent a neck dissection. The median followup was 18 months with a range of 0 to 98 months. Based on the neck dissections that were carried out, the authors conclude because of the good regional control rate and the high rate of unnecessary neck dissections with the planned neck dissection strategy, that a careful watch and wait strategy is safe. Regarding overall survival, patients without recurrent disease seemed to benefit more from this strategy than patients with residual disease.

Mukhija et al [44] studied the issue of SND following adjuvant therapy for advanced cancer of the head

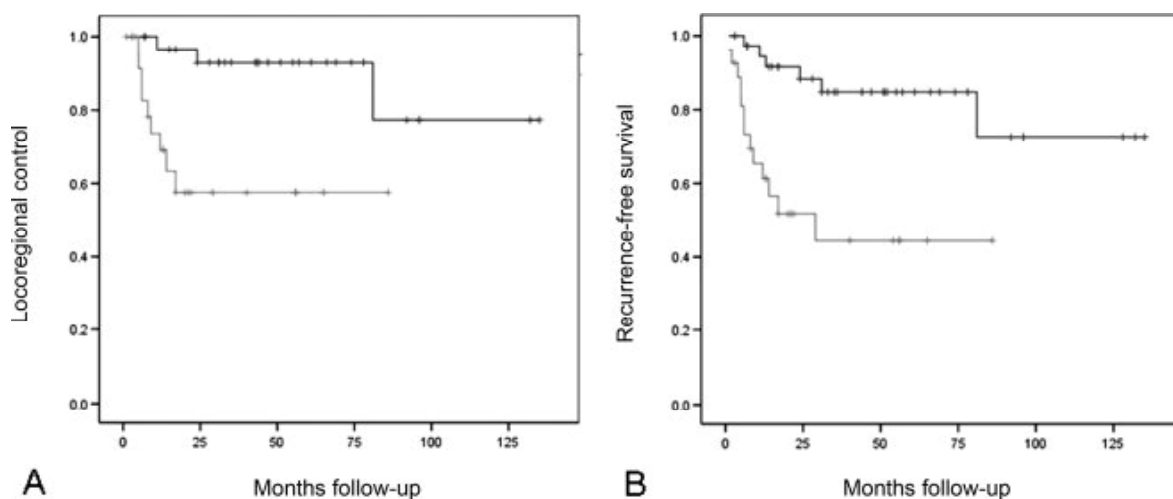


Fig. 1. (A) Locoregional control is diminished in patients with pathologic residual carcinoma in the neck, compared with those with negative specimens ($p = .002$). (B) Recurrence-free survival is diminished in patients with pathologic residual carcinoma compared with those with negative specimens ($p = .002$)

and neck. The authors state that in the past surgeons believed that in order to eradicate regional disease, a radical or modified radical neck dissection was necessary. An evolution in surgical principles and the popularization of primary chemoradiation has raised the question regarding the role and the extent of neck dissection following chemoradiotherapy. The aim of their study was to determine the efficacy of SND for patients with N2 or N3 following treatment with primary radiation or chemoradiation. They carried out a retrospective review of 58 patients with Stage III or Stage IV head and neck squamous cell carcinoma. They concluded that the rate of regional recurrence following SND is similar to rates reported following radical or modified neck dissection and suggested that SND provides an appropriate surgical option for advanced neck disease or selected patients following adjuvant therapy. They state that combined chemoradiation is often successful in eradicating low volume neck metastasis. However, the role of the neck dissection as a planned procedure for high volume disease in N2 and N3 has become controversial. The authors quote an article by Sewall et al [45] who examined the incidence of regional and distant control as well as overall survival of the patients treated with SND and compared these outcomes with patients who had undergone a comprehensive neck dissection. They found that the regional control, distant control and overall survival rate were not different with patients undergoing a SND or comprehensive neck dissection.

REFERENCES

- Haddad R, Shin D. Recent advances in head and neck cancer. *N Engl J Med* 2008; 359: 1143-54.
- Argiris A, Karamouzis M, Raben D, Ferris RL. Head and neck Cancer. *the Lancet* 2008; 371: 1695-708.
- d'Souza G, Kreimer A, Viscidi R, et al. E. Case-control study of human papillomavirus and oropharyngeal cancer. *N Engl J Med* 2007; 356: 1944-1956.
- Nasman A, Attner P, Hammarstedt L, Du J, Eriksson M, Giraud G, et al. Incidence of human papillomavirus (HPV) positive tonsillar carcinoma in Stockholm, Sweden: an epidemic of viral-induced carcinoma? *Int J Cancer* 2009; 125: 362-66.
- Cooper JS, Pajak TF, Forastiere AA, Jacobs J, Campbell BH, Saxman SB, et al. Postoperative concurrent radiotherapy and chemotherapy for high-risk squamous-cell carcinoma of the head and neck. *N Engl J Med* 2004; 350(19): 1937-44.
- Bernier J, Dommene C, Ozsahin M, Matuszewska K, Lefebvre JL, Greiner RH, et al. Postoperative irradiation with or without concomitant chemotherapy for locally advanced head and neck cancer. *N Engl J Med* 2004; 350(19): 1945-52.
- Bonner J, Harari P, Giralt J, et al. Radiotherapy plus cetuximab for squamous-cell carcinoma of the head and neck. *N Engl J Med* 2006; 354: 567-78.
- Vermorken J, Trigo J, Hitt R, et al. E. Open-label, uncontrolled, multicenter phase II study to evaluate the efficacy and toxicity of cetuximab as a single agent in patients with recurrent and/or metastatic squamous cell carcinoma of the head and neck who failed to respond to platinum-based therapy. *J Clin Oncol* 2007; 25: 2171-77.
- Ferrara N. VEGF as a therapeutic target in cancer. *Oncology* 2005; 69 (suppl 3): S11-S16.
- Pignon J, Bourhis J, Dommene C, Designe L. Chemotherapy added to locoregional treatment for head and neck squamous cell carcinoma: three meta-analyses of updated individual data. *Lancet* 2000; 355: 949-55.
- Gleich L, Li Y, Wang X, Stambrook P, Gluckman J. Variable genetic alterations and survival in head and neck cancer. *Arch Otolaryngol Head Neck Surg* 1999; 125: 949-52.

12. Hoffman H, Karnell L, Funk G, et al. E. The National Cancer Data Base report on cancer of the head and neck. *Arch Otolaryngol Head and Neck* 1998; 124: 951-62.
13. Chen A, Halpern H. Factors predictive of survival in advanced laryngeal cancer. *Arch Otolaryngol Head and Neck Surg* 2007; 133: 1270-76.
14. Gourin C, Conger B, Sheils W, Bilodeau P, Coleman T, Proubsky E. The effect of treatment on survival in patients with advanced laryngeal carcinoma. *Laryngoscope* 2009; 119(July): 1312-17.
15. Deganello A, Gallo O, DeCesare J, Benedetta Ninu M, Gitti G, de'Campora L, et al. Supracricoid partial laryngectomy as salvage surgery for radiation therapy failure. *Head and Neck* 2008; 30: 1064-71.
16. Bussu F, Almadori G, DeCorso E, Rizzo D, Rigante M, Parrilla C, et al. Endoscopic horizontal partial laryngectomy by CO₂ laser in the management of supraglottic squamous cell carcinoma. *Head and Neck* 2009; 31(9): 1196-206.
17. Chen A, Pavluck A, Halpern M, Ward E. Impact of treating facilities' volume on survival for early-stage laryngeal cancer. *Head and Neck* 2009; 31(9): 1137-43.
18. Chen AY, Schrag NM, Halpern M, Stewart A, Ward EM. Health insurance and stage at diagnosis of laryngeal cancer: does insurance type predict stage at diagnosis? *Arch Otolaryngol Head Neck Surg* 2007; 133(8): 784-90.
19. Groome P, Schulze K, S K, et al. Explaining socioeconomic status effects in laryngeal cancer. *Clin Oncol (R Coll Radiol)* 2006; 18: 283-92.
20. Cohan D, Popat S, Kaplan S, Rigual N, T L, Hicks W. Oropharyngeal cancer: current understanding and management. *Curr Opin Otolaryngol Head Neck Surg* 2009; 17(2): 88-94.
21. Grant D, Hini M, Salassa J, Perry W, Hayden R, Casler J. Oropharyngeal cancer: A case for single modality treatment with transoral laser microsurgery. *Arch Otolaryngol Head Neck Surg* 2009; 135(12): 1225-30.
22. Fein D, Lee W, Amos W, et al. Oropharyngeal carcinoma treated with radiotherapy: a 30 year experience. *Int J Radiat Oncol Biol Phys* 1996; 34(2): 289-96.
23. Henstrom D, Moore E, Olsen K, Kasperbauer J, McGree M. Transoral resection for squamous cell carcinoma of the base of the tongue. *Arch Otolaryngol Head Neck Surg* 2009; 135(12): 1231-38.
24. Cano E, Lai S, Caylakli F, Johnson J, Ferris R, Carrau R, et al. Management of squamous cell carcinoma of the base of the tongue with chemoradiation and brachytherapy. *Head and Neck* 2009; 31(11): 1431-38.
25. Jackson C. Primary carcinoma of the nasopharynx. A table of cases. *JAMA* 1901; 37: 371-77.
26. Al-Sarraf M, LeBlanc M, PG G, et al. Chemoradiotherapy versus radiotherapy in patients with advanced nasopharyngeal cancer: Phase III randomized Intergroup study 0099. *J Clin Oncol* 1998; 16: 1310-17.
27. Yeo R, Fong K, Hee S, Chua, ET, Tan T, Wee J. Brachytherapy boost for T1/T2 nasopharyngeal carcinoma. *Head and Neck* 2009; 31(12): 1610-18.
28. Kim K, Wu H-G, Kim H, Sung M-W, Kim K, Lee S-H, et al. Intensity-modulated radiation therapy with simultaneous integrated boost technique following neoadjuvant chemotherapy for locoregionally advanced nasopharyngeal carcinoma. *Head and Neck* 2009; 31(9): 1121-28.
29. Wei W, Sham J. Cancer of the nasopharynx. In: Myers E, Suen J, Myers J, Hanna E, eds. *Cancer of the Head and Neck*, ed. 4th edition Philadelphia, PA: Saunders/Elsevier, 2003: 229-50.
30. Ko J-Y, Wang C-P, Ting L-L, Yang T-L, Tan C-T. Endoscopic nasopharyngectomy with potassium-titanyl-phosphate (KTP) laser for early locally recurrent nasopharyngeal carcinoma. *Head and Neck* 2009; 31(9): 1309-15.
31. Tan I, Nyst H, Sterenborg J, Van Veen R, Levendag P, Robinson D, et al. Photodynamic therapy (PDT) in nasopharyngeal cancer. In: Biel M, ed. *Photodynamic therapy of diseases of the head and neck* San Diego: Plural Publishing, 2008: 81-92.
32. Civantos F, Zitsch R, Bared A, Amin A. Sentinel node biopsy for squamous cell carcinoma of the head and neck. *J Surg Oncol* 2008; 97(8): 683-90.
33. Tannis P, Boom R, Koops H, et al. E. Frozen section investigation of the sentinel node in malignant melanoma and breast cancer. *Ann Surg Oncol* 2001; 8: 222-26.
34. Chung C, Parker J, Yabrough W, et al. Molecular classification of head and neck squamous cell carcinoma using patterns of gene expression. *Cancer Cell* 2004; 5: 489-500.
35. Givi B, Andersen P. Rationale for modifying neck dissection. *J Surg Oncol* 2008; 97(8): 674-82.
36. Crile GW. On the surgical treatment of cancer of the head and neck. With a summary of one hundred and twenty-one operations performed upon one hundred and five patients. *Trans South Surg Gynecol Assoc* 1905; 18: 108-27.
37. Suarez O. El problema de las metastasis linfaticas y alejadas del cancer de laringe e hipofaringe. *Rev Otorrinolaringol* 1963; 23: 804-08.
38. Andersen P, Cambronero E, Shaha A, et al. E. The extent of neck disease after regional failure during observation of the NO neck. *Am J Surg* 1996; 172: 689-91.
39. Byers RM. Modified neck dissection. A study of 967 cases from 1970 to 1980. *Am J Surg* 1985; 150(4): 414-21.
40. Andersen PE, Warren F, Spiro J, Burningham A, Wong R, Wax MK, et al. Results of selective neck dissection in management of the node-positive neck. *Arch Otolaryngol Head Neck Surg* 2002; 128(10): 1180-4.
41. Vedrine P-O, Thariat J, Hitier M, Janot F, Kaminsky M-C, Makeieff M, et al. Need for neck dissection after radiochemotherapy? A study of the French GETTEC Group. *Laryngoscope* 2008; 118: 1775-80.
42. Lango M, Andrews G, Ahmad S, Feigenberg S, Tuluc M, Gaughan J, et al. Postradiotherapy neck dissection for head and neck squamous cell carcinoma: pattern of pathologic residual carcinoma and prognosis. *Head and Neck* 2009; 31: 328-37.
43. van der Putten L, van den Broek G, de Bree R, van den Brekel M, Balm A, Hoebbers F, et al. Effectiveness of sal-

- vage selective and modified radical neck dissection for regional pathologic lymphadenopathy after chemoradiation. *Head and Neck* 2009; 31(May): 593-603.
44. Mukhija V, Gupta S, Jacobson A, Anderson Eloy J, Genden E. Selective neck dissection following adjuvant therapy for advanced head and neck cancer. *Head and Neck* 2009; 31(February): 183-88.
45. Sewall G, Palazzi-Churas K, Richards G, Hartig G, Harari P. Planned postradiotherapy neck dissection: rational and clinical outcomes. *Laryngoscope* 2007; 117: 121-28.