




ELSEVIER

Contents lists available at [ScienceDirect](http://ScienceDirect.com)

Urology Case Reports

journal homepage: www.elsevier.com/locate/eucr

Andrology and Fertility

Giant Benign Prostatic Hyperplasia in a Pakistani Patient

Zafaruddin Khan^{a,*}, Muzamil Tahir^a, H. Shahzad Ashraf^a, FazaluRehman Khan Niazi^a, Munazza Khan^a, Sadaf Mustafa^b, Naseruddin Höti^c^a Department of Urology and Transplantation, Shaikh Zayed Hospital, Lahore, Pakistan^b Department of Internal Medicine, MedStar Union Memorial Hospital, MD, USA^c Brady Urological Institute, Johns Hopkins School of Medicine, Baltimore, MD, USA

ARTICLE INFO

Article history:

Received 2 November 2013

Received in revised form

9 November 2013

Accepted 19 November 2013

ABSTRACT

“Giant hyperplasia” of the prostate is a rare pathology of the prostate gland. We report one such case, in which a successful retropubic prostatectomy was performed on an elderly male patient in Pakistan. The weight of the resected prostate was 700 g, which is the eighth largest prostate with benign prostatic hyperplasia reported.

© 2014 The Authors. Published by Elsevier Inc. Open access under [CC BY-NC-ND license](http://creativecommons.org/licenses/by-nc-nd/4.0/).

Keywords:

Giant BPH

Prostatectomy

Prostate

Introduction

Benign prostatic hyperplasia (BPH) often produces chronic and progressive lower urinary tract symptoms or complications, making many men to seek surgical treatment. Prostatic enlargement because of BPH rarely exceeds 100 g, which occurs only in 4% of men older than 70 years.¹ Giant BPH is defined as a prostate weight over 200 or 500 g; the lower threshold was suggested by Japanese authors,² probably because BPH is rare in the East. The largest adenoma ever removed by suprapubic prostatectomy weighed approximately 820 g, but the patient died of hemorrhage.³ Giant BPH is extremely rare, with only 16 cases described earlier in the literature exceeding 500 g till 2013 (Table 1). In this study, we report a case of giant BPH (700 g), which was removed successfully by retropubic prostatectomy without intraoperative complications.

Case presentation

A 73-year-old man was hospitalized because of episodic hematuria and lower urinary tract symptoms (International Prostate Symptom Score 30). He had a history of multiple failed urethral catheterizations for urinary retention and had required suprapubic cystostomy in the past. Digital rectal examination showed a grossly enlarged prostate. The routine laboratory investigations were within normal limits other than total prostate-specific antigen, which was 53.3 ng/mL. The volume of the prostate was measured to be 350 mL by transrectal ultrasound. Retropubic prostatectomy was performed, and a large adenoma was entirely enucleated in 1 piece (Fig. 1A and B). Blood loss was minimal, and there were no intraoperative complications. The removed specimen was 18.2 × 19.4 cm in diameter and weighed 700 g. Pathologic examination revealed BPH with chronic inflammation. The postoperative recovery was complicated by a myocardial infarction, which was promptly treated in critical care unit, as part of the protocol, a Foley catheter was also placed. The catheter was removed after 3 weeks; the patient was able to void without difficulty. At 3 months follow-up, the patient did not have discomfort in voiding or urinary incontinence.

Discussion

BPH is a common problem experienced by aging men around the world that can lead to serious outcomes, including acute

* Corresponding author. Tel.: +92-3005746420.

E-mail address: zafaruddin.khan@hotmail.com (Z. Khan).

Table 1
Reported giant benign prostatic hyperplasia

Author	Weight (g)	Year	Journal Published
Medina Perez et al	2410	1997	Arch Esp Urol
Ockerblad	820	1946	Hinyokiko Kiyo
Üçer et al	734	2011	Dicle Medical Journal
Nelson	720	1940	Urol Cutan Rev
Gilbert	713	1939	Urol Cutan Rev
Wadstein	705	1938	JAMA
Lantzius-Beninga	705	1966	J Urol Nephrol
Ashamalla and Ahmed	695	1972	Arch Surg
Thomson-Walker	680	1920	Br J Surg
Yilmaz et al	610	2006	Int Urol Nephrol
Bacon	602	1949	J Urol
Middleton	557	1937	JAMA
Kitagawa	535	1980	Rinsho Hinyokika
Fishman and Merrill	526	1993	Urology
Akpo and Akpo	510	2010	The Inter J of Urol
Hosseini and Safarinejad	508	2004	Urol J

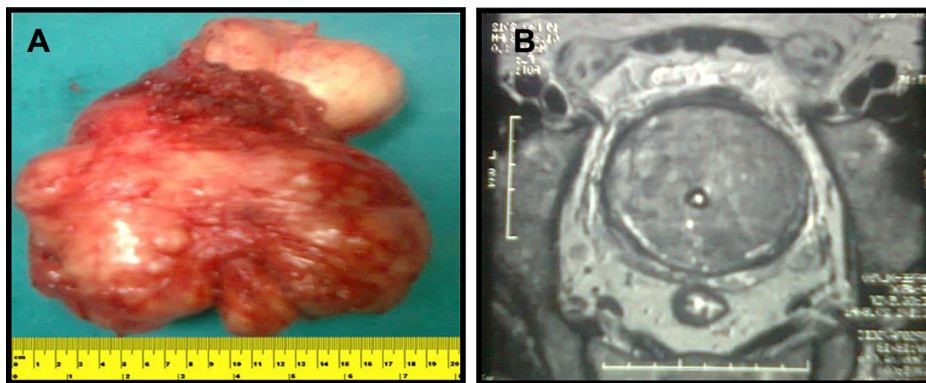
bladder. There have been recent reports in which the giant BPH has been resected by laparoscopy and transurethral electrovaporization.^{5,6} Although these procedures have a steep learning curve and require expertise, there has been an expected increase in the trend. This will improve the outcome of the patient in terms of morbidity and further reduction in mortality.

Conclusion

“Giant BPH” is a rare and underrecognized pathology of the prostate gland. In this study, we report successful resection of a giant BPH (700 g) without intraoperative complications through a suprapubic prostatectomy.

Conflict of interest

Authors declare that they have no conflict of interests.



Giant BPH specimen and Bladder

MRI of Giant Prostate Adenoma

Figure 1. (A) Giant benign prostatic hyperplasia specimen and bladder. (B) Magnetic resonance imaging of giant prostate adenoma.

urinary retention and renal failure. Yonou and colleagues reported a total of 33 cases that have been weighed more than 200 g.⁴ If the conservative management fails, the procedure of choice is usually the transurethral resection of the prostate. Although minimally invasive techniques can be used for small-size prostates, the only valid alternative for large prostates (>75 g) is the old classic open prostatectomy.

Suprapubic prostatectomy is the enucleation of the prostatic adenoma through an extraperitoneal incision of the lower anterior bladder wall. This procedure is best suited for patients who have large median lobe of the prostate, with beaky protrusion into the

References

- Berry SJ, Coffey DS, Walsh PC, Ewing LL. The development of human benign prostatic hyperplasia with age. *J Urol*. 1984;132:474–479.
- Kawamura S, Takata K, Yoshida I, Matsui S. A case of giant prostatic hypertrophy. *Hinyokika Kiyo*. 1984;30:1861–1866.
- Ockerblad NF. Giant prostate; the largest recorded. *J Urol*. 1946;56:81.
- Yonou H, Goya M, Miyazato M, et al. Giant prostatic hypertrophy: a case report. *Hinyokika Kiyo*. 1999;45:375–377.
- Yilmaz K, Istanbuluoglu O, Guven S, Kilinc M. Giant prostatic hyperplasia: case report. *Int Urol Nephrol*. 2006;38:587–589.
- De Silva-Gutiérrez A, Pérez-Evia CA, Alcocer-Gaxiola B, Martínez-Méndez ME. Giant prostatic hyperplasia. A case report and literature review. *Rev Mex Urol*. 2010;70:183–186.