

FIRST CLINICAL CASE IN EMERGING COUNTRY

Fatal *Chromobacterium violaceum* bacteraemia in rural Bandundu, Democratic Republic of the Congo

E. Bottieau¹, D. Mukendi², J.-R. Kalo², A. Mpanya², P. Lutumba², B. Barbé¹, F. Chappuis³, O. Lunguya², M. Boelaert⁴ and J. Jacobs^{1,5}

1) Department of Clinical Sciences, Institute of Tropical Medicine, Antwerp, Belgium, 2) Institut National de Recherche Biomédicale, Kinshasa, Democratic Republic of the Congo, 3) Division of International and Humanitarian Medicine, Geneva University Hospitals and University of Geneva, Geneva, Switzerland, 4) Department of Public Health, Institute of Tropical Medicine, Antwerp and 5) Department of Microbiology and Immunology, University of Leuven, Leuven, Belgium

Abstract

We describe the first case of bacteraemia caused by *Chromobacterium violaceum* in the Democratic Republic of the Congo. This diagnosis was made in an apparently healthy adult who was admitted to a rural hospital of the province of Bandundu with severe community-acquired sepsis. The patient developed multi-organ failure and died; to our knowledge, this is the first reported fatal case in an adult in Africa.

New Microbes and New Infections © 2014 The Authors. Published by Elsevier Ltd on behalf of European Society of Clinical Microbiology and Infectious Diseases.

Keywords: Bacteraemia, Bandundu province, Central Africa, *Chromobacterium violaceum*, DRC

Original Submission: 25 July 2014; **Revised Submission:** 24 October 2014; **Accepted:** 31 October 2014

Available online 12 November 2014

Corresponding author: E. Bottieau, Department of Clinical Sciences, Institute of Tropical Medicine, 155, Nationalestraat, Antwerpen 2000, Belgium

E-mail: ebottieau@itg.be

E. Bottieau and D. Mukendi contributed equally to the manuscript

Introduction

Chromobacterium violaceum is a Gram-negative bacillus present in tropical and subtropical soil and stagnant water. Approximately 150 cases of human infection have been published since its first description in Malaysia in 1927 [1,2]. Infection with this organism often presents as severe, frequently fatal, bacteraemia, which is typically observed in infants and children, sometimes with underlying conditions such as chronic granulomatous disease or glucose-6-phosphate dehydrogenase deficiency. Most recent reports have come from southern Asia [3–6] and, to a lesser extent, from South America [7]. To our knowledge, only four observations have been published from Africa: two cases of bacteraemia in adults, in Nigeria [8] and in South Africa [9], the latter in a patient with leukaemia; a cluster of nosocomial bacteraemia in a neonatal unit in Nigeria [10]; and a child in

Senegal with severe diarrhoea and *C. violaceum* recovered from a stool sample [11]. The nosocomial outbreak in Nigerian newborns had a 50% case-fatality rate, but both adult cases and the Senegalese child reportedly survived. We report here a case of fatal *C. violaceum* bacteraemia in an adult in the province of Bandundu, Democratic Republic of the Congo (DRC). The case was observed during a clinical study investigating the aetiologies of neurological disorders in rural Africa, conducted by the Neglected Infectious Diseases Diagnostics (NIDIAG) consortium (ClinicalTrials.gov; identifier NCT01589289).

Case report

In January 2013, a 30-year-old Congolese man was admitted for acutely altered consciousness to the Hôpital Général de Référence of Mosango, a poorly equipped rural hospital of Bandundu, DRC. The patient was a trader with no medical history who brought agricultural products from remote fields to village markets. Three days before admission, he had developed abrupt fever with cough, thoracic pain, and dyspnoea, followed by abdominal pain, vomiting, diarrhoea and finally, confusion, and did not respond to empirical antimalarial treatment (artesunate–amodiaquine).

Upon examination, the patient was lethargic and could not respond to simple questions and orders (Glasgow Coma Scale: 13/15). He had neck stiffness and moderate dehydration. His temperature was 39°C, his pulse rate was 92/min, his respiratory rate was 28/min, and his blood pressure was 120/90 mmHg. Crackles were heard over both lungs at auscultation, and the abdomen was diffusely painful but depressible on palpation. There was no jaundice and no skin lesion. The haemoglobin level was 12 g/dL (HemoCue HB 301 System; HemoCue AB, Ängelholm, Sweden). White blood cell count and blood chemistry were not determined, owing to temporary breakdown of the respective devices. Chest X-rays revealed bilateral patchy infiltrations. Abdominal ultrasonography did not provide any relevant information. Malaria rapid diagnostic tests, i.e. Pf-pLDH/Pan-pLDH (CareStart Malaria pLDH (Pf/PAN); Access Bio Somerset, New York, NY, USA) and Pf-HRP2/Pan-pLDH (SD Bioline FK60; Standard Diagnostics, Hagal-Dong, Korea), both gave negative results. The programme human immunodeficiency virus (HIV) rapid diagnostic test (Determine HIV1-2; Alere Health, Waltham, MA, USA) and Rapid Plasma Reagin for syphilis (BD Macro-Vue RPR Card Tests; Beckon Dickinson and Company, Sparks, NV, USA) both gave negative results. Microscopic examination of the cerebrospinal fluid (CSF) revealed a white blood cell count of 1/μL. No urine or sputum could be immediately obtained, and no culture facilities were available on site. Ceftriaxone and gentamicin were empirically initiated together with crystalloid and oxygen administration for acute sepsis. Approximately 16 h after admission, the patient became tachypnoeic (respiratory rate of 36/min) and tachycardic (heart rate of 116/min), and developed shock (blood pressure of 85/55 mmHg) that was non-responsive to fluid challenge. Mechanical ventilation and inotropic agents were not available. The patient died 2 h later. No autopsy was performed.

In line with the study protocol, blood was sampled on admission (2 × 10 mL from two separate venipunctures) and inoculated in aerobic blood culture vials (BacT/ALERT FA; BioMérieux, Marcy-L'Étoile, France); CSF was inoculated in paediatric blood culture bottles (BacT/ALERT PF, 4 mL). All samples were shipped at room temperature to the Institut National de Recherche Biomédicale, Kinshasa (8 h by road; only one transport daily). Upon arrival, the growth indicator of the blood and CSF culture isolates had turned positive. Gram staining of both blood and CSF samples revealed Gram-negative rods that, on subculture, had outstanding violet–black pigmentation (Fig. 1). On Kligler-Iron Agar (Oxoid, Basingstoke, UK), the organism fermented glucose. It was identified as *C. violaceum* by API20 NE V7.0 (BioMérieux; profile 1152554, very good identification) and later by the MicroScan (Biotype 40002007, Combo 42 panel; Siemens Healthcare Diagnostics,

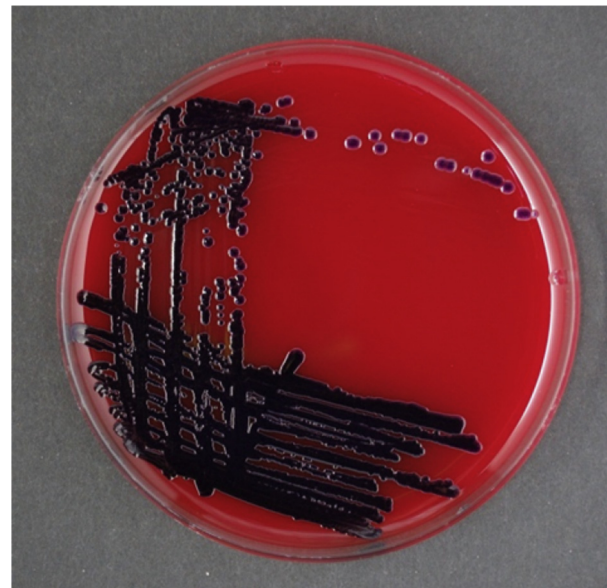


FIG. 1. Violet–black pigmentation of the *Chromobacterium violaceum* isolate on sheep blood agar, after incubation at 37°C for 24 h.

Deerfield, IL, USA). Antibiotic susceptibility testing (Combo 42) interpreted according to CLSI M45 [12] revealed resistance to β-lactam antibiotics (ampicillin, amoxicillin–clavulanic acid, cefazolin, cefotaxime, and ceftazidime), susceptibility to fluoroquinolone antibiotics (ciprofloxacin and levofloxacin), trimethoprim–sulphamethoxazole, and meropenem, and susceptibility and intermediate resistance to gentamicin and amikacin (MICs of ≤4 mg/L and 32 mg/L, respectively).

Discussion

Fatal bacteraemia caused by *C. violaceum* has not been reported in African adults. The large majority of the 106 cases analysed in a recent systematic review had been diagnosed in the Americas and southern Asia [2]. Usually, infection occurs through skin or respiratory system exposure to stagnant water, and tends to disseminate in a fulminant way, with a case-fatality rate exceeding 50%. In the present patient, and similarly to other observations [2,6], the family denied unusual exposure to water, such as swimming or near-drowning. There were no skin lesions suspected of being contaminated by soil [1,3,4]. The patient initially presented with community-acquired sepsis of uncertain origin [2], making the aetiological diagnosis almost impossible, as laboratory and imaging data were not available. Multi-organ failure (bilateral pneumonia, encephalitis, and shock) rapidly developed, with an adverse outcome in this deprived setting. Although the diagnostic exploration of the case was seriously limited by the lack of facilities on site, the

causative pathogen was unequivocally demonstrated in both blood and CSF cultures in the research laboratory of Kinshasa a few days after the patient's death. It was also not possible to further assess the patient for predisposing conditions, but he has been always been reportedly in good health, and the negative HIV test result had ruled out an underlying HIV infection.

Upon admission, typhoid fever, severe pneumonia and even meningitis were considered, and ceftriaxone was finally preferred over ciprofloxacin, although, in retrospect, the latter could have been more beneficial. The antimicrobial susceptibility of *C. violaceum* was in line with that observed elsewhere, with broad resistance to β -lactams that may have played a role in the adverse outcome [2]. Multidrug resistance of bacteria commonly involved in community-acquired infections is being increasingly reported in Central Africa [13], including, for example, decreased fluoroquinolone susceptibility of *Salmonella* Typhi in the DRC [14]. Empirical antibiotherapy covering the whole spectrum of common and less common bacterial aetiologies of community-acquired sepsis is therefore becoming extremely challenging in such settings with limited therapeutic options. The present case illustrates the need for microbiological surveillance also at the peripheral level in remote African settings, as multiresistance is emerging and unusual pathogens may also be recovered. Coordinated research efforts should be relentlessly expanded to comprehensively document the aetiologies of febrile illnesses in the most neglected tropical populations [15].

Transparency declaration

This work was supported by a grant agreement 260260 from the European Commission under the Health Cooperation Work Programme of the 7th Framework Programme (FP7) to the NIDIAG consortium (www.nidiag.org). All authors declare that they have no competing interests.

References

- [1] Ti TY, Tan WC, Chong AP, Lee EH. Nonfatal and fatal infections caused by *Chromobacterium violaceum*. Clin Infect Dis 1993;17:505–7.
- [2] Yan CH, Li YH. *Chromobacterium violaceum* infection: A clinical review of an important but neglected infection. J Chin Med Assoc 2011;74:435–41.
- [3] Baker S, Campbell JJ, Stabler R, Nguyen HV, To DS, Nguyen DV, et al. Fatal wound infection caused by *Chromobacterium violaceum* in Ho Chi Minh City, Vietnam. J Clin Microbiol 2008;46:3853–5.
- [4] Campbell JJ, Lan NP, Qui PT, Dung LT, Farrar JJ, Baker S. A successful antimicrobial regime for *Chromobacterium violaceum* induced bacteraemia. BMC Infect Dis 2013;13:4.
- [5] Slesak G, Douangdala P, Inthalad S, Silisouk J, Vongsouvath M, Sengduangphachanh A, et al. Fatal *Chromobacterium violaceum* septicaemia in northern Laos, a modified oxidase test and post-mortem forensic family G6PD analysis. Ann Clin Microbiol Antimicrob 2009;8:24.
- [6] Karthik R, Pancharatnam P, Balaji V. Fatal *Chromobacterium violaceum* septicemia in a South Indian adult. J Infect Dev Ctries 2012;10:751–5.
- [7] de Siqueira IC, Dias J, Ruf H, Ramos EA, Maciel EA, Rolim A, et al. *Chromobacterium violaceum* in siblings, Brazil. Emerg Infect Dis 2005;11:1443–5.
- [8] Onile A, Sobowale BO, Odugbemi T. Human infection due to *Chromobacterium violaceum*: a report from Ilorin, Nigeria. East Afr Med J 1984;61:849–52.
- [9] Bosch FJ, Badenhorst L, Le Roux JA, Louw VJ. Successful treatment of *Chromobacterium violaceum* sepsis in South Africa. J Med Microbiol 2008;57:1293–5.
- [10] Anah MU, Udo JJ, Ochigbo SO, Abia-Bassey LN. Neonatal septicaemia in Calabar, Nigeria. Trop Doct 2008;38:126–8.
- [11] Dromigny JA, Fall AL, Diouf S, Perrier-Gros-Claude JD. *Chromobacterium violaceum*: a case of diarrhea in Senegal. Pediatr Infect Dis J 2002;21:573–4.
- [12] CLSI. Methods for antimicrobial dilution and disk susceptibility testing of infrequently isolated or fastidious bacteria; Approved Guideline - Second Edition. CLSI document M45–A2. Wayne, PA: CLSI; 2010.
- [13] Vlieghe E, Phoba MF, Tamjun JJ, Jacobs J. Antibiotic resistance among bacterial pathogens in Central Africa: a review of the published literature between 1955 and 2008. Int J Antimicrob Agents 2009;34:295–303.
- [14] Lunguya O, Lejon V, Phoba MF, Bertrand S, Vanhoof R, Verhaegen J, et al. *Salmonella typhi* in the Democratic Republic of the Congo: fluoroquinolone decreased susceptibility on the rise. PLoS Negl Trop Dis 2012;6(11):e1921.
- [15] Yansouni CP, Bottieau E, Chappuis F, Phoba MF, Lunguya O, Ifeka BB, et al. Rapid diagnostic tests for a coordinated approach to fever syndromes in low-resource settings. Clin Infect Dis 2012;4:610–1.