

Contents lists available at [SciVerse ScienceDirect](http://SciVerse.Sciencedirect.com)

Respiratory Medicine Case Reports

journal homepage: www.elsevier.com/locate/rmcr

Case report

Fibrinolytic therapy for parapneumonic empyema during pregnancy

Hakki Ulutas^{a,*}, Erdal Yekeler^b, Zafer Hasan Ali Sak^c, Ihsan Doru^d, Akin Kuzucu^a

^a Department of Thoracic Surgery, School of Medicine, Inonu University, Malatya, Turkey

^b Department of Thoracic Surgery, Ataturk Training and Research Hospital for Chest Disease and Chest Surgery, Kecioren, Ankara, Turkey

^c Department of Pulmonary Medicine, School of Medicine, Harran University, Sanliurfa, Turkey

^d Department of Radiology, Region Training and Research Hospital, Erzurum, Turkey

ARTICLE INFO

Article history:

Received 22 August 2011

Accepted 26 August 2011

Keywords:

Intrapleural fibrinolytic therapy

Parapneumonic empyema

Pregnancy

ABSTRACT

Pneumonia and parapneumonic complicated effusion during pregnancy is uncommon but poses potentially serious risks to both mother and fetus. Enzymatic debridement of the pleural cavity with fibrinolytic agents is a noninvasive option that can facilitate drainage and prevent the need for surgery. Herein, we describe the cases of two pregnant women with parapneumonic empyema who were successfully treated with intrapleural fibrinolytic therapy.

© 2011 Elsevier Ltd. Open access under [CC BY-NC-ND license](http://creativecommons.org/licenses/by-nc-nd/3.0/).

Pneumonia and secondary complications such as pleural effusion or empyema cause considerable morbidity and even mortality in the general population. The first-line therapy for complicated parapneumonic effusion or empyema is drainage via chest tube or catheter combined with antibiotic therapy. In patients with empyema, if the fluid and pus material becomes multiloculated through the formation of fibrin strands, tube drainage may be inadequate and surgical treatment may be necessary. Enzymatic debridement of the pleural cavity with fibrinolytic agents is a noninvasive option that can facilitate drainage and prevent the need for surgery. Parapneumonic empyema during pregnancy is diagnostically and therapeutically challenging. We describe the cases of 2 pregnant women who developed pneumonia with secondary pleural empyema and were successfully managed with intrapleural fibrinolytic therapy.

1. Case descriptions

Case 1. A 22-year-old woman in her 24th week of pregnancy presented with a 15-day history of fever, pain in the lateral left thorax, dyspnea, and productive cough. Physical examination revealed diminished breath sounds and dullness on percussion of the left chest. Obstetric sonography demonstrated a normal uterus and fetus according to the gestational week. Chest x-ray showed

generalized opacity of the left hemithorax (Fig. 1). Computed tomography of the chest revealed pneumothorax, fluid collection, and collapsed left lung (Fig. 2). The patient was hospitalized. A chest tube was placed and 2000 mL of purulent fluid were drained. The status of the fetus was monitored daily by an obstetrician. After chest tube drainage, repeat chest radiography revealed residual fluid but drainage through the thoracostomy tube had stopped. After obstetric consultation, the decision was made to administer fibrinolytic therapy with streptokinase at a dose of 250,000 U/day for 2 days. Each daily dose of streptokinase was diluted in 100 mL saline solution and instilled in the pleural cavity via the chest tube, which was then clamped for 4 h. After the 2 treatments, there was a notable increase in the amount of fluid that was draining. The patient improved continuously thereafter. Her chest tube was removed on day 12 of hospitalization, and she was discharged the following day. The only remarkable finding on a chest x-ray taken the day of discharge was normal (Fig. 3a,b). The patient carried her pregnancy to term. She entered spontaneous labor after 39 weeks' gestation and gave birth to a healthy female infant by vaginal delivery. A follow-up chest x-ray at 2 months after discharge showed complete resolution of the pneumonia and empyema.

Case 2. A 39-year-old woman in her 29th week of pregnancy presented to hospital with a 15-day history of dyspnea, chest pain, fever, and productive cough. Her chest x-ray showed a pleural effusion in the right chest. The fetus' condition was assessed by ultrasound and found to be normal. Thoracocentesis revealed pus. A chest tube was inserted and 700 mL of purulent fluid were

* Corresponding author. Tel.: +90 4223410660 3907, +90 532 7732140 (mobile).
E-mail address: drhakkiulutas@yahoo.com (H. Ulutas).

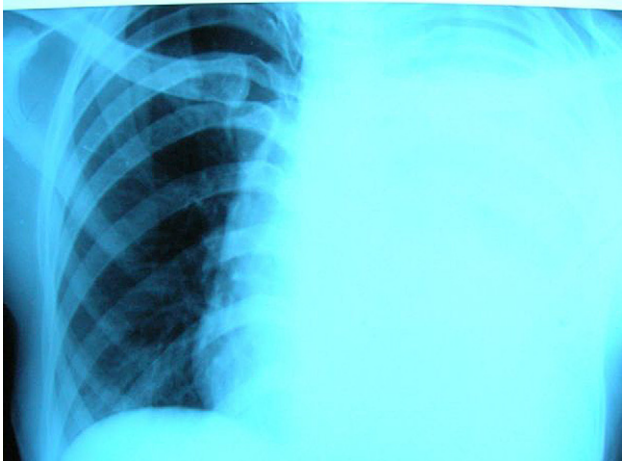


Fig. 1. Chest radiography of patient at presentation.

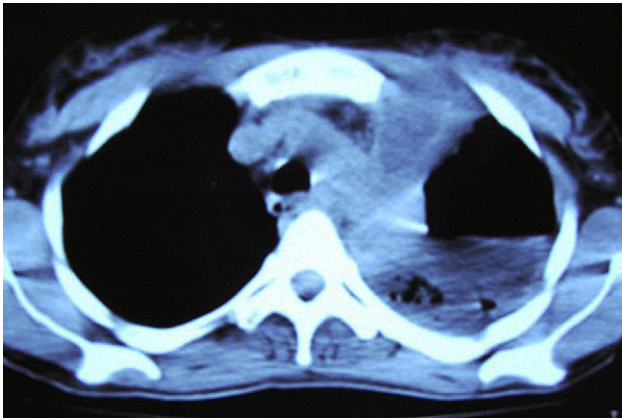


Fig. 2. Computed tomography of the chest showing large left pleural effusion and pneumothorax.

drained. Despite placement of the tube and use of suction, the amount of drainage was considered inadequate. Chest radiography showed an organized fluid collection in the right hemithorax and consolidation and partial collapse of the lower lobe of the right lung

(Fig. 4a,b). Thoracic magnetic resonance imaging demonstrated elevation of the diaphragm, loculated pleural fluid, and atelectasis of the lower right lung lobe (Fig. 5a,b). Fibrinolytic therapy was initiated, with 250,000 units streptokinase diluted in 100 ml saline and instilled into the pleural cavity via the chest tube. The tube was then clamped for 4 h. This treatment was repeated daily for the next 3 days. A chest x-ray after the fourth day of enzymatic debridement showed complete resolution of the pleural collection and re-expansion of the lower right lung lobe (Fig. 6). By day 10 of hospitalization, the drainage had reduced to less than 100 ml daily and the chest tube was removed. After the patient was discharged, her pregnancy continued uneventfully. At 40 weeks' gestation, she had a healthy child via uncomplicated vaginal delivery.

2. Discussion

Pneumonia during pregnancy is uncommon but poses potentially serious risks to both mother and fetus. It is estimated that at least 40% of patients who are hospitalized with pneumonia develop a parapneumonic effusion.¹ There is considerable variation in the clinical course of this condition. Pneumonia is complicated by empyema in approximately 8% of all cases of pneumonia in pregnancy.² The therapy for pneumonia with pleural effusion varies depending on clinical circumstances. Conventional options include antibiotic therapy alone for uncomplicated effusions, chest tube or catheter drainage for complicated effusions, and surgical drainage for organized empyema.

Intrapleural fibrinolytic therapy is a therapeutic alternative for managing complicated parapneumonic effusions. Although some authors do not favor this form of treatment,^{3,4} others recommend the instillation of fibrinolytic drugs in addition to chest tube drainage as a method to lyse fibrous adhesions and enhance pleural fluid drainage, and to thus reduce surgical referrals.^{1,5} Specifically, proponents of enzymatic debridement claim that if this therapy is administered before pleural peel formation and lung entrapment, it can avoid the need for surgical intervention.^{1,5}

We found only one report in the English literature that examined the use of intrapleural fibrinolytic therapy during pregnancy.⁶ However, other authors have documented successful intravascular use of streptokinase during pregnancy for venous thromboembolism without fetal teratogenicity, and with rare serious obstetric complications or adverse effect.^{7,8} Turrentine *et al.* reviewed 172 cases of pregnant women with thromboembolic disease who were

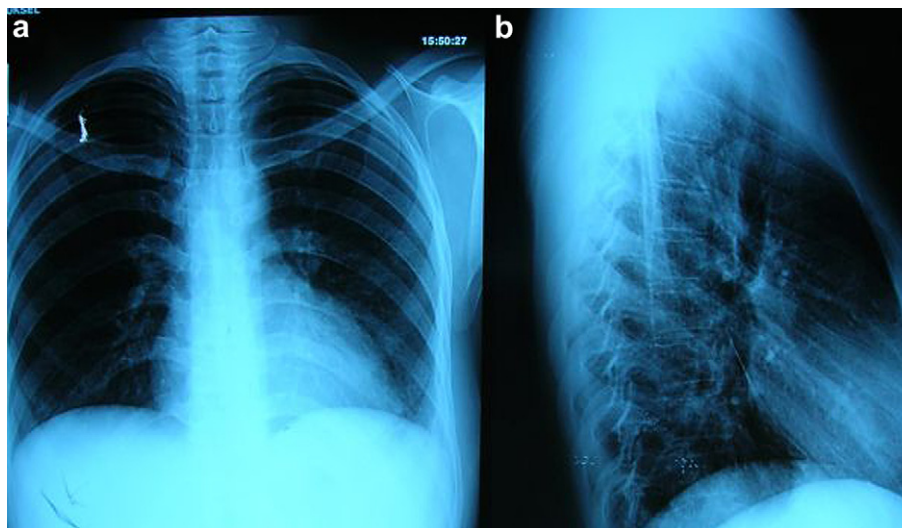


Fig. 3. a,b. Chest radiography of patient after treatment of intrapleural streptokinase.

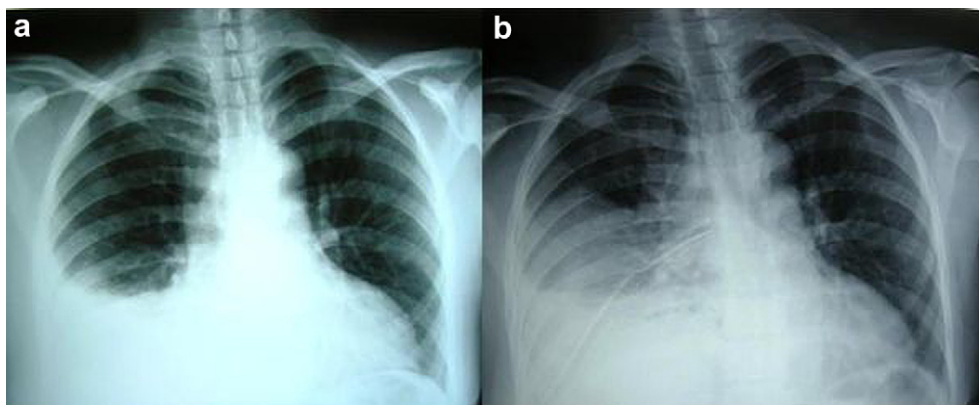


Fig. 4. a. Chest radiography of patient at presentation; b. Chest radiography of patient after tube thoracostomy.

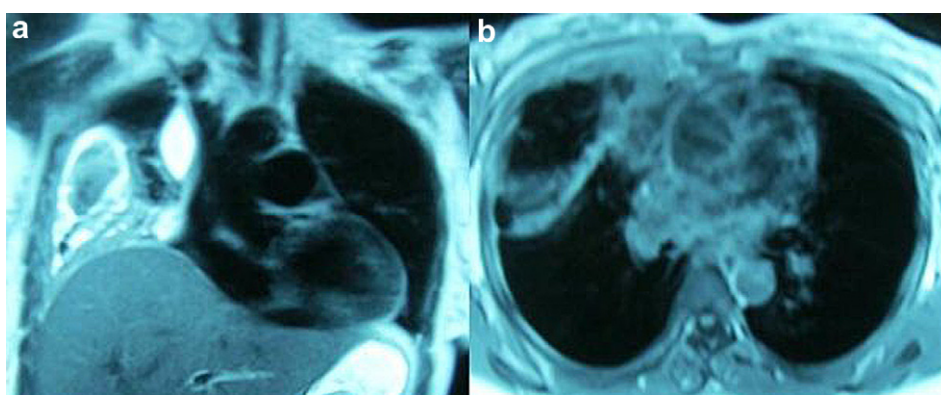


Fig. 5. a,b. Thoracic magnetic resonance imaging showing elevation of the diaphragm, loculated pleural fluid and atelectasis.

managed with systemic fibrinolytic therapy (165 streptokinase, 3 urokinase, 4 rt-PA).⁷ They reported 14 hemorrhagic complications (8.1% of all cases), 10 fetal deaths (5.8%), 10 preterm deliveries (5.8%), and 2 maternal deaths (1.2%). According to the authors, these deaths were not related to the thrombolytic therapy. Turentine et al. and others have suggested that complications of fibrinolytic treatment are acceptable for this patient group considering the gravity of conditions such as pulmonary embolism.^{7,8}

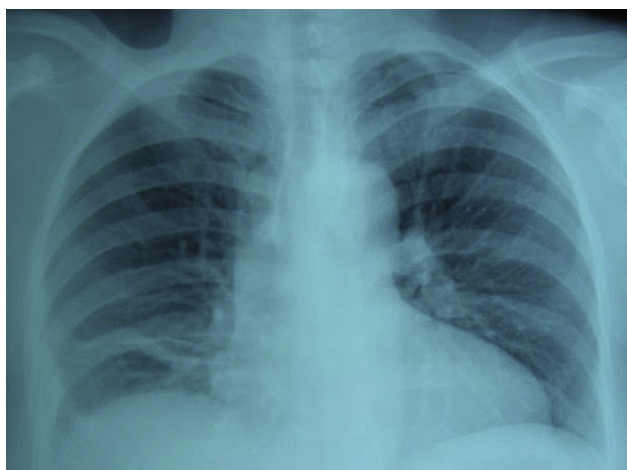


Fig. 6. Chest radiography of patient after treatment of intrapleural streptokinase.

In line with this, our opinion is that empyema and its surgical therapy options expose a mother and fetus to greater risk than fibrinolytic therapy does. A 1998 study of the systemic fibrinolytic effects of intrapleural streptokinase in patients with complicated parapneumonic pleural effusion or empyema showed no significant changes in systemic coagulation indices or status after administration of this treatment.⁹ Maskell and coworkers investigated intrapleural streptokinase therapy in 454 patients with pleural infection and observed modest adverse events, such as chest pain, fever, or allergic reaction.³ Rare occurrences of local and systemic hemorrhage with intrapleural fibrinolytic therapy have also been documented.^{1,10}

Nir *et al.* reported the case of a pregnant woman with empyema who was treated with intrapleural streptokinase instillation,⁶ the same therapy as our 2 patients received. They suggested that this method is safe and effective for managing parapneumonic empyema during pregnancy.

In conclusion, several days of streptokinase instillation into the pleural cavity combined with chest tube drainage may be a relatively safe alternative to surgical treatment of empyema during pregnancy. Currently, there is insufficient evidence regarding any risks that fibrinolytic therapy may pose to pregnant mothers and their fetuses; however, we believe that it is not justified to withhold fibrinolytic therapy from pregnant patients if effective noninvasive alternatives are lacking and this approach can avoid surgical intervention.

Conflict of interest statement

None.

References

1. Bouros D, Tzouvelekis A, Antoniou KM, Heffner JE. Intrapleural fibrinolytic therapy for pleural infection. *Pulm Pharmacol Ther* 2007;**20**:616–26.
2. Goodnight WH, Soper DE. Pneumonia in pregnancy. *Crit Care Med* 2005;**33**(Suppl):390–7.
3. Maskell NA, Christopher WH, Davies MD, et al. Controlled trial of intrapleural streptokinase for pleural infection. *N Eng J Med* 2005;**352**:865–74.
4. Tokuda Y, Matsushima D, Stein GH, Miyagi S. Intrapleural fibrinolytic agents for empyema and complicated parapneumonic effusions. *Chest* 2006;**129**:783–90.
5. Misthos P, Sepsas E, Konstantinou M, Athanassiadi K, Skottis I, Lioulis A. Early use of intrapleural fibrinolytics in management of postpneumonic empyema. A prospective study. *Eur J Cardiothorac Surg* 2005;**28**:599–603.
6. Nir S, Gadi L, Mony S, Meir M, Jaime G, Amir E, et al. Successful use of streptokinase for the treatment of empyema thoracis during advanced pregnancy: a case report. *Respir Med*; 2009;**2**:21–4.
7. Turrentine MA, Braems G, Ramirez MM. Use of thrombolytics for the treatment of thromboembolic disease during pregnancy. *Obstet Gynecol Surv* 1995;**50**:534–41.
8. Te Raa GD, Ribbert LSM, Snijder RJ, Biesma DH. Treatment options in massive pulmonary embolism during pregnancy: a case-report and review of literature. *Thromb Res* 2009;**124**:1–5.
9. Davies CWH, Lok S, Davies RJO. The systemic fibrinolytic activity of intrapleural streptokinase. *Am J Respir Crit Care Med* 1998;**157**:328–30.
10. Temes RT, Follis F, Kessler RM, Pett Jr SB, Wernly JA. Intrapleural fibrinolytics in management of empyema thoracis. *Chest* 1996;**110**:102–6.