

# Monogenic diseases that can be cured by liver transplantation

Stefano Fagioli<sup>1,\*</sup>, Erica Daina<sup>2</sup>, Lorenzo D'Antiga<sup>3</sup>, Michele Colledan<sup>4</sup>, Giuseppe Remuzzi<sup>2,5</sup>

<sup>1</sup>Gastroenterology and Transplant Hepatology, Ospedale Papa Giovanni XXIII, Bergamo, Italy; <sup>2</sup>Istituto di Ricerche Farmacologiche "Mario Negri" – IRCCS, Clinical Research Center for Rare Diseases Aldo e Cele Daccò, Bergamo, Italy; <sup>3</sup>Paediatric Hepatology, Gastroenterology and Transplantation, Ospedale Papa Giovanni XXIII, Bergamo, Italy; <sup>4</sup>Department of Surgery, Ospedale Papa Giovanni XXIII, Bergamo, Italy; <sup>5</sup>Department of Nephrology and Dialysis, Ospedale Papa Giovanni XXIII, Bergamo, Italy

## Summary

While the prevalence of most diseases caused by single-gene mutations is low and defines them as rare conditions, all together, monogenic diseases account for approximately 10 in every 1000 births according to the World Health Organisation.

Orthotopic liver transplantation (LT) could offer a therapeutic option in monogenic diseases in two ways: by substituting for an injured liver or by supplying a tissue that can replace a mutant protein. In this respect, LT may be regarded as the correction of a disease at the level of the dysfunctional protein. Monogenic diseases that involve the liver represent a heterogeneous group of disorders. In conditions associated with predominant liver parenchymal damage (i.e., genetic cholestatic disorders, Wilson's disease, hereditary hemochromatosis, tyrosinemia,  $\alpha$ 1 antitrypsin deficiency), hepatic complications are the major source of morbidity and LT not only replaces a dysfunctional liver but also corrects the genetic defect and effectively cures the disease. A second group includes liver-based genetic disorders characterised by an architecturally near-normal liver (urea cycle disorders, Crigler-Najjar syndrome, familial amyloid polyneuropathy, primary hyperoxaluria type 1, atypical haemolytic uremic syndrome-1). In these defects, extrahepatic complications are the main source of morbidity and mortality while liver function is relatively preserved. Combined transplantation of other organs may be required, and other surgical techniques, such as domino and auxiliary liver transplantation, have been attempted. In a third group of monogenic diseases, the underlying genetic defect is expressed at a systemic level and liver involvement is just one of the clinical manifestations. In these conditions, LT might only be partially curative since the abnormal phenotype is maintained by extrahepatic synthesis of the toxic metabolites (i.e., methylmalonic acidemia, propionic acidemia).

This review focuses on principles of diagnosis, management and LT results in both paediatric and adult populations of selected liver-based monogenic diseases, which represent

examples of different transplantation strategies, driven by the understanding of the expression of the underlying genetic defect. © 2013 European Association for the Study of the Liver. Published by Elsevier B.V. Open access under [CC BY-NC-ND license](https://creativecommons.org/licenses/by-nc-nd/4.0/).

## Introduction

Many human diseases have a genetic basis. Some of these are attributed to chromosome abnormalities or mutations at multiple loci, while a significant number are caused by mutations of a single gene. According to the Online Mendelian Inheritance in Man database (OMIM), as of March 2013, 3730 phenotype descriptions with known molecular basis have been reported [1]. While each of these conditions is relatively rare, if considered all together, monogenic diseases affect a substantial population, estimated by the World Health Organisation to amount approximately to 10 out of 1000 births [2]. These conditions affect an important portion of the world population that requires special health care [3–5] and they represent a frequent cause of mortality, especially in the paediatric population [6,7].

## Management of monogenic diseases

The ideal goal of treatment for monogenic diseases is to revert a harmful phenotype to the normal state. Substantial progress has been made over the past six decades in this direction, beginning with the first report of successful dietary control of phenylketonuria in the early 1950s. Examples of treatments approach of monogenic diseases include dietary prescriptions, pharmacologic interventions to allow alternative pathway excretion of toxic metabolites, oral replacement of enzymatic cofactors, use of chelation to enhance excretion. When a monogenic disorder is caused by enzyme deficiency or dysfunction, enzyme replacement therapy (ERT) represents a viable option. Firstly successfully used in Gaucher disease, ERT has been developed for the treatment of other monogenic diseases. However, ERTs are usually extremely expensive treatments, and their real cost-effectiveness has been questioned [8]. A more definitive approach would be the gene therapy, whose application is still strongly limited by the difficulty to devise efficient delivery systems to allow local transfer and expression of the therapeutic

Keywords: Liver transplantation; Surgical gene therapy; Genetic diseases, Inborn; Metabolic diseases; Rare diseases.

Received 14 November 2012; received in revised form 2 April 2013; accepted 2 April 2013

\* Corresponding author. Address: Division of Gastroenterology and Transplant Hepatology, Ospedale Papa Giovanni XXIII, Piazza OMS 1, 24127 Bergamo, Italy. Tel.: +39 0352673435; fax: +39 0352674964.

E-mail address: [sfagioli@hpg23.it](mailto:sfagioli@hpg23.it) (S. Fagioli).



ELSEVIER

## Frontiers in Liver Transplantation

gene in the target organ or tissue. Severe combined immunodeficiency was the first condition to be successfully treated by gene therapy [9], showing that this approach is feasible although technical limitations have emerged and ethical issues have been raised, suggesting that wider implementation of gene therapy is still far from being a present day option [10]. In the meantime, organ transplantation remains the standard therapy for a variety of life-threatening monogenic diseases, offering either a curative approach or an improvement in the quality of life. Monogenic diseases that involve the liver represent a heterogeneous group of disorders (Table 1). Some conditions are characterised by liver parenchymal damage and hepatic injury. A second group includes liver-based genetic disorders characterised by a structurally normal liver. In these diseases, genes encoding enzymes that allow the regulation of complex metabolic pathways or circulating proteins mainly produced by the liver are involved. Extrahepatic complications are the main source of morbidity and mortality, while liver function is relatively preserved. The replacement of a defective protein-producing liver with one producing the wild type (normal) protein may treat or rather prevent the systemic manifestations. Combined transplantation with other organs may be needed [11]. In a third group of monogenic diseases, the genetic defect is expressed at a systemic level and liver involvement is just one of the clinical manifestations. In these conditions, liver transplantation (LT) is not curative since the abnormal phenotype is partially maintained by extrahepatic synthesis of the toxic metabolites. Discussing all types of monogenic disorders amenable to LT is beyond the purpose of this review. We therefore chose to focus on selected monogenic diseases that represent examples of different transplantation strategies driven by the understanding of the phenotypic expression of the genetic defect. The European Liver Transplant Registry and Bergamo experiences in LT for monogenic diseases are shown in Fig. 1.

### Monogenic diseases with primary hepatic expression and parenchymal damage

In this group of monogenic disorders, the defect is solely expressed within the liver, which is also the organ primarily injured. When manifestations of acute, sub-acute, or chronic liver failure become evident, orthotopic LT not only replaces a dysfunctional liver but also corrects the genetic defect and effectively cures the disease. The role of LT for this group of monogenic disorders is well established.

#### Genetic cholestatic disorders

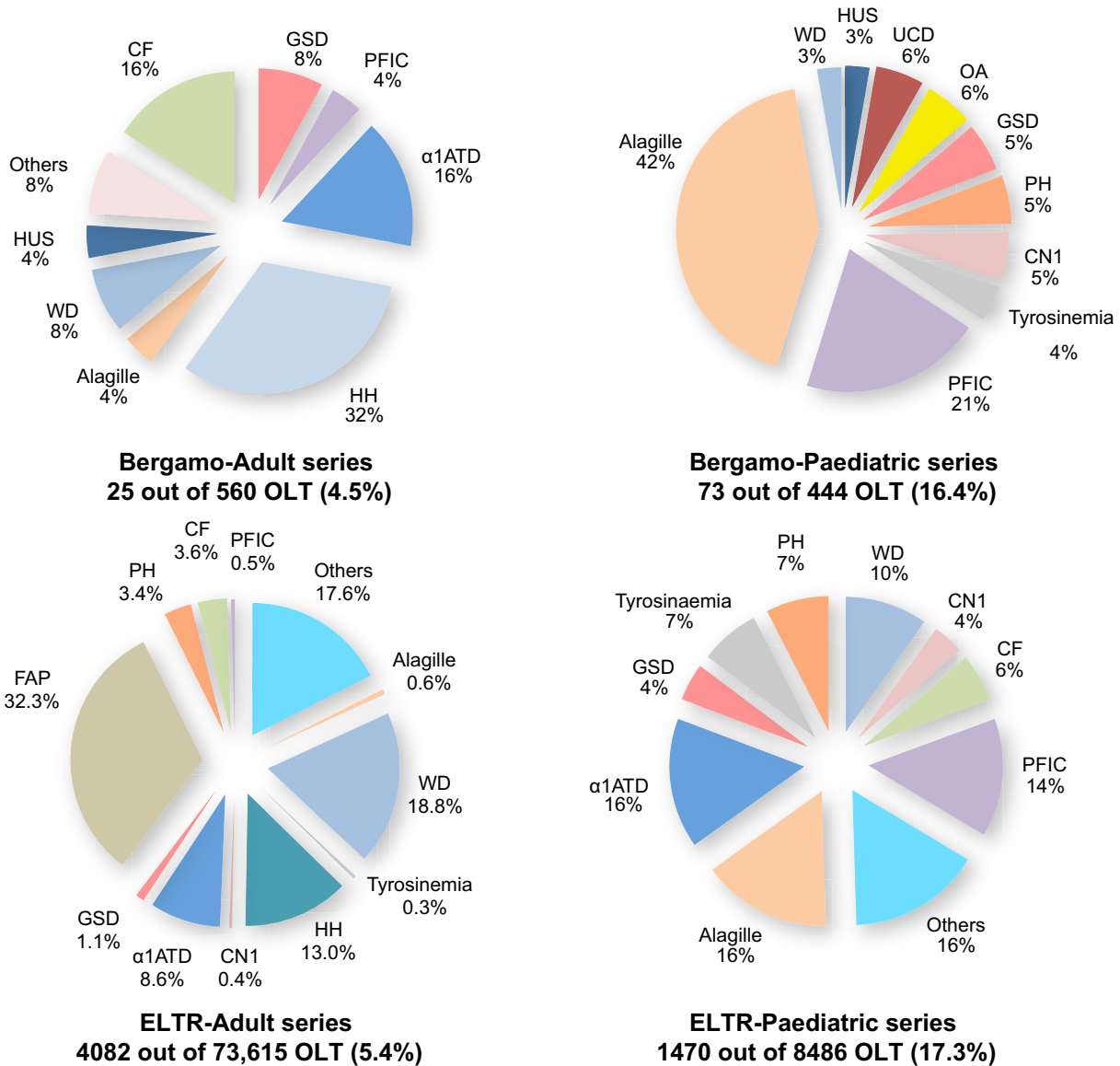
Genetic cholestatic disorders are inherited syndromes that result from mutations in the following genes: *JAG1* (causing Alagille syndrome), *ATP8B1* (also known as *FIC1*), *ABCB11* (*BSEP*), and *MDR3* (*ABCB4*). These disorders represent a common and well established indication to LT, are extensively discussed elsewhere, and therefore will be touched upon only for the most relevant aspects as far as LT is concerned.

#### PFIC

Progressive familial intrahepatic cholestasis (PFIC) is a group of genetic cholestatic disorders presenting in children and often requiring LT during the paediatric age. PFIC includes three major conditions characterized by defective secretion of bile acids or other bile components into the bile canaliculus. The estimated prevalence of PFIC varies between 1/50,000 and 1/100,000 births. Three types of PFIC have been identified. PFIC1 and PFIC2 are caused by impaired bile salt secretion due respectively to defects in *ATP8B1* encoding the FIC1 protein, and in *ABCB11* encoding the bile salt export pump protein (BSEP). They are characterized by infantile presentation with jaundice, pruritus and failure to thrive but low or normal  $\gamma$ -glutamyltransferase (GGT) activity.

**Table 1. Examples of monogenic diseases in which liver transplantation has been proposed, classified according to the extent of either liver or systemic dysfunction.**

Monogenic diseases with primary hepatic expression and parenchymal damage
Genetic cholestasis (PFIC and Alagille syndrome)
Wilson's disease
Hereditary hemochromatosis
Tyrosinemia type 1
$\alpha$ -1-antitrypsin deficiency
Argininosuccinic aciduria (ASL)
Glycogen storage disease (GSD) type I (adenoma/hepatocellular carcinoma)
Monogenic diseases with primary hepatic expression without significant parenchymal damage
Urea cycle disorders (excepted ASL)
Crigler-Najjar syndrome
Familial amyloid polyneuropathy
Atypical haemolytic uremic syndrome-1
Primary hyperoxaluria type 1
Maple syrup urine disease (MSUD)
Acute intermittent porphyria
Coagulation defects
GSD type Ia (in metabolic control)
Homozygous familial hypercholesterolemia
Monogenic diseases with both hepatic and extrahepatic expression
Organic acidurias (excepted MSUD)
Cystic fibrosis
Erythropoietic protoporphyria
Gaucher disease



**Fig. 1. ELTR and Bergamo experiences in adult and paediatric in LT for monogenic diseases: ELTR (1968–2010) and Bergamo (1998–2012).** α1ATD, alpha1 anti-trypsin deficiency; CF, cystic fibrosis; CN1, Crigler Najjar type 1; FAP, familial amyloid polyneuropathy; GSD, glycogen storage disease; HH, hereditary haemochromatosis; HUS, haemolytic uraemic syndrome; OA, organic acidurias; PH, primary hyperoxalurias; PFIC, progressive familial intrahepatic cholestasis; UCD, urea cycle disorders; WD, Wilson's disease.

PFIC3 tends to present later in childhood, is caused by a defect in *ABCB4*, encoding the multi-drug resistant 3 protein (MDR3), that leads to impaired biliary phospholipid secretion resulting in severe cholestatic disorder with raised GGT activity and early development of severe portal hypertension. [12].

PFIC is a well-established indication for LT, which is performed most commonly for end-stage liver disease (ESLD) or pruritus with very good results [13]. However, some patients with PFIC2 may require LT because of the early occurrence of hepatocellular carcinoma (HCC). In this setting, HCC has been shown to have a favorable course even when the child is transplanted outside the Milan criteria [14]. LT is generally curative for patients with PFIC. However, patients with PFIC1 may have ongoing disease due to the extrahepatic expression of FIC1 protein, such as

failure to thrive, chronic diarrhea with malabsorption, and liver steatosis [15].

*Alagille syndrome*

Alagille syndrome (AS) is a disease hallmarked by the paucity of interlobular bile ducts that determines the development of severe cholestasis with pruritus and progression to a biliary type of cirrhosis [16]. The syndrome is characterised by the following associated features: cardiac anomalies (85% of cases); butterfly vertebrae (87%); posterior embryotoxon of the eye (88%), dysmorphic facial features with broad nasal bridge, triangular face and deep set eyes (95%). Patients with AS often demonstrate abnormalities of the arteries predisposing to arterial vascular accidents, including a higher incidence of strokes [17]. The

## Frontiers in Liver Transplantation

syndrome is inherited in an autosomal dominant fashion with variable penetrance. Mutations in the *JAG-1* gene are responsible for Alagille syndrome in more than 90 percent of patients; others have mutations in *NOTCH-2*.

A study by Lykavieris in 163 patients with AS has shown that transplant free survival is significantly worse in those who present with neonatal cholestatic jaundice as compared to those who develop jaundice later in life [18]. Cardiac malformations (such as pulmonary artery stenosis, pulmonary vascular hypoplasia, pulmonary atresia, tetralogy of Fallot, and truncus arteriosus) should be carefully evaluated and treated before LT since they can severely affect the outcome.

Post-LT survival in children transplanted for AS is lower compared to those transplanted for biliary atresia, the most common indication to LT in the paediatric age (1-year patient survival 87% vs. 96%). A comprehensive assessment of the status of cardiac, renal, and vascular co-morbidities by a multidisciplinary team is mandatory before listing a patient with AS for LT [19].

### Wilson's disease

Wilson's disease (WD) is a rare inherited autosomal recessive copper storage disease that has a prevalence of about 1 in 30,000 people, with a carrier rate of 1 in 90 [20]. The copper accumulation occurs primarily in the liver, though toxic concentrations may also be found in other organs, mainly brain, cornea and kidney (Table 2) [21]. In children, WD is often diagnosed in the preclinical phase, unravelled by chance following the detection of raised aminotransferase, or as part of screening of families with an affected first degree relative. In older children and in adults, WD presents with three predominant scenarios that may indicate LT: (a) acute presentation characterised by acute liver failure, haemolysis and renal failure; (b) sub-acute liver disease; (c) chronic liver disease characterised by progression to ESLD, with neuropsychiatric manifestation that might or may not precede the clinical development of hepatic insufficiency [22]. The diagnosis is based on a combination of clinical features (Table 3) [23]. The disease can be successfully treated when identified at an early stage, thus preventing complications [24]. The goal of therapy is to reduce copper accumulation either by enhancing its urinary excretion or by decreasing its intestinal absorption. The available medical treatments are copper-chelating agents (penicillamine, trientine, tetrathiomolybdate) or zinc salts (through the block of intestinal copper absorption) [25–28]. Patients presenting with acute liver failure (ALF) and most cases of severely decompensated liver disease cannot benefit from medical treatment and bear a very high mortality rate, therefore LT is the only option. Dhawan *et al.* [29] have proposed a score predictive of death or transplantation in ALF presenting patients that was prospectively validated both in children and in adults (Table 4). In patients with disease progression under medical treatment, LT must be considered after ruling out insufficient drug dosage or non-compliance. Indication and timing should follow the common criteria adopted for evaluating ESLD. Survival rates after LT for WD are excellent (Table 5) [30–35]. Although LT corrects the underlying copper metabolism defect, whether or not LT is indicated in patients with predominantly neurologic manifestations is controversial. From a pathophysiology point of view, the removal of copper from the brain should avoid further cerebral damage, however, existing cerebral dysfunctions usually do not resolve before approximately 6 months

post-LT [36]. In 56–77% of the cases, complete recovery is possible [31,37]. However, severe worsening has been documented after LT and the survival in the presence of combined neuropsychiatric manifestations is significantly lower than that of recipients with sole liver disease. Therefore, in LT candidates presenting with the combination of ESLD and severe neuropsychiatric symptoms, a thorough specific neuropsychiatric evaluation is mandatory [31,37,38].

Living donor LT from heterozygous-carrier relatives represents a safe and effective option particularly in children with ALF [39]. Good survivals with persistent normalization of copper metabolism in the long-term have been reported [40].

### Hereditary hemochromatosis

Under the term hereditary hemochromatosis (HH) are included several inherited disorder of iron metabolism, characterised by enhanced intestinal absorption of dietary iron [41]. The prevalence of HH is about 0.5% with a carrier frequency of approximately 10% [42–44]. Four types are currently identified according to the involved gene mutation (Table 2). Type 1 is by far the most common and most well defined form of HH in the western countries, it is secondary to the homozygosity for the C282Y *HFE* gene and it corresponds to classical HH phenotype. The other types are rarer and less known genetic conditions involved in the regulation of iron homeostasis. All mutations are autosomal recessive, except for type 4, which is inherited as autosomal dominant. Types 1, 3, and 4 manifest in adulthood and usually during the fourth or fifth decade of life, whereas the clinical onset of type 2 occurs earlier, in the second or third decade, with a much more severe phenotype. Indeed, in type 2, endocrine and cardiac involvement is paramount, and heart failure is a frequent cause of death before the age of 30 years [42–45].

The specific role of the liver in HH was not clear for a long time. The iron-regulatory peptide-hormone hepcidin has been recently identified as the missing link between the liver and intestine in the pathogenesis of iron accumulation. It is now widely accepted that the primary defect of *HFE*-associated HH is within the liver. Isolated cases of inadvertent transplantation of a liver from an HH donor were reported: progressive iron overload has been shown to occur within the second year post-LT, as assessed by liver biopsy and extensive iron studies documented the absence of a secondary cause of iron overload, supporting a primary role of liver rather than small intestine in the regulation of iron homeostasis in HH [46].

Increased intestinal iron absorption causes iron overload as a result of uptake of non-transferrin bound iron from hepatocytes, miocytes, and endocrine gland cells. Without therapeutic intervention, iron overload leads to multiple organ damage, involving primarily the liver and subsequently heart, pancreas, gonads, skin, and joints: the clinical manifestations are cirrhosis, cardiomyopathy, diabetes, arthritis, hypogonadism, and skin pigmentation. Iron overload cardiomyopathy (IOC) is rare in type 1 HH but evident in as much as one third of the type 2 juvenile cases and is characterised by the development of diastolic left ventricular (LV) dysfunction with restrictive filling or LV remodelling with heart chamber dilatation and reduced LV ejection fraction [47].

Transferrin saturation is widely considered the preferred screening test. Liver biopsy with tissue iron quantification used to be the gold standard for the diagnosis of HH before *HFE*

**Table 2. Examples of diseases amenable to OLT as surgical gene therapy.**

Disorder	Gene symbol	Inheritance	Mechanism of disease	Deficient enzyme	Tissue specificity <sup>o</sup>	Liver features	Clinical features	
Wilson's disease	<i>ATP7B</i>	AR	Accumulation of intracellular hepatic copper	Copper-transport P-type ATPase	Liver, kidney	Hepatomegaly, acute liver failure hepatitis, cirrhosis, hepatic coma	Neuro-psychiatric abnormalities	
Hereditary hemochromatosis	Type 1	<i>HFE</i>	AR	Involved in hepcidin synthesis via BMP6, interaction with TFR1	Hemochromatosis modifier (C282Y H63D)	Expressed in all tissues tested except brain	Hepatomegaly Cirrhosis Hepatocellular carcinoma	Arthropathy, skin pigmentation, liver damage, hypogonadism, diabetes, endocrine dysfunction, cardiomyopathy Like HFE with onset <30 years old
	Type 2A	<i>JH</i>	AR	Involved in hepcidin synthesis, BMP co-receptor	Hemojuvelin			
	Type 2B	<i>HAMP</i>	AR	Down regulation of iron efflux from enterocytes	Hepcidin			
	Type 3	<i>TFR2</i>	AR	Involved in hepcidin synthesis, interaction with transferrin	Transferrin receptor 2			
	Type 4	<i>SLC40A1</i>	AD	Altered duodenal iron export	Ferroportin			
Tyrosinemia type 1	<i>FAH</i>	AR	Lack of tyrosine degradation	Fumarylacetoacetate hydrolase (FAH)	Liver, kidney	Hepatomegaly, acute liver failure, cirrhosis, hepatocellular carcinoma	Secondary renal tubular dysfunction (hypophosphatemic rickets), episodic weakness, self-mutilation, seizures	
$\alpha$ -1 antitrypsin deficiency	<i>PI</i>	AR	Lack of inhibitory action against neutrophil elastase	Protease inhibitor	Plasma	Cirrhosis Hepatocellular carcinoma	Emphysema, which becomes evident by the third to fourth decade	
Urea cycle disorders	NAGS deficiency	<i>NAGS</i>	AR	Error of metabolism of the urea cycle with ammonia production	N-acetyl glutamate synthetase	Liver, intestinal mucosa	Near normal liver architecture in acute presentation.	Somnolence, tachypnea, feeding difficulties, failure to thrive, hyperammonemia (due to high-protein diet or febrile illness) Protein intolerance, intermittent ataxia, seizures, lethargy and mental retardation
	CPS I deficiency	<i>CPS</i>	AR		Carbamoyl phosphate synthetase			
	OTC deficiency	<i>OTC</i>	XR		Ornithine transcarbamylase			
	Argininosuccinic aciduria	<i>ASL</i>	AR		Argininosuccinate lyase			
	Argininemia	<i>ARG</i>	AR		Arginase			
	Citrullinemia	<i>ASS</i>	AR		Argininosuccinate synthetase			
Criggler Najjar syndrome	Type 1	<i>UGT1A1</i>	AR, AD	Impairment of bilirubin glucuronide conjugation	Uridine diphosphate glucuronosyltransferase	Liver	Normal liver architecture	Unconjugated hyperbilirubinaemia
TTR-familial amyloid polyneuropathy	TTR1-FAP	<i>TTR</i>	AD	Deposit of insoluble protein fibrils in the extracellular matrix	Transthyretin	Liver, retina, choroid plexus	Normal liver architecture	Polyneuropathy, autonomic insufficiency, cardiomyopathy, renal insufficiency gastrointestinal disorders
Primary hyperoxaluria	Type I	<i>AGXT</i>	AR	Calcium oxalate accumulation in tissues	Alanine-glyoxylate-aminotransferase	Liver	Normal liver architecture	Nephrolithiasis, renal failure
Atypical haemolytic uremic syndrome	aHUS1	<i>CFH</i>	AR, AD	Thrombotic microangiopathy, activation of the complement system	Complement factor H	Liver	Normal liver architecture	Acute renal failure, hypertension, neurologic abnormalities

OMIM, Online Mendelian Inheritance in Man (Adapted from Seashore 2009); AR, autosomal recessive; XR, X-linked recessive; AD, autosomal dominant.

<sup>o</sup>UniProt Consortium <http://www.uniprot.org/>.



**Table 3. Diagnosis of Wilson's disease: tests and diagnostic score.**

Test	Diagnostic confidence	
Baseline 24-h urinary copper excretion	>100 µg: WD very likely 40-100 µg: WD possible <40 µg: WD very unlikely	
24 h urinary copper excretion following penicillamine challenge (500 mg 12 h apart in the previous day)	>1600 µg/24 h: WD very likely <500 µg/24 h: WD very unlikely	
Serum copper	Low in asymptomatic cases High in active liver disease and haemolytic phase	
Serum ceruloplasmine	<0.2 g/L: WD very likely (95% of subjects) >0.25 g/L: WD very unlikely	
KF rings	If present WD very likely (requires expert evaluation)	
Liver copper	>250 µg/g of dry weight: WD likely <50 µg/g of dry weight: WD ruled out	
Biochemical indices	Raised AST, ALT, bilirubin, INR. Normal or low ALP Haemolysis in acute phase/ALF	
Mutations in <i>ATP7B</i> gene	Confirmed diagnosis in homozygous or compound heterozygous subjects (more than 200 mutations)	

Ferenci score			
<b>Liver copper</b> (in absence of cholestasis)		<b>Serum ceruloplasmine</b>	
<50 µg/g (normal)	-1	>0.2 g/L (normal)	0
<5 x ULN (50-250 µg/g)	1	0.1-0.2 g/L	1
>5 x ULN (250 µg/g)	2	<0.1 g/L	2
<b>Rhodianine stain</b> (in absence of quantitative liver copper determination)		<b>Coomb's negative haemolytic anaemia</b>	
absent	0	Present	1
present	1	Absent	0
<b>Mutation analysis</b>		<b>KF rings</b>	
2 chromosomes mutations	4	Present	2
1 chromosome mutation	1	Absent	0
no mutation detected	0		
<b>Urinary copper</b> (in absence of acute hepatitis)		<b>Neurologic symptoms</b>	
normal (<0.9 µmol/d or <100 µg/d)	0	Severe	2
1-2 x ULN	1	Mild	1
>2 x ULN	2	Absent	0
normal but >5 x ULN after penicillamine	2		

Total score ≥4: diagnostic for WD.

Score ≥2 <4: "likely to have WD but more investigations to be performed".

Score <2: diagnosis of WD improbable.

genotyping became available. After ruling out secondary causes of iron overload, in the presence of elevated serum iron and ferritin with transferrin saturation greater than 50%, *HFE* gene evaluation is the preferred test to confirm the diagnosis of HH [48,49].

The first-line treatment of iron overload in HH is based on phlebotomies. This treatment is simple, effective and safe [50]. In patients with evolution in ESLD despite iron chelation or depletion, LT is the ultimate solution and can cure both the genetic defect and liver disease [34,51,52]. In patients presenting with severe ESLD as a result of HH, phlebotomies can rarely be carried out, mainly due to hypersplenism-related anaemia or haemodynamic instability. Overall, only a minority of HH patients (approximately 1%) will eventually undergo LT [48]. Several possible explanations can be found: (a) in the largest US multicentre study, the majority of patients undergoing LT with HH were not identified prior to transplantation, highlighting that the condition is underdiagnosed, mainly due to the confounding fact that a great number of cirrhotic patients present elevated

serum iron and ferritin levels unrelated to HH; (b) the onset of clinical manifestations usually occurs in the 4th or 5th decade of life and progression to ESLD can eventually occur when patients are beyond the age for LT; (c) these patients are at high risk for HCC development (220-fold increase compared with the general population) [53] with clinical onset often beyond eligibility criteria for LT, especially when the patient is not under regular ultrasound follow-up because unaware of the condition.

An extensive cardiac evaluation prior to transplantation should be performed in all HH candidates. However, cardiac complications might occur despite extensive work-up and an ideal evaluation algorithm has not been defined yet. HH patients with severe cardiac dysfunction (NYHA class II) might benefit from a combined heart and liver transplantation (CHLT) [54].

In most initial series, survival post-LT was significantly lower among patients with HH [51,55,56] and in a large study from the United Network for Organ Sharing (UNOS) database, LT recipients with HH had a hazard ratio for death of 2.6 ( $p < 0.002$ ) after

**Table 4. King's College acute failure Wilson's disease prognostic index.**

Score	Bilirubin (mg/dl)	INR	AST (IU/L)	WBC (x 10 <sup>9</sup> /L)	Albumin (g/dl)
0	0-5.8	0-1.2	0-100	0-6.7	>4.5
1	5.9-8.8	1.3-1.6	101-150	6.8-8.3	3.4-4.4
2	8.9-11.7	1.7-1.9	151-300	8.4-10.3	2.5-3.3
3	11.8-17.6	2.0-2.4	301-400	10.4-15.3	2.1-2.4
4	>17.6	>2.4	>400	>15.4	<2.0

Adapted from Dhawan *et al.*, 2005.  
A score >11 points PPV 92% NPV 97% for death or OLT.

adjustment for age, UNOS status, and year of transplantation [57], probably as a result of inadequate patient selection. However, recent studies showed that 3-month, 1- and 5-year survival rates were 90%, 80.7%, and 74%, respectively, better than previously reported (Table 5) [57–60]. The main causes of death after LT are infections (45%) and cardiac complications (22%) [57,59]. A review by Tung and colleagues demonstrated that in a series of 37 patients undergoing LT for HH, cardiac events were the cause

of 22% of the 23 post-LT deaths, mostly occurring after the first post-LT year [61].

There have been conflicting reports on whether or not iron reaccumulates after LT. In series of patients who underwent LT for HH, nearly all recipients had persistently normal serum transferrin saturation and ferritin values post-LT [58,62]. On the other hand, hepatic iron overload is associated with poorer post-LT outcome irrespective of the underlying cause: recipients with and without *HFE* gene mutations had similarly reduced post-LT survival compared to a matched group without iron overload [52].

Indeed, a poor outcome after LT has been shown in subsets of liver transplant recipients with iron overload not associated with *HFE* gene mutations [56,63].

*Tyrosinemia type 1*

Tyrosinemia type 1 (TT1) is an autosomal recessive metabolic disorder characterised by the deficiency of the enzyme fumarylacetoacetate hydrolase (FAH) involved in the final step of the catabolism of tyrosine and phenylalanine (Table 2) [64]. The

**Table 5. Examples of published series of OLT in monogenic diseases.**

Disease	Author, yr	No. of pts	Age at OLT (yr) range	Tx type	Follow-up mean/range	Survival (%)	
						1 yr	5 yr
Wilson's disease	Bellary <i>et al.</i> , 1995	39	23 (± 1.5)	WLDD	4.3 yr (3 mo-10 yr)	79.4	
	Medici <i>et al.</i> , 2005	36	27.5 (1.5-56)	WLDD	64.6 mo (2-152)	89.1	75.6
	Arnon <i>et al.</i> , 2011	170	14.3 (4-18)	WLDD = 146 PLDD = 24	n.a.	90.1	89.0
	Arnon <i>et al.</i> , 2011	400	31.7 (19-68)	WLDD = 388 PLDD = 12	n.a.	88.3	86.0
Hereditary hemochromatosis	Crawford <i>et al.</i> , 2004	26	54.3 (39-64)	n.a.	3.6 yr (1-9)	72.0	55.0
	Kowdley <i>et al.</i> , 2005	22	50.6 (± 10.2)	WLDD	n.a.	64.0	34.0
	Dar <i>et al.</i> , 2009	22	55 (30-72)	WLDD = 21 PLDD = 1	46 mo (12-213)	80.7	74.0
	Yu <i>et al.</i> , 2007	217	54.7 (± 9.0)	WLDD	n.a. (1-10 yr)	86.1	77.3
Tyrosinemia type 1	Arnon <i>et al.</i> , 2011	125	2.5 (± 3.6)	WLDD = 91 PLDD = 19 LD = 15	n.a.	90.4	90.4
	Herzog <i>et al.</i> , 2006	27	2.9 (0.5-14.8)	n.a.	6 yr (1-14)	n.a.	n.a.
	Mohan <i>et al.</i> , 1999	8	5.3 (0.5-10.5)	WLDD	6.7 yr (1-7)	75.0	
Alpha-1-antitrypsin deficiency	Hughes <i>et al.</i> , 2011	35	6.0 (n.a.)	WLDD = 34 LD = 1	≈10 yr (n.a.)	82.7	76.5
	Jain <i>et al.</i> , 2010	9	49.9 (± 7.09)	WLDD	36 mo (n.a.)	100	
	Kemmer <i>et al.</i> , 2008	22	3 (0.5-17)	n.a.	n.a.	89.0	83.0
	Prachalias <i>et al.</i> , 2000	21	3 (0.6-15)	WLDD = 14, PLDD = 11	40 mo (n.a.)	100	
Urea cycle disorders	Morioka <i>et al.</i> , 2005*	51	14.4 (0.1-62)	WLDD = 20 PLDD = 5 LD = 26	10 yr	93.7	91.3
	Wakiya <i>et al.</i> , 2011	12	3.6 (0.8-11.7)	LD = 12	29.2 mo (3-97)	91.7	
	Whittington <i>et al.</i> , 1998	16		WLDD = 16	0.9-6 yr	87.5	
	Kasahara <i>et al.</i> , 2010	5	1 (0.3-2.6)	LD = 5	26.8 mo (12-48)	100	
Crigler Najjar syndrome	Van der Veere <i>et al.</i> , 1996*	21	9.1 (1-23)	WLDD = 18 APOLT = 3	11.4 yr (4-24)	95.2	
	Rela <i>et al.</i> , 1999	6	11.1 (8-18)	APOLT = 6	35 mo (23-59)	83.3	
	Gridelli <i>et al.</i> , 1997	5	8.6 (4-15)	WLDD = 5	30.2 mo (11-62)	100	
TTR-familial amyloid polyneuropathy	Bittencourt <i>et al.</i> , 2002	24	36 (25-52)	n.a.	36 mo (14-82)	70	58
	Herlenius <i>et al.</i> , 2004	539	40.6 ± 10.8 (21-69)	LD = 25	>1 yr	77-90 <sup>a</sup>	77
Primary hyper-oxaluria type 1	Bergstralh <i>et al.</i> , 2010	26	25.3 ± 17.4	CLKT	1.3 yr (0.3-3.2) <sup>b</sup>	-	67

\*Includes previously published series.

<sup>a</sup>1990–1994 vs. 1995–2000 period.

<sup>b</sup>yr median (25th, 75th).

WLDD, whole deceased donor liver; PLDD, partial deceased donor liver; n.a., not available; LD, living donor; APOLT, auxiliary partial orthotopic liver transplant; CLKT, combined liver-kidney transplant.

## Frontiers in Liver Transplantation

incidence of TT1 ranges from 1:100,000 to 1:120,000, but can be higher in specific areas, such as Scandinavia and Quebec, where it has been reported to be as high as 1 in 1846 live births [65]. The deficient enzymatic activity causes the formation and subsequent accumulation of toxic metabolites, such as fumarylacetoacetate and maleylacetoacetate (Supplementary Fig. 1). A by-product is succinylacetone whose presence in the urine is the hallmark of the disease. These toxic metabolites (and particularly fumarylacetoacetate) have been shown to induce apoptosis of both hepatocytes and kidney tubular epithelial cells. The alkylating properties of the toxic metabolites can affect particularly hepatocytes DNA, increasing the risk of HCC. TT1 presents either as acute or chronic form. The acute form usually presents within the 3rd or 4th month of life, and is characterised by ALF during the first year. The chronic form is characterised by failure to thrive, hepatomegaly and chronic liver disease, renal tubular dysfunction (Fanconi-like syndrome), rickets, cardiomyopathy, porphyria-like neurological syndrome with severe muscle pain and waste, extensor hypertonia, vomiting, ileus [66]. The incidence of HCC development is high and its onset rapid. At diagnosis alpha-fetoprotein is almost invariably greater than 30,000 ng/ml and should be utilised as a marker for suspicion.

A major step in the management of TT1 has been achieved with the introduction of 2-(2-nitro-4-trifluoromethylbenzoyl)-1-3-cyclohexenedione (NTBC) in 1992: this compound halts the second step of tyrosine catabolism avoiding the accumulation of toxic metabolites [67]. A combination of tyrosine- and phenylalanine-free diet plus NTBC warrants major improvements in both liver and kidney function, nutritional status and avoids the occurrence of porphyria-like syndrome episodes [68]. NTBC protects from development of HCC especially when started within the first 6 months of life. Since the introduction in clinical practice of NTBC, the need for LT in TT1 patients has dropped from 35% to 12% [69]. The present indication for LT includes: (a) patients who failed the first-line medical treatment based on diet and NTBC; (b) onset of ALF unresponsive to medical treatment; (c) HCC or, in some cases, evidence of histologically-proven dysplastic nodule in the liver. The risk of development of HCC is so high in patients with a nodular cirrhotic liver that early transplantation might be considered cost-effective; (d) poor quality of life and/or chronic liver/kidney dysfunction under severe restriction diet in medical therapy.

LT does not completely cure the enzymatic deficiency, since renal FAH deficiency is not corrected by LT [70]. In the pre NTBC era, combined liver-kidney transplant (CLKT) was indicated, but nowadays, the kidney-sparing effect of NTBC has completely changed the scenario. Isolated LT is usually performed, with 1-year survival higher than 88% in most series (Table 5) [71–73]. In selected cases, low-doses NTBC treatment is required post-LT. Heterozygous relatives are not affected by the disease and they can act as living donors in tyrosinaemia as well as in other monogenic recessive conditions.

### Alpha-1-antitrypsin deficiency

Alpha-1-antitrypsin (AAT) is the most common protease inhibitor present in human plasma and is a member of the serine protease supergene family (Table 2) [74]. AAT protects tissues from proteases such as neutrophil elastase. AAT is encoded by a gene located on the long arm of chromosome 14. The glycoprotein is synthesized within the liver. The phenotype PiMM (protease inhibitor

MM) is present in about 95% of the population and is associated with normal serum levels of AAT. Several mutations have been described, the most common disease-related alleles being PiZ (Glu342Lys) and PiS (Glu264Val) that result in reduced circulating levels of AAT (15% and 60%, respectively) [75]. AAT deficiency (AATD) is a condition characterised by both liver and lung injury. The incidence of the mutation ranges between 1:2500 live birth in Europe to 1:1500 in USA [76]. The PiZZ phenotype has been associated with liver disease in childhood. A prospective nationwide screening study initiated more than 20 years ago in Sweden has shown that significant liver disease develops in only 10–15% of children with a PiZZ phenotype, suggesting that this condition represents a strong predisposition rather than the sole cause of liver disease in these subjects [77]. Persistence of jaundice, paucity of bile ducts, severe fibrosis, and portal hypertension beyond 6 months are indicators of a poor prognosis. However, around 6–10% of PiZZ subjects develop signs of liver disease in late infancy or childhood, without any history of neonatal jaundice. The heterozygous state does not cause liver disease *per se*, but behaves as a cofactor in the presence of other conditions such as hepatitis C virus infection, non-alcoholic fatty liver disease, or cryptogenic cirrhosis. An estimated 10% of adults will eventually develop cirrhosis along their life [78]. The pathophysiology of liver disease is not fully elucidated as yet, but it is likely due to the accumulation and subsequent polymerization of the mutant AAT protein in the endoplasmic reticulum of the hepatocyte, as revealed by the typical periodic acid Schiff–positive granules seen on light microscopy. Patients with cirrhosis secondary to AATD are at high risk of development of HCC. The diagnosis of AATD can be made by either AAT genotyping or phenotyping, but cannot rely on AAT serum levels as they can be falsely elevated in several inflammatory conditions, tumours, pregnancy, and in case of oestrogen supplementation.

The lack of circulating AAT exposes the lungs to proteolytic attack by neutrophil elastase and therefore predisposes the PiZZ patients to early-onset emphysema. In the lungs, the alveolar tissue, unprotected from destruction by the proteolytic aggression of neutrophil elastase, will eventually collapse and cause early emphysema with chronic obstructive airway disease [79].

The indication for LT in AATD is either ESLD or HCC and not the lung disease. However, LT not only cures the ESLD but also prevents the development of lung disease later in life as the recipient develops the Pi phenotype of the donor. Differently from other metabolic disorders, prognosis and timing for LT of AATD-related ESLD can rely on PELD/MELD scoring systems (Pediatric End-stage Liver Disease/Model for End-stage Liver Disease). In most paediatric cases, LT is postponed in late childhood as a result of relapse of jaundice or development of cirrhosis with portal hypertension [80]. In some patients, though, LT might be needed before the age of two years. In adults, the development of cirrhosis and its complication usually occurs in the 4th or 5th decade, frequently in the presence of cofactors such as chronic viral hepatitis, non-alcoholic or alcoholic hepatitis. Overall survival for children and adults are reported over 90% and 80%, respectively (Table 5) [80–83].

### Monogenic diseases with primary hepatic expression without significant parenchymal damage

Liver-based genetic disorders in which the liver structure is not impaired are part of this group of monogenic diseases. Genetic



mutations affect a specific hepatic function with prevalent extrahepatic manifestations. Owing to the limited availability of donor livers, transplantation of hepatocytes, whether genetically modified or not, has been proposed as an alternative to LT for the treatment of such conditions. However, while hepatocyte transplantation can be safely employed in humans, its applicability remains limited and still technical difficult [84,85].

The rationale of using LT to replace an organ that is structurally normal except for a specific pathway raises questions about indications, timing, and priority.

In these conditions, two different special techniques, namely domino liver transplantation (DLT) and auxiliary partial orthotopic liver transplantation (APOLT), can represent an option [86]. In DLT the native liver, removed from a patient with the metabolic disorder, is transplanted into another patient with a different disease, thus increasing the organ pool. This option can be used: (a) when the expected interval before the onset of the metabolic disease in the recipient is longer or at least not significantly shorter than the expected survival with LT; (b) when the genetic defect in the transplanted liver is expected to be compensated by recipient's extrahepatic organs carrying the appropriate gene; and (c) as a bridge, waiting for a second transplantation. DLT has mainly been performed with the liver of patients with familial amyloid polyneuropathy (FAP), although *de novo* FAP development has been described even earlier than expected (2–9 years) in DLT recipients [86,87]. The technique can also be performed with livers of patients with maple syrup urine disease and familial hypercholesterolemia, whereas unsatisfactory results have been reported in primary hyperoxaluria [86].

In APOLT, only a part of the liver with the genetic disorder is removed and replaced with a segmental graft from a deceased or living donor. The rationale for this approach is that the segment of the liver carrying the wild type gene is sufficient to synthesise enough enzyme to correct the metabolic defect, while leaving a segment of the native liver may effectively support the patient's life in case of failure of the graft. Encouraging results with APOLT have been reported in patients with various metabolic disorders (i.e., Crigler Najjar syndrome, urea cycle disorders) [88].

Living donor LT from parents or other relatives may present the advantage of optimal timing and has been successfully used, particularly in situations where deceased donation is problematic [89]. The issue of possible latent disorder in the donor's liver is crucial in this setting. Heterozygous healthy carriers can be safely used as donors in most disorder. Ornithine transcarbamylase deficiency is an exception and evidence of normal tissue enzymatic activity should be obtained before using heterozygotes females as donors for transplantation for this disease [90,91].

#### Urea cycle disorders

The urea cycle comprises a series of metabolic pathways by which ammonia is detoxified and converted into excretory non-toxic compounds [92]. These pathways are located mainly or exclusively within the hepatocytes (Supplementary Fig. 2). Enzymatic defects result in accumulation of nitrogenous waste which are highly neurotoxic [93]. Urea cycle disorders (UCD) have an incidence of about 1:20,000. UCD are named for the 2 initial steps of the pathway, involving the deficiency of carbamyl phosphate synthetase (CPS), and ornithine transcarbamylase (OTC). The other 3 disorders are named after the specific metabolite

detected in affected individuals: citrullinemia (ASS), argininosuccinic aciduria (ASL), and argininemia (ARG1) (Table 2). The clinical presentation is similar in all types of UCD, but the severity of symptoms varies widely between and within the various forms: from a lethal neonatal form to almost asymptomatic adults [94]. The major symptoms are due to hyperammonemia. Ammonia levels >200  $\mu\text{mol/L}$  increase the risk for cerebral oedema, while during decompensation, ammonia can reach levels >1000  $\mu\text{mol/L}$ , that are almost invariably associated with irreversible cerebral damage. Neonates with UCD may present within hours/days from birth with a severe illness characterised by anorexia, hypothermia, poor feeding, tachypnea, vomiting, dystonia, irritability or lethargy with rapid progression to coma [95]. The prognosis of early onset UCD is usually poor despite prompt and aggressive treatment, which must include: (1) direct removal of ammonia by means of continuous hemofiltration or dialysis; (2) limitation of protein breakdown by reversal of the catabolic state by a hypercaloric, low-protein diet with essential amino acids and arginine supplementation; (3) pharmacologic detoxification of nitrate excess.

Long-term management includes strict dietary natural animal protein restriction, combined with essential amino acids supplementation [96]. Oral administration of sodium phenyl butyrate, sodium phenyl acetate or sodium benzoate (the former is more palatable and converts to phenyl acetate *in vivo*) and nocturnal enteral nutrition are often required. Even with very careful and proper management of the disease, episodes of acute hyperammonemia might not be completely prevented, especially during intercurrent illness [97]. Patients with recurrent and severe episodes of hyperammonemia can suffer from devastating neurological sequelae and LT is indicated in such cases to prevent their development [98,99].

In male newborns with severe onset OTC deficiency, LT is the only procedure warranting long-term survival and protection from irreversible brain damage. Since the metabolic defect is located mainly within the liver, LT is curative, providing complete resolution of hyperammonemia within 24 hours from the procedure [89]. Quality of life can be improved in almost all recipients, although neurologic sequelae might remain in some individuals, mainly in severely impaired children [100]. Apart from neonatal onset of OTC deficiency which represents a clear indication for LT, in all other UCD conditions the indication is based on the failure to maintain metabolic compensation with medical treatment and therefore it remains a "case by case" decision. Survival rates with unrestricted diet are reported as 93.8% and 90% at 1 and 5 years post-LT, respectively (Table 5) [89,100–102].

#### Crigler Najjar syndrome

Crigler-Najjar syndrome (CN) is a rare, autosomal recessive disorder of bilirubin metabolism that has been divided into two distinct forms based upon the severity of jaundice: type I disease (CN1) is associated with severe jaundice and high risk of neurologic sequelae (kernicterus); type II disease (CN2) is associated with a lower serum bilirubin concentration and no risk for kernicterus throughout the whole life [103]. Jaundice in CN is due to a variety of alterations in the coding sequences of the bilirubin-uridine diphosphate glucuronosyltransferase (*UGT1A1*) gene, which is responsible for bilirubin conjugation [104]. These mutations lead to the total loss or reduced levels of *UGT1A1* activity respectively in CN1 and CN2. The hallmark of CN1 is

## Frontiers in Liver Transplantation

unconjugated hyperbilirubinemia in the range of 20–25 mg/dl, but can reach values as high as 50 mg/dl [105]. Unlike CN1, CN2 has no indication for LT since it is characterised by bilirubin levels below 20 mg/dl, and therefore compatible with a normal life, although during intercurrent illnesses, bilirubin levels can raise in both (Table 2).

Serum bilirubin concentration can be reduced by the administration of phenobarbital (60–120 mg for 14 days) in most patients with CN2 but not CN1 disease, providing also a helpful tool to differentiate the two conditions [106]. Although several drugs have proven effective to slightly reduce jaundice through the reduction of intestinal reuptake of bilirubin (calcium carbonate and orlistat), the medical management of CN1 relies mainly on phototherapy that acts by converting bilirubin into its isomers, which are excreted in the bile without the need for conjugation [107,108]. Patients with CN1 requires the exposure to fluorescent lamps for at least 12 hours/day, but around the pubertal age thickening of the skin, increased skin pigmentation, and decreased surface area in relation to body mass render this technique less effective, increasing the risk of kernicterus [109]. In an animal model, the Gunn rat, a normal bilirubin-UGT gene can be introduced in the diseased liver by autologous transplantation of cells transduced with the normal gene *ex vivo*, by *in situ* perfusion or systemic administration of vectors that are capable of carrying the gene to the liver [110]. Nevertheless both long-term efficacy and safety of gene therapy for CN1 are not yet established.

Since as little as 5% of the liver mass can reduce bilirubin levels down to near normal values, allogeneic hepatocyte transplantation (AHT) has been attempted in children with CN1 [111]. However, the beneficial effect of AHT lasts no longer than 3 years, making LT mandatory to control the disease [38]. LT remains the ultimate treatment of CN1 [112]. Deciding the best timing for transplantation is challenging in these patients [113]. Even though it is a general rule to try to postpone as much as possible surgery and exposure of children to immunosuppressive drugs, it must be considered that control of jaundice in CN1 can become less and less effective over the years, raising the risk of kernicterus. In the 1996 report of the CN world registry, the mean age at transplantation was 9.1 years. Overall, brain damage developed in 26% of patients. Remarkably, the age of patients with and without brain damage at LT was 14.3 and 5.9 years, respectively (Table 5) [107,114,115]. Nowadays, more effective tools to control jaundice have certainly developed. However, despite a different response to non-surgical treatments can allow tailoring the decisions in these patients, older age, inconsistent family compliance to phototherapy, and intercurrent illnesses remain major threats to neurological integrity in CN1 patients managed conservatively, especially when the levels of bilirubin remain steadily above 25 mg/dl.

### *Transthyretin-type familial amyloid polyneuropathy*

Transthyretin-type familial amyloid polyneuropathy (TTR-FAP) is a rare adult-onset progressive degenerative disorder characterised by extracellular amyloid fibril formation with polymerized TTR systemic accumulation. The condition is inherited as an autosomal dominant trait and is now described worldwide [116]. Reports of about 100 different mutations or deletions in the TTR gene have been published, and several different phenotypes documented. It is also assumed that non-genetic factors must play a role in the molecular mechanisms of the disease [117]. TTR is a

127-residue protein that transports thyroxin in the blood and cerebrospinal fluid. Plasma TTR is predominantly synthesised by the liver and mutated forms of TTR are the precursor protein of amyloid fibre and amorphous aggregates in patients' tissues. The clinical manifestations are mainly represented by progressive polyneuropathy associated with sensory loss, motor weakness, and autonomic dysfunction. In the final stages, cachectic and incontinent patients die from renal insufficiency, metabolic imbalance, arrhythmia, or infections [118] (Table 2). TTR-FAP was long considered a fatal illness and palliation of systemic manifestations represented the only available option. A number of drugs able to stabilise TTR or inhibit fibril formation have been investigated. Currently, the most promising is tafamidis [119]. Liver tissue of TTR-FAP patients has normal structure and function, except for the production of amyloidogenic variant TTR.

As the liver produces most of the amyloidogenic TTR in serum, it was assumed that the replacement of a liver expressing an abnormal TTR gene should stop the production of the variant TTR. Since the first operation in 1990, LT has become an accepted treatment of this disorder. Transplanted patients have significantly prolonged survival compared with the non-transplanted ones [120]. The outcome is generally favourable for those with an early onset of the disease (age at onset <50 years) (Table 5) [121,122]. Although LT is life-saving for patients with TTR-FAP, long-term progression of systemic organ involvement has been recently observed in a significant number of LT recipients [123,124]. Re-evaluation of recent LT series have shown unforeseen heart complications, affecting mortality and morbidity [125]. The development of post-LT cardiomyopathy seems to be related to TTR-fibril composition and to age at onset of the disease [126,127]. Although favourable outcomes have been described in patients with the most common TTR mutation V30M, in patients with other mutations, outcomes have been worse due to progression of cardiac amyloidosis [128]. LT must be proposed to the symptomatic patients as early as possible. High incidence of thrombotic complications, mainly hepatic artery thrombosis, has been reported in the early post-operative phases [129]. CHLT has been performed in few cases [123,130,131].

### *Primary hyperoxaluria type 1*

The most severe form of primary hyperoxaluria is type 1 (PH1) due to a deficiency of the liver peroxisomal enzyme alanine:glyoxylate-aminotransferase (AGXT), which catalyses the conversion of glyoxylate to glycine. When AGXT activity is absent, glyoxylate is converted to oxalate, which forms insoluble calcium salts that accumulate in the kidney and other organs [132]. As glomerular filtration rate decreases to less than 25 ml/min/1.73 m<sup>2</sup>, the daily production of oxalate far outstrips renal oxalate clearance, resulting in a rapid decline in residual renal function with a concurrent increase in systemic oxalate storage (oxalosis) [133]. The prevalence of PH1 ranges from one to three in 1,000,000 [134,135]. PH1 often remains underdiagnosed because of the wide variability in both clinical presentation and age at onset [136]. The natural history of untreated PH1 is one of inexorable decline in renal function as a result of progressive nephrolithiasis/nephrocalcinosis, with eventual progression to end stage renal disease (ESRD) and/or complications of systemic oxalosis [133,137,138] (Table 2).

Early diagnosis and initiation of supportive therapies with hydration and crystallisation inhibitors are critical in allowing long lasting renal survival [139]. Approximately 10–30% of individuals with PH1 respond to treatment with pyridoxine [140]. Among these, 40% show normalisation and the remainders only a partial reduction of oxalate concentrations [141]. As neither maintenance haemodialysis nor peritoneal dialysis clear oxalate quickly enough to prevent systemic oxalosis, organ transplantation is the only potential cure for PH1 [142].

Much discussion has occurred regarding the best transplantation strategy for an individual with PH1. Isolated kidney transplantation restores oxalate excretion to normal, but is associated with a high rate of recurrence and in many cases early graft loss [137,138,140]. Pre-emptive LT before ESRD and systemic oxalosis is an attractive approach for individuals with PH1, as replacing the liver offers the possibility of correcting the metabolic defect. The optimal timing of this approach is still controversial, being based on highly variable GFR cut-off values (from 40 to 80 ml/min/1.73 m<sup>2</sup>) [143–146]. During LT procedure, patients with severe systemic oxalosis are at high risk of both haemodynamic and septic complications due to poor responsiveness to inotropes. CLKT from a single donor is the preferred option when GFR is below 40 ml/min/1.73 m<sup>2</sup>, however, a sequential procedure may be technically advantageous in infants. Excellent outcome data from the International Primary Hyperoxaluria Registry have been reported (Table 5). Comparing isolated kidney transplantation to CLKT, 5-year kidney graft survival was 45% vs. 64% ( $p = 0.10$ ), respectively, but death-censored graft survival was 45% vs. 78% ( $p = 0.003$ ). Delay in PH diagnosis until after transplant favoured early kidney graft loss [147].

#### *Atypical haemolytic uremic syndrome 1*

Haemolytic uremic syndrome (HUS) – the most frequent cause of acute renal failure in children – usually follows infection with *Escherichia coli* (so called typical HUS) and about 95% of patients have a favourable outlook. Atypical HUS (aHUS) is much less common and has a considerably worse prognosis in terms of both mortality and development of ESRD [148]. It is now established that aHUS is often associated with mutations in genes encoding complement regulatory proteins and secondary disorders of complement regulation. Of the genes in which mutations are known to be associated with aHUS, *CFH* (encoding complement factor H) is the most common, accounting for 30% of cases, also known as *aHUS1*. Irrespective of the pattern of inheritance, aHUS1 occurs at all ages. The clinical course is characterised by a high rate of relapse and a 60–80% rate death or ESRD following the presenting episode or as a consequence of relapse. Conditions that trigger complement activation precipitate the acute event in approximately 60% of cases [149] (Table 2).

The mortality rate for aHUS dropped from 50% to 25% after plasma manipulation (plasma infusion or exchange) was introduced [150]. In published studies, some patients with aHUS1 did not respond at all to plasma therapy and died or developed ESRD. Others required infusion of plasma at weekly intervals in order to raise CFH plasma levels enough to maintain remission [151]. In the Bergamo cohort [149], approximately 60% of patients with aHUS1 treated with plasma underwent either complete or partial remission. However, the remaining patients did not respond at all to plasma and 20% died during the acute episode. More recently, case reports and two phase II trials have

shown an impressive efficacy of eculizumab, a human monoclonal antibody directed against the complement protein C5, that is now considered the standard of care [152].

It is generally accepted that renal transplantation is an effective and safe treatment for patients with *E. coli*-associated HUS who have progressed to ESRD. By contrast, in patients with aHUS1, the kidney graft outcome is poor. Recurrence rate ranges from 30% to 100% and is significantly higher than in patients without CFH mutations [153,154]. Interpretation of these results is facilitated by the knowledge that CFH is a plasma protein that is produced nearly exclusively by the liver. Thus, a kidney transplant will not correct the CFH genetic defect in these patients. CLKT was first performed in Bergamo in a child with aHUS1 [155]. Kidney function promptly recovered, while, after an initial improvement, liver function progressively deteriorated with severe hepatic encephalopathy. A second uneventful LT was undertaken a few days later, nevertheless, the neurologic abnormalities only partially improved. On subsequent follow-up, the child had no sign of disease recurrence but died 3 years later as a result of the neurologic sequelae [156]. Regardless of the unfortunate outcome, this was the first evidence that aHUS1 could be cured by CLKT. The clinical course of the second reported case was also complicated by irreversible liver failure with a fatal outcome just after transplantation [157]. After these initial reports, a modified approach to CLKT was successfully applied in few cases [158–160]. The pivotal modification was to exchange large quantities of plasma before transplantation and during the procedure. This both increased the bioavailability of functional factor H during the critical period needed for the liver graft to recover synthetic functions and, at the same time, removed the endogenous mutant CFH [156]. Since then, CLKT has been regarded as a viable therapeutic option for patients with aHUS1 resulting in ESRD, and ideally also for patients with mutations of other factors synthesised in the liver [161]. Isolated pre-emptive LT has been first performed in 2002 in a child with aHUS1 and preserved renal function despite severe recurrent episodes. At that time, the transplant protocol did not include plasma therapy and the child died 11 months after transplantation from repeated infections, lymphoproliferative disease, and some signs of HUS recurrence during infections [162]. More recently, a second child with aHUS1 underwent successful pre-emptive LT [163]. Outcome of LT in patients with aHUS1 is reported in Table 6. Hopefully, emerging therapies with complement inhibitors will allow successful kidney only transplantation in the near future.

#### **Monogenic diseases with both hepatic and extrahepatic expression**

In this group of monogenic diseases, the enzymatic defect is ubiquitous, the liver is one among several targets for systemic injury and LT has been generally considered as an enzyme replacement treatment. In these disorders, LT is not curative since the abnormal phenotype is partially maintained by extrahepatic synthesis of the toxic metabolites. Indeed, the experience of LT in this group of monogenic diseases is scant, the results quite poor and the indications far from being established.

#### *Organic acidurias*

The organic acidurias (OA) are part of a family of inborn errors of organic acid metabolism, characterised by the excretion of

**Table 6. Outcome of OLT performed in patients with atypical haemolytic uremic syndrome 1.**

Study (Author, year)	Pa-tient	Sex	Age at HUS onset	Time be-tween HUS and dialysis	Age at Tx	Tx Type	Graft failure	Reason for failure	Disease recurrence	Follow-up of functioning grafts/ outcome
Remuzzi G <i>et al.</i> , 2002	1	M	6 mo	<6 mo	2 yr	CLKT	Liver 1: Yes  Liver 2: No Kidney: No	Humoral hyperacute rejection at day 26, liver retransplantation few days later	No	Death 3 years after CLKT for neurologic sequelae
Cheong HI <i>et al.</i> , 2004	2	M	3 mo	Preserved renal function	2.5 yr	preOLT	No		Signs of HUS recurrence during infections	Death 11 months post-OLT (infections, lymphoproliferative disease)
Remuzzi G <i>et al.</i> , 2005	3	F	13 mo	<6 mo	2 yr	CLKT	Liver: Yes Kidney: ?	Early acute liver failure	No	Death on day 3rd for cardiocirculatory failure
Saland JM <i>et al.</i> , 2006, Saland JM <i>et al.</i> , 2009	4	M	4 mo	Within weeks	5.5 yr	CLKT	No		No	>4 yr
Jalanko H <i>et al.</i> , 2008	5	M	12 mo	2 mo	18 mo	CLKT	No		No	15 mo
Koskinen AR <i>et al.</i> , 2011	6	F	16 yr	Within weeks	16.5 yr	CLKT	No		No	4 yr
Saland JM <i>et al.</i> , 2009	7	M	9 mo	Preserved renal function	4 yr	CLKT	No		No	21 mo
Haller W <i>et al.</i> , 2010	8	M	5.5 mo	Preserved renal function	5 yr	preOLT	No		No	2 yr
Wilson C <i>et al.</i> , 2011	9	M	62 yr	Within days	65 yr	CLKT	No		No	1 yr
Koskinen AR <i>et al.</i> , 2011	10	M	21 yr	<6 mo	22 yr	CLKT	No		No	3 yr

CLKT, combined liver-kidney transplantations; preOLT, pre-emptive liver transplantation.

**Table 7. Features of organic acidurias.**

Disorder	Deficient enzyme	Gene achronimous	Mechanisms of disease	Clinical features	Risk of metabolic crisis at OLT	Enzymatic correction with OLT	
Maple syrup urine disease (MSUD)	Type IA	<i>BCKDHA</i>	Deficit of catalytic components of the branched-chain alpha-ketoacid dehydrogenase complex	Maple syrup odour. Lethargy, altering hypotonia and hypertonia, hyperammonemia typically absent, ketosis	High	Good	
	Type IB	Branched-chain ketoacid dehydrogenase (leucine, isoleucine, valine)*					<i>BCKDHB</i>
	Type II						<i>DBT</i>
Propionic acidemia	Type I	Propionyl CoA carboxylase	Excessive deamination of branched-chain amino acids in muscle	Vomiting, lethargy, hyperammonemia, developmental retardation, neutropenia, acidosis, ketosis,	High	Moderate	
	Type II	(isoleucine, valine, methionine, threonine)*					<i>PCCB</i>
Methylmalonic academia (MMA)	Methylmalonyl CoA mutase (isoleucine, valine, methionine, threonine)*	<i>MUT</i>	Disorder of methylmalonate and cobalamin leading to methylmalonyl CoA accumulation in the body	Toxic encephalopathy, hyperammonemia vomiting, failure to thrive, neutropenia, acidosis, ketosis	High	Poor	

non-amino organic acids in urine. The majority of the organic acidurias are caused by a systemic deficient enzymatic activity involved in the catabolism of the branched-chain amino acids (BCAA) leucine, isoleucine, and valine [164]. The clinical phenotype of OA is dependent on the type of enzymatic defect and on the degree of residual enzymatic activity. The clinical picture of OA is the consequence of the accumulation of toxic compounds into brain, liver, kidney, pancreas, retina, and other organs. The typical presentation is that of a newborn who, after initial feeding, within few days develops an intoxication type of metabolic derangement with encephalopathy, vomiting, poor feeding, seizures, dystonia, cerebral oedema with lethargy, and progression to coma, often misdiagnosed as sepsis. The outcome is strongly influenced by a rapid diagnosis and prompt removal of neurotoxins by means of continuous hemofiltration or dialysis [165]. In the older infant or adolescent, variant clinical forms of OA can present with poor intellectual performance, ataxia, Reyes syndrome, recurrent ketoacidosis or psychiatric symptoms.

Most OA are managed by dietary treatment aimed at restoring biochemical and physiological homeostasis. The strategy is based on both dietary restriction of the precursor amino acids and use of compounds that remove toxic metabolites [166]. Despite a correct long-term dietary management, patients with OA remain at high risk of metabolic decompensation (because of intercurrent concomitant illnesses, fasting or temporary reduction in caloric intake), and often fatal acute pancreatitis [167].

Among OA, LT has been proposed for maple syrup urine disease (MSUD), methylmalonic acidemia (MMA) and propionic acidemia (PA), with uneven results. In these conditions, the pre-transplant protocol appears to be vital to protect from severe perioperative decompensation and long-term sequelae (Table 7).

**MSUD**

Strauss has reported on 11 children transplanted at a median age of 6.3 years, with an accurate pre-LT management. After 14-month follow-up, all patients were well, with low plasma leucine levels under unrestricted diet [168]. The experience made

so far suggests that LT can provide a good metabolic control in MSUD.

**MMA**

Kasahara reported on 18 children, median age 20 months, median follow-up 36 months, who received LT for recurrent metabolic decompensation. Five patients had a CLKT; 8 had preparatory perioperative haemodialysis to reduce serum MMA. After LT, mortality was 17% and morbidity 38% (renal failure and neurological disability). Levels of methylmalonic acid decreased but not enough to avoid ongoing renal and neurological damage. Patients who received a CLKT had a better metabolic control after the procedure [169]. In another series reported by Morioka, seven children with MMA received a living donor LT, of whom 1 died and the remainders were alive at 10-month follow-up. The requirement of metabolism-correcting medications remained unchanged after LT, whereas protein restriction was liberalised and tube feeding became unnecessary [170].

**PA**

A series of 12 children with PA who received an LT at a median age of 24 months has been reported by Barshes. After 12-month follow-up, survival on unrestricted diet was 72%. After LT, the patients showed a clear neurological improvement on unrestricted diet [171]. In more recent reports, a good metabolic control and improved quality of life without protein restriction and medication post-LT were documented in 8 recipients, although urinary metabolites methylcitrate and serum propionylcarnitine did not decrease markedly [172,173]. In one of these patients, it was possible to maintain good metabolic control in the long term by APOLT [174].

In OA, LT can only correct the enzymatic deficiency in the liver, while the widespread diffusion of the specific metabolic deficit in other organ systems may maintain a significant production of toxic compounds, particularly in central nervous system and kidneys [168,175]. The experience made so far suggests that LT is able to provide a good metabolic control only in MSUD,

Frontiers in Liver Transplantation



# Frontiers in Liver Transplantation

whereas its indication is questioned in PA and mostly discouraged in MMA.

## Key Points

- Monogenic diseases affect approximately 10 out of 1000 births and represent a frequent cause of mortality, especially in the paediatric population. Effective treatments are rarely available and organ transplantation remains the standard option for a variety of life threatening conditions
- Liver transplantation offers a curative approach in monogenic diseases with primary hepatic expression and parenchymal damage, as well as in liver-based genetic disorders with prevalent extra-hepatic manifestations
- When the genetic defect is ubiquitous and the liver is one among several targets for systemic injury, results of liver transplantation are quite poor and indications less clearly established
- Characterization of genetic diseases allows to better address the comorbidities, may influence selection of organ transplant candidates and donors and improves governance of postoperative complications.
- Different transplantation strategies are driven by the understanding of the phenotypic expression of the genetic defect

## Conclusions

The concept of gene therapy has long appealed to biomedical researchers and clinicians because of its promise to correct the basis defect of genetic diseases. The disease targets for gene therapy are multiple, but the most promising preclinical data come from monogenic disorders. Nevertheless, although data so far demonstrated a potential role for gene therapy in a wide range of animal models of human diseases, the clinical efficacy in humans remains elusive even after decades of trial experience in patients with disease such as ornithine transcarbamylase deficiency, haemophilia caused by factor IX deficiency, as well as brain tumours, colon cancer and mesothelioma. Adverse effects of gene therapy have been also observed because it is based on viral vectors that retain some of their pathogenic potential. First generation of vectors triggered a dose-dependent induction of both innate and adaptive immune responses, which have not only limited the duration of the gene expression, but have also resulted in severe inflammatory toxicity in some patients, causing at least one death in a patient with partial ornithine transcarbamylase deficiency. Thus, the future remains uncertain regarding the ultimate clinical impact that gene therapy will have in single gene or multifactorial gene diseases. Meanwhile, organ transplantation for monogenic diseases that involve the liver remains the most suitable and cost-effective approach, also considering the very high cost of innovative drugs/biologics recently proposed as possible treatment. While awaiting the maturity of gene therapy, liver transplantation may continue to be seen as a surrogate sort of gene therapy holding the potential of alleviating the suffering of many patients with monogenic diseases of

organs in which the abnormal responsible proteins are produced nearly exclusively by the liver.

## Conflict of interest

The authors declared that they do not have anything to disclose regarding funding or conflict of interest with respect to this manuscript.

## Acknowledgments

The authors thank Dr. Vincent Karam, PhD (Clinical Data Manager of the European Liver Transplant Registry – Paul Brousse Hospital Hepatobiliary Center) for his kindness in providing the ELTR data set shown in Fig. 1; Dr. Arrigo Schieppati, MD who revised the manuscript, and Monica Lena for writing assistance.

## Supplementary data

Supplementary data associated with this article can be found, in the online version, at <http://dx.doi.org/10.1016/j.jhep.2013.04.004>.

## References

- [1] Online Mendelian Inheritance in Man; 2012.
- [2] Genes and human disease. Monogenic diseases; 2012.
- [3] Dye DE, Brameld KJ, Maxwell S, Goldblatt J, Bower C, Leonard H, et al. The impact of single gene and chromosomal disorders on hospital admissions of children and adolescents: a population-based study. *Public Health Genomics* 2011;14:153–161.
- [4] Dye DE, Brameld KJ, Maxwell S, Goldblatt J, O'Leary P. The impact of single gene and chromosomal disorders on hospital admissions in an adult population. *J Community Genet* 2011;2:81–90.
- [5] O'Malley M, Hutcheon RG. Genetic disorders and congenital malformations in pediatric long-term care. *J Am Med Dir Assoc* 2007;8:332–334.
- [6] Cunniff C, Carmack JL, Kirby RS, Fiser DH. Contribution of heritable disorders to mortality in the pediatric intensive care unit. *Pediatrics* 1995;95:678–681.
- [7] Stevenson DA, Carey JC. Contribution of malformations and genetic disorders to mortality in a children's hospital. *Am J Med Genet A* 2004;126A:393–397.
- [8] Lachmann RH. Enzyme replacement therapy for lysosomal storage diseases. *Curr Opin Pediatr* 2011;23:588–593.
- [9] Bordignon C, Notarangelo LD, Nobili N, Ferrari G, Casorati G, Panina P, et al. Gene therapy in peripheral blood lymphocytes and bone marrow for ADA-immunodeficient patients. *Science* 1995;270:470–475.
- [10] Fischer A, Cavazzana-Calvo M. Gene therapy of inherited diseases. *Lancet* 2008;371:2044–2047.
- [11] Zhang KY, Tung BY, Kowdley KV. Liver transplantation for metabolic liver diseases. *Clin Liver Dis* 2007;11:265–281.
- [12] Davit-Spraul A, Gonzales E, Baussan C, Jacquemin E. Progressive familial intrahepatic cholestasis. *Orphanet J Rare Dis* 2009;4:1.
- [13] Englert C, Grabhorn E, Richter A, Rogiers X, Burdelski M, Ganschow R. Liver transplantation in children with progressive familial intrahepatic cholestasis. *Transplantation* 2007;84:1361–1363.
- [14] Romano F, Stroppa P, Bravi M, Casotti V, Lucianetti A, Guizzetti M, et al. Favorable outcome of primary liver transplantation in children with cirrhosis and hepatocellular carcinoma. *Pediatr Transplant* 2011;15:573–579.
- [15] Lykavieiris P, van Mil S, Creteil D, Fabre M, Hadchouel M, Klomp L, et al. Progressive familial intrahepatic cholestasis type 1 and extrahepatic features: no catch-up of stature growth, exacerbation of diarrhea, and appearance of liver steatosis after liver transplantation. *J Hepatol* 2003;39:447–452.

- [16] Alagille D, Estrada A, Hadchouel M, Gautier M, Odievre M, Dommergues JP. Syndromic paucity of interlobular bile ducts (Alagille syndrome or arteriohepatic dysplasia): review of 80 cases. *J Pediatr* 1987;110:195–200.
- [17] Emerick KM, Rand EB, Goldmuntz E, Krantz ID, Spinner NB, Piccoli DA. Features of Alagille syndrome in 92 patients: frequency and relation to prognosis. *Hepatology* 1999;29:822–829.
- [18] Lykavieris P, Hadchouel M, Chardot C, Bernard O. Outcome of liver disease in children with Alagille syndrome: a study of 163 patients. *Gut* 2001;49:431–435.
- [19] Kamath BM, Yin W, Miller H, Anand R, Rand EB, Alonso E, et al. Outcomes of liver transplantation for patients with Alagille syndrome: the studies of pediatric liver transplantation experience. *Liver Transpl* 2012;18:940–948.
- [20] Figus A, Angius A, Loudianos G, Bertini C, Dessi V, Loi A, et al. Molecular pathology and haplotype analysis of Wilson disease in Mediterranean populations. *Am J Hum Genet* 1995;57:1318–1324.
- [21] European Association for Study of Liver. EASL Clinical Practice Guidelines: Wilson's disease. *J Hepatol* 2012;56:671–685.
- [22] Stremmel W, Meyerrose KW, Niederau C, Heffer H, Kreuzpaintner G, Strohmeyer G. Wilson disease: clinical presentation, treatment, and survival. *Ann Intern Med* 1991;115:720–726.
- [23] Ferenci P, Caca K, Loudianos G, Mieli-Vergani G, Tanner S, Sternlieb I, et al. Diagnosis and phenotypic classification of Wilson disease. *Liver Int* 2003;23:139–142.
- [24] Sternlieb I. Perspectives on Wilson's disease. *Hepatology* 1990;12:1234–1239.
- [25] Walshe JM, Yealland M. Chelation treatment of neurological Wilson's disease. *Q J Med* 1993;86:197–204.
- [26] Dahlman T, Hartvig P, Lofholm M, Nordlinder H, Loof L, Westermark K. Long-term treatment of Wilson's disease with triethylene tetramine dihydrochloride (trientine). *QJM* 1995;88:609–616.
- [27] Brewer GJ, Hedera P, Kluin KJ, Carlson M, Askari F, Dick RB, et al. Treatment of Wilson disease with ammonium tetrathiomolybdate: III. Initial therapy in a total of 55 neurologically affected patients and follow-up with zinc therapy. *Arch Neurol* 2003;60:379–385.
- [28] Medici V, Trevisan CP, D'Inca R, Barollo M, Zancan L, Fagioli S, et al. Diagnosis and management of Wilson's disease: results of a single center experience. *J Clin Gastroenterol* 2006;40:936–941.
- [29] Dhawan A, Taylor RM, Cheeseman P, De Silva P, Katsiyiannakis L, Mieli-Vergani G. Wilson's disease in children: 37-year experience and revised King's score for liver transplantation. *Liver Transpl* 2005;11:441–448.
- [30] Bellary S, Hassanein T, Van Thiel DH. Liver transplantation for Wilson's disease. *J Hepatol* 1995;23:373–381.
- [31] Medici V, Mirante VG, Fassati LR, Pompili M, Forti D, Del Gaudio M, et al. Liver transplantation for Wilson's disease: the burden of neurological and psychiatric disorders. *Liver Transpl* 2005;11:1056–1063.
- [32] Arnon R, Annunziato R, Schilsky M, Miloh T, Willis A, Sturdevant M, et al. Liver transplantation for children with Wilson disease: comparison of outcomes between children and adults. *Clin Transplant* 2011;25:E52–E60.
- [33] Podgaetz E, Chan C. Liver transplantation for Wilson's disease: our experience with review of the literature. *Ann Hepatol* 2003;2:131–134.
- [34] Fagioli S, Mirante VG, Pompili M, Gianni S, Leandro G, Rapaccini GL, et al. Liver transplantation: the Italian experience. *Dig Liver Dis* 2002;34:640–648.
- [35] Sutcliffe RP, Maguire DD, Muesan P, Dhawan A, Mieli-Vergani G, O'Grady JG, et al. Liver transplantation for Wilson's disease: long-term results and quality-of-life assessment. *Transplantation* 2003;75:1003–1006.
- [36] Schumacher G, Platz KP, Mueller AR, Neuhaus R, Steinmuller T, Bechstein WO, et al. Liver transplantation: treatment of choice for hepatic and neurological manifestation of Wilson's disease. *Clin Transplant* 1997;11:217–224.
- [37] Lui CC, Chen CL, Cheng YF, Lee TY. Recovery of neurological deficits in a case of Wilson's disease after liver transplantation. *Transplant Proc* 1998;30:3324–3325.
- [38] Ambrosino G, Varotto S, Strom SC, Guariso G, Franchin E, Miotto D, et al. Isolated hepatocyte transplantation for Crigler-Najjar syndrome type 1. *Cell Transplant* 2005;14:151–157.
- [39] Asonuma K, Inomata Y, Kasahara M, Uemoto S, Egawa H, Fujita S, et al. Living related liver transplantation from heterozygote genetic carriers to children with Wilson's disease. *Pediatr Transplant* 1999;3:201–205.
- [40] Yoshitoshi EY, Takada Y, Oike F, Sakamoto S, Ogawa K, Kanazawa H, et al. Long-term outcomes for 32 cases of Wilson's disease after living-donor liver transplantation. *Transplantation* 2009;87:261–267.
- [41] Ajioka RS, Kushner JP. Hereditary hemochromatosis. *Semin Hematol* 2002;39:235–241.
- [42] Pietrangelo A. Hereditary hemochromatosis: pathogenesis, diagnosis, and treatment. *Gastroenterology* 2010;139:393–408, 408, e391–e392.
- [43] Pietrangelo A. Hepcidin in human iron disorders: therapeutic implications. *J Hepatol* 2011;54:173–181.
- [44] Santos PC, Krieger JE, Pereira AC. Molecular diagnostic and pathogenesis of hereditary hemochromatosis. *Int J Mol Sci* 2012;13:1497–1511.
- [45] Mura C, Raguenes O, Ferec C. HFE mutations analysis in 711 hemochromatosis probands: evidence for S65C implication in mild form of hemochromatosis. *Blood* 1999;93:2502–2505.
- [46] Dwyer JP, Sarwar S, Egan B, Nolan N, Hegarty J. Hepatic iron overload following liver transplantation of a C282y homozygous allograft: a case report and literature review. *Liver Int* 2011;31:1589–1592.
- [47] Kremastinos DT, Farmakis D. Iron overload cardiomyopathy in clinical practice. *Circulation* 2011;124:2253–2263.
- [48] European Association for the Study of the Liver. EASL clinical practice guidelines for HFE hemochromatosis. *J Hepatol* 2010;53:3–22.
- [49] Moyer TP, Highsmith WE, Smyrk TC, Gross Jr JB. Hereditary hemochromatosis: laboratory evaluation. *Clin Chim Acta* 2011;412:1485–1492.
- [50] Powell LW. Hemochromatosis: the impact of early diagnosis and therapy. *Gastroenterology* 1996;110:1304–1307.
- [51] Kowdley KV, Hassanein T, Kaur S, Farrell FJ, Van Thiel DH, Keeffe EB, et al. Primary liver cancer and survival in patients undergoing liver transplantation for hemochromatosis. *Liver Transpl Surg* 1995;1:237–241.
- [52] Brandhagen DJ. Liver transplantation for hereditary hemochromatosis. *Liver Transpl* 2001;7:663–672.
- [53] Niederau C, Fischer R, Sonnenberg A, Stremmel W, Trampisch HJ, Strohmeyer G. Survival and causes of death in cirrhotic and in noncirrhotic patients with primary hemochromatosis. *N Engl J Med* 1985;313:1256–1262.
- [54] Raichlin E, Daly RC, Rosen CB, McGregor CG, Charlton MR, Frantz RP, et al. Combined heart and liver transplantation: a single-center experience. *Transplantation* 2009;88:219–225.
- [55] Brandhagen DJ, Alvarez W, Therneau TM, Kruckeberg KE, Thibodeau SN, Ludwig J, et al. Iron overload in cirrhosis-HFE genotypes and outcome after liver transplantation. *Hepatology* 2000;31:456–460.
- [56] Farrell FJ, Nguyen M, Woodley S, Imperial JC, Garcia-Kennedy R, Man K, et al. Outcome of liver transplantation in patients with hemochromatosis. *Hepatology* 1994;20:404–410.
- [57] Kowdley KV, Brandhagen DJ, Gish RG, Bass NM, Weinstein J, Schilsky ML, et al. Survival after liver transplantation in patients with hepatic iron overload: the national hemochromatosis transplant registry. *Gastroenterology* 2005;129:494–503.
- [58] Crawford DH, Fletcher LM, Hubscher SG, Stuart KA, Gane E, Angus PW, et al. Patient and graft survival after liver transplantation for hereditary hemochromatosis: implications for pathogenesis. *Hepatology* 2004;39:1655–1662.
- [59] Dar FS, Faraj W, Zaman MB, Bartlett A, Bomford A, O'Sullivan A, et al. Outcome of liver transplantation in hereditary hemochromatosis. *Transpl Int* 2009;22:717–724.
- [60] Yu L, Ioannou GN. Survival of liver transplant recipients with hemochromatosis in the United States. *Gastroenterology* 2007;133:489–495.
- [61] Tung BY, Farrell FJ, McCashland TM, Gish RG, Bacon BR, Keeffe EB, et al. Long-term follow-up after liver transplantation in patients with hepatic iron overload. *Liver Transpl Surg* 1999;5:369–374.
- [62] Stuart KA, Fletcher LM, Clouston AD, Lynch SV, Purdie DM, Kerlin P, et al. Increased hepatic iron and cirrhosis: no evidence for an adverse effect on patient outcome following liver transplantation. *Hepatology* 2000;32:1200–1207.
- [63] Fenton H, Torbenson M, Vivekanandan P, Yeh MM, Hart J, Ferrell L. Marked iron in liver explants in the absence of major hereditary hemochromatosis gene defects: a risk factor for cardiac failure. *Transplantation* 2009;87:1256–1260.
- [64] Lindblad B, Lindstedt S, Steen G. On the enzymic defects in hereditary tyrosinemia. *Proc Natl Acad Sci U S A* 1977;74:4641–4645.
- [65] De Braekeleer M, Larochelle J. Genetic epidemiology of hereditary tyrosinemia in Quebec and in Saguenay-Lac-St-Jean. *Am J Hum Genet* 1990;47:302–307.
- [66] Mitchell G, Larochelle J, Lambert M, Michaud J, Grenier A, Ogier H, et al. Neurologic crises in hereditary tyrosinemia. *N Engl J Med* 1990;322:432–437.
- [67] Lindstedt S, Holme E, Lock EA, Hjalmarson O, Strandvik B. Treatment of hereditary tyrosinaemia type I by inhibition of 4-hydroxyphenylpyruvate dioxygenase. *Lancet* 1992;340:813–817.

- [68] Masurel-Paulet A, Poggi-Bach J, Rolland MO, Bernard O, Guffon N, Dobbelaere D, et al. NTBC treatment in tyrosinaemia type I: long-term outcome in French patients. *J Inher Metab Dis* 2008;31:81–87.
- [69] Paradis K. Tyrosinemia: the Quebec experience. *Clin Invest Med* 1996;19:311–316.
- [70] Laine J, Salo MK, Krogerus L, Karkkainen J, Wahlroos O, Holmberg C. The nephropathy of type I tyrosinemia after liver transplantation. *Pediatr Res* 1995;37:640–645.
- [71] Aron R, Annunziato R, Miloh T, Wasserstein M, Sogawa H, Wilson M, et al. Liver transplantation for hereditary tyrosinemia type I: analysis of the UNOS database. *Pediatr Transplant* 2011;15:400–405.
- [72] Herzog D, Martin S, Turpin S, Alvarez F. Normal glomerular filtration rate in long-term follow-up of children after orthotopic liver transplantation. *Transplantation* 2006;81:672–677.
- [73] Mohan N, McKiernan P, Preece MA, Green A, Buckels J, Mayer AD, et al. Indications and outcome of liver transplantation in tyrosinaemia type I. *Eur J Pediatr* 1999;158:S49–S54.
- [74] Alagille D. Alpha-1-antitrypsin deficiency. *Hepatology* 1984;4:115–145.
- [75] Mahadeva R, Chang WS, Dafforn TR, Oakley DJ, Foreman RC, Calvin J, et al. Heteropolymerization of S, I, and Z alpha1-antitrypsin and liver cirrhosis. *J Clin Invest* 1999;103:999–1006.
- [76] Sveger T. Liver disease in alpha1-antitrypsin deficiency detected by screening of 200,000 infants. *N Engl J Med* 1976;294:1316–1321.
- [77] Sveger T, Eriksson S. The liver in adolescents with alpha 1-antitrypsin deficiency. *Hepatology* 1995;22:514–517.
- [78] Fregonese L, Stolk J. Hereditary alpha-1-antitrypsin deficiency and its clinical consequences. *Orphanet J Rare Dis* 2008;3:16.
- [79] Parfrey H, Mahadeva R, Lomas DA. Alpha(1)-antitrypsin deficiency, liver disease and emphysema. *Int J Biochem Cell Biol* 2003;35:1009–1014.
- [80] Prachalias AA, Kalife M, Francavilla R, Muiesan P, Dhawan A, Baker A, et al. Liver transplantation for alpha-1-antitrypsin deficiency in children. *Transpl Int* 2000;13:207–210.
- [81] Hughes Jr MG, Khan KM, Gruessner AC, Sharp H, Hill M, Jie T, et al. Long-term outcome in 42 pediatric liver transplant patients with alpha 1-antitrypsin deficiency: a single-center experience. *Clin Transplant* 2011;25:731–736.
- [82] Jain AB, Patil V, Sheikh B, Apostolakis M, Ryan C, Kashyap R, et al. Effect of liver transplant on pulmonary functions in adult patients with alpha 1 antitrypsin deficiency: 7 cases. *Exp Clin Transplant* 2010;8:4–8.
- [83] Kemmer N, Kaiser T, Zacharias V, Neff GW. Alpha-1-antitrypsin deficiency: outcomes after liver transplantation. *Transplant Proc* 2008;40:1492–1494.
- [84] Soltys KA, Soto-Gutierrez A, Nagaya M, Baskin KM, Deutsch M, Ito R, et al. Barriers to the successful treatment of liver disease by hepatocyte transplantation. *J Hepatol* 2010;53:769–774.
- [85] Hughes RD, Mitry RR, Dhawan A. Current status of hepatocyte transplantation. *Transplantation* 2012;93:342–347.
- [86] Popescu I, Dima SO. Domino liver transplantation: how far can we push the paradigm? *Liver Transpl* 2012;18:22–28.
- [87] Adams D, Lacroix C, Antonini T, Lozeron P, Denier C, Kreib AM, et al. Symptomatic and proven de novo amyloid polyneuropathy in familial amyloid polyneuropathy domino liver recipients. *Amyloid* 2011;18:174–177.
- [88] Cirià R, Davila D, Heaton N. Auxiliary liver transplantation in children. *Curr Opin Organ Transplant* 2011;16:489–493.
- [89] Morioka D, Kasahara M, Takada Y, Corrales JP, Yoshizawa A, Sakamoto S, et al. Living donor liver transplantation for pediatric patients with inheritable metabolic disorders. *Am J Transplant* 2005;5:2754–2763.
- [90] Wong DA. Ornithine transcarbamylase deficiency: are carrier females suitable donors? *Pediatr Transplant* 2012;16:525–527.
- [91] Wakiya T, Sanada Y, Urahashi T, Ihara Y, Yamada N, Okada N, et al. Living donor liver transplantation from an asymptomatic mother who was a carrier for ornithine transcarbamylase deficiency. *Pediatr Transplant* 2012;16:E196–E200.
- [92] Summar M. Urea cycle disorders. In: Sucky FJ, Sokol RJ, Balistreri WF, editors. *Liver disease in children*, 3rd ed. Frederick J. Suchy, Ronald J. Sokol, William F. Balistreri. Cambridge University Press:Cambridge; 2007.
- [93] Tuchman M. The clinical, biochemical, and molecular spectrum of ornithine transcarbamylase deficiency. *J Lab Clin Med* 1992;120:836–850.
- [94] Bachmann C. Outcome and survival of 88 patients with urea cycle disorders: a retrospective evaluation. *Eur J Pediatr* 2003;162:410–416.
- [95] Endo F, Matsuura T, Yanagita K, Matsuda I. Clinical manifestations of inborn errors of the urea cycle and related metabolic disorders during childhood. *J Nutr* 2004;134:1605S–1609S, discussion 1630S–1632S, 1667S–1672S.
- [96] Maestri NE, Brusilow SW, Clissold DB, Bassett SS. Long-term treatment of girls with ornithine transcarbamylase deficiency. *N Engl J Med* 1996;335:855–859.
- [97] Lee B, Goss J. Long-term correction of urea cycle disorders. *J Pediatr* 2001;138:S62–S71.
- [98] Leonard JV, McKiernan PJ. The role of liver transplantation in urea cycle disorders. *Mol Genet Metab* 2004;81:S74–S78.
- [99] Campeau PM, Pivalizza PJ, Miller G, McBride K, Karpen S, Goss J, et al. Early orthotopic liver transplantation in urea cycle defects: follow up of a developmental outcome study. *Mol Genet Metab* 2010;100:S84–S87.
- [100] Whittington PF, Alonso EM, Boyle JT, Molleston JP, Rosenthal P, Emond JC, et al. Liver transplantation for the treatment of urea cycle disorders. *J Inher Metab Dis* 1998;21:112–118.
- [101] Wakiya T, Sanada Y, Mizuta K, Umehara M, Urahashi T, Egami S, et al. Living donor liver transplantation for ornithine transcarbamylase deficiency. *Pediatr Transplant* 2011;15:390–395.
- [102] Kasahara M, Sakamoto S, Shigeta T, Fukuda A, Kosaki R, Nakazawa A, et al. Living-donor liver transplantation for carbamoyl phosphate synthetase I deficiency. *Pediatr Transplant* 2010;14:1036–1040.
- [103] Crigler Jr JF, Najjar VA. Congenital familial nonhemolytic jaundice with kernicterus. *Pediatrics* 1952;10:169–180.
- [104] Kadakol A, Ghosh SS, Sappal BS, Sharma G, Chowdhury JR, Chowdhury NR. Genetic lesions of bilirubin uridine-diphosphoglucuronate glucuronosyltransferase (UGT1A1) causing Crigler-Najjar and Gilbert syndromes: correlation of genotype to phenotype. *Hum Mutat* 2000;16:297–306.
- [105] Slesinger MH. Nonhemolytic unconjugated hyperbilirubinemia with hepatic glucuronyl transferase deficiency: a genetic study in four generations. *Trans Assoc Am Physicians* 1967;80:259–266.
- [106] Arias IM, Gartner LM, Cohen M, Ezzer JB, Levi AJ. Chronic nonhemolytic unconjugated hyperbilirubinemia with glucuronyl transferase deficiency. Clinical, biochemical, pharmacologic and genetic evidence for heterogeneity. *Am J Med* 1969;47:395–409.
- [107] van der Veere CN, Sinaasappel M, McDonagh AF, Rosenthal P, Labrune P, Odievre M, et al. Current therapy for Crigler-Najjar syndrome type 1: report of a world registry. *Hepatology* 1996;24:311–315.
- [108] Nishioka T, Hafkamp AM, Havinga R, Vn Lierop PP, Velvis H, Verkade HJ. Orlistat treatment increases fecal bilirubin excretion and decreases plasma bilirubin concentrations in hyperbilirubinemic Gunn rats. *J Pediatr* 2003;143:327–334.
- [109] Lund HT, Jacobsen J. Influence of phototherapy on the biliary bilirubin excretion pattern in newborn infants with hyperbilirubinemia. *J Pediatr* 1974;85:262–267.
- [110] Toietta G, Mane VP, Norona WS, Finegold MJ, Ng P, McDonagh AF, et al. Lifelong elimination of hyperbilirubinemia in the Gunn rat with a single injection of helper-dependent adenoviral vector. *Proc Natl Acad Sci U S A* 2005;102:3930–3935.
- [111] Fox JJ, Chowdhury JR, Kaufman SS, Goertzen TC, Chowdhury NR, Warkentin PI, et al. Treatment of the Crigler-Najjar syndrome type I with hepatocyte transplantation. *N Engl J Med* 1998;338:1422–1426.
- [112] Pett S, Mowat AP. Crigler-Najjar syndrome types I and II. Clinical experience—King's College Hospital 1972–1978. Phenobarbitone, phototherapy and liver transplantation. *Mol Aspects Med* 1987;9:473–482.
- [113] Sokal EM, Silva ES, Hermans D, Reding R, De Ville de Goyet J, Buts JP, et al. Orthotopic liver transplantation for Crigler-Najjar type I disease in six children. *Transplantation* 1995;60:1095–1098.
- [114] Gridelli B, Lucianetti A, Gatti S, Colledan M, Benti R, Bruno A, et al. Orthotopic liver transplantation for Crigler-Najjar type I syndrome. *Transplant Proc* 1997;29:440–441.
- [115] Rela M, Muiesan P, Vilca-Melendez H, Dhawan A, Baker A, Mieli-Vergani G, et al. Auxiliary partial orthotopic liver transplantation for Crigler-Najjar syndrome type I. *Ann Surg* 1999;229:565–569.
- [116] Araki S, Ando Y. Transthyretin-related familial amyloidotic polyneuropathy—Progress in Kumamoto, Japan (1967–2010). *Proc Jpn Acad Ser B Phys Biol Sci* 2010;86:694–706.
- [117] da Costa G, Gomes RA, Guerreiro A, Mateus E, Monteiro E, Barroso E, et al. Beyond genetic factors in familial amyloidotic polyneuropathy: protein glycation and the loss of fibrinogen's chaperone activity. *PLoS One* 2011;6:e24850.
- [118] Coelho T. Familial amyloid polyneuropathy: new developments in genetics and treatment. *Curr Opin Neurol* 1996;9:355–359.
- [119] de Carvalho M. Is it better than it seems or just good enough? The tafamidis saga. *Muscle Nerve* 2012.
- [120] Yamashita T, Ando Y, Okamoto S, Misumi Y, Hirahara T, Ueda M, et al. Long-term survival after liver transplantation in patients with familial amyloid polyneuropathy. *Neurology* 2012;78:637–643.



- [121] Bittencourt PL, Couto CA, Farias AQ, Marchiori P, Bosco Massarollo PC, Mies S. Results of liver transplantation for familial amyloid polyneuropathy type I in Brazil. *Liver Transpl* 2002;8:34–39.
- [122] Herlenius G, Wilczek HE, Larsson M, Ericzon BG. Ten years of international experience with liver transplantation for familial amyloidotic polyneuropathy: results from the Familial Amyloidotic Polyneuropathy World Transplant Registry. *Transplantation* 2004;77:64–71.
- [123] Barreiros AP, Post F, Hoppe-Lotichius M, Linke RP, Vahl CF, Schafers HJ, et al. Liver transplantation and combined liver-heart transplantation in patients with familial amyloid polyneuropathy: a single-center experience. *Liver Transpl* 2010;16:314–323.
- [124] Ohya Y, Okamoto S, Tasaki M, Ueda M, Jono H, Obayashi K, et al. Manifestations of transthyretin-related familial amyloidotic polyneuropathy: long-term follow-up of Japanese patients after liver transplantation. *Surg Today* 2011;41:1211–1218.
- [125] Wiklund U, Hornsten R, Olofsson BO, Suhr OB. Cardiac autonomic function does not improve after liver transplantation for familial amyloidotic polyneuropathy. *Auton Neurosci* 2010;156:124–130.
- [126] Gustafsson S, Ihse E, Henein MY, Westermark P, Lindqvist P, Suhr OB. Amyloid fibril composition as a predictor of development of cardiomyopathy after liver transplantation for hereditary transthyretin amyloidosis. *Transplantation* 2012;93:1017–1023.
- [127] Okamoto S, Zhao Y, Lindqvist P, Backman C, Ericzon BG, Wijayatunga P, et al. Development of cardiomyopathy after liver transplantation in Swedish hereditary transthyretin amyloidosis (ATTR) patients. *Amyloid* 2011;18:200–205.
- [128] Muller KR, Padbury R, Jeffrey GP, Poplawski NK, Thompson P, Tonkin A, et al. Poor outcome after liver transplantation for transthyretin amyloid neuropathy in a family with an Ala36Pro transthyretin mutation: case report. *Liver Transpl* 2010;16:470–473.
- [129] Bispo M, Marcelino P, Freire A, Martins A, Mourao L, Barroso E. High incidence of thrombotic complications early after liver transplantation for familial amyloidotic polyneuropathy. *Transpl Int* 2009;22:165–171.
- [130] Pilato E, Dell'Amore A, Botta L, Arpesella G. Combined heart and liver transplantation for familial amyloidotic neuropathy. *Eur J Cardiothorac Surg* 2007;32:180–182.
- [131] Marriott AJ, Hwang NC, Lai FO, Tan CK, Tan YM, Lim CH, et al. Combined heart-liver transplantation with extended cardiopulmonary bypass. *Singapore Med J* 2011;52:e48–e51.
- [132] Coulter-Mackie MB, White CT, Hurley RM, Chew BH, Lange D. Primary Hyperoxaluria Type 1. In: Pagon RA, Adam MP, Bird TD, Dolan CR, Fong CT, Stephens K, editors. *Source GeneReviews™* [Internet]. Seattle (WA): University of Washington, Seattle; 1993–2013. 2002 Jun 19 [updated 2011 Nov 17].
- [133] Watts RW. The clinical spectrum of the primary hyperoxalurias and their treatment. *J Nephrol* 1998;11:4–7.
- [134] van Woerden CS, Groothoff JW, Wanders RJ, Davin JC, Wijburg FA. Primary hyperoxaluria type 1 in The Netherlands: prevalence and outcome. *Nephrol Dial Transplant* 2003;18:273–279.
- [135] Hoppe B, Latta K, von Schnakenburg C, Kemper MJ. Primary hyperoxaluria—the German experience. *Am J Nephrol* 2005;25:276–281.
- [136] Cochat P, Fargue S, Harambat J. Primary hyperoxaluria type 1: strategy for organ transplantation. *Curr Opin Organ Transplant* 2010;15:590–593.
- [137] Bobrowski AE, Langman CB. The primary hyperoxalurias. *Semin Nephrol* 2008;28:152–162.
- [138] Hoppe B, Beck BB, Milliner DS. The primary hyperoxalurias. *Kidney Int* 2009;75:1264–1271.
- [139] Fargue S, Harambat J, Gagnadoux MF, Tsimaratos M, Janssen F, Llanas B, et al. Effect of conservative treatment on the renal outcome of children with primary hyperoxaluria type 1. *Kidney Int* 2009;76:767–773.
- [140] Leumann E, Hoppe B. The primary hyperoxalurias. *J Am Soc Nephrol* 2001;12:1986–1993.
- [141] Toussaint C. Pyridoxine-responsive PH1: treatment. *J Nephrol* 1998;11:49–50.
- [142] Marangella M, Petrarulo M, Vitale C, Bagnis C, Berutti S, Ramello A, et al. The primary hyperoxalurias. *Contrib Nephrol* 2001;11–32.
- [143] Nolkemper D, Kemper MJ, Burdelski M, Vaismann I, Rogiers X, Broelsch CE, et al. Long-term results of pre-emptive liver transplantation in primary hyperoxaluria type 1. *Pediatr Transplant* 2000;4:177–181.
- [144] Galanti M, Contreras A. Excellent renal function and reversal of nephrocalcinosis 8 years after isolated liver transplantation in an infant with primary hyperoxaluria type 1. *Pediatr Nephrol* 2010;25:2359–2362.
- [145] Scheinman JI. Liver transplantation in oxalosis prior to advanced chronic kidney disease. *Pediatr Nephrol* 2010;25:2217–2222.
- [146] Kemper MJ. The role of preemptive liver transplantation in primary hyperoxaluria type 1. *Urol Res* 2005;33:376–379.
- [147] Bergstralh EJ, Monico CG, Lieske JC, Herges RM, Langman CB, Hoppe B, et al. Transplantation outcomes in primary hyperoxaluria. *Am J Transplant* 2010;10:2493–2501.
- [148] Noris M, Remuzzi G. Atypical hemolytic-uremic syndrome. *N Engl J Med* 2009;361:1676–1687.
- [149] Noris M, Caprioli J, Bresin E, Mossali C, Pianetti G, Gamba S, et al. Relative role of genetic complement abnormalities in sporadic and familial aHUS and their impact on clinical phenotype. *Clin J Am Soc Nephrol* 2010;5:1844–1859.
- [150] Lara Jr PN, Coe TL, Zhou H, Fernando L, Holland PV, Wun T. Improved survival with plasma exchange in patients with thrombotic thrombocytopenic purpura-hemolytic uremic syndrome. *Am J Med* 1999;107:573–579.
- [151] Landau D, Shalev H, Levy-Finer G, Polonsky A, Segev Y, Katchko L. Familial hemolytic uremic syndrome associated with complement factor H deficiency. *J Pediatr* 2001;138:412–417.
- [152] Loirat C, Fremeaux-Bacchi V. Atypical hemolytic uremic syndrome. *Orphanet J Rare Dis* 2011;6:60.
- [153] Bresin E, Daina E, Noris M, Castelletti F, Stefanov R, Hill P, et al. Outcome of renal transplantation in patients with non-Shiga toxin-associated hemolytic uremic syndrome: prognostic significance of genetic background. *Clin J Am Soc Nephrol* 2006;1:88–99.
- [154] Loirat C, Fremeaux-Bacchi V. Hemolytic uremic syndrome recurrence after renal transplantation. *Pediatr Transplant* 2008;12:619–629.
- [155] Remuzzi G, Ruggenenti P, Codazzi D, Noris M, Caprioli J, Locatelli G, et al. Combined kidney and liver transplantation for familial haemolytic uraemic syndrome. *Lancet* 2002;359:1671–1672.
- [156] Saland JM, Ruggenenti P, Remuzzi G. Liver-kidney transplantation to cure atypical hemolytic uremic syndrome. *J Am Soc Nephrol* 2009;20:940–949.
- [157] Remuzzi G, Ruggenenti P, Colledan M, Gridelli B, Bertani A, Bettinaglio P, et al. Hemolytic uremic syndrome: a fatal outcome after kidney and liver transplantation performed to correct factor h gene mutation. *Am J Transplant* 2005;5:1146–1150.
- [158] Saland JM, Emre SH, Shneider BL, Benchimol C, Ames S, Bromberg JS, et al. Favorable long-term outcome after liver-kidney transplant for recurrent hemolytic uremic syndrome associated with a factor H mutation. *Am J Transplant* 2006;6:1948–1952.
- [159] Jalanko H, Peltonen S, Koskinen A, Puntilla J, Isoniemi H, Holmberg C, et al. Successful liver-kidney transplantation in two children with aHUS caused by a mutation in complement factor H. *Am J Transplant* 2008;8:216–221.
- [160] Saland JM, Shneider BL, Bromberg JS, Shi PA, Ward SC, Magid MS, et al. Successful split liver-kidney transplant for factor H associated hemolytic uremic syndrome. *Clin J Am Soc Nephrol* 2009;4:201–206.
- [161] Loirat C, Noris M, Fremeaux-Bacchi V. Complement and the atypical hemolytic uremic syndrome in children. *Pediatr Nephrol* 2008;23:1957–1972.
- [162] Cheong HI, Lee BS, Kang HG, Hahn H, Suh KS, Ha IS, et al. Attempted treatment of factor H deficiency by liver transplantation. *Pediatr Nephrol* 2004;19:454–458.
- [163] Haller W, Milford DV, Goodship TH, Sharif K, Mirza DF, McKiernan PJ. Successful isolated liver transplantation in a child with atypical hemolytic uremic syndrome and a mutation in complement factor H. *Am J Transplant* 2010;10:2142–2147.
- [164] Ogier de Baulny H, Saudubray JM. Branched-chain organic acidurias. *Semin Neonatol* 2002;7:65–74.
- [165] Picca S, Dionisi-Vici C, Abeni D, Pastore A, Rizzo C, Orzalesi M, et al. Extracorporeal dialysis in neonatal hyperammonemia: modalities and prognostic indicators. *Pediatr Nephrol* 2001;16:862–867.
- [166] Wajner M, Coelho DM, Barschak AG, Araujo PR, Pires RF, Lulhier FL, et al. Reduction of large neutral amino acid concentrations in plasma and CSF of patients with maple syrup urine disease during crises. *J Inher Metab Dis* 2000;23:505–512.
- [167] Bultron G, Seashore MR, Pashankar DS, Husain SZ. Recurrent acute pancreatitis associated with propionic acidemia. *J Pediatr Gastroenterol Nutr* 2008;47:370–371.
- [168] Strauss KA, Mazariegos GV, Sindhri R, Squires R, Finegold DN, Vockley G, et al. Elective liver transplantation for the treatment of classical maple syrup urine disease. *Am J Transplant* 2006;6:557–564.
- [169] Kasahara M, Horikawa R, Tagawa M, Uemoto S, Yokoyama S, Shibata Y, et al. Current role of liver transplantation for methylmalonic acidemia: a review of the literature. *Pediatr Transplant* 2006;10:943–947.
- [170] Morioka D, Kasahara M, Horikawa R, Yokoyama S, Fukuda A, Nakagawa A. Efficacy of living donor liver transplantation for patients with methylmalonic acidemia. *Am J Transplant* 2007;7:2782–2787.

## Frontiers in Liver Transplantation

- [171] Barshes NR, Vanatta JM, Patel AJ, Carter BA, O'Mahony CA, Karpen SJ, et al. Evaluation and management of patients with propionic acidemia undergoing liver transplantation: a comprehensive review. *Pediatr Transplant* 2006;10:773–781.
- [172] Kasahara M, Sakamoto S, Kanazawa H, Karaki C, Kakiuchi T, Shigeta T, et al. Living-donor liver transplantation for propionic acidemia. *Pediatr Transplant* 2012;16:230–234.
- [173] Vara R, Turner C, Mundy H, Heaton ND, Rela M, Mieli-Vergani G, et al. Liver transplantation for propionic acidemia in children. *Liver Transpl* 2011;17:661–667.
- [174] Rela M, Battula N, Madanur M, Mieli-Vergani G, Dhawan A, Champion M, et al. Auxiliary liver transplantation for propionic acidemia: a 10-year follow-up. *Am J Transplant* 2007;7:2200–2203.
- [175] Nyhan WL, Gargus JJ, Boyle K, Selby R, Koch R. Progressive neurologic disability in methylmalonic acidemia despite transplantation of the liver. *Eur J Pediatr* 2002;161:377–379.