EJVES Extra (2011) 21, e29–e31

SHORT REPORT

Massive Penoscrotal Hematoma and Testicular Ischemia from Failed Vascular Closing Device

H.V. Polavarapu [a,*], J.M. Reyes [b], E.J. Anoia [a], R.A. Jubelirer [a]

[a] Department of Surgery, Abington Memorial Hospital, Abington, PA 19001, USA
[b] Department of Urology, Temple University Hospital, Philadelphia, PA 19140, USA

Submitted 7 January 2011; accepted 11 March 2011

KEYWORDS
Pseudoaneurysm;
Hematoma;
Cardiac catheterization;
Femoral artery;
Scrotum

Abstract Vascular closing devices (VCD) were developed as an alternative to mechanical compression devices for hemostasis at arterial access site after cardiac catheterization (CC). We report a case of expanding penoscrotal hematoma compromising blood flow to ipsilateral testicle following a VCD use, an unusual presentation of access site hematoma. The patient was explored emergently and the testicle was salvaged by evacuating the hematoma. This case highlights the importance of early investigation and where indicated, exploration of arterial access site hematomas and reviews the current role of various VCDs and alternative arterial access in CC.

The global use of coronary interventions is growing annually. Along with major coronary complications, complications related to the site of peripheral arterial access following a diagnostic cardiac catheterisation (CC) include haematoma, bleeding, infection, pseudoaneurysm and arteriovenous fistula. We report a case of expanding access site haematoma that dissected into the tissue planes causing a massive penoscrotal haematoma and, subsequently, testicular ischaemia. This case highlights the importance of early investigation and, where indicated, exploration of the haematomas at the arterial access site.

Case Description

A 34-year-old male presented to the emergency room with sudden onset of right inguino-scrotal swelling and pain after a CC 12 h earlier for atypical chest pain. History included hypertension and end-stage renal disease on haemodialysis. The patient was not taking anticoagulation or anti-platelet agents. Vascular closing device (VCD) was used for haemostasis; neither manual compression nor mechanical compression devices were used.

On examination, the right groin and penis were swollen and the scrotum was tense (Fig. 1). The patient was

DOI of original article: 10.1016/j.ejvs.2011.03.025.
* Corresponding author. Tel.: +1 (215) 481 7183; fax: +1 (215) 481 2159.
E-mail address: hpolavarapu@amh.org (H.V. Polavarapu).

1533-3167
doi:10.1016/j.ejvsextra.2011.03.001

Figure 1 Expansile penoscrotal hematoma from the pseudoaneurysm.

haemodynamically stable. Ultrasound showed pseudoaneurysm of the right common femoral artery with communication to a large scrotal haematoma (Fig. 2). No appreciable blood flow to the right testicle was identified; the left testicle had normal blood flow. Packed red blood cells were transfused for his haemoglobin of 5.7 g dl^{-1} (14—18 g dl^{-1}).

During emergent operative exploration, the angioseal patch was found at the level of the deep fascia. On opening the fascia, active bleeding was identified from a small defect in the common femoral artery, which was repaired. A large amount of clot was evacuated from the tissue planes of the scrotum, which was compressing the right testicle. After an intra-operative ultrasound demonstrated normal blood flow to both testes, the incision was closed with a drain in place.

Postoperative recovery was uneventful, and the patient was discharged home on hospital day 4.

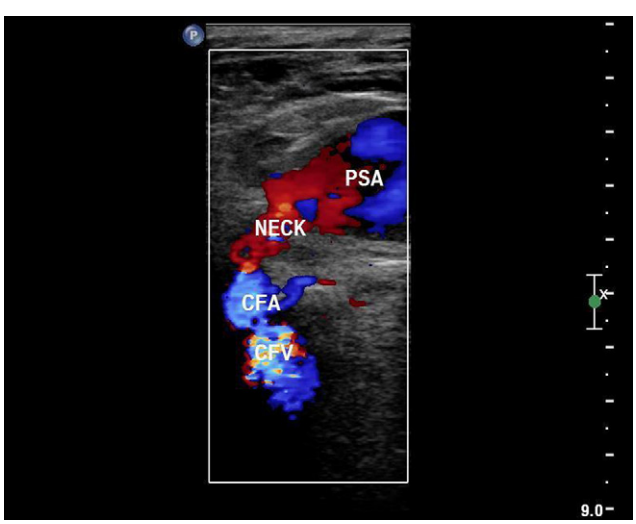

Figure 2 Ultrasound image of right groin showing pseudoaneurysm (PSA), common femoral vein (CFV) and common femoral artery (CFA), with active flow through the neck of the aneurysm.

Discussion

Haemostasis at the vascular access site after CC is usually achieved by manual compression with or without the use of adjunctive mechanical compression devices. Thereafter, prolonged bed rest is often recommended. To shorten bed rest and replace these mechanical compression devices, VCDs have been developed.

Various VCDs currently available include a suture-like stitch placed around the femoral artery; collagen plugs, with or without an anchor from inside the artery; and balloon-positioning catheters combined with bovine microfibrillar collagen and thrombin. The reported overall vascular complication rates from VCDs range from 1.5% to 9%, with 20—40% of patients who experience such complications requiring surgical repair.[1]

In the case reported herein, a VCD had been selected for closure. Access site haematoma following CC is a known complication, but massive penoscrotal hematoma compromising testicular blood flow has not been reported in the literature. There are two case reports of scrotal haematoma after CC in the literature.[2,3] In neither of these were VCDs used for haemostasis. Our case is unique not only because it involved the use of VCD, but also because the haematoma and ischaemia involved the entire penis and scrotum, compromising the testicular blood flow.

The superiority of VCDs over traditional mechanical compression in terms of overall incidence of access-related complications was not demonstrated in two large meta-analyses.[4,5]

Potential strategies to reduce bleeding include improved puncture technique, individually tailored and monitored anticoagulant and anti-platelet treatments and alternative arterial access.

The use of transradial approach for CC has been shown to dramatically reduce transfusion related to the access site. The principal findings of the M.O.R.T.A.L study (Mortality benefit Of Reduced Transfusion after PCI via the Arm or Leg (M.O.R.T.A.L)) by Chase et al. showed that there is a reduction in 30-day and 1-year mortality associated with halving of transfusion rate using transradial instead of femoral access in all comers to CC.[6] The continued unpopularity of this approach may be due to its lower procedural success rates and increased technical demands.[7] This approach, however, would not have been an option in our patient because of the need to preserve his radial artery for dialysis access.

VCDs are shown to be helpful in early ambulation and discharge, but these advantages come at a price of increased access site complications. Judicial use of VCDs in selective patient populations, post-procedural monitoring with a high level of suspicion accompanied by patient education will help in the prevention and early identification of these complications. Our patient in this study with end-stage renal disease would represent a typical case where the need for closer post-procedural monitoring is indicated. With its decreased access site complication rate and simplified post-procedural care, the transradial approach should strongly be considered.

Conflict of Interest/Funding

None.

References

1 Nasser T, Mohler ER, Wilensky R, Hathaway D. Peripheral vascular complications following coronary interventional procedures. *Clin Cardiol* 1995;**18**:609—14.

2 Borden TA, Rosen RT, Schwarz GR. Massive scrotal hematoma developing after transfemoral cardiac catheterization. *Am Surg* 1974;**40**(3):193—4.

3 Thomas AA, Hedgepeth R, Sarac TP, Vasavada SP. Massive scrotal hematoma following transfemoral cardiac catheterization. *Can J Urol* 2008;**15**(2):4020—3.

4 Koreny M, Riedmüller E, Nikfardjam M, Siostrzonek P, Müllner M. Arterial puncture closing devices compared with standard manual compression after cardiac catheterization: systematic review and meta-analysis. *JAMA* 2004;**291**:350—7.

5 Nikolsky E, Mehran R, Halkin A, Aymong ED, Mintz GS, Lasic Z, et al. Vascular complications associated with arteriotomy closure devices in patients undergoing percutaneous coronary procedures: a meta-analysis. *J Am Coll Cardiol* 2004;**44**(6):1200—9.

6 Chase AJ, Fretz EB, Warburton WP, Klinke WP, Carere RG, Pi D, et al. Association of the arterial access site at angioplasty with transfusion and mortality: the M.O.R.T.A.L study. *Heart* 2008; **94**(8):1019—25.

7 Brueck M, Bandorski D, Kramer W, Wieczorek M, Höltgen R, Tillmanns H. A randomized comparison of transradial versus transfemoral approach for coronary angiography and angioplasty. *JACC Cardiovasc Interv* 2009;**2**(11):1047—54.