



## Reconstruction after pancreatic trauma by pancreaticogastrostomy



Gonzalo Martín Martín\*, Patricia Jiménez Morillas, José C. Rodríguez Pino, José M. Morón Canis, Francesc X. González Argente

General & Digestive Surgery Department, Hospital Universitario Son Espases, Carretera de Valldemossa, 79, Palma de Mallorca, Spain

### ARTICLE INFO

#### Article history:

Received 3 December 2014

Received in revised form 18 February 2015

Accepted 23 February 2015

Available online 26 February 2015

#### Keywords:

Blut abdominal trauma

Pancreatic trauma

Pancreatogastrostomy

Horse-riding abdominal trauma

Distal pancreatic preservation

### ABSTRACT

**INTRODUCTION:** Pancreatic lesions are very infrequent after closed abdominal trauma (5% of cases) with a complication rate that affects 30–40% of patients, and a mortality rate that can reach 39%. In our experience, closed abdominal traumatism occurring at typical popular horse-riding festivals in our region constitute a high risk of pancreatic trauma. The purpose of the present paper is to raise awareness about our experience in the diagnosis and treatment of pancreatic lesions secondary to closed abdominal traumatism.

**PRESENTATION OF CASE:** We present the clinical cases of two young patients who, after suffering blunt abdominal trauma secondary to the impact of a horse during the celebration of typical horse-riding festival, were diagnosed with pancreatic trauma type III. The treatment was surgical in both cases and consisted in performing a pancreaticogastric anastomosis with preservation of the distal pancreas and spleen. The postoperative period was uneventful and, at present, both patients are asymptomatic.

**DISCUSSION:** Signs and symptoms caused by pancreatic lesion are unspecific and difficult to objectify. With some limitations CT is the imaging test of choice for diagnosis and staging in the acute phase. The Wirsung section is indication for surgical treatment. The most extended surgical procedure in these cases is the resection of pancreatic body, tail, and spleen.

**CONCLUSION:** The identification of a pancreatic injury after closed abdominal trauma requires a high suspicion based on the injury mechanism. A safer option may be the distal pancreatic preservation with pancreaticogastric anastomosis in grade III lesions with healthy pancreatic tissue.

© 2015 The Authors. Published by Elsevier Ltd. on behalf of Surgical Associates Ltd. This is an open access article under the CC BY-NC-ND license (<http://creativecommons.org/licenses/by-nc-nd/4.0/>).

## 1. Introduction

Pancreatic lesions are very infrequent after closed abdominal trauma (5% of cases) with a complication rate that affects 30–40% of patients, and a mortality rate that can reach 39% [1,2]. In our experience, closed abdominal traumatism occurring at typical popular horse-riding festivals in our region constitute a high risk of pancreatic trauma [3]. The purpose of the present paper is to raise awareness about our experience in the diagnosis and treatment of pancreatic lesions secondary to closed abdominal traumatism.

## 2. Presentation of case

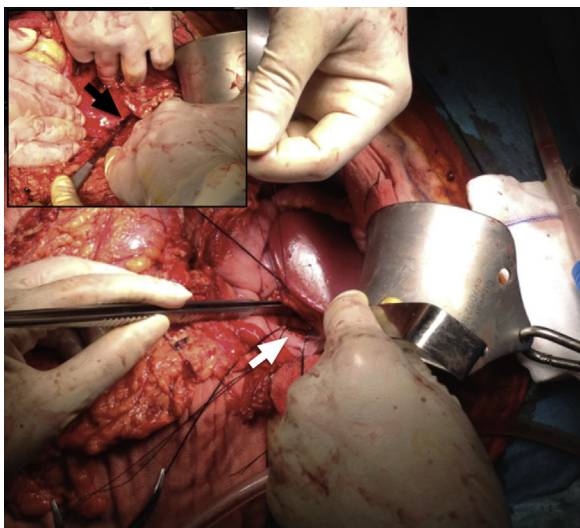
### 2.1. Case 1

A 15-year-old female who suffered closed abdominal trauma and abdominal crushing after falling from a horse presented

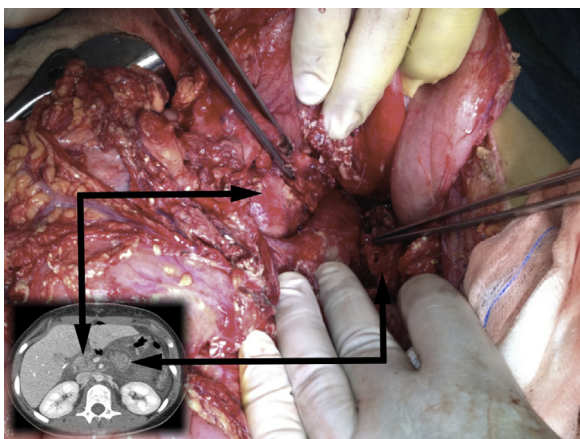
to the emergency room (ER) with abdominal pain and hemodynamic instability. A Focused Abdominal Sonography for Trauma (FAST) was performed which revealed the presence of free liquid. The intraoperative findings showed small hepatic laceration. During the immediate postoperative period there was no clinical improvement, and high levels of amylase in the serum were observed. Thus, an abdominal computed tomography (CT) was requested. It reported a complete section at the pancreatic isthmus level. The patient was transferred to our center where an urgent re-intervention was performed. Image findings were confirmed intraoperatively and, after checking the viability of the pancreatic tissue, a proximal closure was performed with mechanical suture and distal posterior pancreaticogastrostomy (Fig. 1). The pancreaticogastric anastomosis was performed on the back side of the greater curvature of the stomach with non-absorbable monofilament suture dashed through an anterior assistance gastrostomy, which was subsequently closed with a continuous monofilament suture. For the introduction of the pancreas into the stomach, four transmural sutures were used. After completing the anastomosis, the latter were removed. The evolution was satisfactory reaching oral intake on the third postoperative day and the drainage was removed after ruling out postoperative pancreatic fistula (POPF).

\* Corresponding author at: General & Digestive Surgery Department, Hospital Universitario Son Espases, Carretera de Valldemossa, 79, PC: 07120, Palma de Mallorca, Spain. Tel.: +34 686328041.

E-mail address: [martin.martin.g@icloud.com](mailto:martin.martin.g@icloud.com) (G.M. Martín).



**Fig. 1.** The image shows the intraoperative findings and the reconstruction phase in Section 2.1. The black arrow indicates the line of pancreatic section at the isthmus. The white arrow shows the pancreaticogastric anastomosis through the anterior assistance gastrotomy.



**Fig. 2.** Correlation of radiological and intraoperative CT imaging where the entire section of the pancreatic gland in the neck is observed. The arrows indicate the pancreatic head and body–tail, respectively.

After one and a half years of follow-up the patient is now asymptomatic.

## 2.2. Case 2

A 16-year-old female came to the ER after a closed abdominal trauma caused by a horse kick. Physical examination showed epigastric abdominal pain with no signs of peritoneal irritation, as well as significant blood amylase levels. Suspecting pancreatic gland compromise, a CT was performed with unspecific report and, subsequently, a magnetic resonance cholangiography (MRCP) was also performed where a complete pancreatic fracture at the pancreatic isthmus was observed. During the exploratory laparotomy the radiological findings were confirmed (Fig. 2) and a closure of the cephalic pancreatic portion was performed with non-absorbable monofilament suture and distal posterior pancreaticogastrostomy. Reconstruction was performed following the same steps as those described in Section 2.1. Three days after the operation, she presented low-output of type A POPF, which was handled conservatively. Seventeen days after the operation the patient was

discharged and eight months after the operation, she is currently asymptomatic.

## 3. Discussion

Abdominal high energy traumas, such as those caused by horse-riding accidents may provoke the transection of the pancreatic gland by crushing the retroperitoneal structures against the spinal column [1]. The most affected region is the neck in 37% of cases [2,4]. The retroperitoneal location of the pancreas means that the signs and symptoms caused by the lesion are unspecific and difficult to objectify [5]. Evidence suggesting a potential pancreatic injury includes a history of high-energy trauma in the epigastrium [6]. Regarding other initial complementary tests, we acted in accordance with Advanced Trauma Life Support protocols in ER [2,6,7]. 40% of patients with pancreatic injury present normal serum amylase levels [1]. With some limitations, CT is the imaging test of choice for diagnosis and staging in the acute phase [4]. If the suspicion of pancreatic injury persists and the CT findings are negative, endoscopic retrograde cholangiopancreatography (ERCP) and/or MRCP can prove useful. MRCP seems to be more effective than CT in assessing the integrity of the pancreatic duct in differential diagnosis but not in the acute phase [8]. The ERCP is the best imaging technique to visualize the Wirsung, but its availability is limited [1]. Once diagnosed, we stage the pancreatic injury according to the American Association for the Surgery of Trauma [4]. The pancreatic injury complete transection (types III–V) is indication for surgical treatment [2]. The most extended surgical procedure for a complete traumatic pancreatic section in the neck is the resection of pancreatic body, tail, and spleen. On average, distal pancreatectomy involves resections of 56% of the pancreatic gland [5,9]. While endocrine and/or exocrine failure of the pancreas is uncommon after pancreatic trauma if more than 20% of the glandular tissue is conserved, it is all the more important to conserve as much pancreatic tissue and spleen as possible in the case of young patients [1,10]. In the case of distal pancreas preservation, it is common to perform a pancreaticojejunal anastomosis and Roux Y. In our experience, with evidence of the complete lesion of the main duct at the neck level and after checking the viability of the pancreatic tissue intraoperatively, we chose to perform distal pancreatic preservation with pancreaticogastric anastomosis. After a thorough review of existing literature, we found no clear consistency in the choice of the surgical reconstruction technique after type III pancreatic trauma. The two most important determining prognostic factors are the state of the main pancreatic duct and the time from the injury to definitive treatment [1].

## 4. Conclusion

In conclusion, a safer option may be the distal pancreatic preservation with pancreaticogastric anastomosis in grade III lesions with healthy pancreatic tissue. We believe that further studies with larger series are needed to achieve greater evidence for this surgical technique.

## Conflict of interest

All authors declare no conflict of interest existence.

## Funding

There are no sources of funding in this research.

### Ethical approval

This work has the approval of the ethical committee of the Hospital Son Espases where the patients were treated.

### Consent

Written informed consent was obtained from the patient for publication of this case report and accompanying images. A copy of the written consents is available for review by the Editor-in-Chief of this journal on request.

### Author contribution

All authors contributed to treat the cases presented.

All authors contributed in gathering information, studying the literature, and writing this paper.

### Guarantor

The Guarantor of this work is Gonzalo Martin Martin.

### References

- [1] G.J. Jurkovich, Pancreatic and duodenal injuries, in: A. Cassan (Ed.), ACS Surgery Principles & Practice, vol. 1, B.C. Decker, Spanish Ed. Barcelona, 2013, pp.21–35.
- [2] A. Subramanian, C.J. Dente, D.V. Feliciano, The management of pancreatic trauma in the modern era, *Surg. Clin. N. Am.* 87 (2007) 1515–1532.
- [3] A. Buenaventura, Horse at the festival, in: A. Buenaventura (Ed.), *Menorca, Horses and Popular Tradition*, Menorca Editorial, Mahon, 2007.
- [4] K. Maeda, S. Ono, K. Baba, I. Kawahara, Management of blunt pancreatic trauma in children, *Pediatr. Surg. Int.* 29 (2013) 1019–1022.
- [5] R. Hutchins, R. Hart, Long-term results of distal pancreatectomy for chronic pancreatitis in 90 patients, *Ann. Surg.* 236 (2002) 6128.
- [6] American College of Surgeons, Advanced trauma life support, in: P.N. Scardiglia (Ed.), *Advanced Trauma Life Support*, 8th edition, American College of Surgeons, Chicago, 2008.
- [7] J. Asensio, J.C. García, P. Petrone, G. Roldán, M. Pardo, et al., Pancreatic trauma: complex lesions, difficult treatments, *Cir. Esp.* 74 (2003) 124–133.
- [8] J.W. Stuhifaut, K.W. Fleming, B.C. Lucey, J.A. Soto, Blunt trauma of the pancreas and biliary tract: a multimodality imaging approach to diagnosis, *Radiographics* 24 (2004) 1381–1395.
- [9] W. Jones, J. Finkelstein, Managing pancreatic trauma, *Infect. Surg.* 3 (1990) 29–36.
- [10] S. Jacko, V. Sim, A. Cernero, S.R. Todd, Traumatic distal pancreatic transection: beware of the horses, *J. Trauma Nurs.* 19 (2012) 102–103.

### Open Access

This article is published Open Access at [sciedirect.com](http://sciedirect.com). It is distributed under the [IJSCR Supplemental terms and conditions](#), which permits unrestricted non commercial use, distribution, and reproduction in any medium, provided the original authors and source are credited.